

Parto Resaneh



@Parto\_Resaneh



Shenoto.com/PartoResaneh

<http://PartoResaneh.blog.ir>

بسم الله الرحمن الرحيم

فایل ضمیمه آموزش مبانی MRI-قسمت ۴

کاری از کیانوش حسینی

تمامی حقوق این اثر برای پرتو رسانه محفوظ است. (۱۳۹۶)

تصاویر این ضمیمه از کتاب MRI In Practice اخذ شده است.

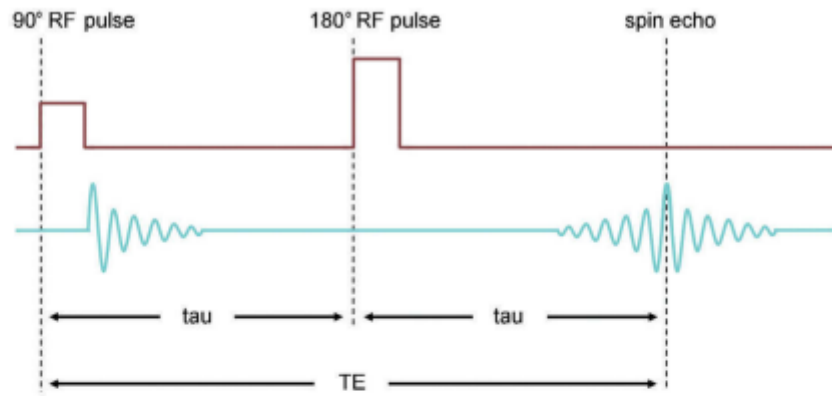


Figure 2.20 TAU.

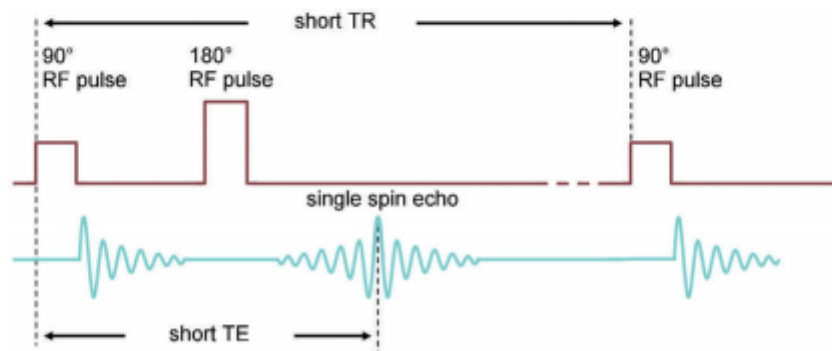


Figure 2.21 Spin echo with one echo.

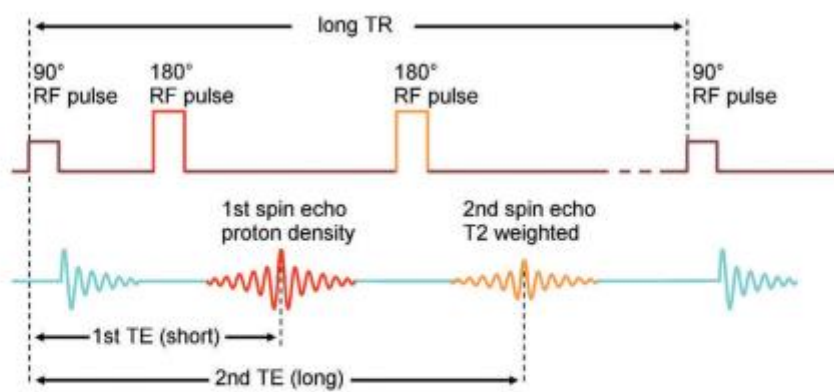
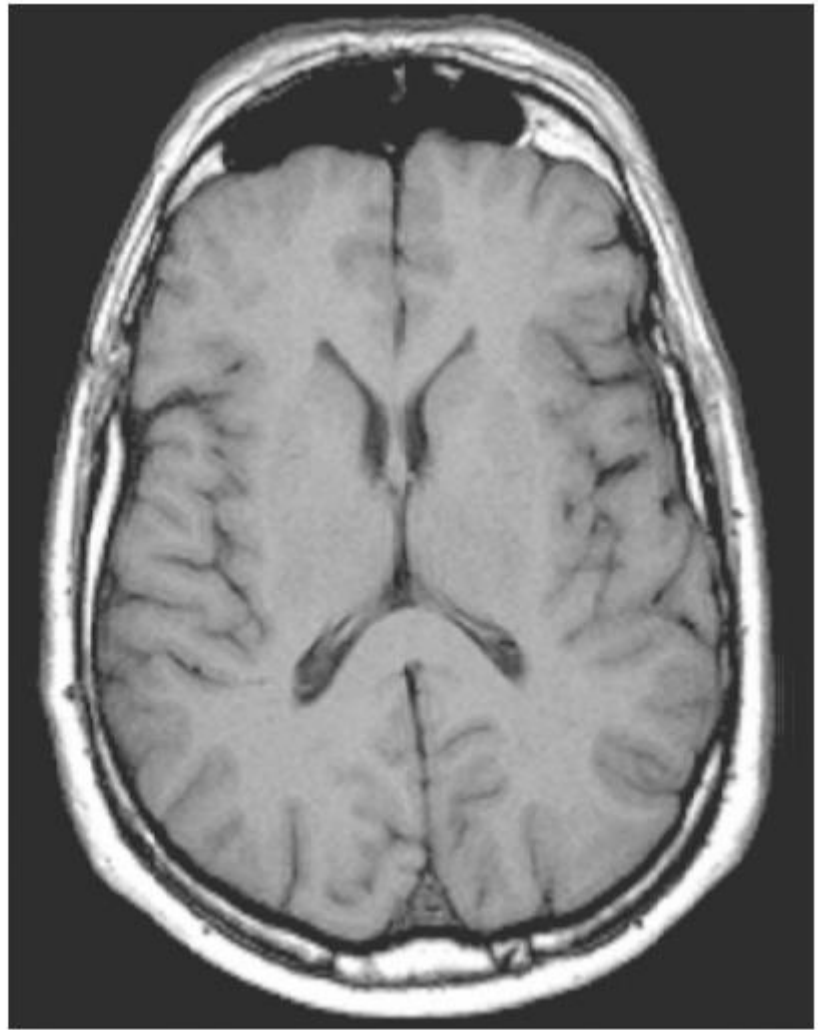
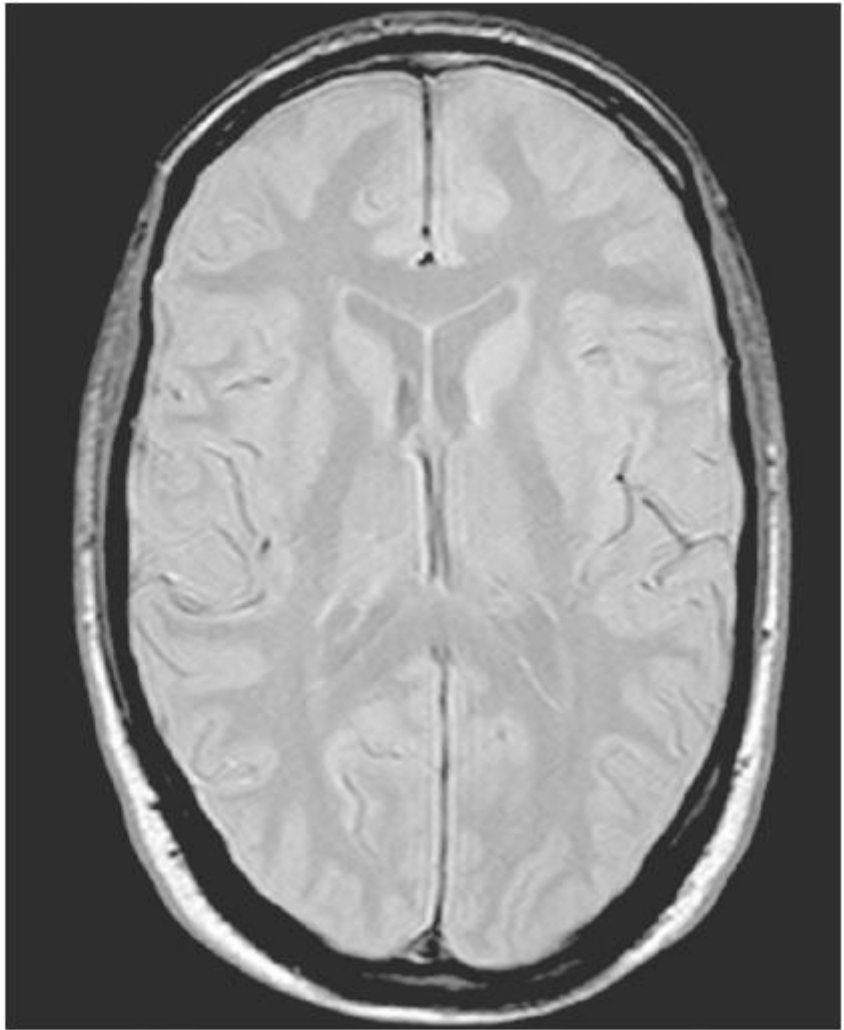


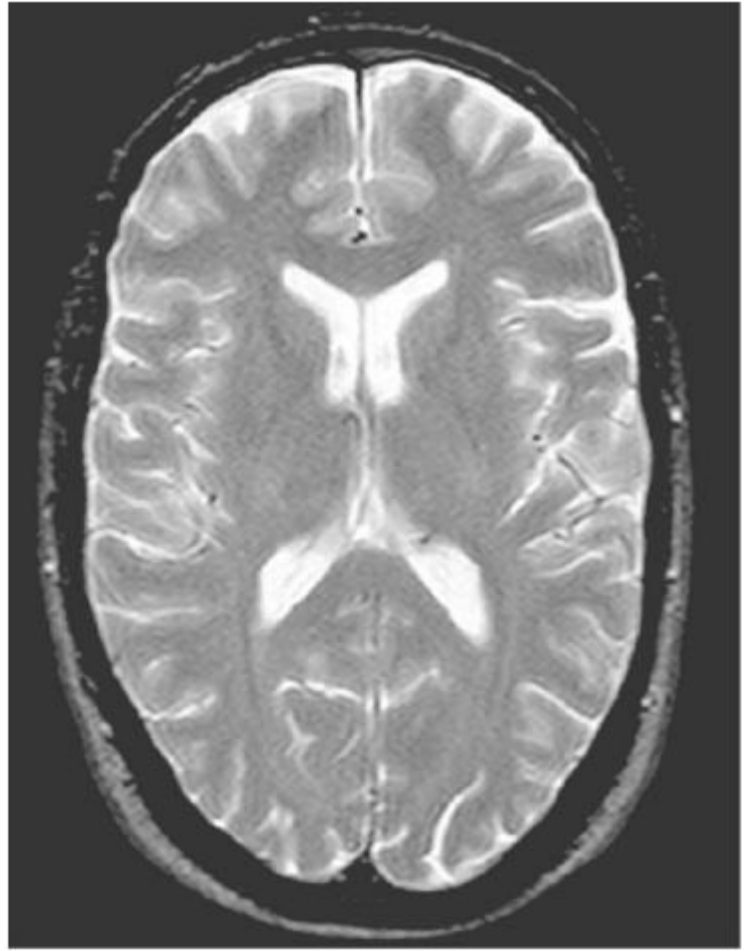
Figure 2.22 Spin echo with two echoes.



**Figure 2.23** Axial T1 weighted spin echo image through the brain.



**Figure 2.24** Axial PD weighted spin echo image through the brain.



**Figure 2.25** Axial T2 weighted spin echo image through the brain.

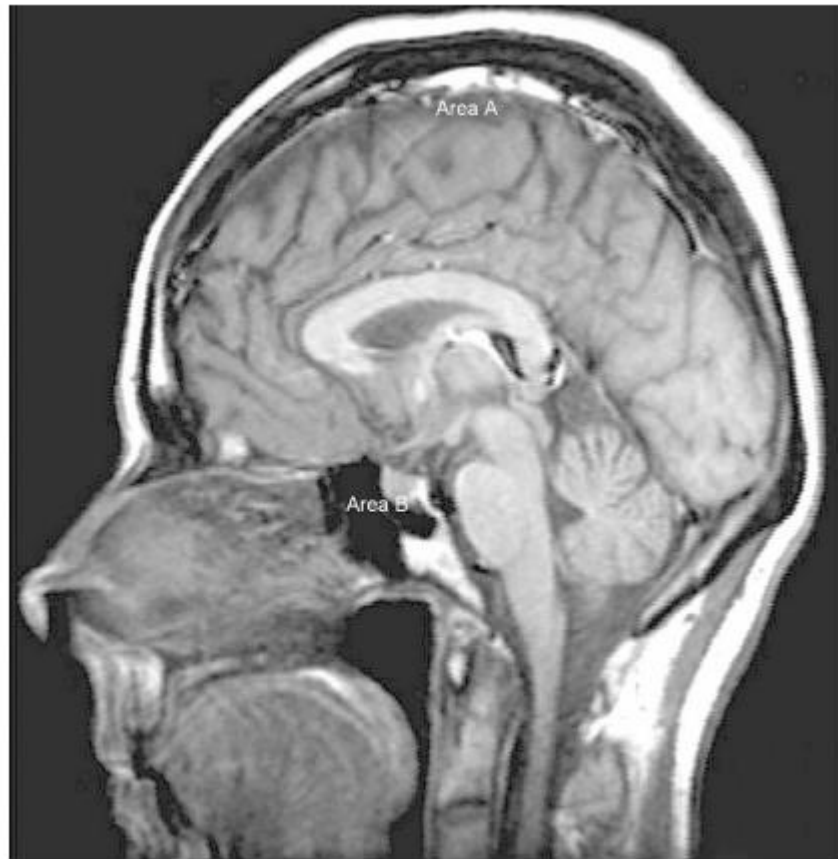


Figure 2.26 Midline sagittal T1 weighted spin echo image through the brain.

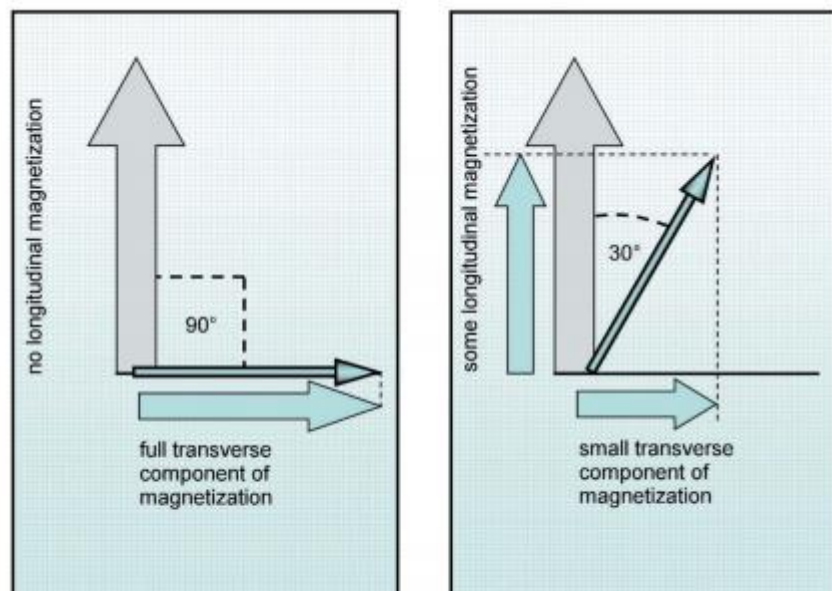


Figure 2.27 How the flip angle controls the amplitude of the signal.

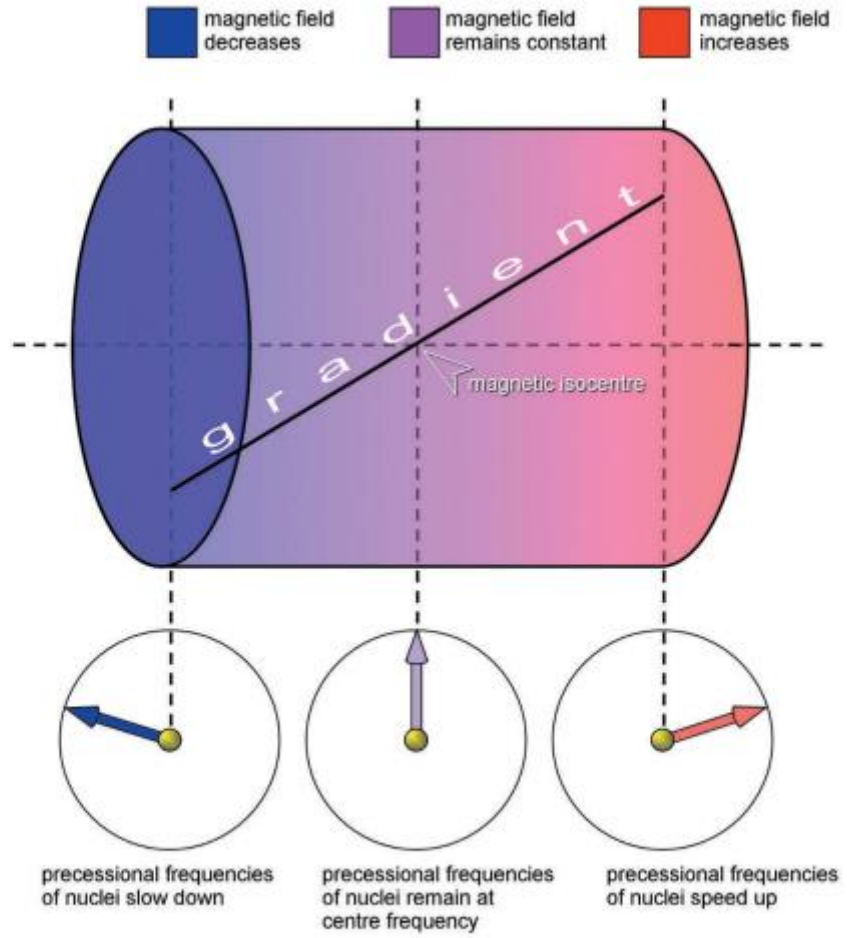


Figure 2.28 The gradients.