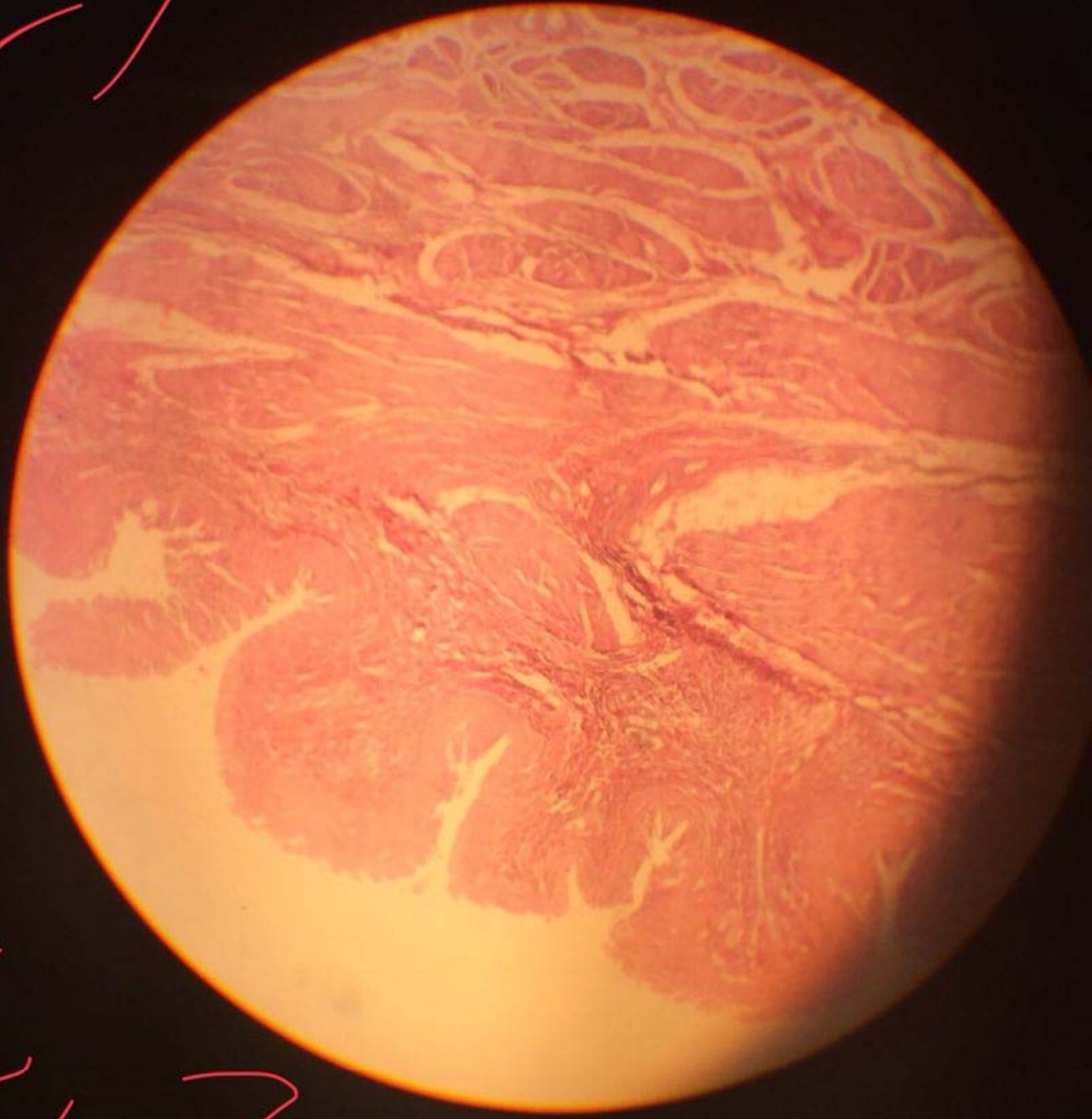
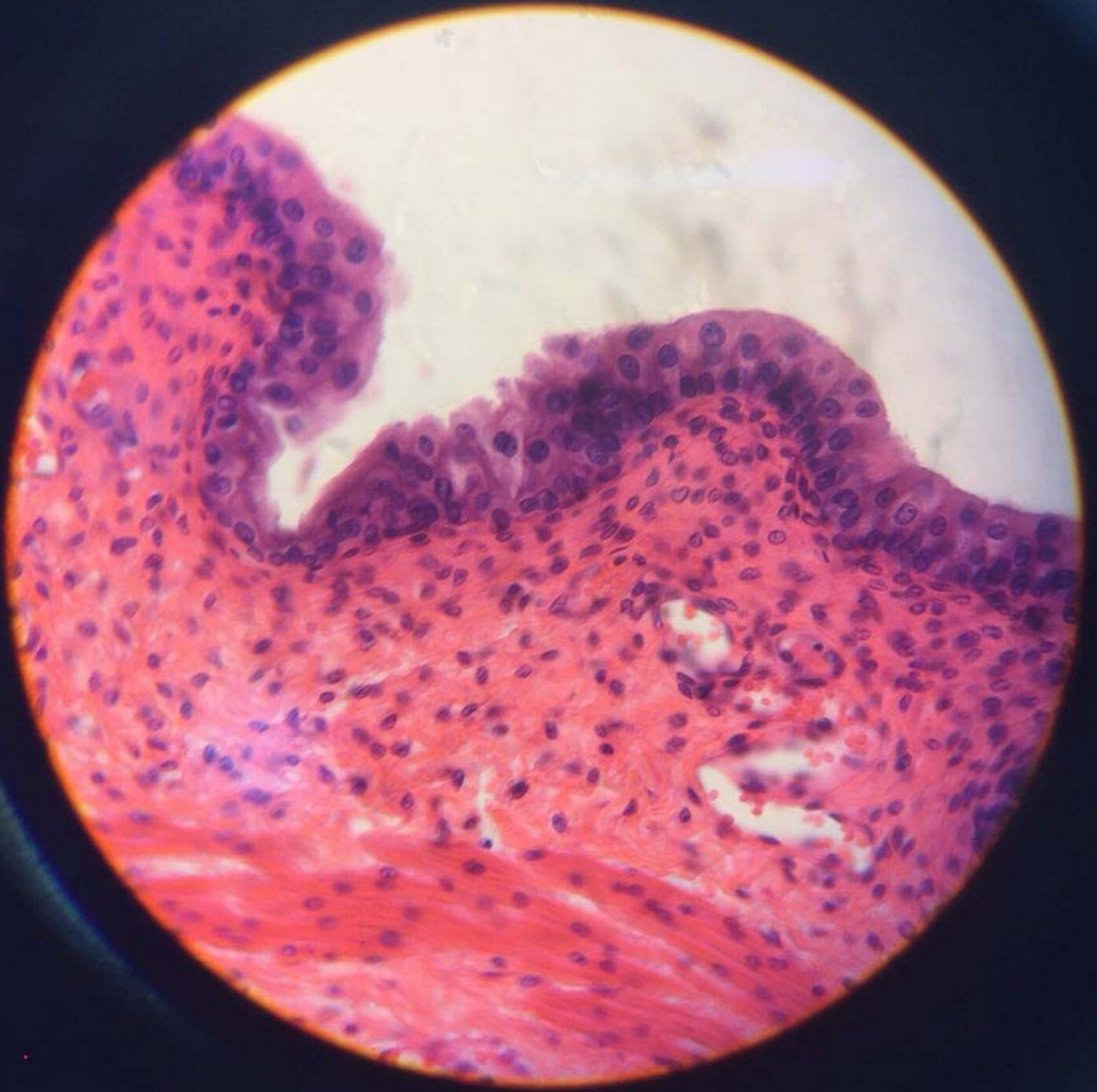
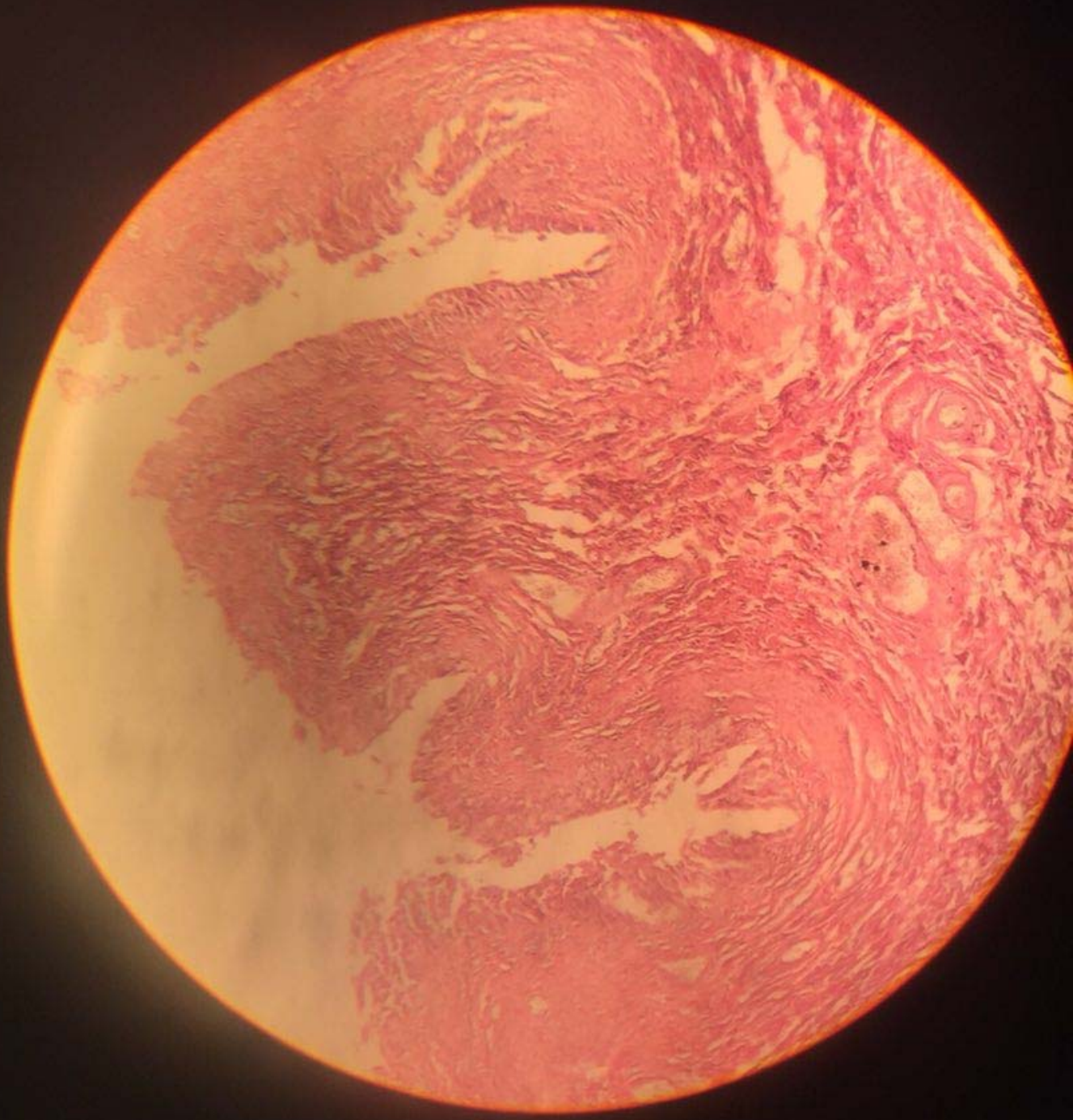
Handwritten pink scribbles in the top left corner, consisting of several overlapping, irregular lines.



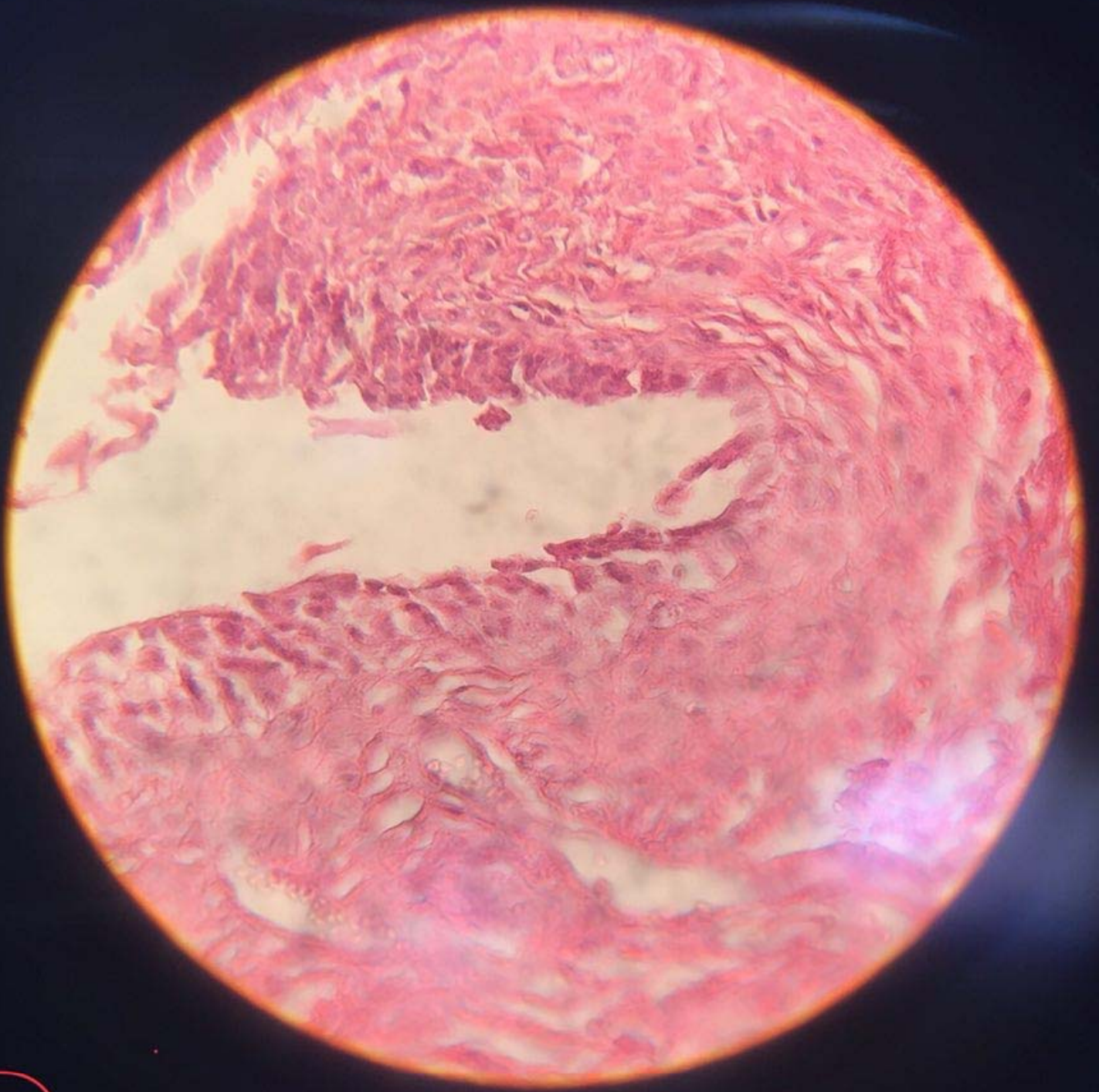Handwritten pink scribbles in the bottom left corner, consisting of several overlapping, irregular lines.



Handwritten red ink scribbles at the bottom of the page, possibly representing a signature or initials.



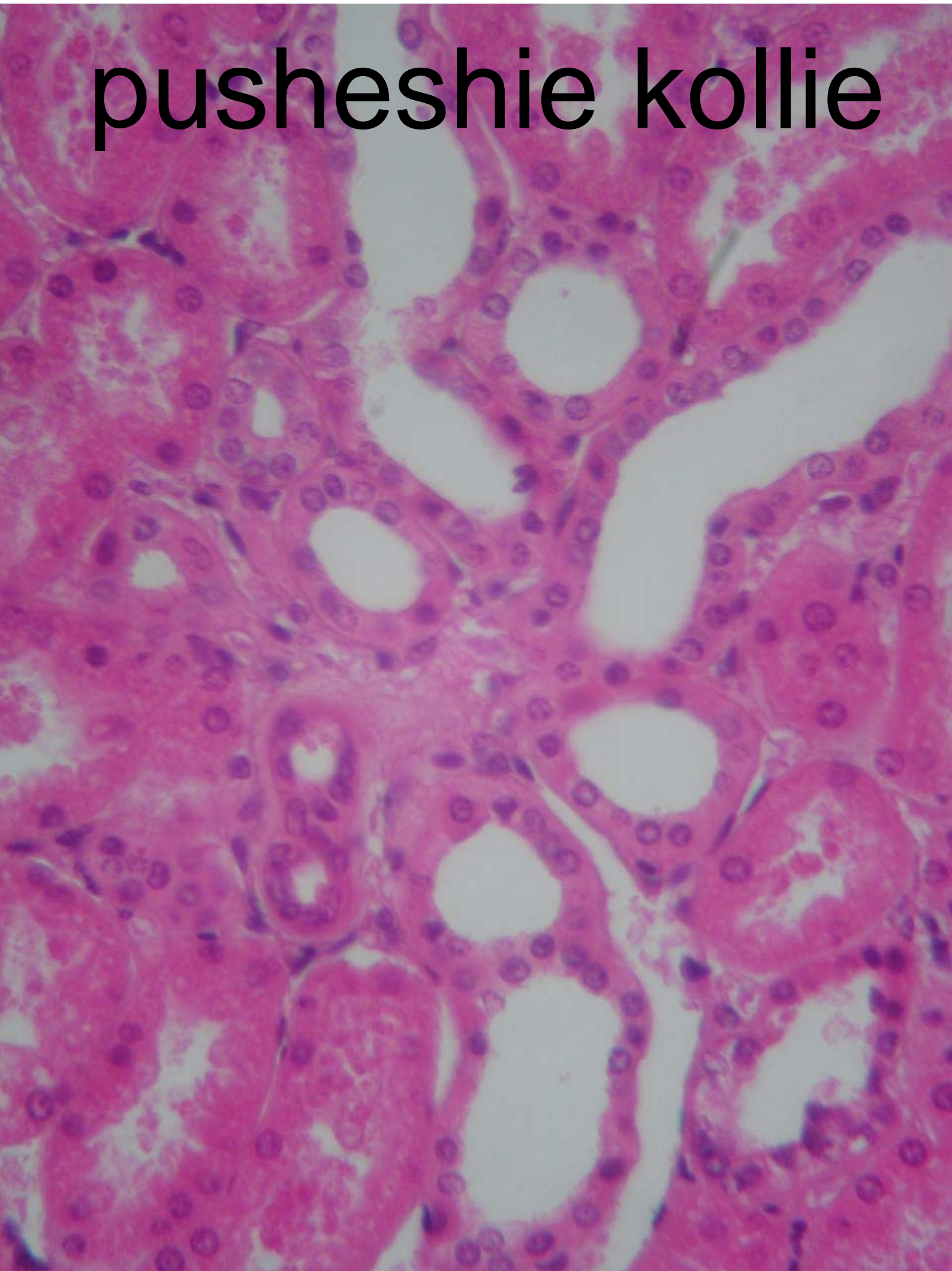
2010/03/20



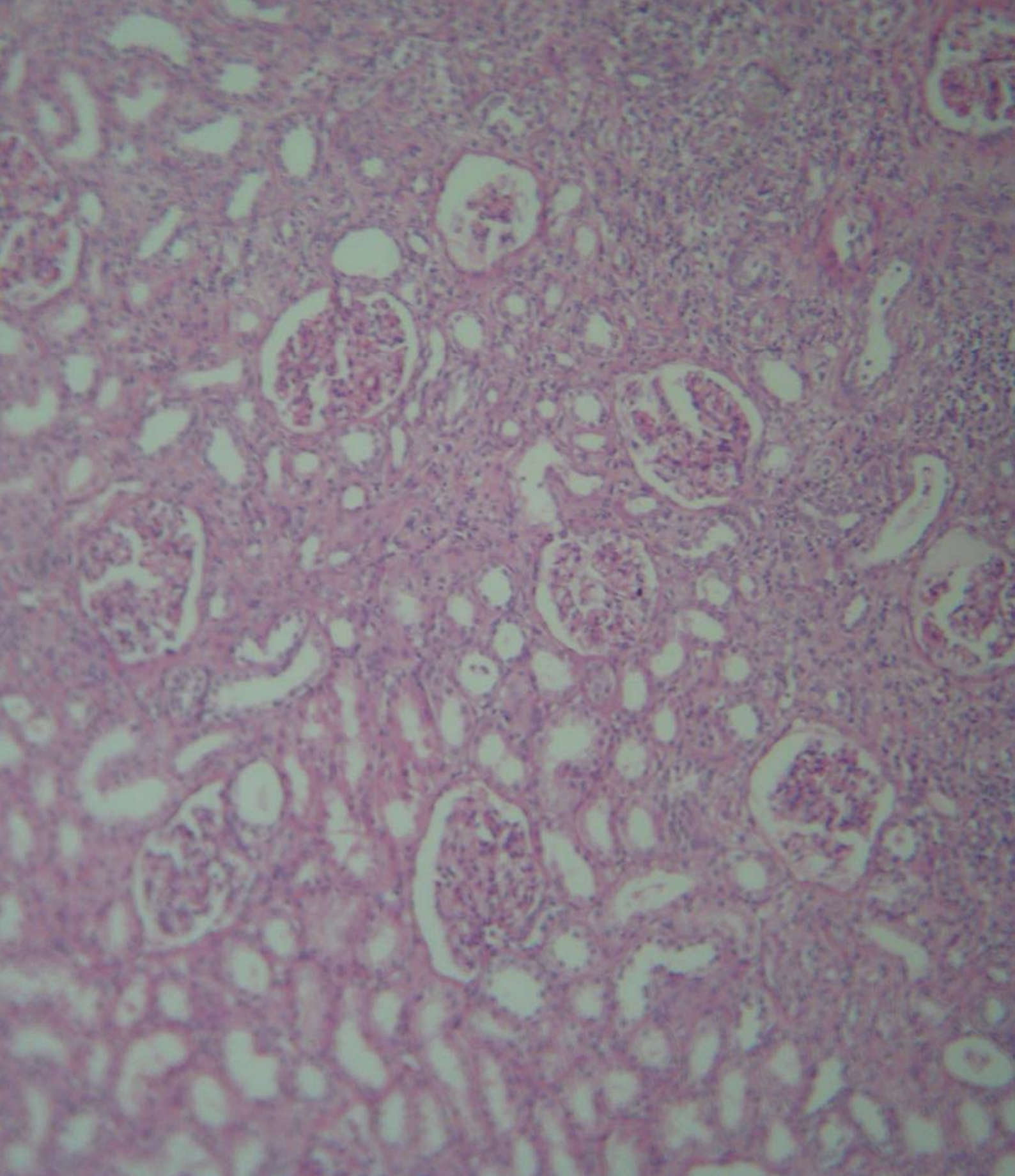
Handwritten red markings, possibly a signature or initials, located below the microscopic image.

pusheshie kollie

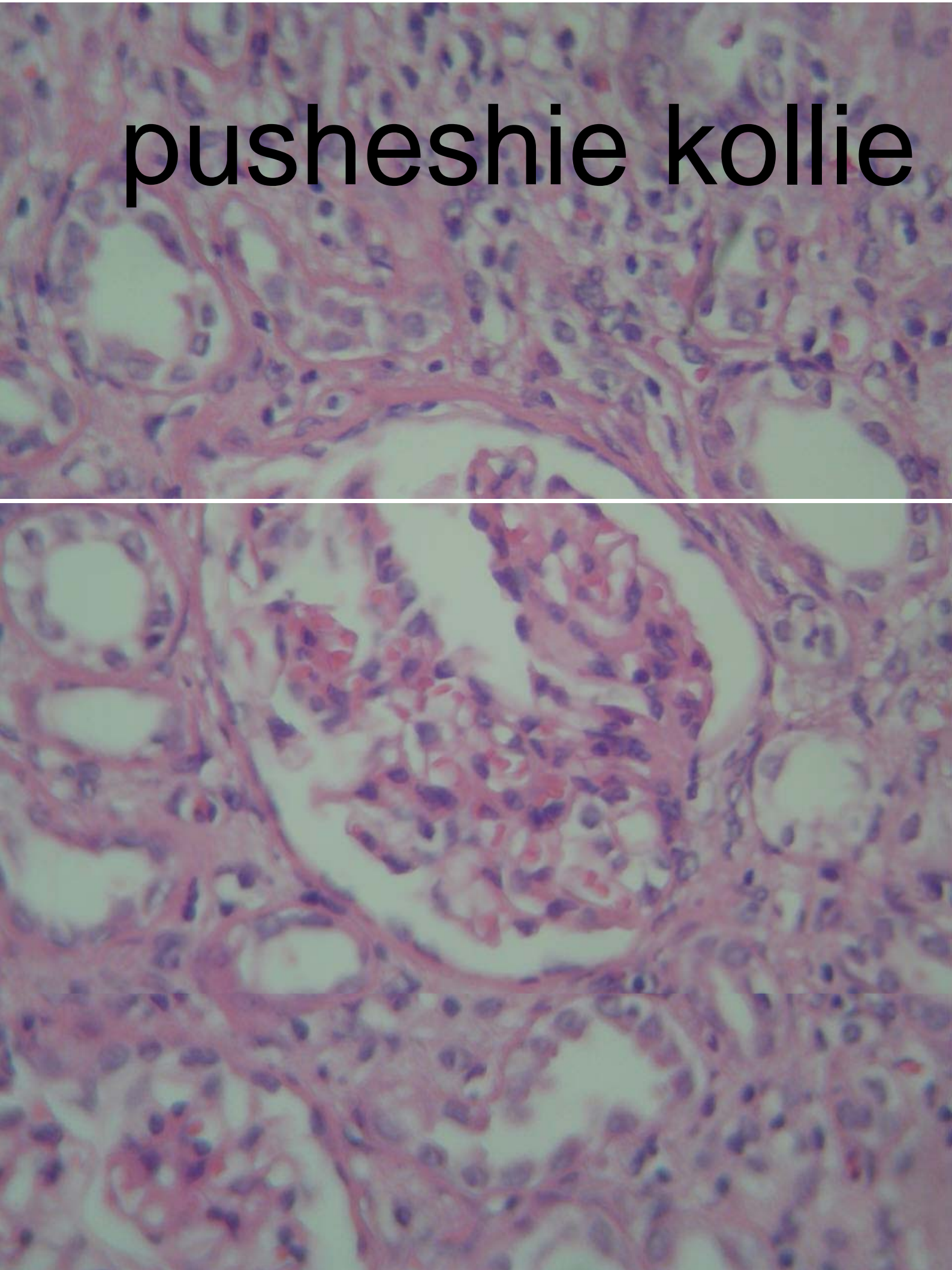
pusheshie kollie



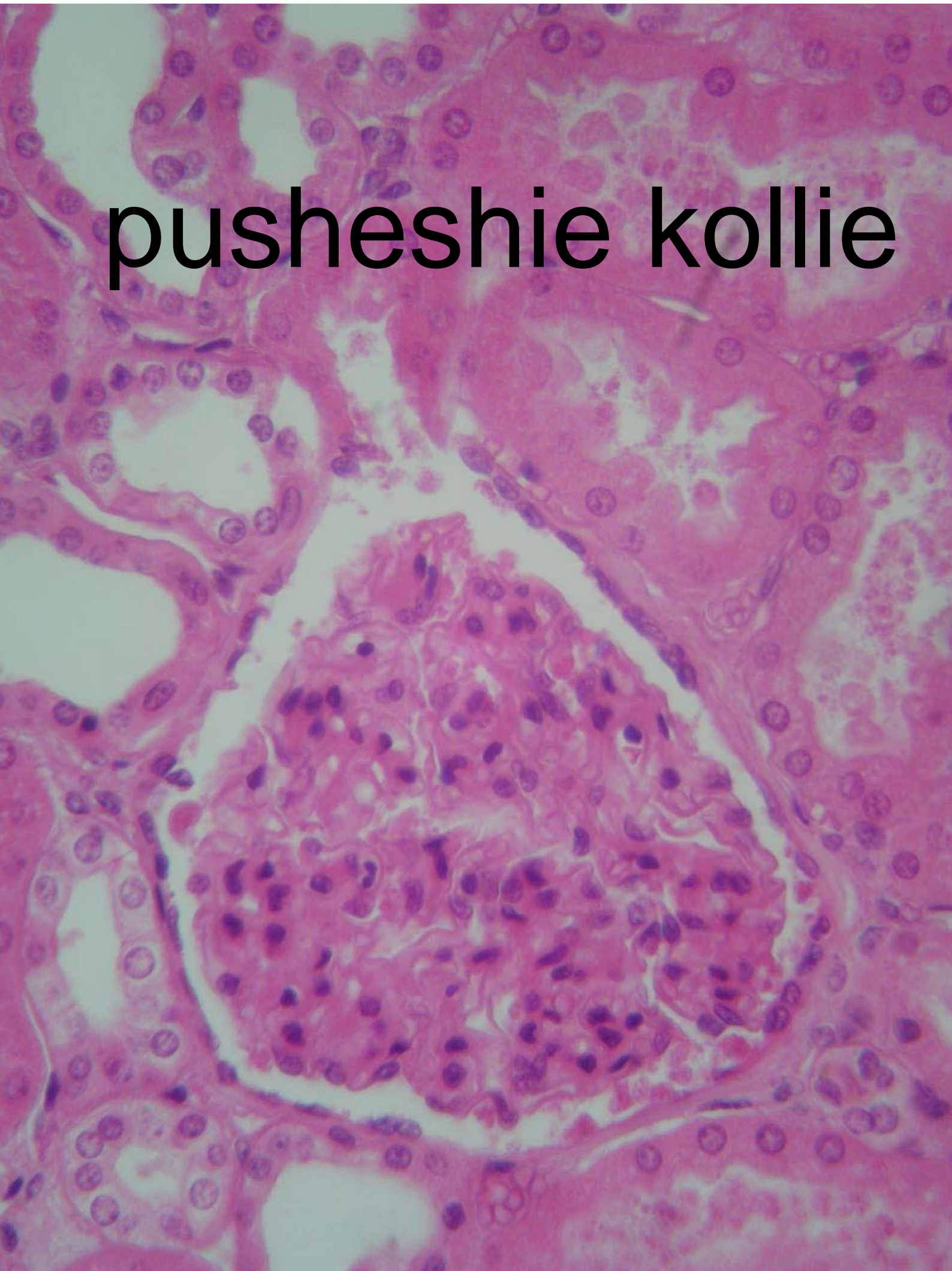pushesie kollie



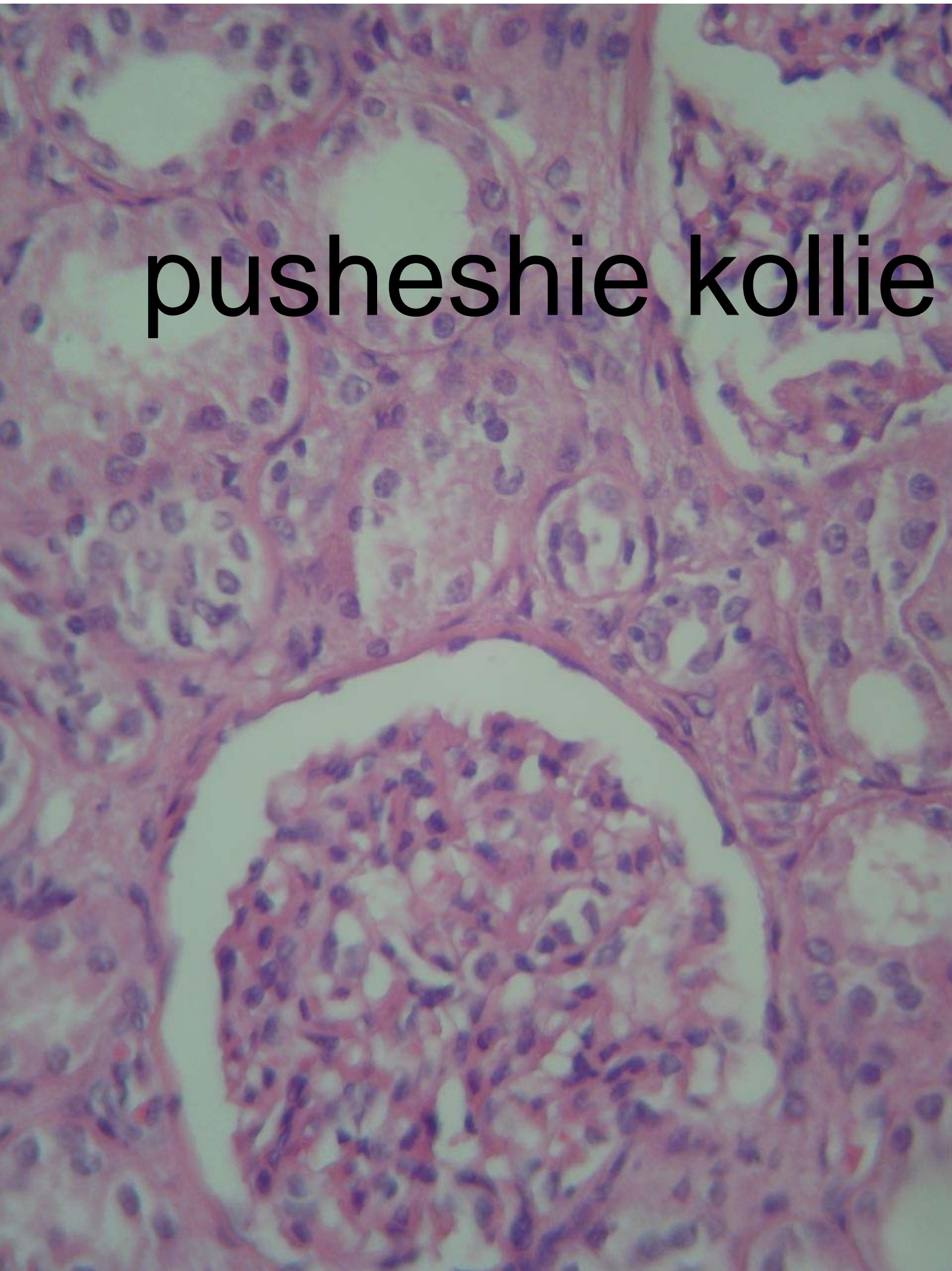pushesie kollie



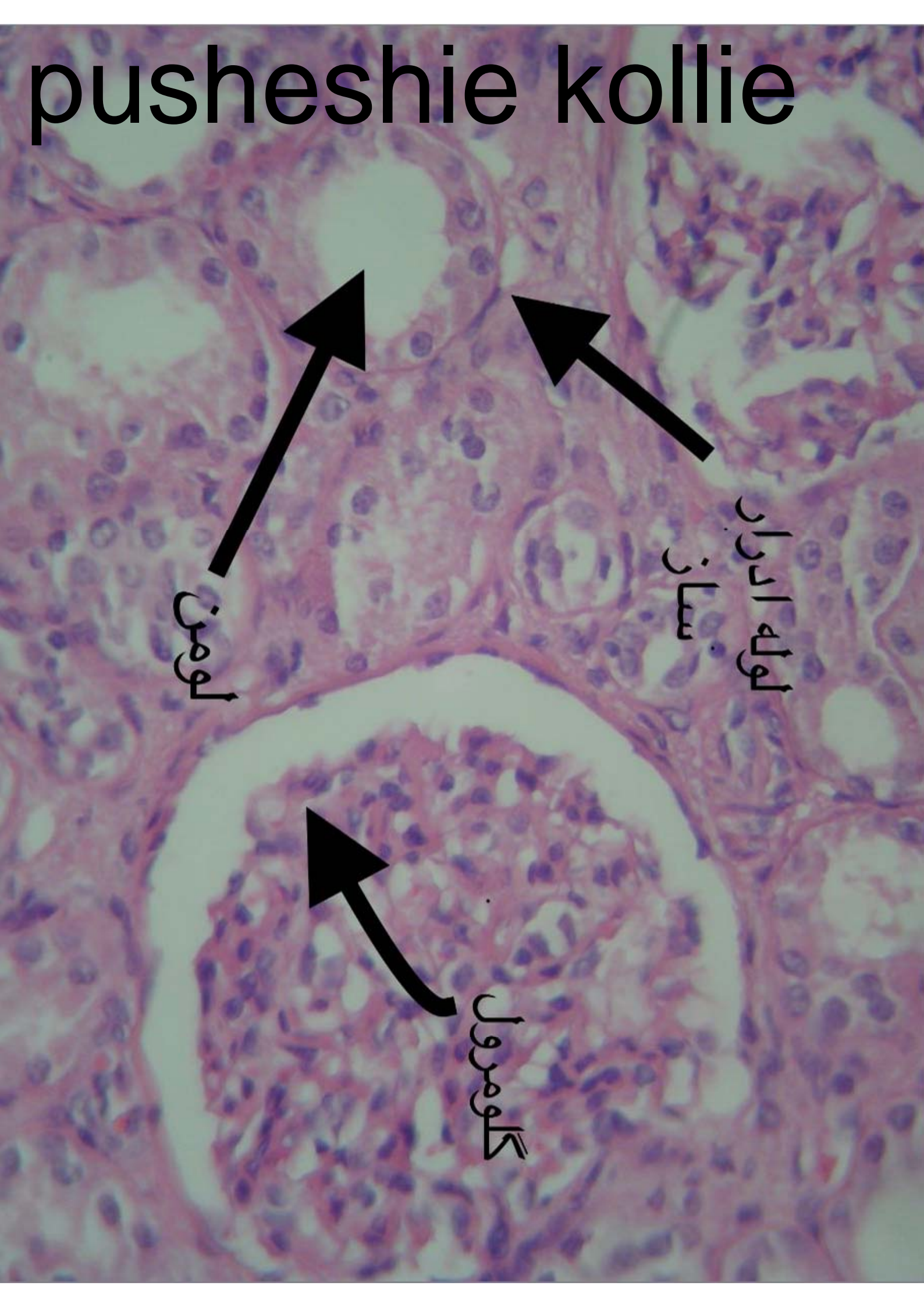
pusheshie kollie



pushesie kollie



pusheshie kollie



لومن

لوله الدرار
ساز

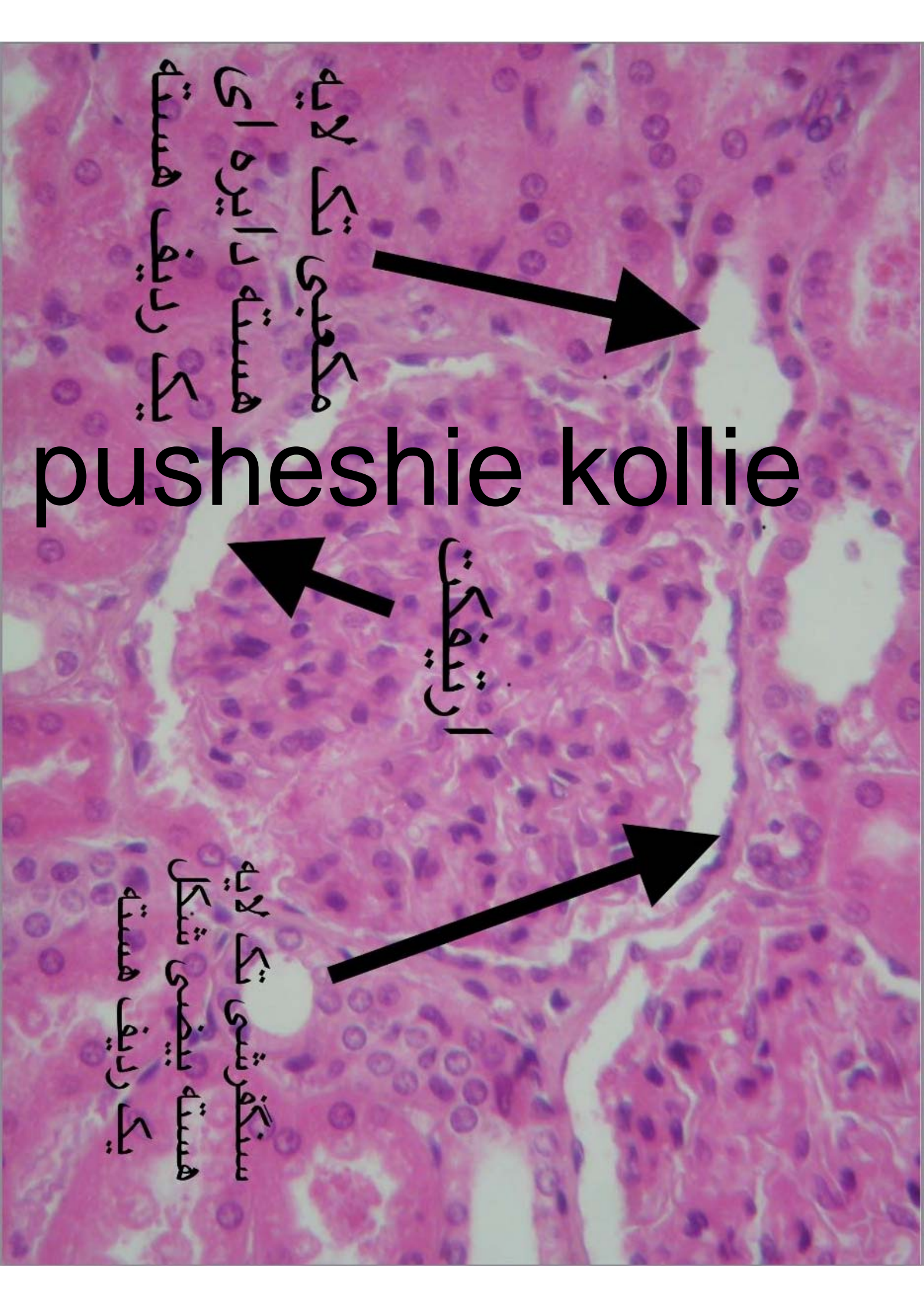
گالومرول

pushesie kollie

مکعبی تک لایه
هسته دایره ای
یک رلیف هسته

ارتیفاکت

سنگفرشی تک لایه
هسته بیضی شکل
یک رلیف هسته

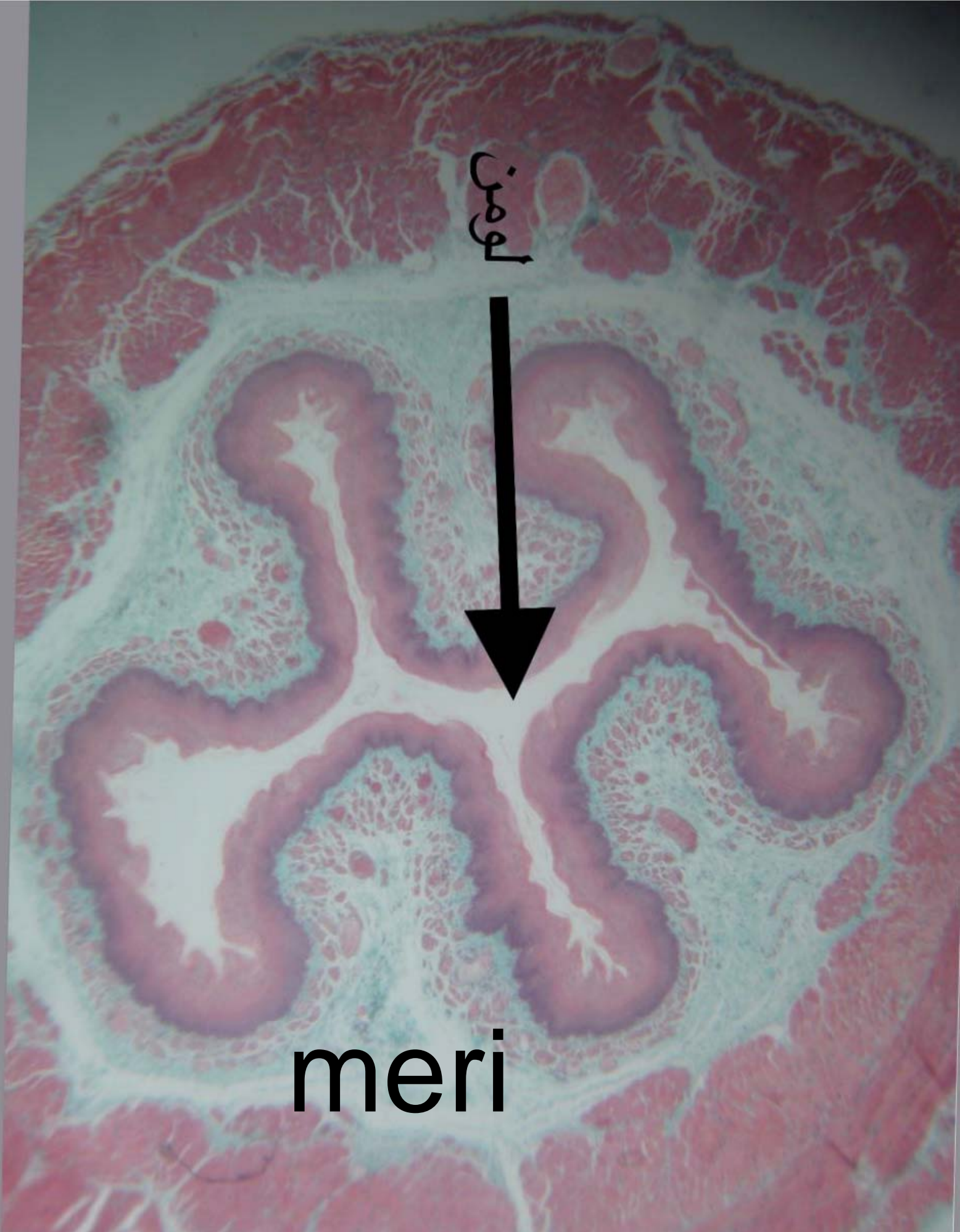

meri

لومن

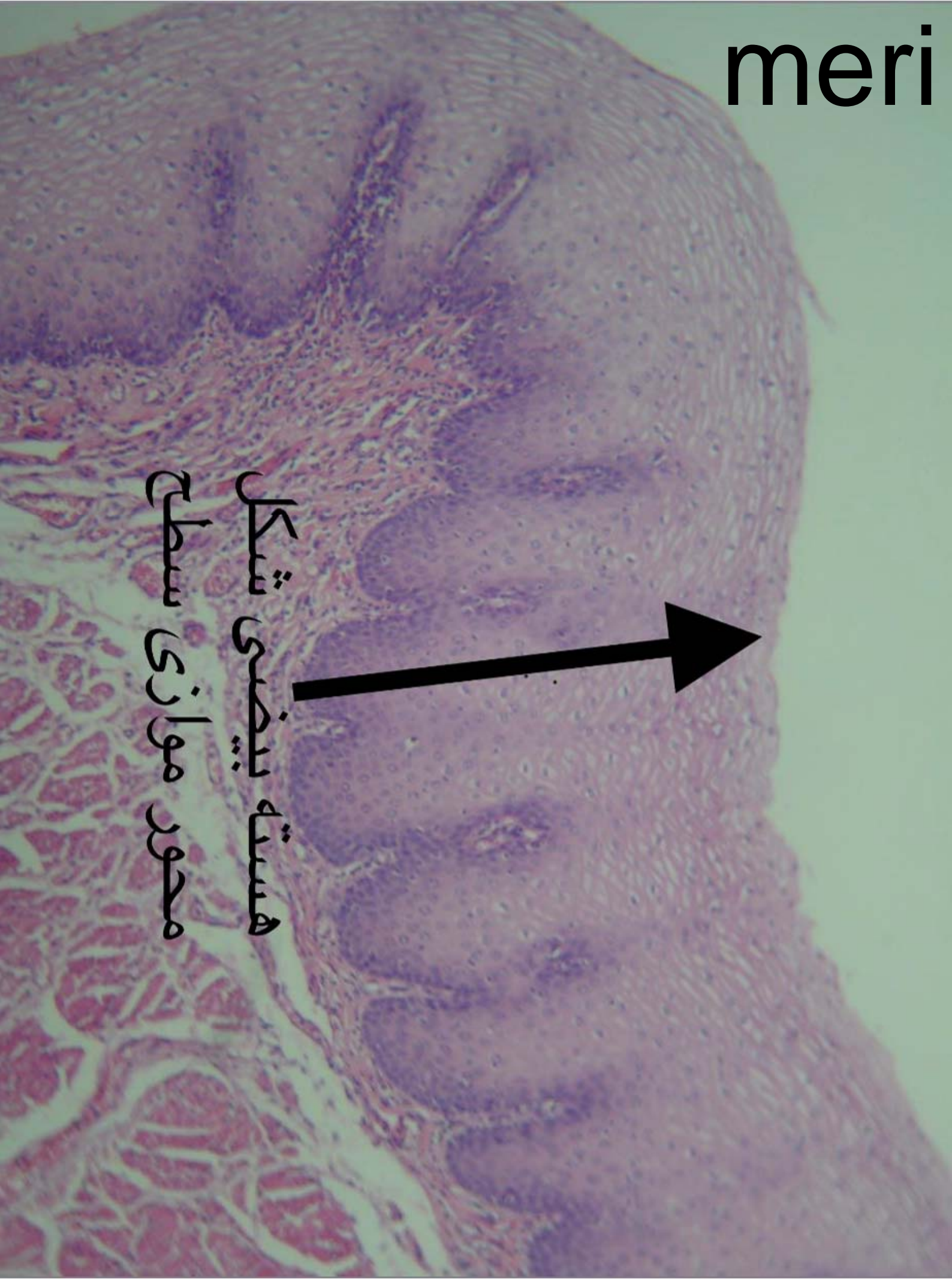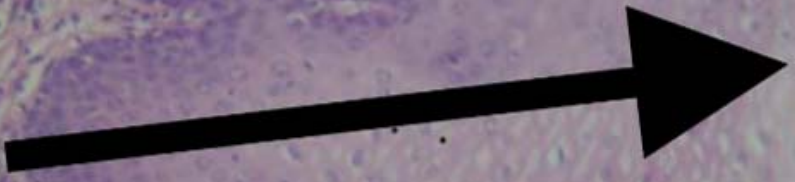


meri



meri

هسته بیضی شکل
محور موازی سطح



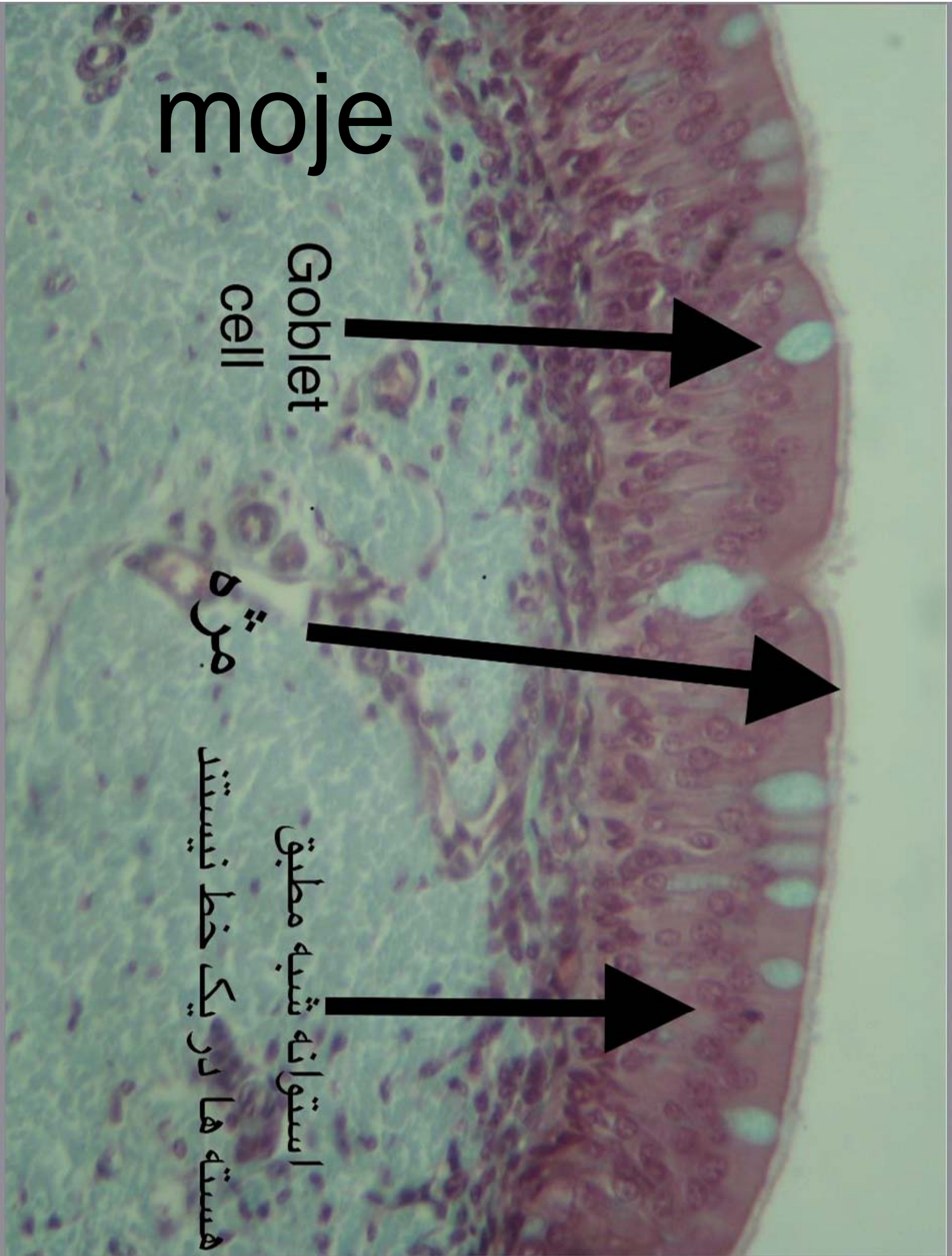
moje

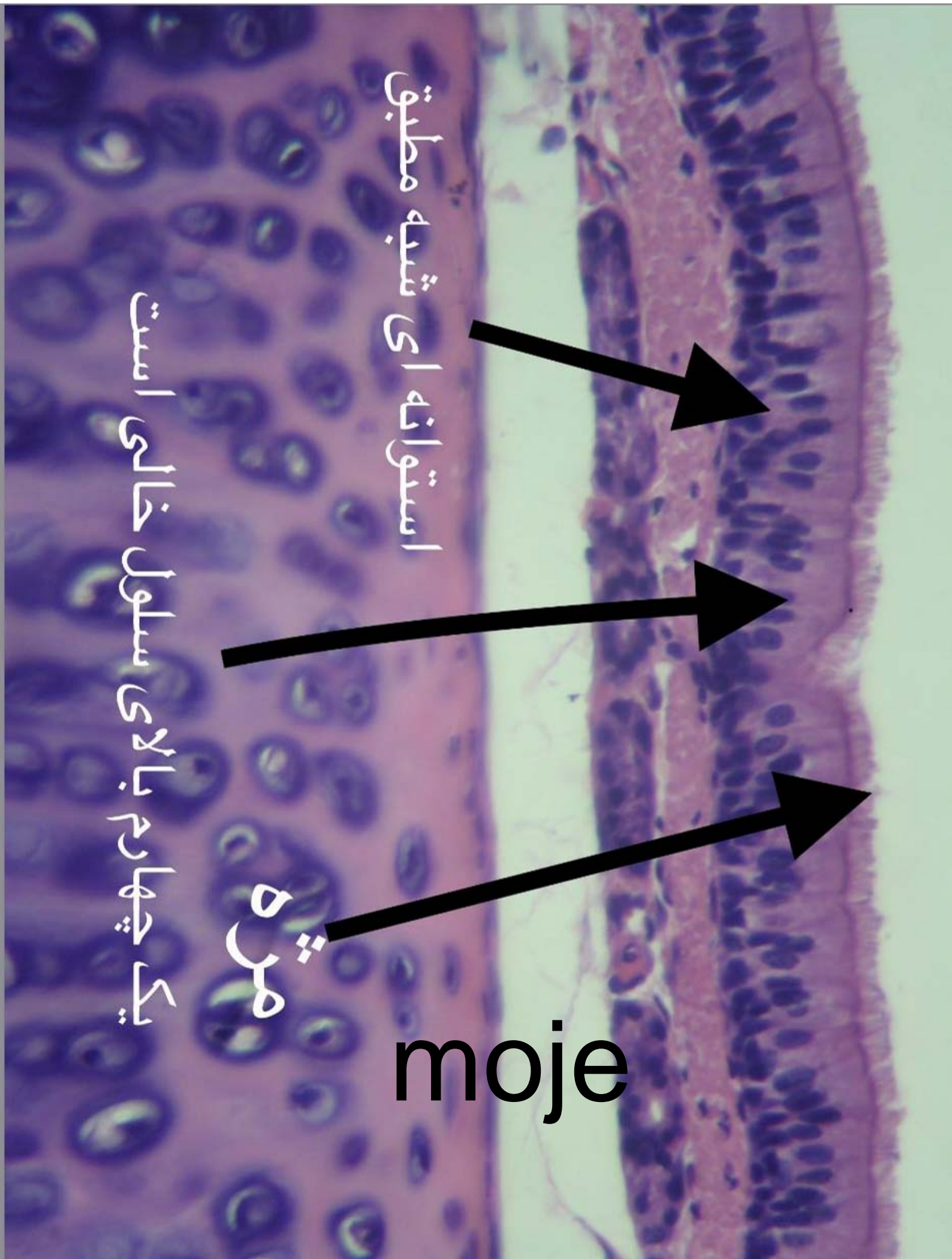
moje

Goblet
cell

مژه

استوانه شبه مطبق
هسته ها در یک خط نیستند



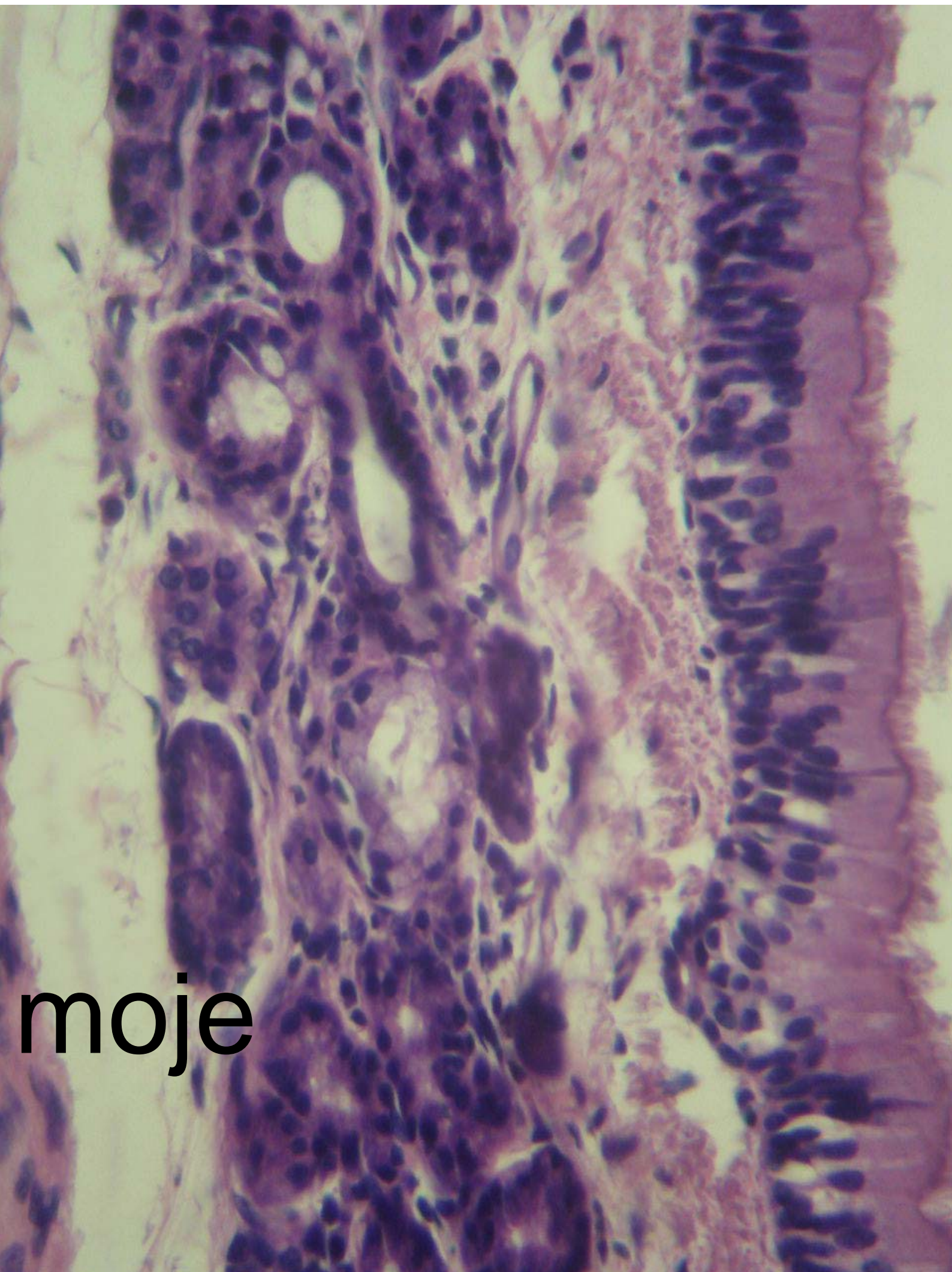


استوانه ای شبیه مطابق


یک چهارم بالای سلول خالی است

مدره

moje



moje

A low-magnification (4x) light micrograph of a tissue section. The image shows a large, roughly circular field of view. The central area is a bright, uniform yellowish-tan color. This central area is surrounded by a thick, multi-layered border of pinkish-red tissue. The layers appear somewhat irregular and dense. In the upper left quadrant, there is a distinct, grid-like pattern of blue-stained structures, likely representing a specific tissue component or artifact. The overall background is dark, suggesting the field of view is centered on a specific area of interest.

nay 4x

pusheshie

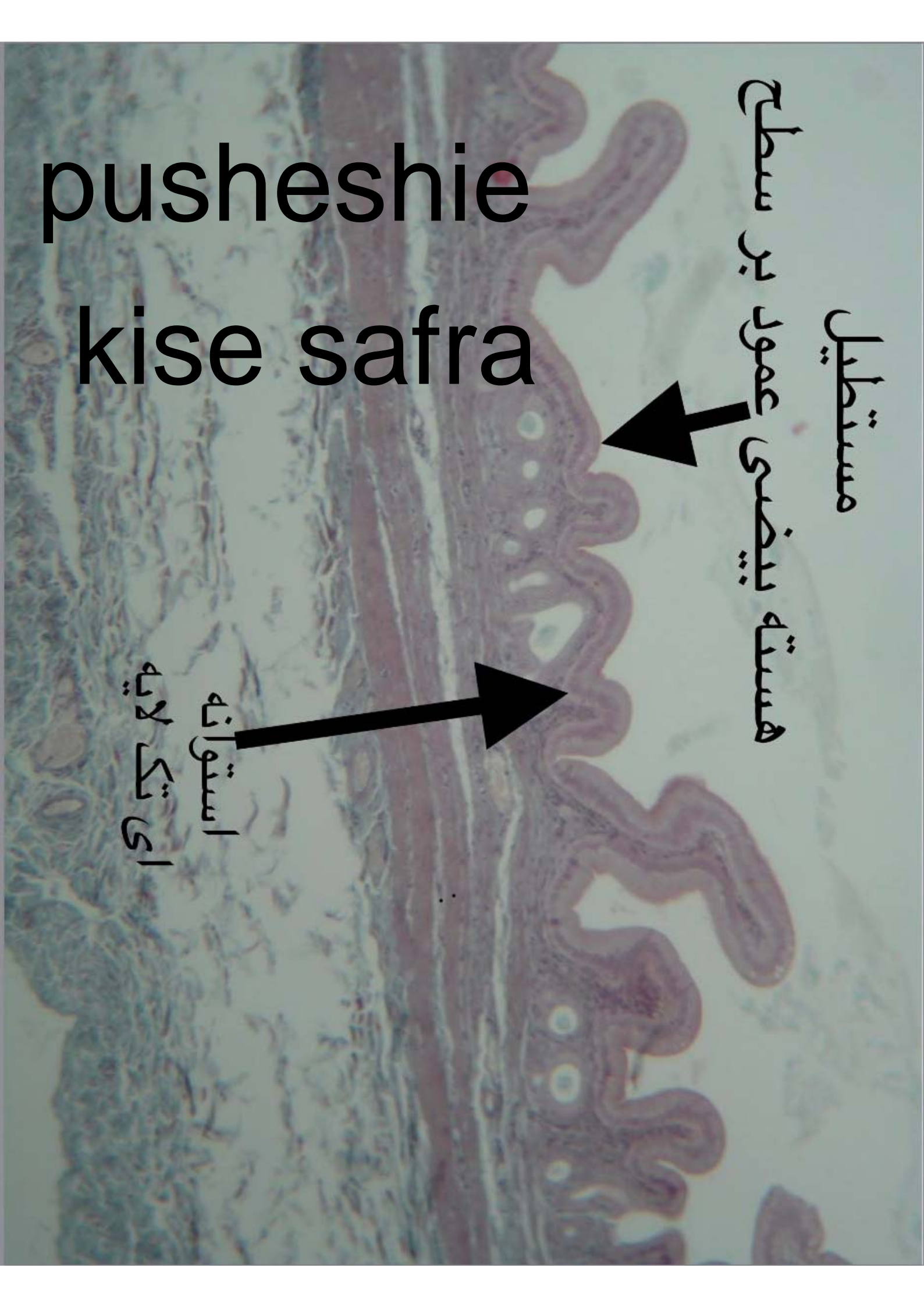
kise safra

pusheshie
kise safra

مستطیل

هسته بیضی عمود بر سطح

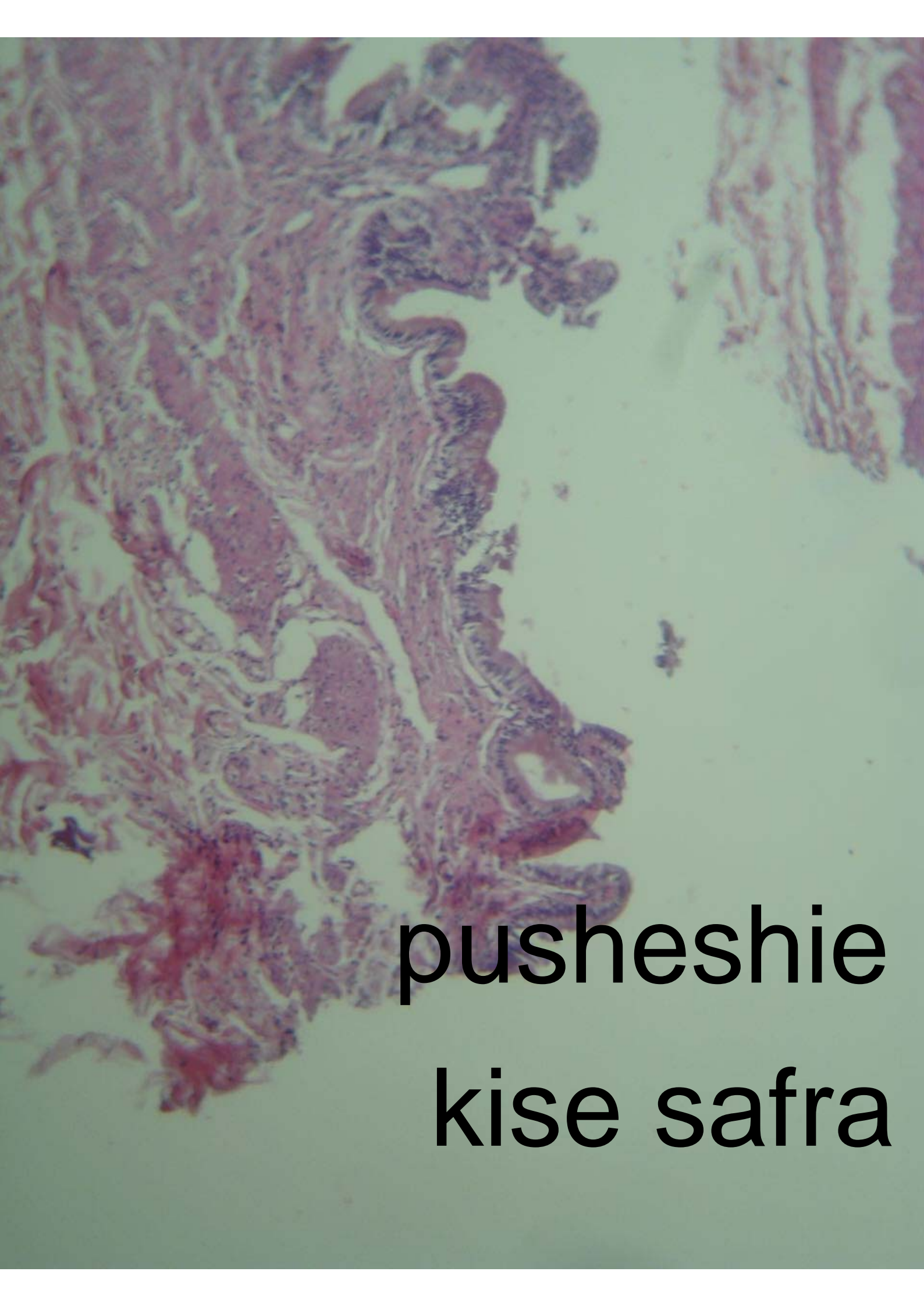استوانه
ای تک لایه



استوانه ای ساده



pusheshie
kise safra



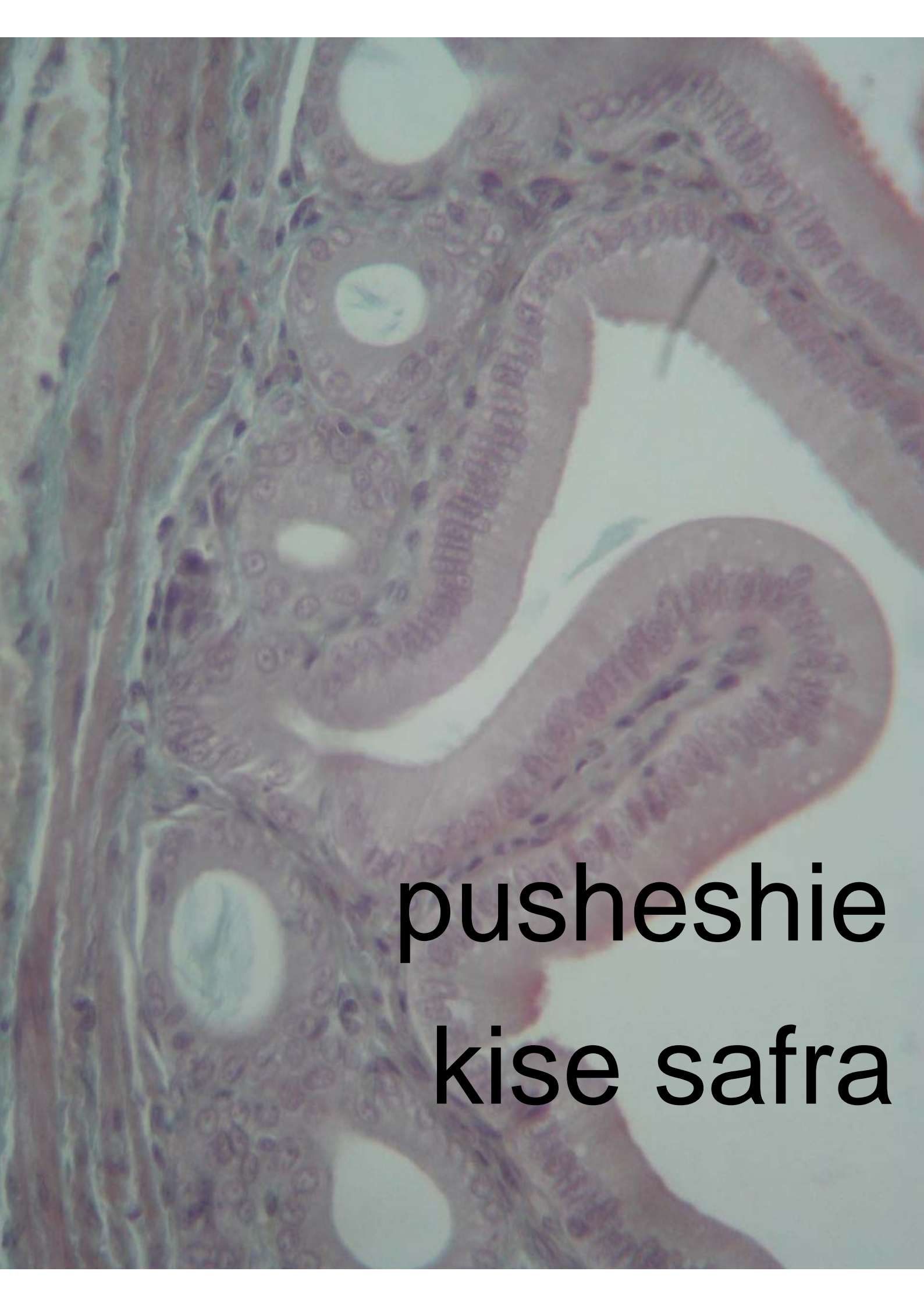**pusheshie
kise safra**

A histological section of the uterine wall, stained with hematoxylin and eosin (H&E). The image shows the endometrium on the right, characterized by its highly convoluted, glandular structure. The myometrium is visible on the left, showing a dense, organized layer of smooth muscle fibers. The overall appearance is typical of the normal anatomy of the uterus.

**pusheshie
kise safra**

A histological section of the placenta, showing chorionic villi. The villi are finger-like projections of the chorion, each containing a fetal blood vessel (artery and vein) and a decidual blood vessel. The villi are connected to the decidua by the chorionic plate. The image shows a cross-section of the placenta with a central umbilical cord and surrounding chorionic plate. The villi are arranged in a regular pattern, and the fetal blood vessels are clearly visible within them. The decidual blood vessels are also visible in the chorionic plate.

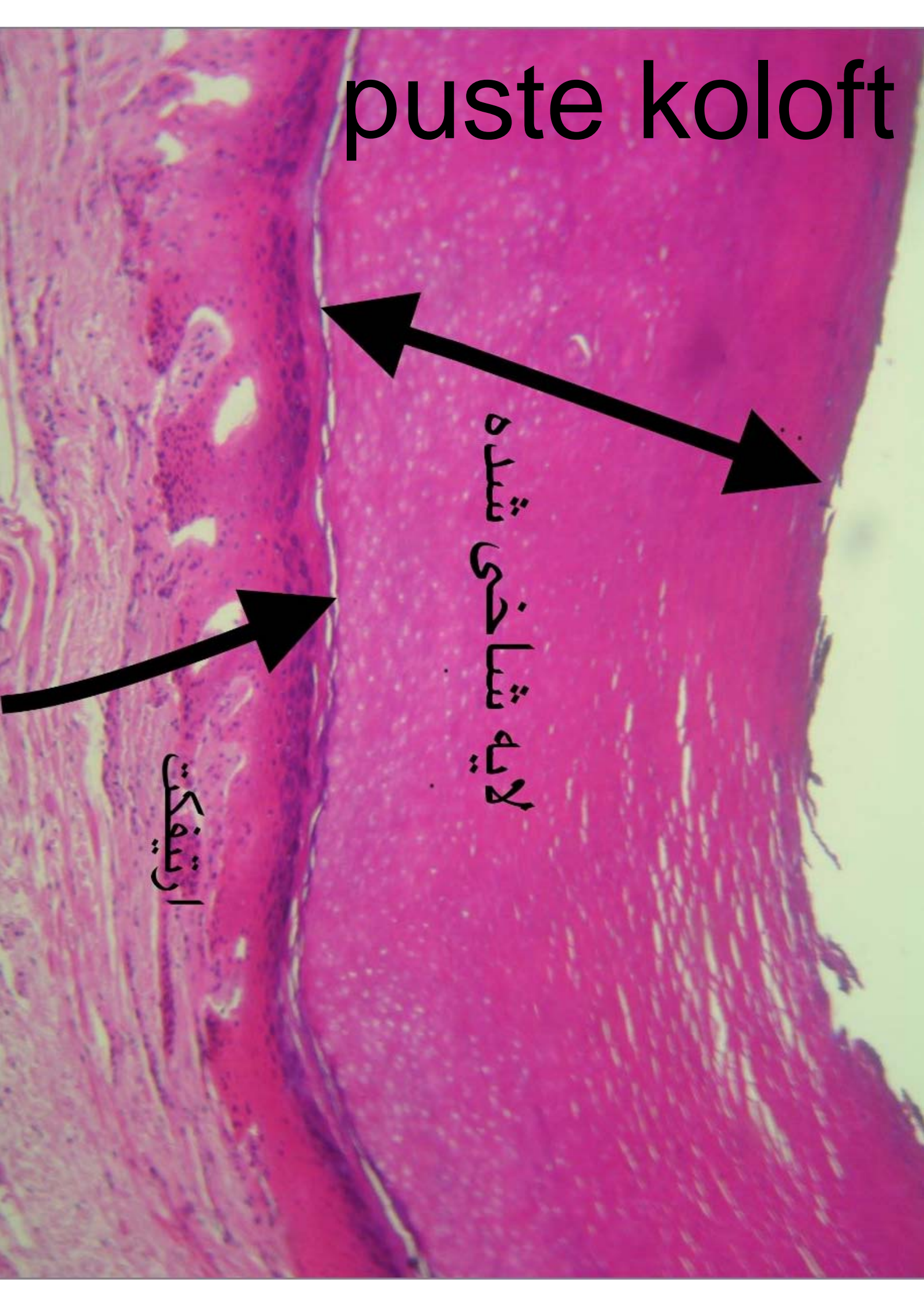
**pusheshie
kise safra**



**pusheshie
kise safra**

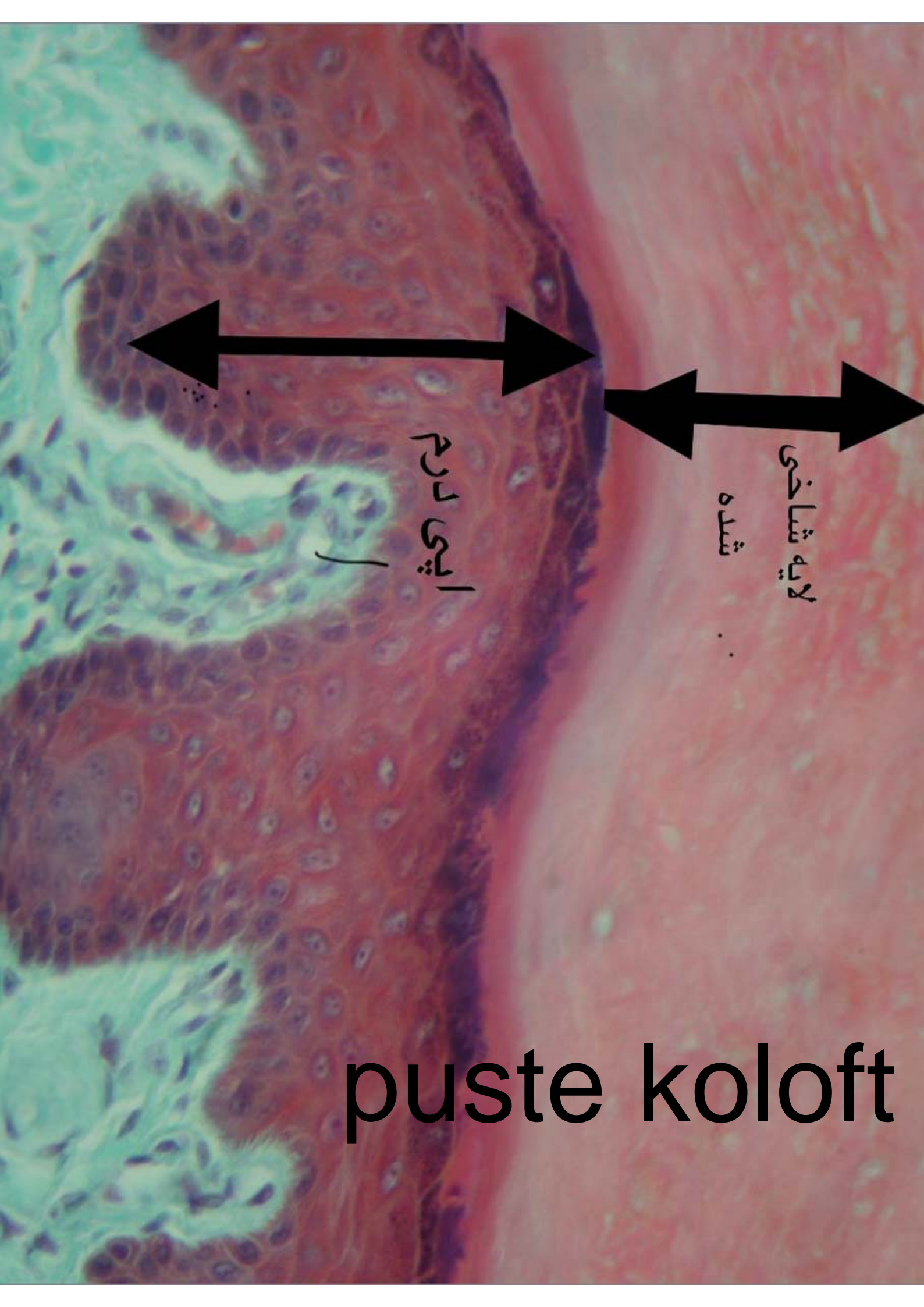
puste koloft

puste koloft



لایه شاخشی شده

ارتیفکت



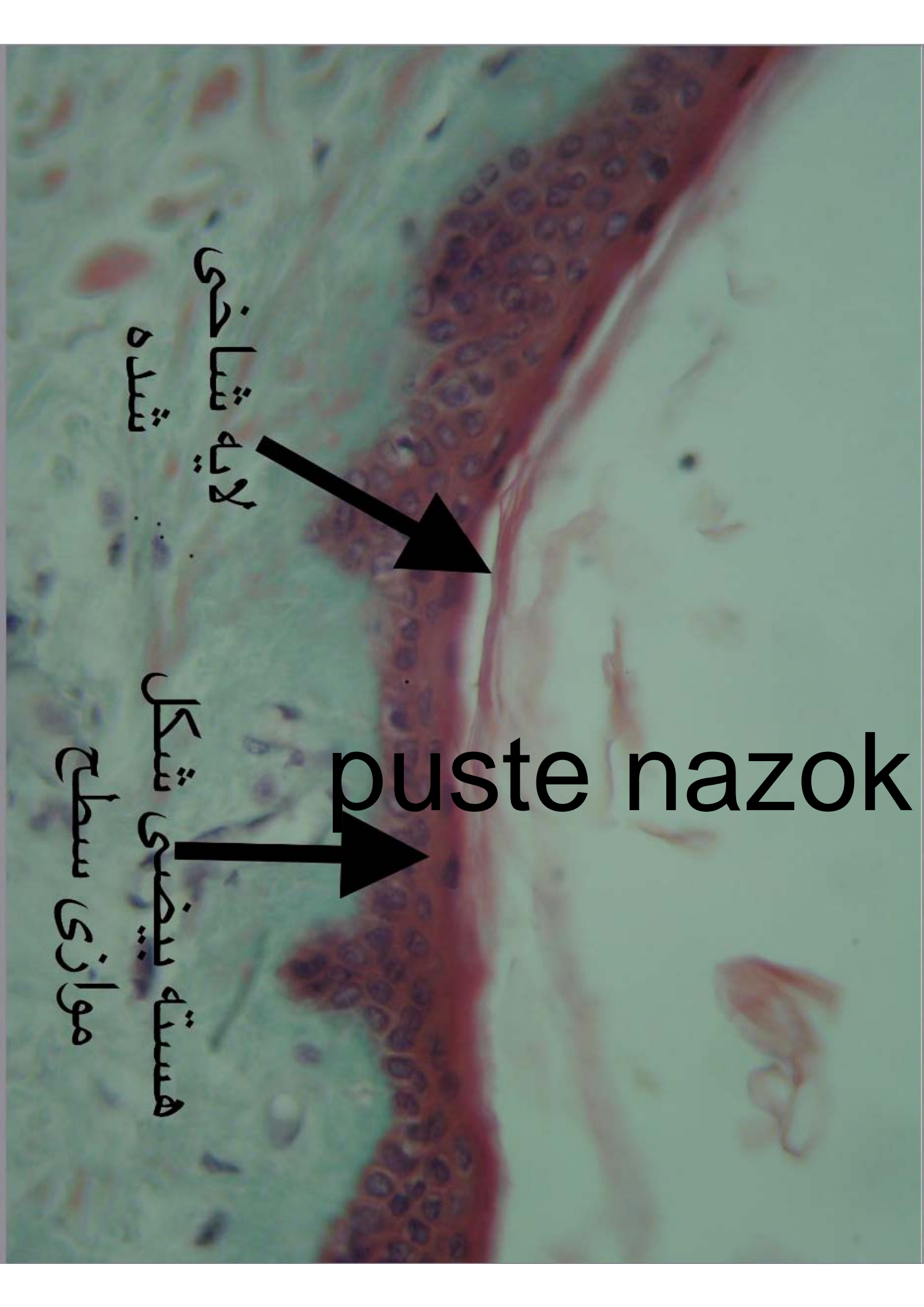
لایه شاخی

شده

ایپی درم

puste koloft


puste nazok



لایه شاخی
شده



هسته بیضی شکل
موازی سطح

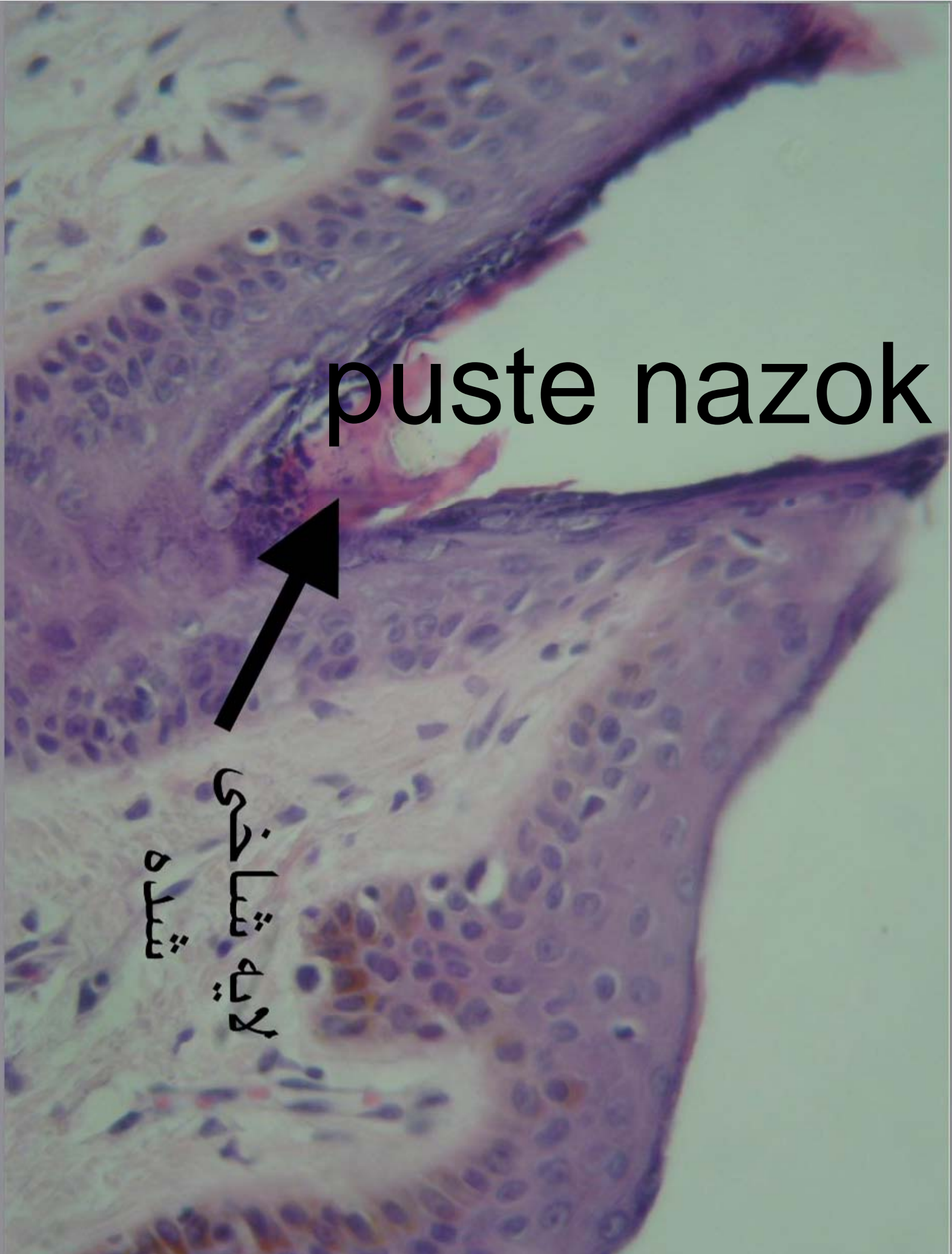


puste nazok

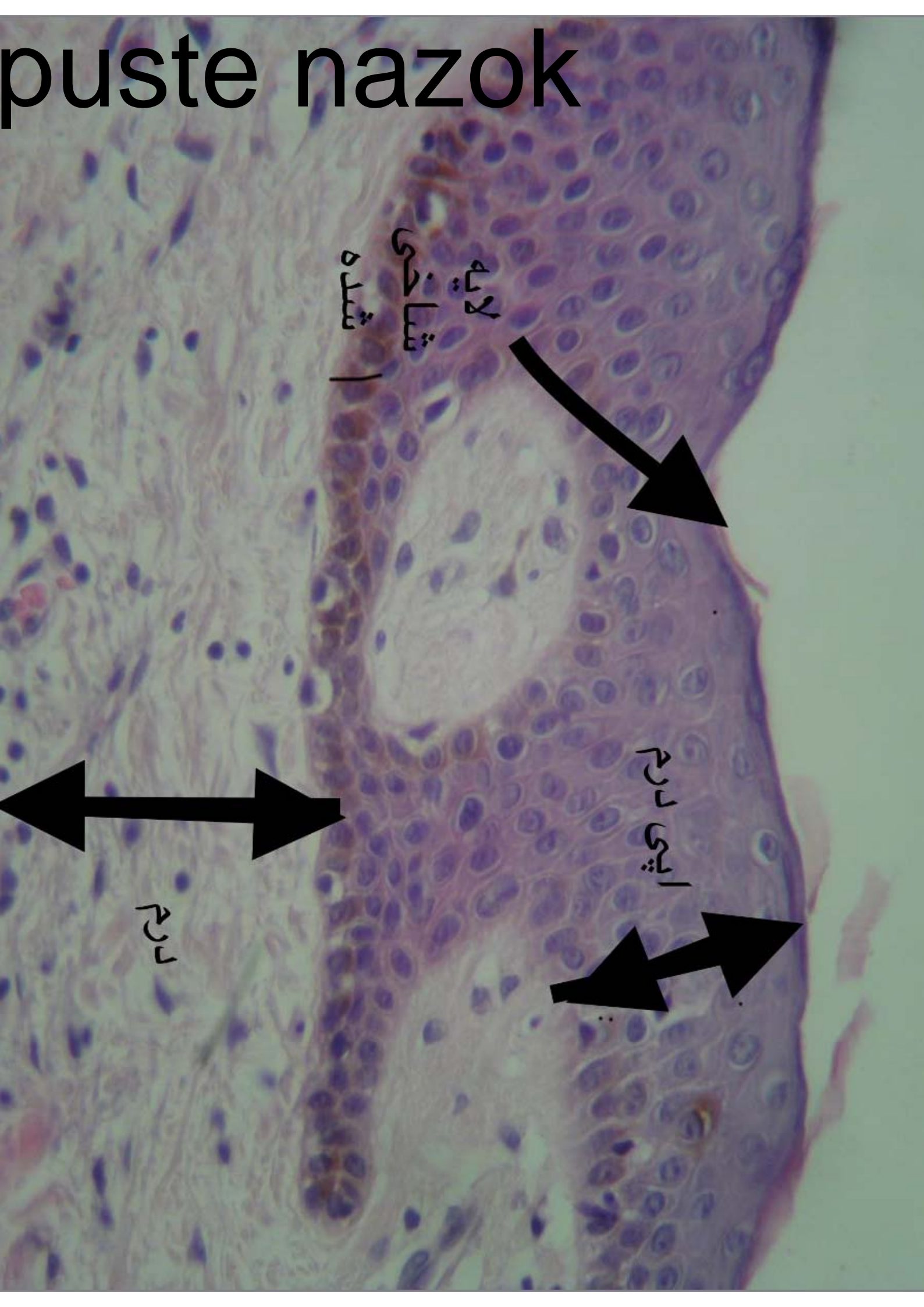
puste nazok



لایه شاخشی
شده



puste nazok



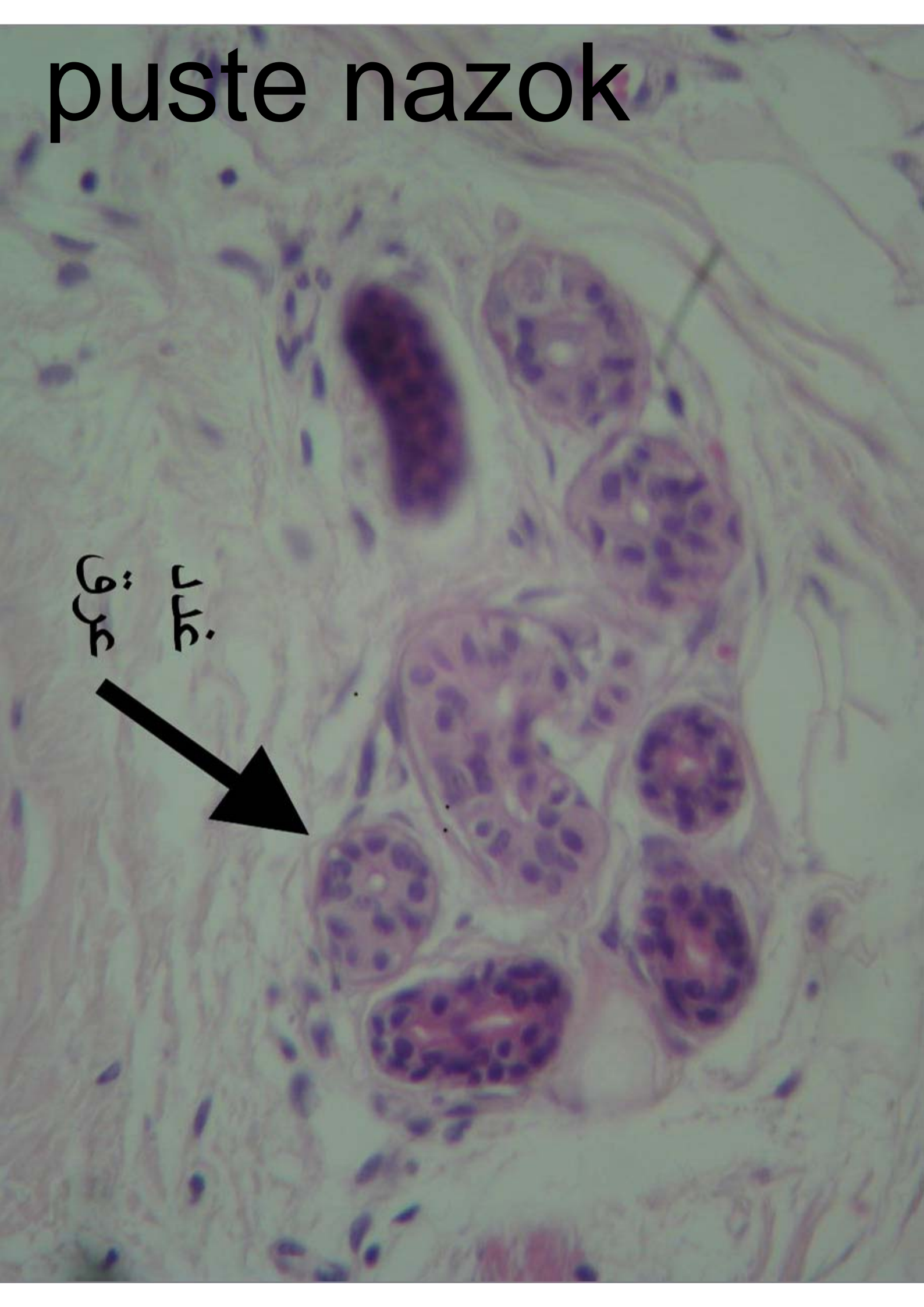

لایه شاخی
شکل شده

اثری درم

درم

puste nazok

غدد
عرق



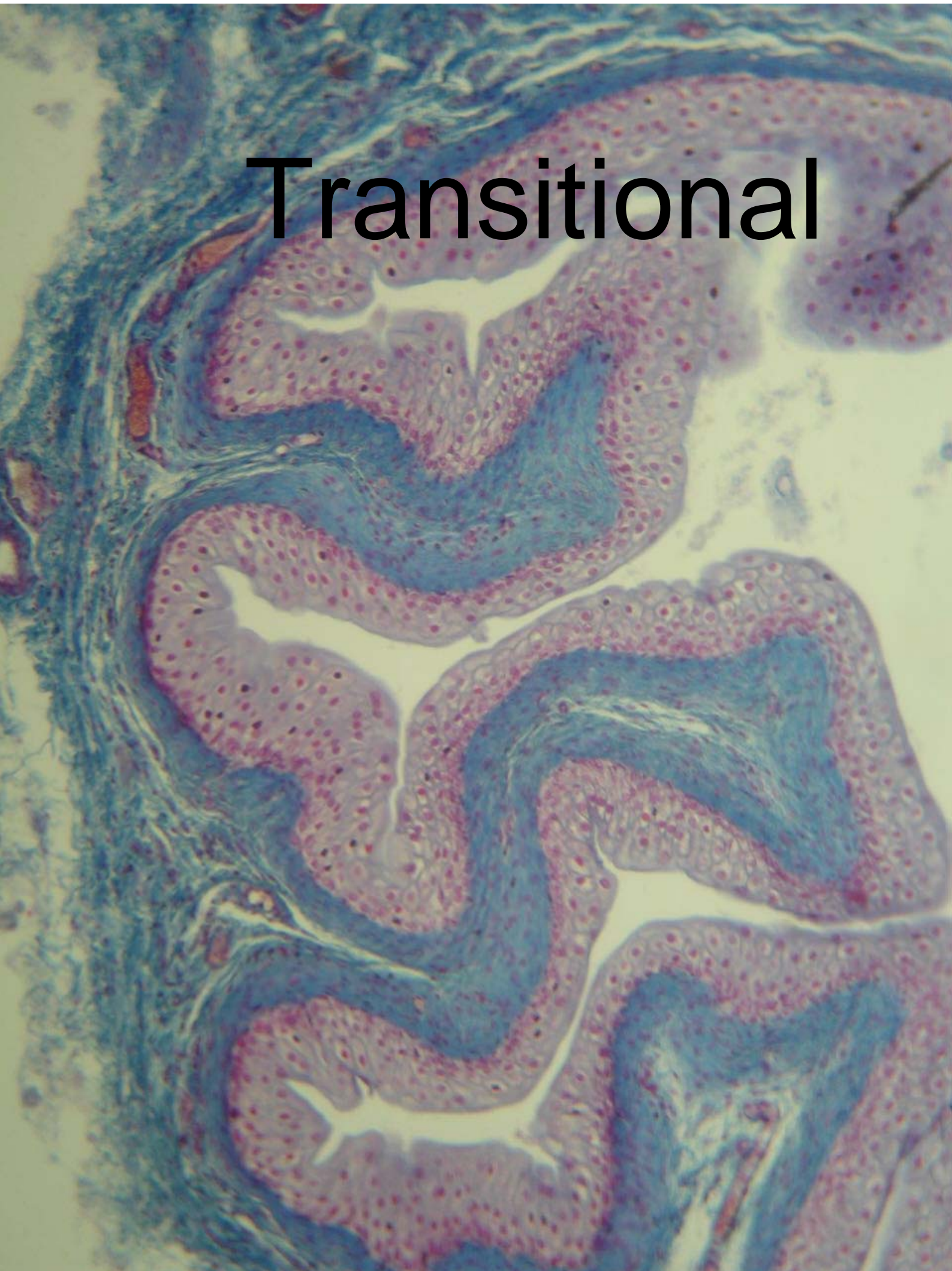Transitional

Transitional

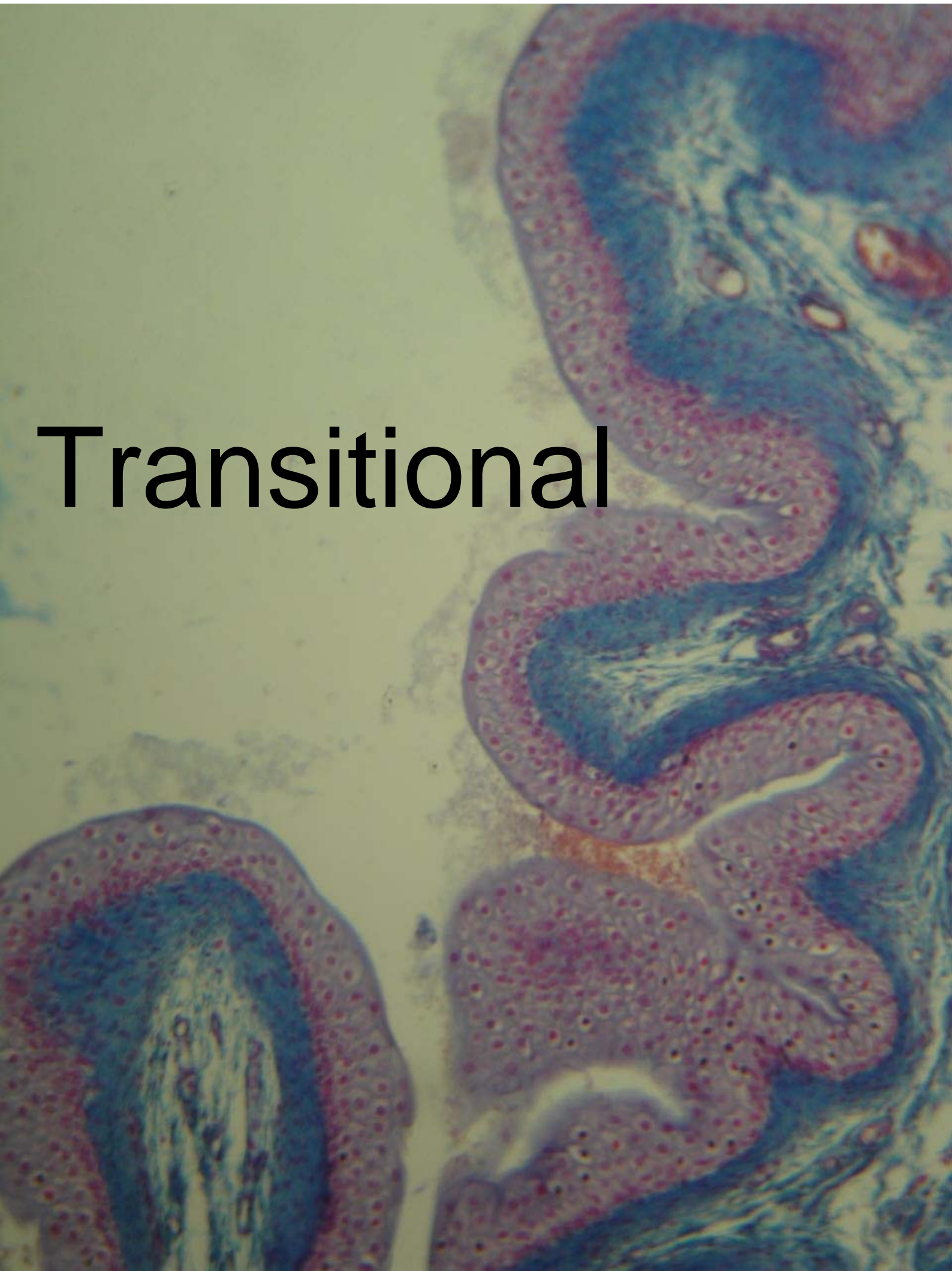گنبدی شکل



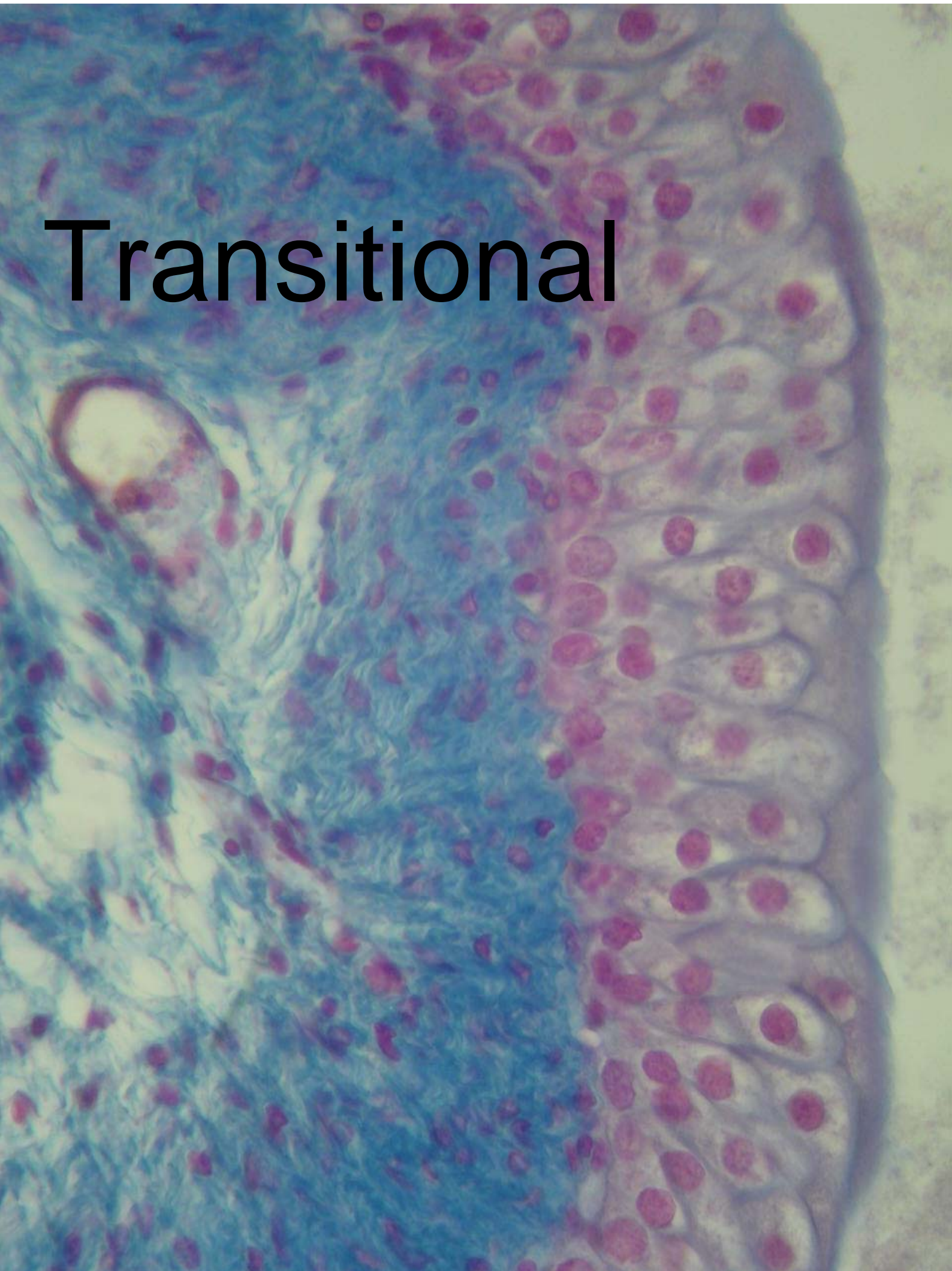
Transitional

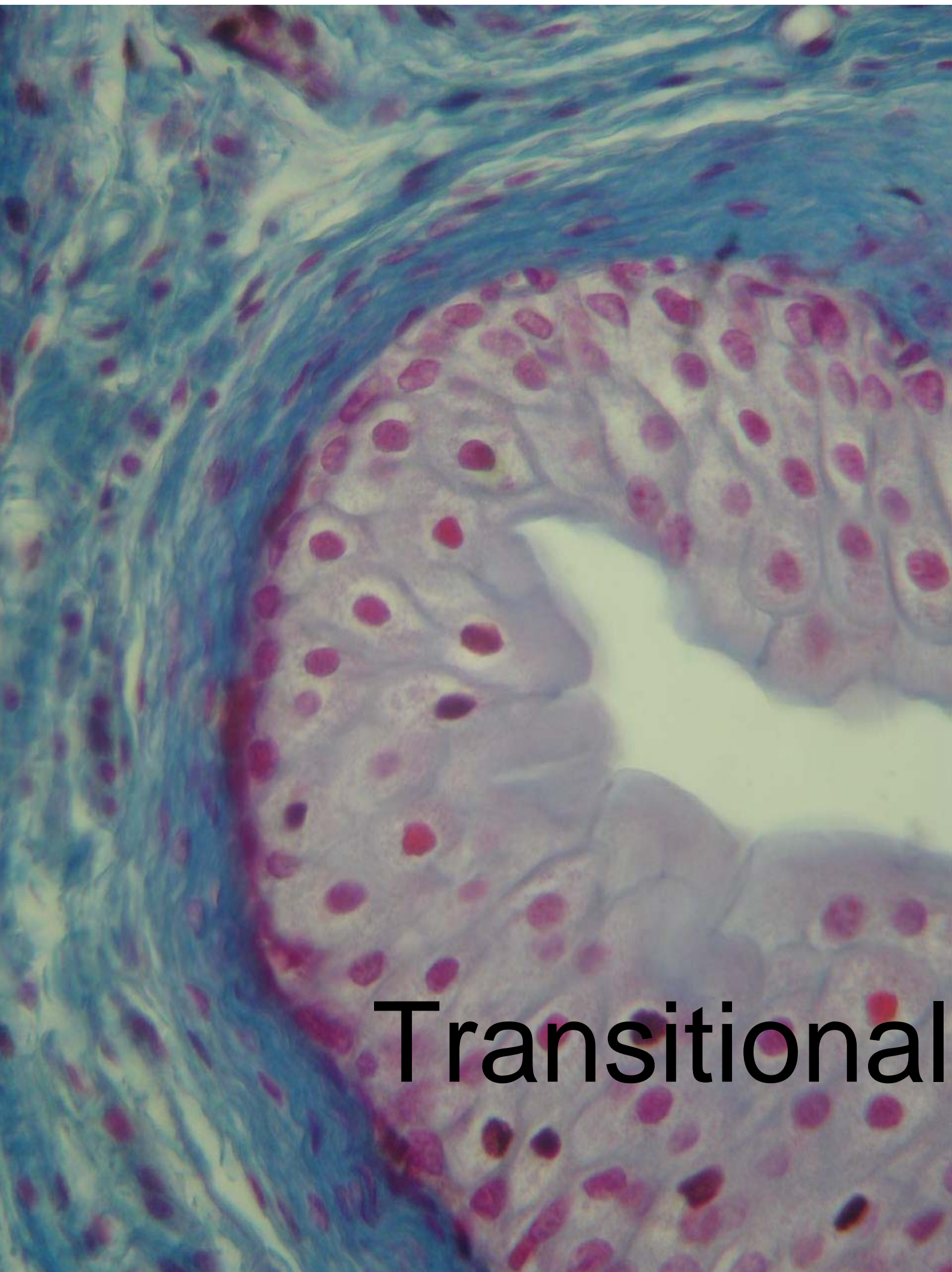


Transitional



Transitional





Transitional