

Handbook of

# AVIAN MEDICINE

Second Edition

Edited by

T.N. Tully, Jr., G.M. Dorrestein, A.K. Jones



SAUNDERS  
ELSEVIER

Butterworth-Heinemann  
Linacre House, Jordan Hill, Oxford OX2 8DP  
225 Wildwood Avenue, Woburn, MA 01801-2041  
A division of Reed Educational and Professional Publishing Ltd

 A member of the Reed Elsevier plc group

First published 2000

© Reed Educational and Professional Publishing Ltd 2000

All rights reserved. No part of this publication may be reproduced in any material form (including photocopying or storing in any medium by electronic means and whether or not transiently or incidentally to some other use of this publication) without the written permission of the copyright holder except in accordance with the provisions of the Copyright, Designs and Patents Act 1988 or under the terms of a licence issued by the Copyright Licensing Agency Ltd, 90 Tottenham Court Road, London, England W1P 0LP. Applications for the copyright holder's written permission to reproduce any part of this publication should be addressed to the publishers

### **British Library Cataloguing in Publication Data**

Avian medicine

1. Avian medicine

I. Tully, Thomas N.    II. Lawton, Martin P. C.

III. Dorrestein, Gerry M.

636.5'089

### **Library of Congress Cataloguing in Publication Data**

Avian medicine / edited by Thomas N. Tully, Jr.,  
Martin Lawton, Gerry M. Dorrestein.

p.cm.

Includes bibliographical references and index.

ISBN 0 7506 3598 3

1. Avian medicine.    I. Tully, Thomas N.

II. Lawton, Martin P. C.    III. Dorrestein, G. M.

SF994.A93 2000

636.5'089-dc21

00-036020

ISBN 0 7506 3598 3

Composition by Genesis Typesetting, Laser Quay, Rochester, Kent  
Printed and bound by MPG Books Ltd, Bodmin, Cornwall

**PLANT A  
TREE**



FOR EVERY TITLE THAT WE PUBLISH, BUTTERWORTH-HEINEMANN  
WILL PAY FOR BTCV TO PLANT AND CARE FOR A TREE.

---

# Acknowledgements

The completion of an international text is a substantial achievement. Only a cohesive team can accomplish what one person cannot. We the editors want to first thank the authors, without whom there would be no *Avian Medicine* handbook. The idea of an international text to call upon the expertise of a global avian community was encouraged by our publisher. Wanting this expertise and having them commit to this project with their busy schedules were two different matters. Fortunately, we were able to secure their commitment and feel the veterinary community as a whole will benefit from this work.

There was a large support staff which was an invaluable asset in formatting the original manuscript. Joseph A. Smith, whose hard work and dedication will serve him well in his chosen profession, veterinary medicine, led this support staff team. Others who made significant contributions to this project included Harry M. Cowgill, photographer; Michael L. Broussard, graphic artist; Sam Moran and the staff at the Greater Baton Rouge Zoo and Joshua R. Pinkston.

We are also grateful to our colleagues in our practices who supported us during this endeavour. Drs. Mark Mitchell and J. Jill Heatley at LSU, Drs. Lynne Stoakes, Stephen Divers and Julie Austin in the UK and Dr. Marein van der Hage in Utrecht were all instrumental in the completion of this text. The editors would also like to thank Marion Jowett for her belief in this project from the beginning.

Of course this work could never have come to fruition without the constant nurturing, commitment and work of our publisher, Butterworth-Heinemann. There are a few special people we would like to thank for their help and efforts, Mary Seager, Senior Commissioning Editor, for being the captain and running this ship, and Angela Davies, Medical Desk Editor, and Caroline Savage, Editorial Assistant, for making the impossible task of putting the original manuscript into a publishable text possible.

Finally, a heartfelt thank you to our wives, Susie Tully, Lynne Stoakes and Marein van der Hage and families who helped us survive the ups and downs of editing a multi-author medical text.

---

# Foreword

'The night when I came home I was much troubled to hear that my poor  
Canary Bird, that I have kept these three or four years, is dead'

Samuel Pepys (1665)

Of all animals, those in the Class Aves – the birds – have most fascinated the human race. Their almost ubiquitous distribution, the tendency of many species to live in villages, towns and cities and the ease with which some can be tamed or trained: these and other features have led to birds occupying a very special place in the lives and traditions of various cultures.

Interest in the biology and health of birds is not new. Two thousand years ago, Pliny, Aristotle and others studied birds, taught others and published their observations. In the 17th century European anatomists carried out painstaking dissections of many species and were able to produce scholarly descriptions that have, in a number of cases, withstood the test of time and are still valid today. A century later John Hunter, the great surgeon, anatomist and champion of the veterinary profession, explored the links between structure and function in animals and amongst many other great discoveries, described the air sac system and studied factors that influenced the healing of fractures in avian species.

Medical care for birds is also not new. As long ago as 1486 advice on the diagnosis and treatment of falcons was given in the *Boke of St Albans* written by Dame Juliana Berners – a reminder of the key role in avian science played by women, even 500 years ago! The popularity of the sport of falconry over the succeeding three centuries ensured that publications on raptors continued to appear. There was interest in other types of bird – see the quotation from Pepys at the beginning of this Foreword – but it was only in the 19th century that serious attention began to be paid to the diseases of those kept in cage and aviary.

In 1903, Arthur G. Butler produced his *Hints on Cage-Birds (British and Foreign)* and in the Preface declared that 'Aviculturists in the present century ought to do better work than their predecessors....'. Butler went on to say 'Now that men who have laboured and suffered are recording the results of their work..., their successors may confidently look for brighter and more prosperous times, starting where the pioneers left off they may continue to add to the sum of knowledge, and may hope eventually to bring the science of birdkeeping to something approaching perfection'.

Nearly a hundred years later, it cannot be claimed that the 'science of birdkeeping' has yet approached perfection, but the advances have been enormous. Over the past two decades our knowledge and understanding of bird diseases in particular has progressed extraordinarily and much of the credit for this is owed to the 'pioneers', amongst them the editors and many of the contributors of this book, who have turned avian medicine into a bona fide, state-of-the-art, scientific discipline.

It gives me particular pleasure in this Foreword to note and to commend the book's international orientation. The Editors are from three different countries and the authors of chapters span even more. This spread reflects the global importance of avian medicine, in terms not only of treating individual sick birds but also of promoting the health of wild (free-living) avian populations, particularly those that are under pressure for other reasons. The part that the veterinary profession can play in conservation is now widely recognized and a Resolution at last year's (1999) meeting of the European Committee of the Association of Avian Veterinarians urged

international bodies and policy makers to recognize that role and to incorporate veterinarians in their programmes. In my own work overseas I have witnessed the contributions that can be made by those with a sound knowledge of aviculture and pathology, medicine and surgery. Thus, for example, the survival and recovery of the Mauritius Kestrel (*Falco punctatus*) owes much to the collaboration in the 1970s between veterinarians and biologists who, often unfunded, worked to save the species from extinction. This study has been repeated on a number of occasions since then and augurs well for the future.

Tom Tully, Martin Lawton and Gerry Dorrestein are familiar names to all who keep or

treat birds. Those of us who care about – or for – the class Aves owe them a debt of gratitude for all they have done to promote a better understanding of these animals and their requirements. This book will serve as a lasting legacy of their work, and at the same time, will encourage others to contribute to the challenging and exciting field of avian medicine.

**Professor John E. Cooper**

DTVM, FRCPath, FIBiol, Dip ECAMS, FRCVS

Consultant Veterinary Pathologist

Durrell Wildlife Conservation Trust

(Jersey Zoo)

February 2000

---

# Contributors

**Alan Abrey** BVSc  
Consultant/Director, Zoological Collections,  
Durban, South Africa

**Janette Ackermann** DVM, MS  
Chief, Veterinary Services, American Wildlife  
Foundation, Molalla, Oregon, USA

**Brian H. Coles** BVSc, FRCVS, Dipl ECAMS  
4 Dorfold Way, Upton, Chester, Cheshire,  
UK

**Gerry M. Dorrestein** DVM PhD Dipl Vet  
Pathology  
Associate Professor in Avian, Exotic Animal  
and Wildlife Pathology, Utrecht University,  
Utrecht, The Netherlands

**Peter de Herdt** DVM, DVSc  
Professor of Veterinary Medicine, University  
of Gent  
Director of Clinic for Poultry and Special  
Animal Diseases, Merelbeke, Belgium

**Luc Devriese** DVM  
Senior Researcher in Veterinary Bacteriology,  
University of Gent, Merelbeke, Belgium

**Nigel H. Harcourt-Brown** BVSc, FRCVS,  
Dipl ECAMS  
30 Crab Lane, Bilton, Harrogate, North  
Yorkshire, UK

**Don J. Harris** DVM  
Avian and Exotic Animal Medical Center,  
Miami, Florida, USA

**Maria-Elisabeth Krautwald-Junghanns**  
PD Dr Med Vet, Dr Med Vet Habil,  
Dipl ECAMS FTA  
Professor, University of Leipzig, Leipzig,  
Germany

**Martin P.C. Lawton** BVetMed CertVOphthal  
CertLAS CBiol MIBiol DZOOMed FRCVS  
RCUS Specialist in Exotic Animal Medicine,  
Exotic Animal Centre, Romford, Essex, UK

**Patricia Macwhirter** BVSc (Hons), MA,  
FACVSc  
Principal, Highbury Veterinary Clinic,  
Burwood, Victoria, Australia

**Glenn H. Olsen** DVM, MS, PhD  
Veterinary Medical Officer, US Department  
of Interior, US65 Patuxent Wildlife Research  
Center, Laurel, Maryland, USA

**Patrick T. Redig** DVM, PhD  
Associate Professor and Director, The Raptor  
Center, University of Minnesota, St. Paul,  
Minnesota, USA

**Ian Robinson** BVSc, Cert. SAP, MRCVS  
RSPCA Norfolk Wildlife Hospital, Station  
Road, East Winch, Kings Lynn, Norfolk, UK

**Andrew Routh** BVSc, MRCVS  
RSPCA Norfolk Wildlife Hospital, Station  
Road, East Winch, Kings Lynn, Norfolk, UK

**Stephanie Sanderson** MA, VetMB, MRCVS  
RSPCA Norfolk Wildlife Hospital, Station  
Road, East Winch, Kings Lynn, Norfolk, UK

**Katja Trinkaus** DVM, FTA  
Staff member, Clinic for Avian and Reptile  
Diseases, Institute for Avian and Reptile  
Diseases, Justus-Liebig-University of  
Giessen, Giessen, Germany

**Thomas N. Tully, Jr** DVM MS Dipl ABVP  
(avian)  
Associate Professor, Louisiana State  
University School of Veterinary Medicine,  
Baton Rouge, Louisiana, USA

**Amy B. Worell** DVM, Dipl ABVP (avian)  
Director, All Pets Medical Centre, West Hills,  
California, USA

---

# Introduction

There have been a number of surveys performed by veterinary research groups concerning the number of avian patients seen per week in the average small animal practice. In those practices that see avian and exotic patients, on average two to three bird cases are seen each week. Most of the veterinary surveys show that the vast majority of avian owners, approximately 80 per cent, do not seek veterinary care. There is therefore great potential for veterinarians to offer health care for these untreated birds and maintain them as healthy pets for their owners. To garner this population of potential avian clients, there must be competent caring avian veterinarians.

The general public has a basic conception that veterinarians do not know how to treat birds, or that a sick bird is a dead bird. This public perception is slowly changing in the face of significant medical advances in the field of avian veterinary medicine made over the last 20 years. These advances, and the expertise of avian specialists, have been acknowledged by the aviculture community and by lay avian publications such as *Bird Talk* magazine. These groups of bird owners are just the tip of the iceberg; we are looking to treat and care for all birds, and this can only occur when the general public is aware of the ability and availability of avian veterinarians to care for their pets.

Private practitioners founded the primary avian veterinary organization, the Association of Avian Veterinarians (AAV), in 1980. The majority of AAV members have always been clinical veterinarians. These practice owners saw an unfulfilled need in the veterinary community, and took up the challenge of meeting the avian pet owners' demands for adequate health care for their pets by gaining knowledge and experience and sharing it with like-minded colleagues. Since the veterinary schools and colleges at that time were woefully inadequate in teaching companion avian medicine, veterinarians had to learn through conferences and wet-labs. Slowly but steadily

over the last 20 years avian medicine and surgery has made its way into mainstream academia and veterinary continuing education programmes.

To add to the existing knowledge base of proceedings and journal articles, a number of reference avian texts have been published, as well as periodicals that keep practising veterinarians up to date with the latest trends in avian medicine. This information is especially useful to the high volume avian veterinarians. However, what about the majority of veterinarians, who see only a few birds a week and enjoy the variety of patients but do not want to specialize?

*Avian Medicine* has been developed to give the average small animal practitioner a complete information source for the basics of avian medicine and surgery. It is a multi-author text, which utilizes the international expertise of the avian veterinary community. By incorporating the knowledge of authors from Europe, Africa, Australia and North America, different techniques that have been successful in treating the average avian patient are covered.

The first five chapters cover the basic medical information needed to run a primary care avian practice. Again, the focus of the text is on introductory level material and the average companion animal practice. If you see between one and five birds a week, this text is for you.

The later chapters are species-specific. If a practice sees avian patients, it is not unusual to treat any one of these species. The information in these chapters will allow the veterinarian a comfort zone of knowledge in order to evaluate, treat and/or refer.

We hope the book reaches the groups of veterinarians and allied technical staff who need it the most; also veterinary students, veterinary technicians and the general veterinary practitioner.

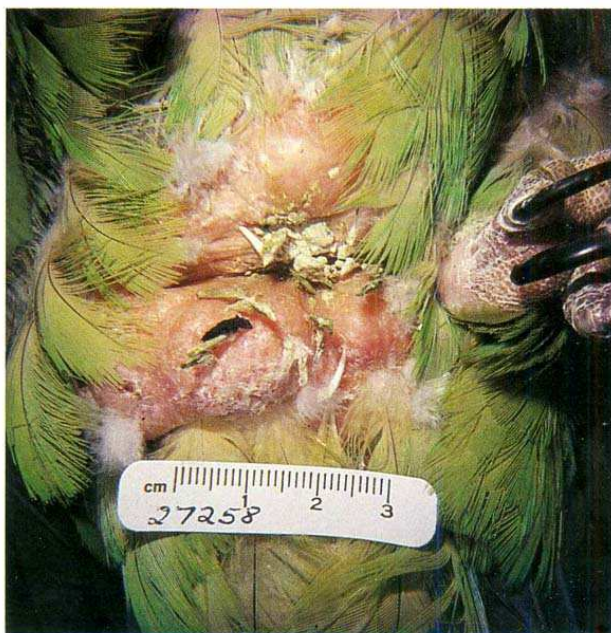Thomas N. Tully, Jr.  
Martin P.C. Lawton  
Gerry M. Dorrestein



**Plate 1** Abnormal feather development may be seen as lines in the feather due to endogenous steroid release during the growth phase. Note the black lines in the blue primary tail feathers.

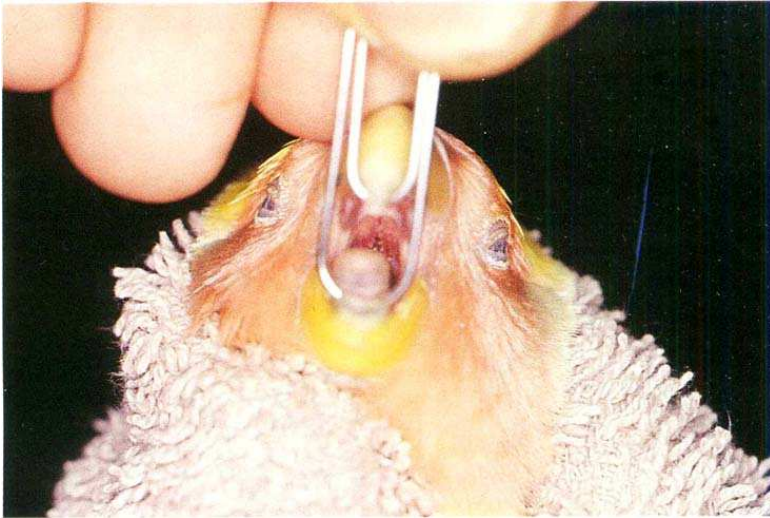

**Plate 2** An African grey (*Psittacus erithacus*) exhibiting neurologic signs that may be associated with hypocalcaemia.

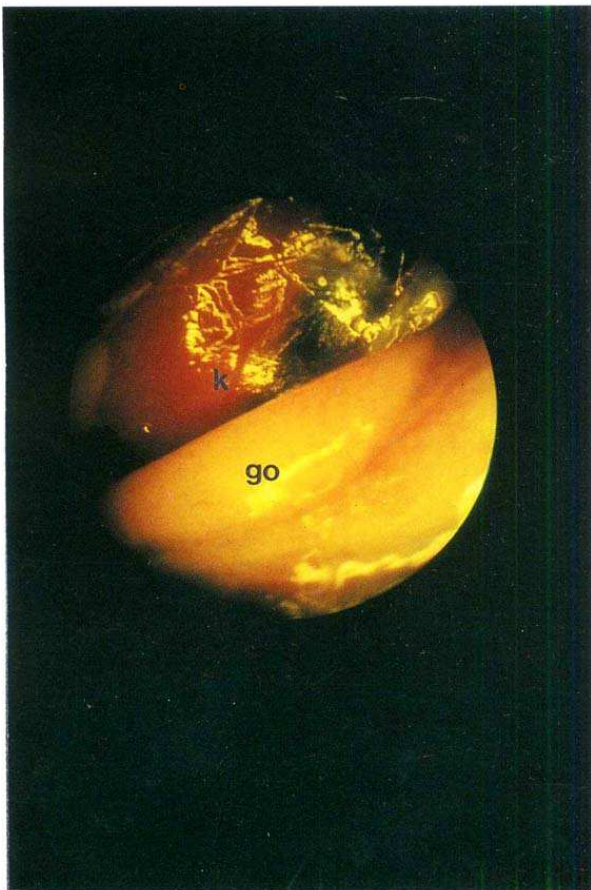


**Plate 3** Lipomata in an orange-cheeked Amazon (*Amazona amazonica*) in the caudal ventral area of the vent.

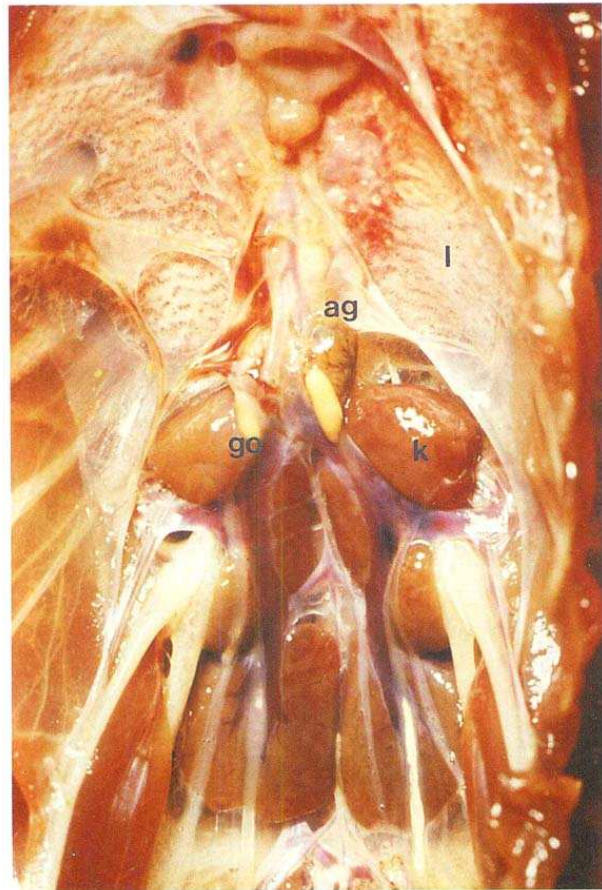




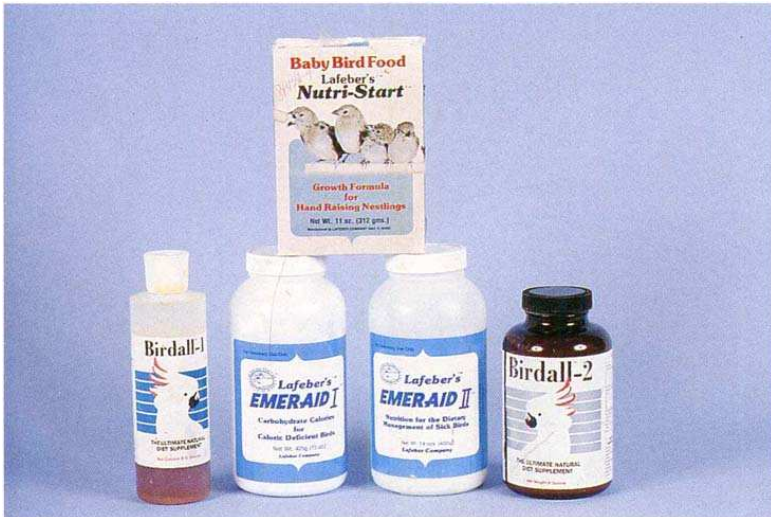**Plate 4** Examining the oral cavity of a cockatiel using a paper clip gag.



**Plate 5** Testis of a juvenile common buzzard: as = thoracic and abdominal air sac region; go = gonad; k = kidney.



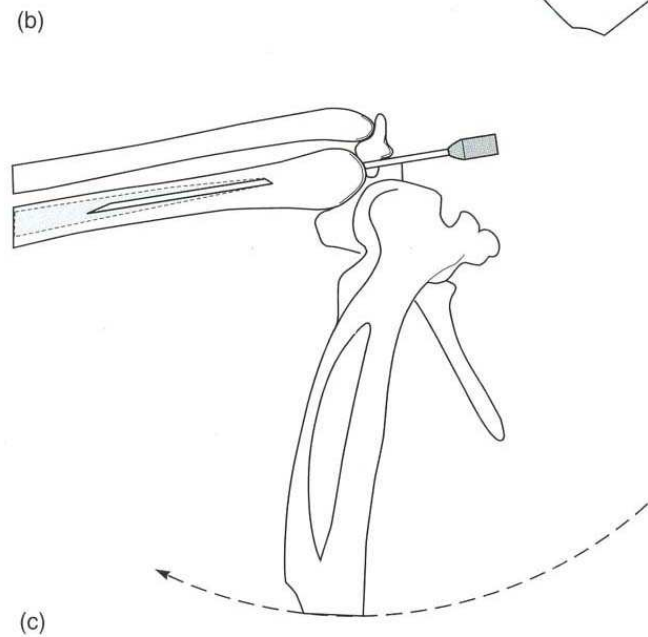
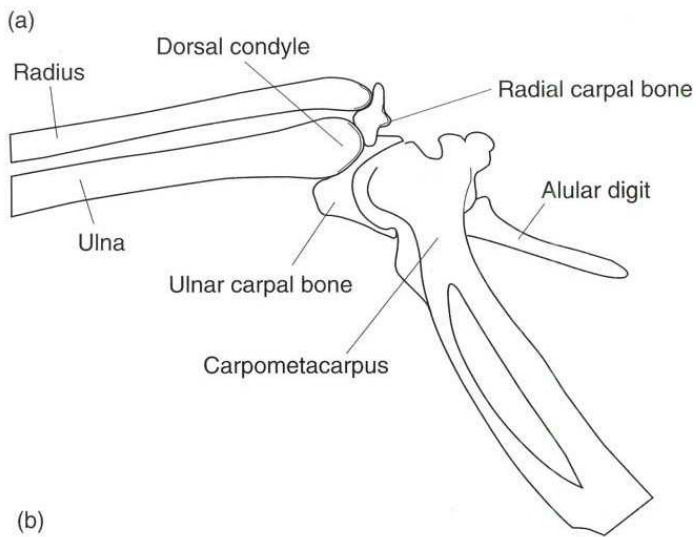
**Plate 6** Localization of testes in the abdomen of a juvenile Amazon: ag = adrenal gland; go = gonad; k = kidney; l = lung.



**Plate 7** Nutritional supplementation for sick birds is commercially available.




**Plate 8** An Amazon parrot being fed using a gavage feeding tube.



**Plate 9** (a) Distal ulnar placement of an intraosseous catheter in an Amazon parrot. (b) and (c) Schematic diagram of an intraosseous catheter placement in the proximal ulna.



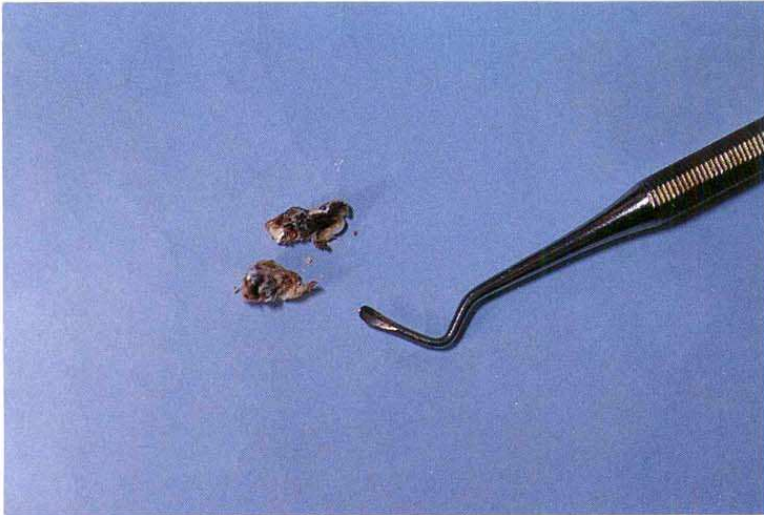**Plate 10** This dropping was from an ill parrot (*Amazona* spp.) The dropping contains excess urine, the urates are vividly coloured with biliverdin and there is only a small amount of faecal material present, indicating that the bird has not been eating.



**Plate 11** The bottom of this parrot's cage shows that the bird has passed normal faeces over the last few days. It was found to be acutely ill, and two droppings have increased urine and decreased faeces; the bird has also regurgitated its crop contents.



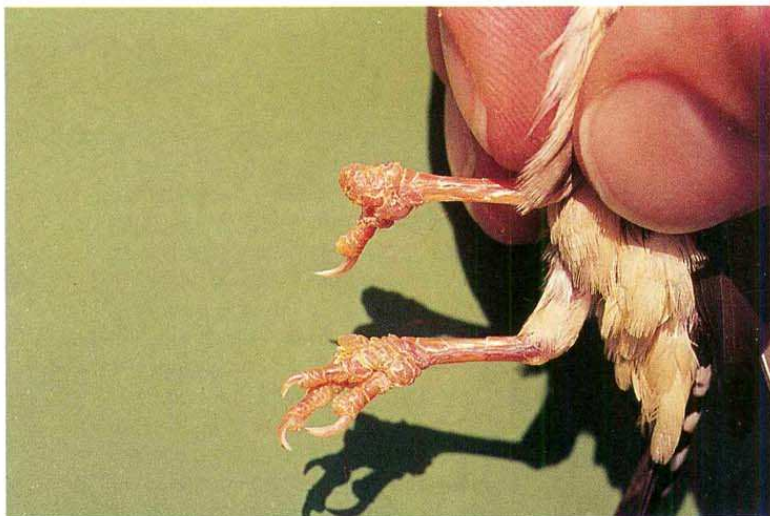**Plate 12** A Timneh grey parrot (*Psittacus erithacus timneh*) was presented with a large rhinoloth blocking and (permanently) deforming the nostril. The blockage had extended caudo-medially as an abscess and blocked the drainage of the periorbital sinus, causing swelling and inflammation around the eye. Removal of the abscess/rhinolith, culture of the moist infected mucus in the base of the abscess and 10 days of appropriate antibiotic therapy cured the sinusitis. However, the bird required its nostril to be cleared of rhinoloth every 4 months.



**Plate 13** This small dental tool is convenient for removing rhinoliths. These rhinoliths came from a red-fronted (Jardine's) parrot (*Poicephalus gulielmi*).



**Plate 14** Plants should be used for environmentally enhancing free flight aviaries.



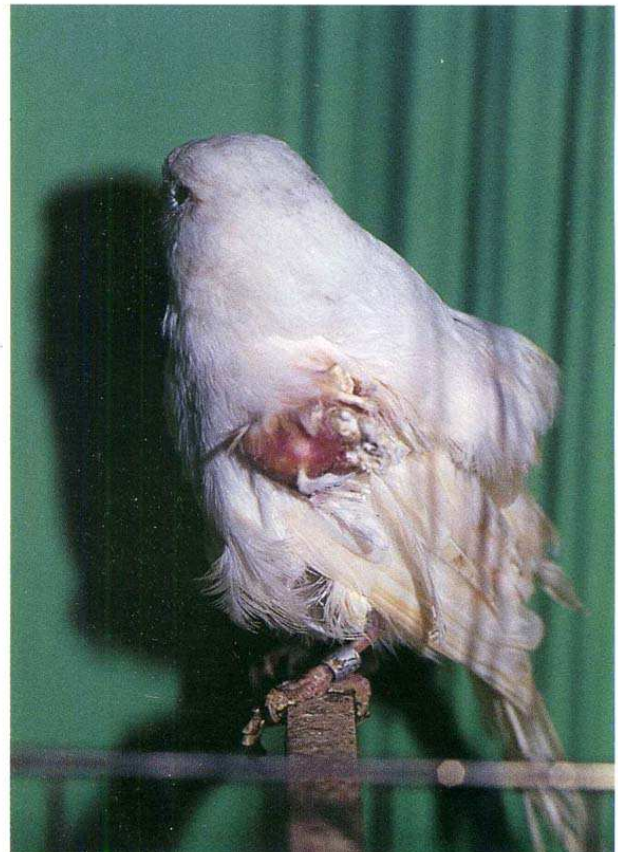**Plate 15** Zebra finch feet entangled in synthetic fibres.



**Plate 16** Gouldian Finch (*Chloebia gouldiae*) with feather loss and trauma in finches due to cage mate aggression.



**Plate 17** Two male whydahs (*Vidua* sp.) displaying their long tails.



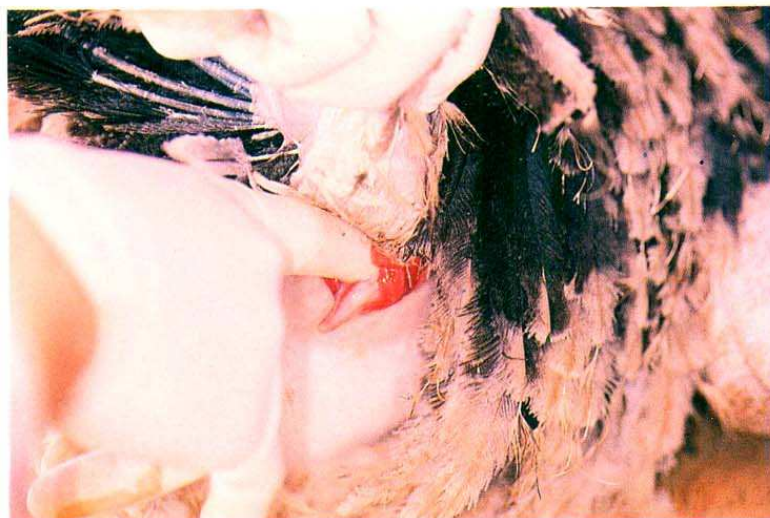**Plate 18** A canary with feather cysts.



**Plate 19** Finch with tassel foot.



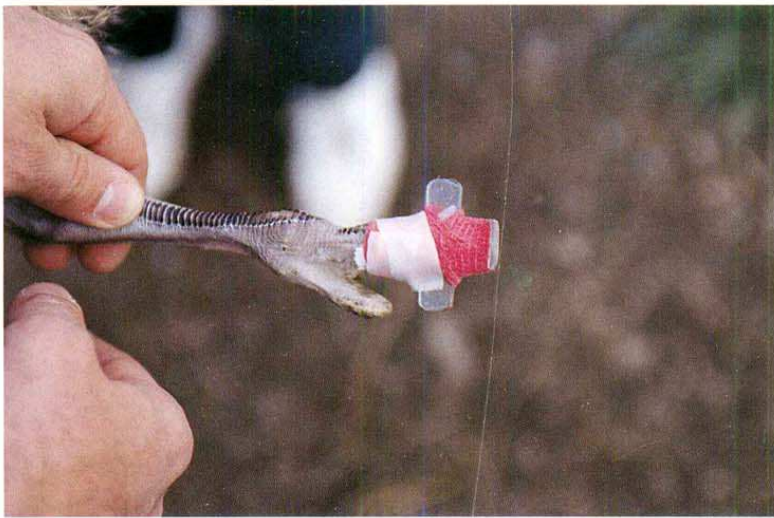
**Plate 20** A normal whooping crane showing the red skin on top of the head. The size of the red patch can be altered by the crane to reflect dominance or aggression.



**Plate 21** Vent sexing a 6-month-old male ostrich.



**Plate 22** Young emu with angular limb deformities.

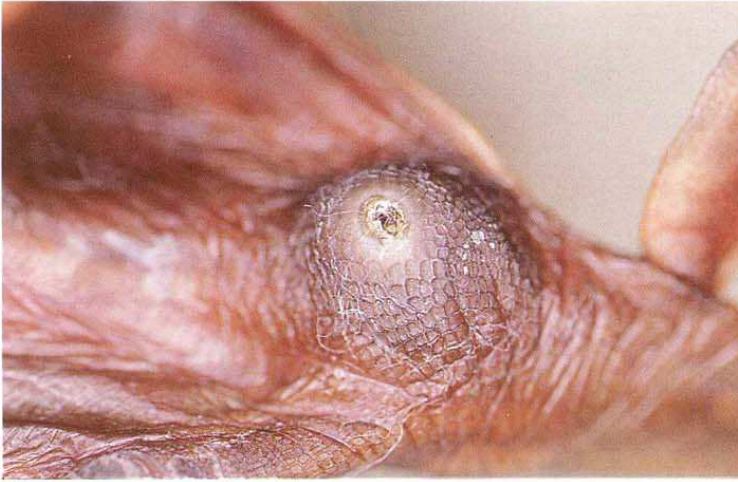

**Plate 23** Corrective splint used to treat rolled toe in a young ostrich.



**Plate 24** Large pen of ostriches, typical of growing production facilities.





**Plate 25** Bumblefoot in a red-breasted merganser.




**Plate 26** Golden pheasant (*Chrysolophus pictus*).



**Plate 27** Vulturine Guinea fowl (*Acryllium vulturinum*).



**Plate 28** Pheasant (*Tragopan satayu*).

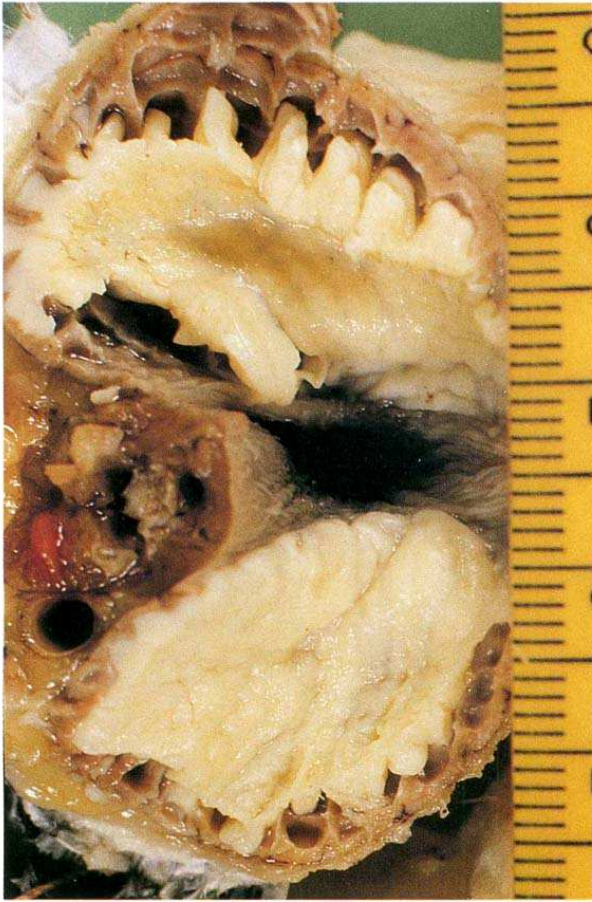


(a)

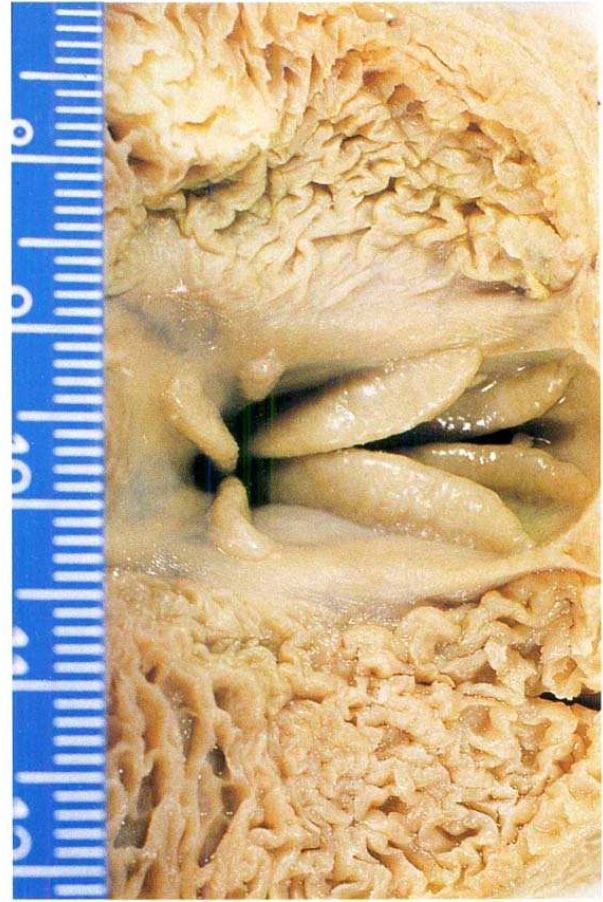


(b)

**Plate 29** (a) A Toco toucan and (b) a keel-billed toucan.




(a)

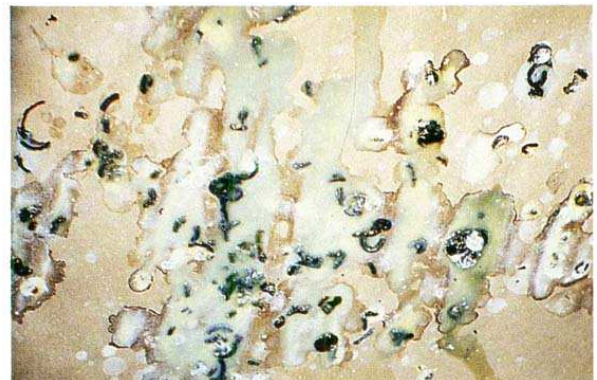


(b)

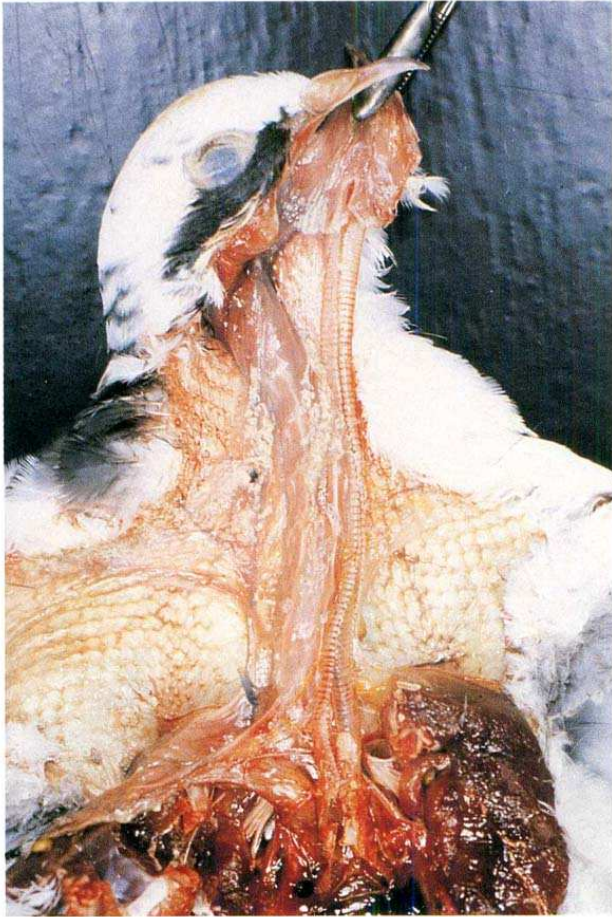
**Plate 30** The crop lining of pigeons producing crop milk at (a) day one and (b) day five.



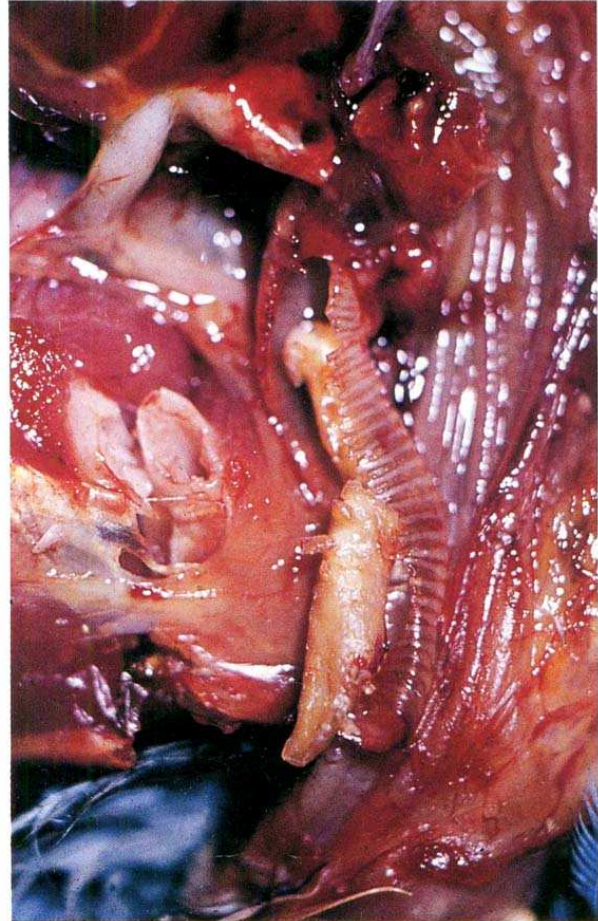
**Plate 31** A pigeon exhibiting torticollis due to a paramyxovirus infection.



**Plate 32** Yellow regurgitant and droppings due to an adenovirus infection.

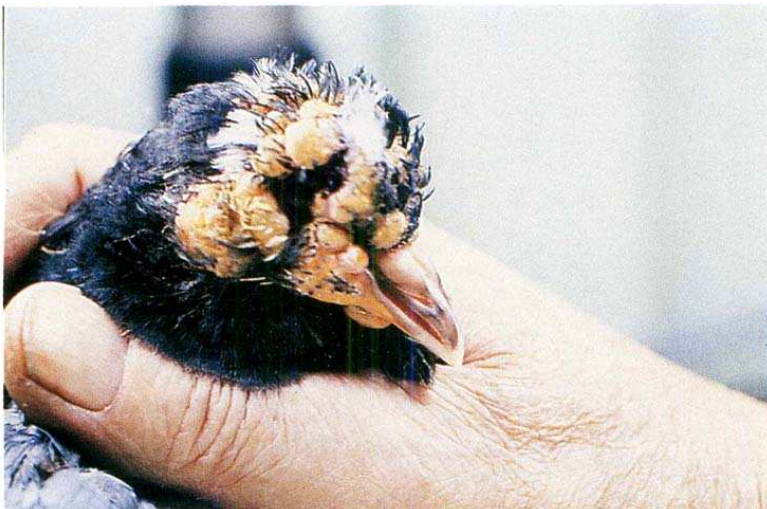

(a)



(b)

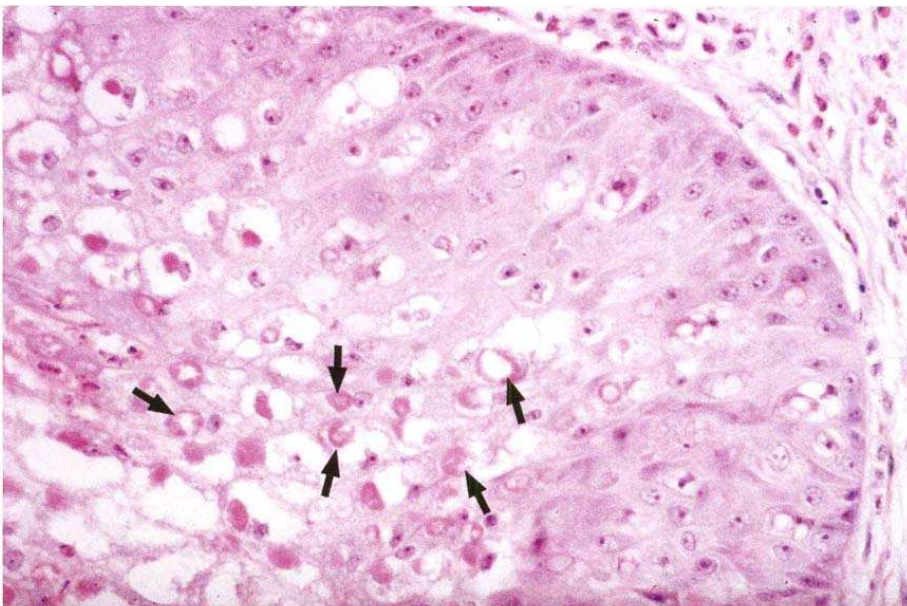
**Plate 33** (a) and (b) Diphtheritic membrane of the crop, larynx and trachea due to a herpesvirus infection.



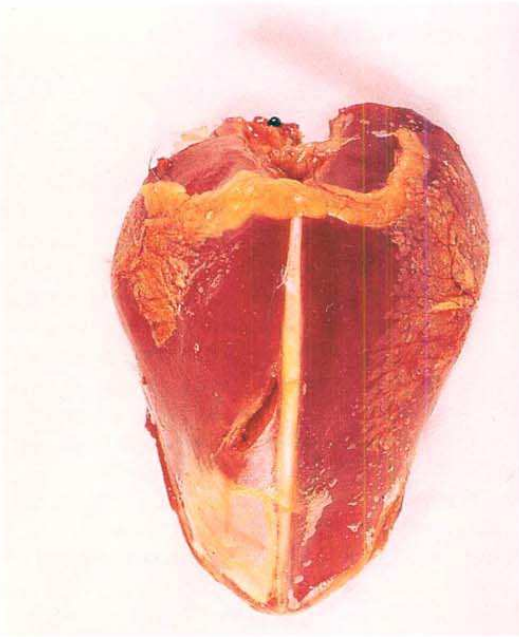
**Plate 34** Typical cutaneous lesions associated with an avian pox virus infection.



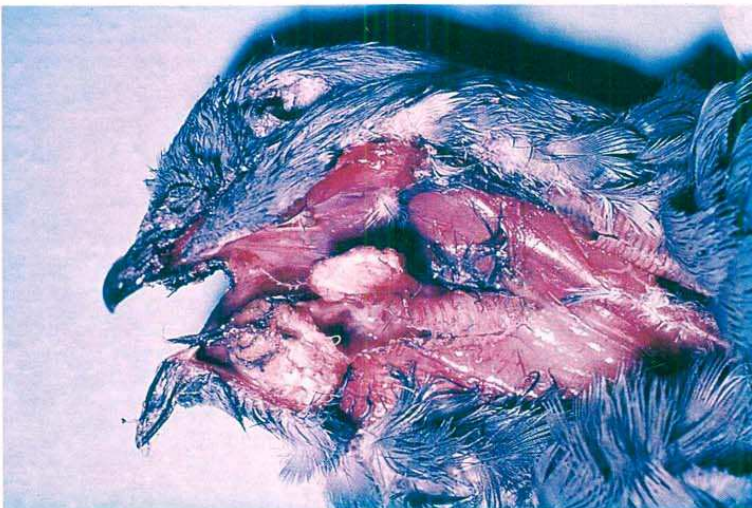
**Plate 35** Oral diphtheritic membrane from avian pox virus infection.



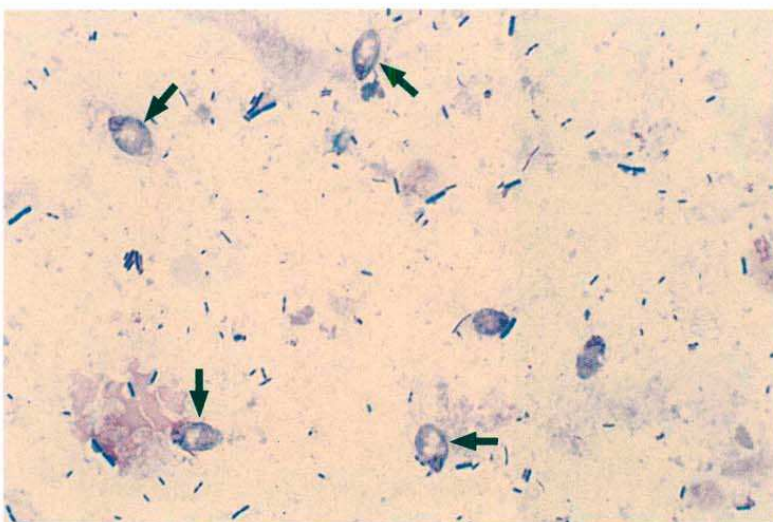
**Plate 36** Intracytoplasmic inclusion bodies (Bollinger bodies) associated with avian pox virus infection.



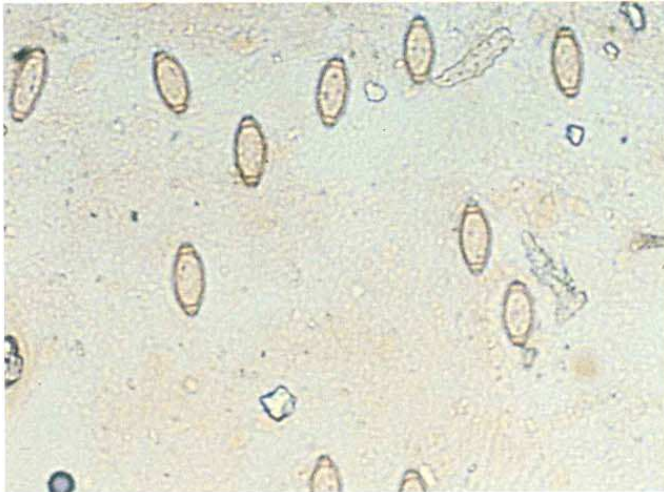
**Plate 37** Circumscribed area of necrosis typical of a streptococcal infection.



**Plate 38** Pigeons infected with trichomoniasis may develop caseous masses on the roof of the mouth.



**Plate 39** *Hexamita columbae*.



**Plate 40** Double operculated eggs of *Capillaria* spp. found in pigeon droppings.



**Plate 41** A pair of rainbow lorries (*Trichoglossus haematodus*).



**Plate 42** Feather colour supplement in the manufacturer's container.

---

# Basic anatomy, physiology and nutrition

*Patricia Macwhirter*

## Introduction

In companion animal practice, veterinarians traditionally treat dogs and cats – species that are significant because of the bonds they form with their human owners. Avian practice shares the focus on the human–animal bond, but in addition avian practitioners routinely treat cage and aviary birds, zoo birds, wild birds, racing and fancy pigeons, ducks, raptors, ratites and poultry. A fundamental challenge for the avian practitioner is to be able to offer quality patient care across this wide range of species as well as to understand the needs and expectations of their owners. There is an added dimension to this discipline, because many of the species that practitioners treat are currently threatened or endangered. Sadly, in some cases avicultural pressure has contributed to the demise of species in the wild. However, there is a strong movement among caring and responsible avian veterinarians to develop global links with bird owners and conservation groups to try and redress habitat damage and ensure the survival of wild as well as pet bird populations.

Because of the diversity of species encountered, avian medicine is best mastered by learning about one family of birds in some detail and then drawing comparisons (McLelland, 1991; Rubels *et al.*, 1992; Smith and Smith, 1992). In this chapter, avian anatomy, physiology and nutrition are reviewed using the psittacine species as a basic model; however, where appropriate, there is comparison with other avian species likely to be encountered in veterinary practice. When studying or treating birds, it is important to consider how each species has evolved and take every

opportunity to observe birds in their natural habitat. By thinking beyond the examination room, veterinarians can gain insight into medical and behavioural problems of individual patients as well as playing a role in trying to preserve avian biodiversity for future generations to experience and enjoy.

## Feathers

Feathers are unique to birds, and evolved from reptilian scales. They are arranged in feather tracts called pterylae. The unfeathered areas between the pterylae are called apteria (Figure 1.1).

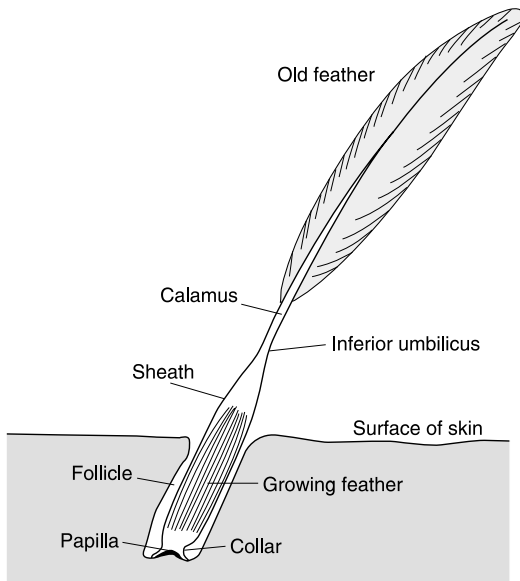
New feathers develop from the epidermal collar at the base of the feather follicle, and grow in an upward and outward manner. This development process is sensitive, and nutritional deficiencies, stress or exogenous cortisone can cause horizontal fault lines to occur on the emerging feather (Plate 1).

The central stalk or shaft of the feather is composed of the calamus or quill, which is present below skin level, and the rachis, above the skin. In developing feathers there is a nutrient artery that traverses the centre of the shaft and is surrounded in the calamus by feather pulp. The feather pulp and artery regress as the feather matures, but keratinized pulp caps remain as horizontal bars across the lumen of the shaft (Figure 1.2). If an emerging feather is cut or damaged, it may bleed profusely from the nutrient artery (a so-called blood feather).





**Figure 1.1** The unfeathered apertia may provide skin exposure without removing feathers to provide a site for subcutaneous fluid administration or, as shown here, for intradermal skin testing.

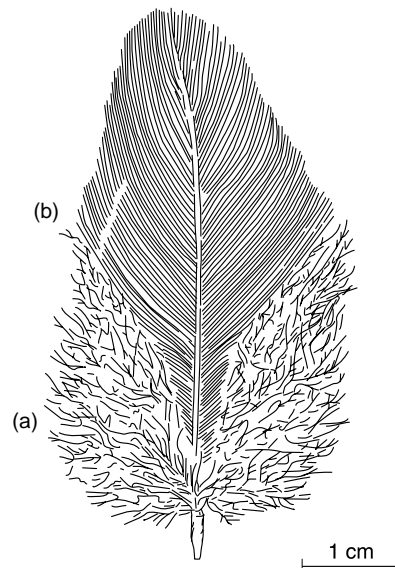


**Figure 1.2** Line drawing of a developing feather.

Emerging laterally at 45° to the rachis are the barbs, and emerging from the barbs at 45° are barbules. These interlock with each other by a system of hooks (or barbicels), which enables waterproofing. Preening restores interlocking if the barbules become dislodged. The vane is the portion of the feather extending either side of the rachis, and may be plumulaceous (soft and fluffy) or pennaceous (closely interlocked), depending on the individual type of feather (Figure 1.3).

Contour feathers are those that cover the bird's body. They have well-developed shafts with plumulaceous and pennaceous components to the vane. Covert feathers are small contour feathers present on the wings and tail.

Flight feathers, or remiges, are generally asymmetric in form to enable flight, and the vane is pennaceous. The primary remiges are those that emerge from the periosteum of the metacarpus, while the secondary remiges are those that emerge from the periosteum of the ulna. Primary remiges are numbered from the carpus distally, while secondary remiges are numbered from the carpus proximally. The tail feathers (or retrices) are structurally similar to remiges, but are symmetrical. They are numbered from the centre laterally.



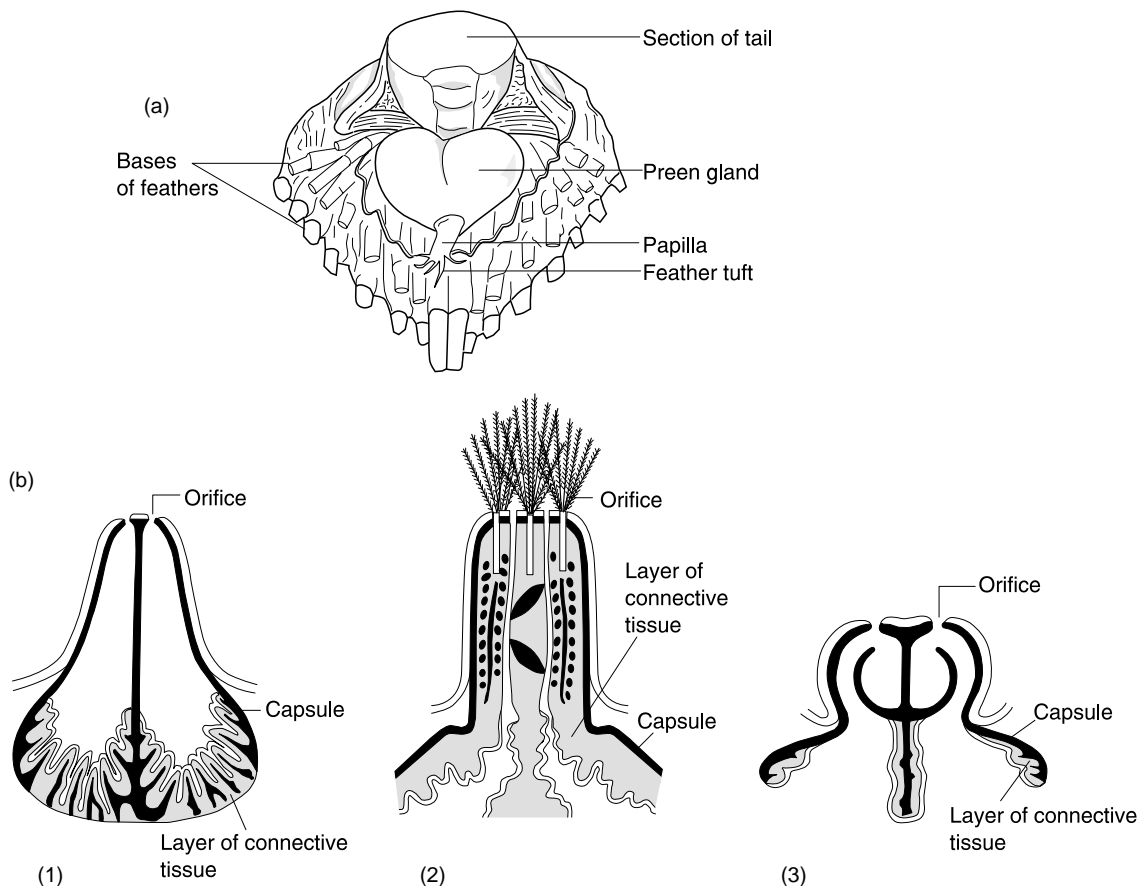
**Figure 1.3** A typical avian feather showing (a) plumulaceous and (b) pennaceous vane structure.

Birds have other feathers adapted for special purposes. Plume (or down) feathers have a rachis shorter than the longest barb, and non-interlocking barbules. These provide the undercoat. Powder downs are specialized down feathers located anterior to the hips, which produce a keratin material from the surface cells of barb-forming tissue. This performs a dry lubrication function. Powder downs grow continuously, and are often the first feathers to show abnormalities if a bird is infected with circovirus. Powder down feathers are most prominent in cockatoos, cockatiels and African grey parrots, so owners prone to feather allergies should avoid these species. Overgrowth of powder down feathers can occur if a bird is prevented from preening – for example, if it is collared or suffering from beak damage. Semiplume feathers have fluffy vanes, but the rachis is longer than the longest

barb. These usually lie near feather tracts to aid in insulation. Filoplumes are hair-like, with a long rachis and short barbs at the end. Bristles have a stiff rachis with few or no barbs at the end, and function like whiskers. After feathers (hypopnea) are small remnant feather structures attached to the shaft at the superior umbilicus, the position where the calamus emerges from the skin.

## Integument

Bird skin is thinner and more delicate than that of mammals. In most cases the subcutaneous layer is insufficient to suture surgically. The only epithelial glands are the uropygial glands and holocrine glands of the external ear canal, but the keratinocytes produce lipid, essentially making the entire skin an



**Figure 1.4** Line drawings of the uropygial gland (preen gland) representing various avian species. (a) Dorsal view of the gland on a White Leghorn chicken. (b) Details of papilla: (1) delicate type; (2) compact type; (3) unique passerine type.

oil-producing holocrine gland. Because they lack sweat glands, hyperthermic birds dissipate heat by increasing respiration and holding the wings away from the body. Cold birds ruffle their feathers and crouch to retain heat. Normal body temperature for birds is higher than for mammals (generally 40–44°C).

Bilobed uropygial glands are found dorsally at the base of the tail on most psittacine species, except for Amazon parrots and some Columbiformes (Figure 1.4). Each lobe is drained by a single duct, which empties into a lone papilla. The gland secretes a lipoid sebaceous material, which is spread over feathers during preening. Impaction (which can be treated by manual expression) or neoplasia are occasionally encountered. Uropygial glands are not essential, and can be removed surgically.

A brood patch forms on birds incubating eggs. The dermis on the chest becomes thickened and vascular, and feathers are lost. This structure should not be mistaken as pathological.

## Legs, claws and feet

In psittacines, digits II and III point anteriorly while digits I and IV point in a posterior

position. In passerines, digit I points anteriorly while digits II–IV point in the posterior direction.

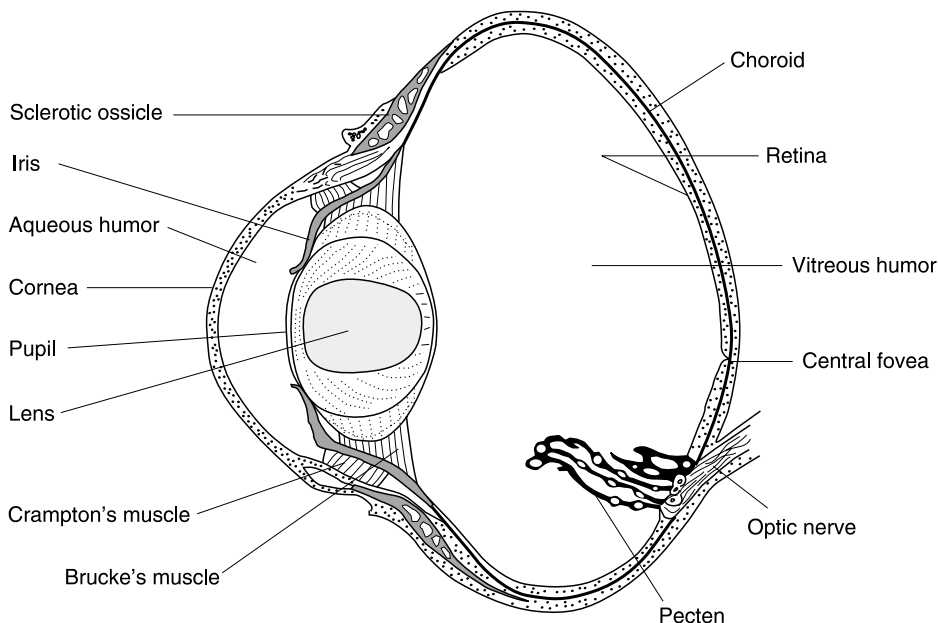
A bird's feet and legs are covered with scales – raised areas of highly keratinized epidermis separated by a fold of less keratinized skin. Claws have a strongly keratinized dorsal plate and a softer ventral plate that grows more slowly, thus producing the curved claws for perching. Vitamin A deficiency, e.g. from an all seed diet, can produce loss of the plantar footprint as well as hyperkeratosis and overgrown claws. Scaly mite (*Cnematoptes* sp.) can also induce hyperkeratosis and disrupt normal scale formation.

## Senses

### Sight

Birds possess great visual acuity. Most birds' eyes are very large, the globe is asymmetrical, and there are 10–18 ossicles (eyebones) that overlap to form a ring encircling the sclera. The sphincter and dilator muscles of the pupil are striated; therefore, unlike mammals, atropine has no effect.

A soft lens allows for rapid accommodation. The retina is thick and has no direct blood



**Figure 1.5** Cross-section of the avian globe showing the pecten as it projects into the posterior chamber.

vessels but many cones, which allow for excellent colour vision, while the fovea is well developed and, in some avian species, multiple, allowing for good visual acuity. The pecten, which projects into the vitreous body from the optic nerve and consists of capillaries and extravascular pigmented stromal cells, provides nutrients to the avascular retina (Figure 1.5). In some birds, small regular torsional movements of the eye sweep the pecten through the vitreous (Myer, 1986).

Birds' dorsal and ventral eyelids do not blink, and there are semiplumes rather than eyelashes. There are no meibomian glands, and the third eyelid blinks in a nasal to temporal direction. Eye movements are limited, but this is compensated for by greater head mobility and by the ability of both eyes to move independently.

## Hearing

Birds have no pinna. Instead, specialized contour feathers (ear coverts) cover the meatus. The tympanic membrane projects outwards rather than inwards, and the columella is the only bony ossicle (compared with three ossicles in mammals). The cochlear duct is short when compared to that of mammals. Because of these differences, birds have good discrimination of pitch (frequency) but are less sensitive to higher and lower tones than humans. Temporal resolution is about 10 times faster than in humans.

## Taste

Taste buds are present on the roof and floor of the oropharynx, but not on the tongue. Parrots, budgerigars, hummingbirds and nectar feeders actively select sugar solutions. Insectivorous and granivorous species may not be particular in selecting food for taste.

## Smell

The sense of smell in psittacines and passerines is, in general, poorly developed. In other species – for example, kiwis, vultures and albatrosses – the sense of smell may be well developed.

## The digestive system

### Beak

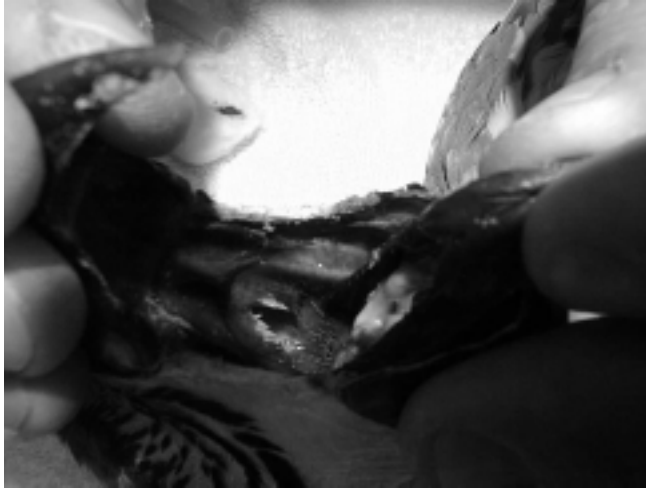The beak consists of the bones of the upper and lower jaws and their keratinized sheaths, the rhamphotheca (Figure 1.6). In psittacines, the jaws are connected to the skull by kinetic joints. The upper jaw is called the rhinotheca and the lower jaw is the gnathotheca. These are composed of modified epidermis, with cells of the *stratum corneum* containing free calcium phosphate and hydroxylapatite crystals as well as abundant keratin. Beak tissue extends outwards towards the surface, over much of the beak, extending to the edges and tip. In cases of chronic nasal discharge, vertical defects in the rhinotheca leading from the nares to the tomia (the cutting edge of the beak) are occasionally seen.

### Oropharynx

Birds have no soft palate. The opening to the nasal passageway, the choana, is a slit



**Figure 1.6** The large beak of a green winged macaw (*Ara chloroptera*).



**Figure 1.7** The choanal slit is the oral nasal interface located in the dorsal aspect of the oral cavity.

between the palatine folds of the roof of the mouth (Figure 1.7). Caudally directed papillae are abundant in this region. The infundibular cleft, which opens to the auditory tube, is situated immediately caudal to the choana. Parrots have intrinsic muscles in the tongue, while other birds have only extrinsic muscles. Salivary glands produce mucus rather than watery secretion, and are abundant on the walls of the oropharynx. Vitamin A deficiency may produce hyperkeratosis of these glands.

### Oesophagus and crop

The oesophagus goes down the right side of the neck – opposite to its situation in mammals. The crop is a dilatation of the oesophagus in which food is stored and softened prior to passage into the proventriculus. No digestion takes place in the crop. Food enters the crop on the right and exits caudally on the midline, where the oesophagus extends to the proventriculus. Enlarged thyroid glands or lesions due to *Trichomonas* spp. can cause obstructions in this region and induce vomiting, crop dilatation or respiratory distress due to pressure on the trachea.

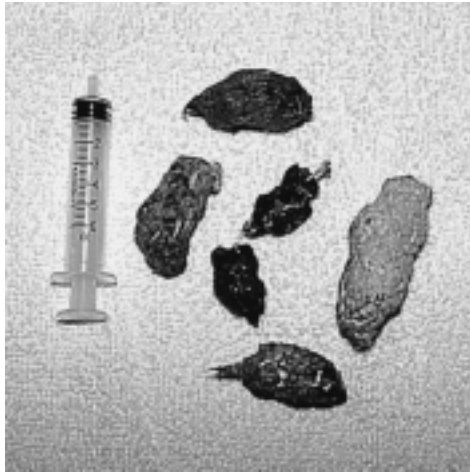A full crop can be viewed under the skin at the base of the neck in nestlings without feathers, or in adults that have lost feathers. Alarmed owners will sometimes present birds, not realizing that this structure is normal.

### Stomachs

The cranial proventriculus (or glandular stomach) is thin walled and is lined with mucus-secreting columnar epithelial cells and oxynticopeptic cells, which secrete hydrochloric acid and pepsinogen. The caudal ventriculus or gizzard lies ventrally on the left side of the abdomen, with the pylorus joining the duodenum just to the right of the midline. The proventricular-ventricular junction is a common site for inflammation associated with megabacteria infections in budgerigars.

The anatomy of the stomachs relates to the bird's diet. In granivorous birds, glands in the thick, biconvex, muscular gizzard wall secrete a hard, proteinaceous, cuticular lining, the koilin. This helps to pulverize food in preparation for proteolysis in the intestinal tract. The koilin is usually yellow or green due to bile pigment regurgitation, and the gizzard generally contains grit. In finches, gizzard worms (*Acuaria* sp.) are sometimes found beneath the koilin lining.

Birds that consume predominately soft food or nectar, such as the lorikeets, have poorly developed muscular gizzards. On the other hand, birds consuming large prey items compared to their body size (for example penguins, which feed on whole fish) may have enormous stomachs relative to their body size. As a normal digestive process, the raptors regurgitate castings composed of bones and



**Figure 1.8** Regurgitated casts produced in the proventriculus of raptor species.

fur of their prey species from their gizzards (Figure 1.8).

## Intestines

The duodenum, jejunum and ileum are located on the right side of the abdomen. Folds and villi do not contain lacteals, but have a well-

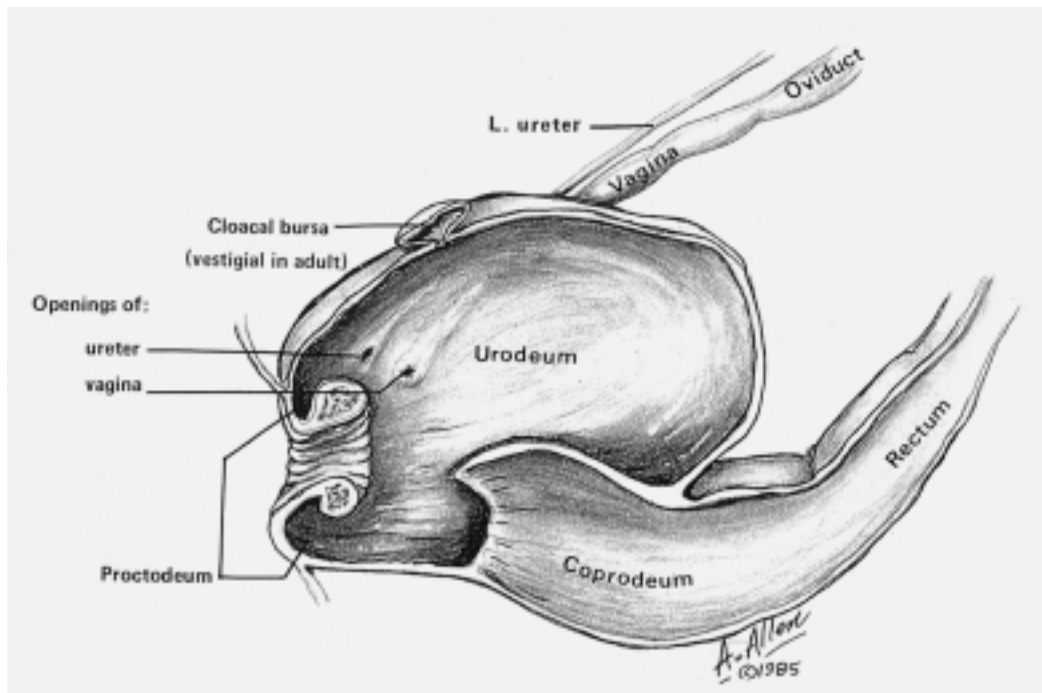
developed capillary system instead. Many species, particularly poultry, ducks and quail, have large paired caeca, but these are absent or vestigial in psittacines, passerines and Columbiformes. Caeca are the site of blackhead (histomoniasis) infection in gallinaceous birds. The rectum is usually short and straight. The liver consists of two lobes joined cranially. The gall bladder is usually absent in psittacines and ostriches, but is present in many other species. It receives bile from the hepatocystic duct from the right lobe only.

The vitelline diverticulum (Merkel's diverticulum) is the remnant of the yolk duct, and is located opposite the cranial mesenteric artery. In altricial birds the yolk sac is generally resorbed by 4 days, while in precocial species it may persist for up to 10 days.

## Cloaca and vent

The cloaca consists of:

- the cranial coprodeum, which receives faeces from the rectum
- the middle urodeum, which receives the oviduct or ductus deferens and the ureters on the dorsolateral surface



**Figure 1.9** Cross-section of the cloaca.

- the caudal proctodeum, on the dorsal surface of which is located the bursa of Fabricius and on the floor of which is located the phallus if present (not in psittacines) (Figure 1.9).

Urine deposited in the urodeum moves retrograde into the rectum, where resorption of water takes place. Stressed birds may have watery droppings because they defecate before this occurs. The vent is the external opening to the cloaca.

## Respiratory system

The nares are located above the beak, and may be surrounded by feathers or present in a fleshy cere. In budgerigars the cere is generally blue and smooth in males as opposed to brown and lumpy in females, but this varies depending on the bird's age, colour, health and reproductive status. Paired nasal cavities communicate in psittacines, but not in passerines. A cornified flap of tissue, the operculum, is located in the nasal cavity. Care must be taken not to mistake this for a nasal foreign body, as it is a normal structure (Figure 1.10). There are three conchae; the rostral, middle and caudal. The caudal nasal concha does not connect directly with the nasal cavity, but instead opens dorsally into the infra-orbital sinus.

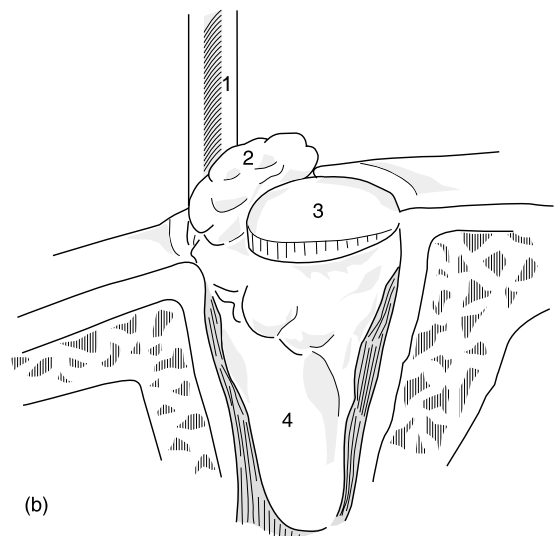


**Figure 1.10** (a) Operculum located in the nasal opening of an umbrella cockatoo (*Cacatua alba*). (b) Line drawing of the opercular bone showing the removal of a rhinolith. (1) probe; (2) rhinolith; (3) operculum; (4) conchae.

The infra-orbital sinus is an irregular cavity that runs extraosseous and rostroventral to the eye. It has two exits, both dorsal; one to the nasal cavity and the other to the caudal nasal concha. This makes drainage of exudates difficult, so surgical intervention may be necessary in many cases.

In birds, the larynx lacks vocal cords and plays no part in vocalization. The trachea is located on the left side, and contains complete cartilaginous rings (360°). Because of this, cuffed endotracheal tubes should be avoided. There have been incidents of tracheal necrosis due to vascular compromise caused by the use of cuffed endotracheal tubes. The syrinx is located at the bifurcation of the trachea, and produces voice by vibrations of bilateral tympaniform membranes during the expiratory phase of respiration. Successful surgery to devocalize parrots has not yet been devised, as the tympaniform membranes are obscured by intricate muscles and are difficult to access. Devocalization by cauterizing the tympaniform membrane is possible in gallinaceous birds but is not always successful, and there is risk involved in the surgery. Male ducks have a cartilaginous out pocketing of the trachea at the level of the syrinx called the syringeal bulla. This should not be mistaken for an abnormal structure on radiographs or at autopsy.

The lungs are small and recessed in the ribs. There are no lobes or alveoli, and expansion during inspiration is limited.



Primary bronchi form at the tracheal bifurcation, while four groups of secondary bronchi connect with the air sacs. Parabronchi (tertiary bronchi) anastomose freely with other parabronchi and connect with the air sacs. Each parabronchus has anastomosing air capillaries that exit from it and are surrounded by blood capillaries. There are two types of parabronchi; paleopulmonic, in which there is unidirectional flow of air through the air capillaries, and neopulmonic, in which there is bidirectional flow. Gaseous exchange occurs between the air capillaries and blood capillaries. The predominantly one-way counter-current flow of blood and air allows for very efficient oxygen exchange in birds compared with mammals.

Psittacines have paired caudal air sacs (caudal thoracic and abdominal) and paired cranial air sacs (cervical and cranial thoracic), as well as one unpaired medial sac with several diverticula (clavicular). Gas exchange does not occur in the air sacs, which are hollow spaces with thin walls consisting of simple squamous epithelium supported by a small amount of connective tissue.

There is no diaphragm, and the triangular shape of the combined thoracic and abdominal cavities allows for a bellows-like effect during breathing. Both inspiration and expiration require active muscle contraction. Particular care should be taken to avoid constricting birds' respiration during restraint or when bandaging.

## Breathing

Air takes two complete breathing cycles to pass through the respiratory passages.

### 1 First breathing cycle

- Inspiration 1: the air goes into the trachea, past the lungs and into the caudal air sacs; some stays in the lungs, moving directly into the secondary bronchi and parabronchi to undergo gas exchange.
- Expiration 1: most of the air goes from caudal air sacs to the lungs, parabronchi and then to the air capillaries, where gas exchange occurs. Some air escapes from the primary bronchus up the trachea.

### 2 Second breathing cycle

- Inspiration 2: air goes from the lungs to the cranial air sacs.
- Expiration 2: air is expelled via the primary bronchus and trachea.

It is possible to respire birds via a breathing tube placed in the abdominal air sacs (Figure 2.7) or the clavicular air sac (Figure 5.11). These options are useful in anaesthetizing birds with upper airway obstructions, or when allowing upper airway injuries to heal.

## Male reproductive system

Birds have paired internal testes that may be white, cream, yellow or melanistic (for example, in cockatoos and rosellas). They are located near the cranial pole of the kidneys, and may enlarge over 50-fold during breeding. Daylight hours and other environmental triggers are important in initiating gonadotrophin release, testicular development and testosterone production.

The epididymis lies dorsal to the testes, and is a system of ductules to collect sperm. Sperm storage and maturation occurs in the convoluted ductus deferens, which leads from the epididymis to the urodeum. There are no accessory sex glands.

A phallus is present in some species, notably ducks, geese and ratites, but not in psittacines (Figure 1.11). This organ is solely reproductive in function and is not associated with urination. The semen travels via a groove on the external surface of the phallus. The erectile tissue is lymphatic. Lacerations, abscesses and paralysis of the phallus are occasionally encountered, particularly in ducks, when several males attempt to mate with the same female and the organ gets injured in the fray. If reproductive function is not important, for example in pet ducks, the phallus can be amputated.

## Semen

Birds produce sperm of high density and viscosity. Capacitation is not necessary for fertilization. Once ejaculated into the oviduct, sperm is stored in the spermatid fossulae at





**Figure 1.11** Protruding phallus of a male ostrich.

the uterovaginal junction and the glandular grooves and tubular glands of the infundibulum. It may remain fertile for many days to weeks, depending on the species and the individual bird.

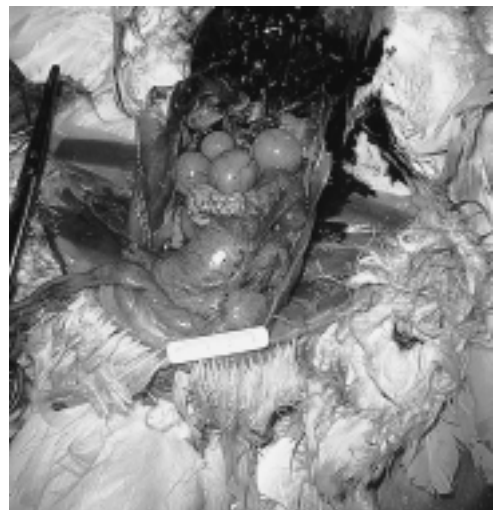## Female reproductive system

In most species, apart from raptors and kiwis, only the left ovary and oviduct develop. The immature ovary is small and triangular, and resembles pancreatic tissue. It is generally cream or white but may be melanistic, particularly in macaws, rosellas and cockatoos. The mature ovary looks like a cluster of grapes as primary oocytes develop into follicles and become mature (Figure 1.12).

After ovulation, the oocyte is engulfed by the oviduct and formation of an egg begins. There is no corpus luteum, and progesterone levels drop rapidly after ovulation. This stimulates additional leutinizing hormone secretion, which promotes ovulation of the next mature follicle. The post-ovulatory follicle is believed to secrete non-steroidal hormones that are involved in oviposition and nesting behaviour (King and McLelland, 1984). Fertilization is not required for egg formation.

The oviduct enlarges tremendously during egg laying, and occupies much of the left abdomen. It is composed of five sequential

regions. The infundibulum is the funnel-shaped anterior opening where fertilization and formation of the yolk membrane and the outer and chalaziferous layer of albumen occur. Thick albumen is secreted in the glandular magnum, along with sodium, magnesium and calcium. The isthmus produces the shell membranes, and its glandular tissue is less well developed than that of the magnum. The uterus has leaf-like longitudinal folds, and is the site of shell formation. It takes around 5 hours for an egg to pass from the



**Figure 1.12** Mature ovaries in a hen.

infundibulum to the uterus; it remains in the uterus for 20–26 hours, and is then expelled through the vagina.

In birds the female is heterogametic ('zw' sex chromosomes) and thus determines sex, while the male is homogametic ('zz' sex chromosomes). Aviculturalists will sometimes talk about a cock bird being 'split' for a particular recessive sex-linked gene – for example, a normal green Indian ringneck 'split for lutino'. It is not possible for a hen to be 'split' for a sex-linked gene, as whatever gene is present on the z chromosome will manifest phenotypically.

## Urinary system

Birds have paired kidneys recessed into bony depressions in the synsacrum, the renal fossae. There are three lobes, with no distinct medulla or cortex. Avian kidneys have both reptilian and mammalian features, with the renal lobule containing two types of nephrons:

- 1 The cortical type with no loop of Henle, which are uricotelic (i.e. produce uric acid as the end product of nitrogen excretion)
- 2 The less common medullary type with a loop descending into the medullary region of the lobule, which produce urine.

Blood supply to the kidneys comes from two sources. Arterial blood from the aorta is the only source for the renal corpuscle. The renal portal system supplies two-thirds of the blood, and comes as venous blood from the large intestines and pelvic limbs. It enters the peritubular capillary network within the cortical region of the lobule, where it mixes with arterial blood from the renal corpuscle. All of the renal blood drains via efferent veins to the common iliac vein or caudal vena cava.

Infections of the feet, legs or lower intestines may drain to kidneys and cause septic nephritis. Renal neoplasia or infection may cause venous stasis of the pelvic limbs or paralysis due to pressure on the sciatic nerves. Injections into birds' legs of drugs that are cleared by the kidneys should be avoided because, due to the renal portal system, such drugs may be excreted before entering the general circulation or before the therapeutic agent has been diluted by the general blood

circulation. Unfortunately, some avian species, such as ratites, may have to be injected in the large leg muscles.

Urine is drained by ureters, which empty into the urodeum; it is then moved by retroperistalsis into the rectum, where resorption of water and salt takes place.

Uric acid is produced by the liver, transported in the blood, and excreted by means of glomerular filtration and tubular secretion. In the collecting tubules it forms a colloidal solution which allows transport through the kidney without precipitation.

## Endocrine system

### The pituitary gland

The neurohypophysis produces arginine vasotocin (AVT), which is analogous to mammalian antidiuretic hormone, and mesotocin (MT), which is analogous to oxytocin. AVT, MT and oxytocin will all induce uterine contractions in birds.

There is no separate *pars intermedia* in the avian pituitary, and both adrenal corticotrophic hormone (ACTH) and melanin stimulating hormone (MSH) are secreted by the cortico-melanotrophic cells of the adenohypophysis. The adenohypophysis also produces prolactin, which stimulates proliferation and sloughing of mucosal cells of the crop wall for the production of 'crop milk' in doves, pigeons and most psittacines. This occurs in parents of both genders just before the eggs hatch, but the mechanism and the identity of the avian prolactin releasing factor has not yet been determined. Pituitary tumours are occasionally encountered in budgerigars.

### The thyroid

The thyroid, which controls moulting, is located within the thoracic inlet and is not palpable externally. Enlargement due to goitre or neoplasia may cause wheezing respiration and crop dilatation in budgies, but in this species goitre has not been associated with hypothyroidism. In pigeons, on the other hand, goitre has been associated with clinical signs

of hypothyroidism. Thyroid hormone is necessary for the growth, differentiation of structure and formation of patterns on feathers.

## The adrenal glands

The adrenal glands are not clearly divided into a cortex and medulla; rather, the cortical and chromaffin tissues are intermingled. Corticosterone is the most important corticoid hormone in birds. In birds possessing a nasal salt gland, such as ducks, corticosterone functions as a mineral-regulating hormone by acting simultaneously on the small intestine, kidney and nasal salt gland. In birds without a nasal salt gland, who are unable to tolerate hyperosmotic drinking water, mineral regulation occurs via aldosterone (as in mammals).

## The pancreas

Glucagon, secreted by alpha cells, occurs at levels 10 times higher than in mammals. Somatostatin, which is produced in the D-cells, is also present at higher levels than found in mammalian species. Conversely, insulin, secreted by beta cells, occurs at levels only one-sixth of those in mammals. Budgerigars and cockatiels frequently develop diabetes mellitus or 'deranged carbohydrate metabolism', resulting in hyperglycaemia, but the pathogenesis of the condition is unclear. Some birds respond to treatment with insulin.

## The pineal body

The pineal body is a median, conical projection of the diencephalon involved with photoreception, circadian rhythms and reproductive control. Its secretions affect the hypothalamus, and it may supply immunocompetent cells for surveillance of the central nervous system.

## Neurological system

The avian brain is lissencephalic with minimal convolutions. The *corpus striatum* is well developed while the cerebral cortex is under-

developed; hence instincts dominate bird behaviour. The optic lobes are very large, consistent with excellent vision in most species.

## Circulatory system

Healthy birds have excellent endurance and exercise capacity. Compared with mammals, the heart is larger and beats faster, the arterial pressure is greater and the peripheral resistance lower. The aorta is derived from the right rather than the left fourth arterial arch. The right jugular vein is much larger than the left, and is a preferred site of blood collection in most species.

## Blood

Birds have large nucleated erythrocytes that live only 20–35 days (compared with 120 days in most mammals). There are also nucleated thrombocytes rather than platelets, and heterophils rather than neutrophils. Erythropoiesis takes place in the yolk sac and the bone marrow (Hawkey and Dennett, 1989).

## Lymphatic system

Thymus progenitor cells come from the yolk sac and marrow, and differentiate into immunologically competent T cells that regulate cellular immunity. These colonize secondary lymphoid tissue in the spleen, marrow and lymph nodules.

The spleen does not serve as a reservoir for blood. It is small, spherical and located dorsal to the liver in psittacines and pigeons, but can show marked enlargement in response to antigenic stimulation, particularly with psittacosis. In canaries and finches, the spleen is comma-shaped.

The cloacal bursa (of Fabricius) is a diverticulum on the dorsal surface of the proctodeum, which is unique to birds. Progenitor cells from the yolk sac differentiate into immunologically competent B lymphocytes, which colonize secondary lymphoid tissue. This organ regresses in adult birds.

Birds have two thoracic ducts, but lymphatic tubules are less numerous than in mammals; they follow blood vessels and empty into large veins. Variable amounts of lymphoid tissue occur in virtually all avian tissues and organs, but lymph nodes occur in only a few species (not psittacines).

## Musculoskeletal system

The avian skeletal system has intricately evolved as a highly efficient, strong, lightweight and aerodynamic apparatus. It has specific adaptations, which, along with the bird's feathers, muscles and specialized circulatory and respiratory systems, enable flight (Krautwald *et al.*, 1992).

There are two main types of bone:

- 1 Pneumatic bones, which are found in the skull, vertebrae, pelvis, sternum, ribs, humerus and sometimes the femur
- 2 Medullary bones, which have interconnecting spicules growing from the endosteal surface of the cortical bone and fill the medullary cavity in response to estrogens. These provide a store of calcium, and should not be mistaken as pathological on radiographs of egg-laying birds.

There are also two types of muscle:

- 1 Red muscle, which uses fat as an energy source
- 2 White muscle, which uses glycogen as an energy source.

Many avian bones are fused to decrease weight, increase strength and improve the bird's aerofoil effect. The spine is divided into cervical, fused thoracic, synsacral (fused lumbar, sacral and caudal vertebrae), free caudal and fused caudal (pygostyle) sections. The number of vertebrae varies with the species.

There is generally only one mobile joint in the lower back (this is between the sixth and seventh thoracic vertebrae in budgerigars; Evans, 1982), and it is at this point that fractures and soft tissue injuries most commonly occur, particularly in birds that are hypocalcaemic. Damage to this site should be considered in cases of bilateral leg paresis. The seventh and eighth thoracic vertebrae are fused to the lumbar vertebrae as well as to the overlapping ilia.

Caudal cervical and thoracic vertebrae have attached ribs. The cervical ribs are short and fused to the vertebrae, while the thoracic ribs articulate dorsally with vertebrae and (in most cases) ventrally with a large central carina or sternum (the keel bone). Uncinate processes anchor the caudal edges of some of the ribs to the cranial edge of the subsequent rib and lend strength to the thoracic cage, but make surgical access to the thoracic cavity difficult.

## The thoracic limb

The thoracic girdle is comprised of the scapulae, clavicles or furunculae (which are fused medially) and strong coracoid bones, which act as struts for the wings. In most species, the triosseal foramen is formed by the articulation of these three bones. The tendon to the supracoracoideus (deep pectoral muscle) passes through this foramen to attach onto the head of the humerus. Contraction of this muscle, (along with greater air pressure under the wing) helps lift and alter the angle of the wing's leading edge, while contraction of the overlying superficial pectoral muscle causes the wing to lower. The pectoral muscles are well developed and provide a convenient muscle mass for injection in even very small birds, but injections should be avoided in racing pigeons' pectoral muscles because irritant solutions could impair flight. Clavicular or coracoid fractures may impair flight without causing noticeable wing drooping.

The humerus is short, stout and pneumatic, with an extension of the clavicular air sac in its proximal end. The ulna is larger than the radius, opposite to the situation in mammals, and the secondary remiges emerge from the periosteum at the caudal border of the ulna. The distal ulna is a preferred site for intraosseous fluid administration. Two proximal carpal bones, distal carpal bones and three metacarpal bones fuse to form the carpometacarpus. There are three digits; the alula or bastard wing, the major digit (with two large phalanges), and the minor digit.

A complex of inter-related muscles, tendons and ligaments controls wing movement. These soft tissue structures are critical to flight. For example, the propatagium or skin fold between the shoulder and the elbow contains tendons of the propatagialis muscle complex,

which inserts onto the tendon of the *extensor carpi radialis* and extends the metacarpus while flexing the elbow. This muscle complex also tenses the propatagium, an important factor in controlling the angle of the wing for lift (Orosz *et al.*, 1992). The biceps and triceps brachii, on the other hand, serve a similar purpose to their mammalian counterparts in flexing and extending the elbow respectively.

## The pelvic limb

The ilium, ischium and pubis comprise the pelvis. These three bones are partially fused to each other and to the synsacrum. The pubic bones are not fused ventrally, to allow for the passage of eggs.

Movement of the femur is almost exclusively cranial and caudal; lateral rotation is limited. The tibiotarsus is formed by the fusion of the tibia and proximal tarsal bones, while the tarsometatarsus is formed by the fusion of the distal tarsal bones to the three main metatarsal bones. The hock joint is formed between the tibiotarsus and the tarsometatarsus. Limb tendons may be ossified in birds. In psittacine species, two, three, four and five phalanges are usually found in digits I, II, III and IV respectively.

## Nutrition

The diversity of dietary requirements in avian patients is far greater than that needed for canine and feline patients. Nutritional deficiencies, excesses or imbalances are commonly encountered in avian practice. Not only do veterinarians need to consider individual species' requirements, but they must also consider individual variation due to life stage, reproduction, exercise and disease conditions (Brue, 1994a).

Bird owners are often quick to blame the seed or formula when a health problem arises, but a broad knowledge of disease, husbandry and nutritional requirements is often needed to unravel problems in the context of an individual aviary situation. While some nutritional imbalances will cause specific clinical abnormalities, they are often only one aspect of a multifactorial problem. Poor nutrition

may suppress the bird's ability to resist disease, prolong recovery from illness or decrease reproductive performance.

Increased information has been forthcoming in recent years regarding the nutritional requirements of individual species, and formulated foods have improved substantially as problem areas have been identified and addressed (Schubot *et al.*, 1992). However, comprehensive data are still lacking, and manufacturers' claims may not reflect this lack of information. It is particularly important to understand that there is considerable interspecies variation in nutrient requirements. For example, finches may consume up to 30 per cent of their body weight daily and budgerigars 25 per cent, whereas poultry consume only 6 per cent. Extrapolating nutrient requirements (particularly minerals) from poultry data to other species may cause health problems. Because essential basic information is lacking, rather than trying to rely on first principles to resolve a suspected nutritional imbalance, a practical approach is empirically to change the bird to a formulated diet or supplementation regime that is considered to be successful for the particular species. If health problems continue to occur, adjustments can be made based on the history of the problems and presenting clinical abnormalities.

## Specific nutrients

### Water

Avian species that have evolved in arid regions, such as budgerigars and zebra finches, can survive several months without drinking, apparently relying on water derived from metabolic sources. However, most companion birds consume water daily and become distressed if water is withheld. Birds that are not native to an arid environment (e.g. canaries) may die if water is withheld for more than 48 hours. The addition of any compound to the drinking water that makes it unpalatable may result in dehydration and death, particularly in birds that are ill for other reasons. Bacterial contamination of water or of foods with a high moisture content ('soft foods') is also a health hazard. Water

containers should be regularly cleaned and disinfected.

## Protein and amino acids

These are needed for enzyme, hormone, muscle, bone and feather production. Both uric acid and urea are produced from protein breakdown, but uric acid is a far more prevalent by-product in avian species.

Substantial species variation occurs in protein requirements. Protein deficiency can be a

problem in insectivorous birds as these species have higher than average protein requirements, particularly when breeding. Crickets and other insects for feeding insectivorous birds should be raised on high protein and calcium gut-loading supplements. If fed on vegetable matter or bran alone, their protein and calcium content may be too low.

On the other hand, starter diets for turkeys, which are designed for rapid weight gain, contain nearly 30 per cent protein. Most granivorous species respond poorly to diets that contain 30 per cent protein. Clinical signs

**Table 1.1** Recommended nutritional allowances for granivorous companion bird diets (Brue, 1994a)

<i>Nutrient</i>	<i>Recommended allowance for maintenance</i>	<i>Good source</i>
Protein (%)	12*	Fish and meat by-products, eggs, milk, oil seeds
Fat (%)	4*	Animal and vegetable oils, oil seed, eggs, animal fat
Energy, kcal/kg	3000	Same as above
<i>Vitamins</i>		
Vitamin A (IU/kg)	5000*	Greens, carrot, fish liver oil, liver, eggs, dried milk
Vitamin D (IU/kg)	1000*	Fish liver oil, eggs, dried milk
Vitamin E (IU/kg)	20*	Vegetable oils, sunflower, safflower, wheatgerm
Vitamin K (IU/kg)	1	Green vegetables, eggs
Thiamine (ppm)	5	Yeast products, sunflower, wheatgerm, carrots
Riboflavin (ppm)	10	Yeast products, dried milk, eggs
Niacin (ppm)	75	Yeast products, sunflower, meat and fish by-products
Pyridoxine (ppm)	10	Yeast products, sunflower, eggs, wheat germ
Pantothenic acid (ppm)	15	Yeast products, sunflower, eggs, wheat germ
Biotin (ppm)	0.2	Eggs, safflower, dried milk
Folic acid (ppm)	2	Yeast products, wheat germ
Vitamin B12 (ppm)	10	Yeast products, eggs, fish and meat by-products
Choline (ppm)	1000*	Yeast products, fish and meat by-products
<i>Minerals</i>		
Calcium (%)	0.5*	Bone meal, calcium carbonate (cuttle fish, egg shell)
Phosphorus (total) (%)	0.4*	Bone meal, fish and meat products, yeast products
Sodium (%)	0.15	Salt, dried milk, fish meal
Chlorine (%)	0.15	Salt, dried milk, fish meal
Potassium (%)	0.4	Dried fruit, yeast products, wheat germ
Magnesium (ppm)	600	Yeast products, wheat germ, sunflower
Iron (ppm)	80	Bone meal, fish and meat products, yeast products
Zinc (ppm)	50	Bone meal, fish and meat products, wheat germ
Copper (ppm)	8	Yeast products, nuts, oil seeds
Iodine (ppm)	0.3	Dried whey, yeast products, eggs
Selenium (ppm)	0.1	Fish meal, yeast products, oil seeds
<i>Amino acids</i>		
Lysine (%)	0.6	Yeast products, wheat germ, fish and meat meals
Methionine (%)	0.25	Yeast products, wheat germ, fish and meat meals
Tryptophan (%)	0.12	Yeast products, wheat germ, fish and meat meals
Arginine (%)	0.6	Yeast products, wheat germ, fish and meat meals
Threonine (%)	0.4	Yeast products, wheat germ, fish and meat meals

Other amino acids are sufficient in common diets.

These allowances are general approximations only, appropriate for granivorous passerines and psittacines. Variation in requirements will occur between species and depending on life cycle, life stage and general health.

\*These nutrients should be increased in growing and breeding birds.

**Box 1.1 Clinical signs associated with protein excess or deficiency**

Excess protein intake has been associated with:

- weight loss or poor weight gain
- gout (which is also associated with high vitamin D and calcium or low vitamin A)
- aeroplane wings (lateral deviation of the metacarpals) in growing waterfowl
- leg deformities, particularly tibial rotation in ratites (also associated with low calcium)
- behavioural changes such as biting, feather picking, nervousness, rejection of food and regurgitation
- death.

Protein and amino acid deficiencies have been associated with:

- poor weight gain and loss of body weight
- poor feathering
- plumage colour changes
- stress lines on feathers
- obesity
- poor reproductive performance.

**Box 1.2 Clinical signs associated with fat and fatty acid imbalances**

Excess fats have been associated with:

- obesity
- fatty liver infiltration
- diarrhoea
- oily feather texture
- interference with the absorption of other nutrients such as calcium
- atherosclerosis – with diets high in saturated fats and cholesterol.

Fat deficiencies may result in:

- weight loss, poor growth and reduced disease resistance (if other adequate sources of energy are not provided)
- neurological abnormalities (rancid fats)
- linolenic acid deficiency has been associated with:
  - decreased metabolic efficiency
  - decreased growth
  - hepatomegaly
  - increased fat storage
  - decreased reproduction
  - poor hatchability.

associated with protein excess can occur if turkey starter rations are fed to species with lower protein requirements. As a guide, recommended nutritional allowances for granivorous companion birds are listed in Table 1.1. Clinical signs associated with protein excess or deficiency are listed in Box 1.1.

Birds will sometimes attempt to overeat to compensate for a protein deficiency. A study in budgies found that birds on a low protein seed diet increased food intake and gained weight in the form of excess body fat. Those on low protein mash lost weight, but some died with their crops packed with food (Underwood *et al.*, 1991).

## Fats and essential fatty acids

Fats are needed as an energy source. Essential fatty acids (linoleic and arachidonic) are needed for the formation of membranes and cell organelles. In mammals lipogenesis occurs mainly in adipose tissue, while in birds it predominantly occurs in the liver. Fatty liver syndromes are common in companion birds.

Birds can tolerate a wide range of fats in their diet. For example, young cockatiels grow normally if given fat levels from 1–60 per cent of the diet, but half of the birds fed 60 per cent died (Roudybush, 1986).

If fats become rancid (e.g. as with fish liver oils), essential fatty acids may be destroyed. Dietary fats that develop a foetid odour reduce amino acid availability. Activities of fat- and water-soluble vitamins may be blocked, leading to clinical signs that present as neurological abnormalities.

Clinical signs associated with fat and fatty acid imbalances are listed in Box 1.2.

## Carbohydrates

Carbohydrates provide an energy source that is readily converted into fats in the liver and *vice versa*. Glucagon, rather than insulin, is the principal director of carbohydrate metabolism in birds. High-sugar diets have been associated with clostridial infections in insectivorous birds and lorikeets. Gas fermentation in the intestines, which can be detected as abnormal

radiolucent areas on radiographs, can be associated with these infections.

Carbohydrates are the only source of energy utilizable by the nervous system, so deficiencies manifest as neurological signs. Raptors and small birds may suffer hypoglycaemia if deprived of food. Vitamin B deficiencies may exacerbate the problem, as these vitamins are involved in carbohydrate metabolism. All-meat diets are deficient in carbohydrates, B vitamins (particularly thiamine) and calcium. Birds presenting with neurological signs that have been fed an all-meat diet should be given glucose, B vitamins and calcium supplementation.

## Vitamins and minerals

General principles regarding vitamin requirements for birds are comparable to those for mammals, except that vitamin D<sub>3</sub> (cholecalciferol) is the active form rather than vitamin D<sub>2</sub> (ergocalciferol). Vitamin C is only essential in some fruit-eating species (e.g. bulbuls), but it may be useful in debilitated birds where the ability to synthesize the vitamin is reduced and the requirements are therefore higher.

Antibiotics may induce vitamin deficiencies by interfering with normal intestinal microflora. Intestinal infections such as *Giardia* may block vitamin absorption from the intestine (e.g. of vitamins E or A). Hypervitaminosis has become an increasing problem, as clients may over-supplement formulated food or multivitamin preparations, thereby causing renal failure due to hypervitaminosis D.

### **Fat-soluble vitamins**

#### *Vitamin A*

Vitamin A is needed in mucopolysaccharide biosynthesis, for the formation of normal mucous membranes and epithelial surfaces, for growth, vision, vascular development, adrenal hormone production, immune response and the formation of red and yellow pigments in feathers.

A vitamin A deficiency may cause squamous cell metaplasia of mucous membranes and deranged keratosis of epithelial surfaces. Treatment for hypovitaminosis A should initially be by parenteral administration, as intestinal absorption may be poor. Excess

#### **Box 1.3 Clinical signs of vitamin A deficiency**

- White pustules along the mouth, oesophagus, crop and nasal passages
- Caseous nodules blocking salivary glands or accumulating under the eyelids
- White caseous material, which may block the infra-orbital sinuses (especially in gallinaceous birds)
- A caseous plug, which may block the syrinx
- Polyuria/polydypsia and gout (associated with damage to ureters)
- Reduced egg and sperm production (associated with squamous cell metaplasia along the reproductive tract)
- Loss of footprint and hyperkeratosis of the plantar surface of the feet, which predisposes to pododermatitis
- Feather coloration may become muted yellow and red if these are dependent on carotenoid precursors
- Immune response may be affected, leading to increased susceptibility to disease – particularly aspergillosis.
- Xero-ophthalmia due to damage at lacrimal glands.

vitamin A (20–100 times that required) may cause weight loss, dermatitis, hepatopathy, inflammation of the nares and mouth, haemorrhaging and decreased bone strength.

Clinical signs of vitamin A deficiency are listed in Box 1.3.

#### *Vitamin D*

Ingested vitamin D precursors (e.g. ergocalciferol) are converted to the active form (Vitamin D<sub>3</sub>-1,25 dihydrocholecalciferol) through the action of sunlight on non-feathered parts of the skin or in oil from the preen gland. Vitamin D<sub>3</sub> works in concert with parathyroid hormone (PTH) to stimulate the absorption of calcium from the intestinal tract, increase calcium reabsorption in the renal tubules and increase mobilization of calcium from medullary bone.

Clinical signs of vitamin D<sub>3</sub> deficiency and of excess vitamin D<sub>3</sub> are listed in Box 1.4.

#### *Vitamin E*

Vitamin E is an antioxidant, and acts in concert with sulphur containing amino acids and selenium to prevent peroxidase damage



**Box 1.4 Clinical signs associated with Vitamin D deficiency or excess**

Deficiency, which is exacerbated by concurrent calcium deficiency, causes:

- decreased calcium absorption, hypocalcaemia, increased PTH
- demineralized soft bones, bent bones, pathological fractures
- thin-shelled and soft-shelled eggs.

Treatment should be by parenteral supplementation initially. Calcium requirements need to be addressed concurrently.

Excess Vitamin D<sub>3</sub> (4–10 times the requirement) causes:

- increased calcium absorption, increased bone resorption
- hypercalcaemia, decreased PTH
- mineralization of soft tissue
- nephrocalcinosis, polyuria.

Macaw chicks are particularly susceptible to hypervitaminosis D<sub>3</sub>. It is important not to oversupplement vitamin D.

**Box 1.5 Clinical signs associated with vitamin E deficiency**

- Poor muscle function (this may induce elevated creatinine kinase levels):
  - muscular dystrophy/spastic leg paralysis (for example in lorikeets)
  - undigested seed in droppings due to poor gizzard muscle function
  - degeneration of pipping muscle in neonates, causing poor hatchability
  - spraddle legs
  - exertional rhabdomyolysis
  - muscle twitching, localized wing paralysis (for example in cockatiels with concurrent giardiasis)
- Neurological abnormalities:
  - encephalomalacia
  - unco-ordination, abnormal body movements and torticollis
- Reproductive abnormalities:
  - testicular degeneration in males
  - infertility in hens
  - early embryonic mortality and poor hatchability
- Steatitis (in birds fed fish with a high fat content)
- Exudative diathesis (in poultry).

to cell membranes. Increased demand for vitamin E may occur with malabsorption syndromes – for example, in intestinal protozoan infections (Harrison and Harrison, 1986). Rancid fats in the diet may also increase the demand for vitamin E, as these induce higher antioxidant requirements. This has been seen in lorikeets fed with liquid formulas, inducing spastic leg paralysis (Wilson 1994), and in *Neophema* parrots fed on diets containing rancid dog food and showing neurological signs (Campbell, 1987).

Clinical signs of vitamin E deficiency vary depending on the species, age and concurrent health/nutritional problems (Box 1.5). Treatment is by parenteral supplementation and by correcting the diet or eliminating the inciting cause. Hypervitaminosis E is unlikely to be a problem, as toxic levels exceed normal requirements by 100-fold.

**Vitamin K**

Vitamin K is needed for synthesis of prothrombin and clotting factors. Intestinal bacteria are the natural source of vitamin K.

Naturally occurring deficiencies have not been demonstrated in birds, but deficiencies in poultry have been associated with sulphonamide treatment interfering with normal intestinal flora (Calnek *et al.*, 1991). Care must be taken in using warfarin derivatives to control rodents in the vicinity of aviaries as these compounds, which block the action of vitamin K, are also toxic to birds.

**Water-soluble vitamins**

Unlike fat-soluble vitamins, water-soluble vitamins can be excreted in the urine, so toxicity is much less likely to occur and, except in the case of niacin, suspected deficiencies can be addressed by supplementation with little risk of adverse side-effects. Often it is not possible to identify the precise vitamin deficiency. In such cases, multiple B vitamins are indicated.

**Thiamine (B<sub>1</sub>)**

Thiamine is needed for nerve transmission, and deficiencies are associated with loss of

appetite, opisthotonus, seizures and death. This vitamin occurs widely in plant food sources, but only at low levels. All-meat diets are deficient. Compounds with antithiamine activity include: drugs such as amprolium, which act as competitive inhibitors; enzyme-splitting thiaminases contained in raw fish; some bacteria and food preservatives; and thiamine agonists such as tannic acid (Brue, 1994b). Birds on marginal dietary levels of thiamine may show acute deficiency signs if their diets also contain antithiamine components.

Clinically, thiamine deficiency is most commonly seen in juveniles consuming all-meat diets (e.g. in hand reared baby magpies or raptors), but it will also occur with fish eating birds fed raw fish containing high thiaminase levels. In Victoria, Australia, a tragedy occurred when nearly 50 per cent of the captive breeding population of helmeted honeyeaters (*Lichenostomus melanops* var. *cassidix*), the highly endangered state bird, died showing signs of thiamine deficiency. Analysis of the diet showed marginal thiamine levels, but there was also the possibility of a thiamine agonist being present in natural foods being fed concurrently. Supplementation resolved the problem, but not before the losses had occurred.

Treatment for thiamine deficiency is urgent, and response is often dramatic. Suspected cases should be given thiamine by intramuscular injection, and the diet supplemented. Birds showing neurological signs consistent with deficiency should be given this empirical treatment even if deficiency is considered unlikely. Toxicity from overdose has not been reported and, as demonstrated with the helmeted honeyeater case, delay while trying to definitively diagnose the cause of the neurological symptoms can result in death.

#### *Riboflavin (B<sub>6</sub>)*

In cockatiels, deficiency has been associated with failure to incorporate pigment into feathers (Roudybush, 1986). In other species, deficiency has been associated with poor growth, weakness and diarrhoea, rough dry skin and curled toe paralysis (Lowensteine, 1986). Hens may show fatty infiltration of the liver and decreased egg hatchability. In chronic cases permanent nerve damage will occur, but other signs are responsive to riboflavin supplementation.

#### *Niacin, pyridoxine*

Deficiencies have not yet been described in psittaciformes, but in other species deficiency may be associated with poor growth, nervousness and neurological symptoms.

#### *Pantothenic acid, biotin*

Deficiencies of these nutrients, which are needed in the formation of critical enzymes in carbon dioxide metabolism, cause similar clinical signs, including dermatitis around the face and feet, perosis (slipping of the gastrocnemius tendon from the hock), poor growth, poor feathering and ataxia. Egg white contains avidin, a biotin antagonist, and should therefore be cooked before feeding to inactivate the avidin, or additional biotin should be provided. Egg yolk and dried milk are good sources of these nutrients (see Table 1.1).

#### *Folic acid, vitamin B<sub>12</sub> and choline*

Folic acid is needed for carbon transfer in the biosynthesis of amino acids and nucleotides. Deficiency has been associated with poor feathering, embryonic mortality, poor growth, anaemia and perosis. Foliates are widespread in grains and other common foods.

Vitamin B<sub>12</sub>, or cyanocobalamin, is involved in single carbon unit transfer, and is critical in a variety of metabolic pathways, including nucleic acid, protein, fat and carbohydrate synthesis. Its utilization is interrelated with folate and choline, so signs of deficiency parallel those of folic acid deficiency. Unlike folate, however, vitamin B<sub>12</sub> is produced by bacterial biosynthesis and must be obtained by consuming a bacterial source, animal tissues or the few plants that accumulate the vitamin. Sources include liver, muscle, peas, beans and spirulina.

Choline is required for acetylcholine, phospholipid and cartilage production, and prevents hepatic lipidosis by promoting fatty acid transport and utilization. While essential, choline is widespread and deficiencies are unlikely to be encountered. Deficiencies may be associated with poor growth and perosis in juveniles, or fatty liver infiltration in adults. Oversupplementation has been associated with mortalities and should be avoided.

## **Minerals**

### *Calcium, phosphorus and magnesium*

Calcium is essential for bone and eggshell formation, for blood coagulation and nerve and muscle function. Its absorption from the intestinal tract and deposition in bone is regulated by vitamin D<sub>3</sub> and parathyroid hormone. Calcitonin controls hypercalcaemia by decreasing calcium resorption from bone. Diets high in fats, phytate (in grain), oxylates (in spinach as well as other leafy green vegetables) and phosphates will decrease calcium absorption by forming insoluble soaps or complexes.

Secondary nutritional hyperparathyroidism (SNH) due to calcium deficiency and/or calcium/phosphorus imbalance is commonly encountered in birds. High phosphate levels will interfere with calcium absorption from the intestinal tract. The calcium to phosphorus ratio should be around 2:1, but seeds, fruit, vegetables, meat and day-old chicks or mice are extremely calcium deficient and unbalanced (e.g. corn has a 1:37 ratio, sunflower 1:7, muscle meat 1:20). Juveniles on these diets are likely to develop SNH, particularly if exacerbated by vitamin D<sub>3</sub> deficiency.

Phosphorus deficiency is unlikely to occur because it is widespread in plant food and meat diets, but much of plant phosphorus may be bound as phytate and not utilizable. Calcium deficiency may result in poor mineralization of bone, bent bones, pathological fractures, angel wing, soft-shelled eggs, leg deformities in ratites, egg binding and neurological symptoms.

Osteoporosis is a common problem in egg-laying chickens whose exercise is restricted, and it is occasionally seen in egg-laying psittacines. Affected birds may suffer paralysis due to spinal compression of the caudal thoracic vertebrae. Egg-laying birds on low calcium diets may also show muscle tetany or seizures responsive to injectable calcium.

Hypocalcaemia in African grey parrots is a clinical syndrome associated with an inability to mobilize calcium from bone in response to stress or immediate physiological demands (Plate 2). Affected birds will often present with seizure activity or show signs of ataxia. Calcium supplementation for these birds is considered a lifelong treatment course.

Birds suspected of calcium deficiency should be given immediate parenteral calcium supplementation, and the overall suitability of the diet assessed and modified as appropriate.

Magnesium serves as an activator for many enzymes involved with phosphate transfer. High levels of either calcium or phosphorus will increase magnesium requirements. Magnesium deficiency may cause poor growth, lethargy, convulsions and death, while excess may cause diarrhoea, irritability, decreased egg production and thin-shelled eggs.

### *Iron*

Iron is needed for the production of haemoglobin, which is needed for cellular respiration. While there is negligible excretion, body reserves are efficiently recycled and intestinal absorption is controlled to prevent excess accumulation. Iron deficiencies may cause hypochromic microcytic anaemia and poor feather pigmentation.

Iron storage disorders are sometimes encountered with birds on high dietary iron, but have also been seen in other cases where dietary iron levels have been low. Clinically affected birds present with liver failure, and liver biopsy shows haemochromatosis and haemosiderosis. Serum iron levels or total iron binding capacity do not correlate very well with the occurrence of the disease. Toucans and mynahs may have a genetic predisposition to the problem, and are commonly affected by this disease process.

Treatment for iron storage disease is by lowering the iron level in the diet and, if necessary, regular phlebotomy and bleeding to lower blood iron. Response to treatment may be poor, and the condition is often associated with sudden death.

### *Copper*

Copper is needed for haemoglobin synthesis and in the formation of several enzymes, including those involved in the formation of elastin and melanin synthesis. Deficiency has been associated with aortic rupture, bone fragility, poor feather pigmentation, decreased egg production and shell abnormalities.

### *Zinc*

Zinc is needed for the formation of insulin and many enzymes in the body. Deficiency

may cause hyperkeratosis and bone deformities, but this is rarely seen clinically. Zinc toxicosis is a common occurrence, as aviary birds are exposed by chewing the zinc-impregnated galvanized coating off the cage wire. Clinical signs are usually non-specific, but may include vomiting, diarrhoea, neurological abnormalities and death.

### *Selenium*

Selenium is part of an enzyme that acts as an antioxidant. It has a vitamin E sparing effect, as well as being linked with pancreatic exocrine function and the production of thyroid hormones. Deficiency may cause poor growth and feathering, impaired fat digestion and pancreatic atrophy. Excess may impair hatching success, and may be teratogenic.

### *Manganese*

Manganese is needed for chondroitin sulphate production, normal eggshell and bone formation, growth and reproduction. Deficiency may cause perosis, limb deformities, retarded growth and ataxia in poultry and waterfowl. Excess dietary calcium may interfere with uptake.

### *Iodine*

Iodine is needed for the formation of thyroxine and related compounds in the thyroid gland. Deficiency may result in goitre (commonly seen in budgerigars) and/or hypothyroidism (seen in pigeons). Gross excess iodine may also induce goitre, antagonize chloride, depress growth rates and cause CNS signs and death.

Clinical signs of goitre in budgerigars are associated with the space-occupying effect of the enlarged thyroid gland, which lies just within the thoracic inlet. Signs may include wheezing respiration, crop dilatation and vomiting or sudden death due to respiratory obstruction or aspiration of vomitus. Budgerigars suffering with goitre are considered emergency cases, and should not be stressed during examination and treatment. Initial treatment should include dilute iodine given orally or parenterally. For long-term treatment, iodine supplementation may be added to water or the bird may be supplied with iodine-supplemented food.

### *Sodium and chloride*

Salt deficiency may cause weight loss, poor egg production and cannibalism, and may be associated with self mutilation syndromes. Excessive amounts of salt may be acutely toxic, with affected birds showing intense thirst, muscle weakness and convulsions.

Sea birds have a nasal salt gland controlled by an ATPase pump. Oil contamination may suppress the pump and cause clinical signs of salt toxicity.

## **Practical nutrition**

Health problems due to deficiencies and imbalances associated with all-seed diets are commonly encountered in birds, and such diets should be avoided. In particular, oil seeds such as sunflower and safflower contain excessive levels of fat but may be deficient in vitamins A, D<sub>3</sub>, E, B<sub>12</sub> and K, riboflavin, pantothenic acid, niacin, biotin, choline, iodine, iron, copper, manganese, selenium, sodium, calcium, zinc and some amino acids (e.g. lysine and methionine).

Appropriate diets will vary between species but, if feeding seed, supplementation should be offered to address these imbalances. Spinach, silver beet and carrot are good sources of most of the deficient vitamins and minerals, but a variety of fruits and vegetables are useful to add interest to the diet. Avoid avocado, as this may be toxic to some species – particularly canaries.

A calcium source such as cuttlefish bones or calcium blocks should be available, particularly for growing or breeding birds. Grit is not essential, but studies in poultry suggest that it may increase the digestibility of feed by as much as 10 per cent in gallinaceous species. Some avian species may ingest too much grit and become impacted.

Formulated diets are useful, but not all birds will eat these foods.

## **Tips on getting birds to eat a balanced diet**

Birds often develop strong preferences for unbalanced diets, and even if they are offered appropriate nutrients they may choose

inappropriate items; for example, they may select sunflower seeds exclusively. Ideally birds should be offered a wide variety of foodstuffs from the time of weaning. Birds can be encouraged to accept a new food by:

- offering it first thing in the morning when the appetite is greatest
- mixing it with the bird's normal diet
- allowing birds to watch others eating the food
- handfeeding, if the bird is attached to a human
- only offering the new food.

Care must be taken when attempting to change a bird's diet! If the bird becomes ill, return to what the bird is willing to eat and attempt dietary change at a later date. Ketosis is a risk in birds that starve themselves (therefore breaking down body fat too rapidly) because they refuse to accept dietary change.

## Nutritional disorders

Nutritional imbalances may cause digestive and respiratory disorders; skin changes; skeletal and muscular disorders; neurological signs; reproductive disorders and general ill health or sudden death. These disorders and possible causes are listed below.

### Digestive disorders

These are treated initially by giving appropriate parenteral medication, then by addressing the underlying nutritional imbalance and/or disease condition. They include:

- 1 White plaques in the mouth or lumps around the choana or salivary ducts – associated with squamous metaplasia due to vitamin A deficiency
- 2 Partial paralysis of the muscles of mastication or other body muscles – vitamin E deficiency, associated with malabsorption due to giardiasis in cockatiels
- 3 Crop impaction
  - high fibre diets
  - foreign material ingestion
  - excess grit consumption

- in handfed babies, it can be associated cold food, a cold environment, infrequent feeding, food of an inappropriate consistency (too thick), or microwaved food that has been inappropriately mixed.

#### 4 Regurgitation

- high protein diets in cockatiels
- iodine-deficient diets (in budgerigars, where an enlarged thyroid obstructs the outlet to the crop)

#### 5 Crop liths (concretions) – in birds on marginal diets or on high protein supplementation

#### 6 Diarrhoea

- in birds fed high fat, low fibre diets of human processed food
- bacterial contamination of food may occur if feed dishes are positioned so that faecal contamination can occur

#### 7 Polyuria/polydypsia

- hypovitaminosis A
- hypocalcaemia
- excess dietary protein
- hypervitaminosis D<sub>3</sub>
- excessive salt intake
- dry seed diets
- formulated diets or a high percentage of dietary fibre

#### 8 Passing undigested food in the faeces – may be associated with vitamin E/selenium deficiency, lack of grit, excess oil in the diet or dehydration.

Polyuria alone may occur in birds fed semi-moist foods, fruit or vegetables. B vitamins, berries and some foodstuffs can alter urine colour without causing concurrent health problems.

## Respiratory disorders

Respiratory disorders associated with nutritional imbalances include:

- 1 Wheezing/squeaking respiration (partial airway obstruction)
  - iodine deficiency where enlarged thyroid glands press on the trachea (goitre)
  - vitamin A deficiency, inducing squamous cell metaplasia of the tracheal mucosa; in these cases obstruction most commonly occurs at the level of the syrinx
- 2 Airway obstruction – aspiration of feeding formula or incorrect tube feeding; such food

will lodge in the caudal thoracic and abdominal air sacs and move into the caudal lung fields.

### Skin changes

Skin changes associated with nutritional imbalances include:

- 1 Plantar corns, loss of papillae and pododermatitis – biotin and vitamin A deficiencies
- 2 Oedema of subcutaneous tissues – vitamin E and selenium deficiencies
- 3 Exfoliative dermatitis on the face and legs – biotin, pantothenic acid, riboflavin or zinc deficiencies.

### Skeletal and muscular disorders

Skeletal and muscular disorders associated with nutritional imbalances include:

- 1 Demineralized, bent bones with pathological fractures – hypovitaminosis D or deficiencies of calcium, phosphorus or manganese
- 2 ‘Aeroplane wing’ (rotation of the distal metacarpal) – high protein or low calcium in rapidly developing waterfowl
- 3 Slipped tendon of the hock (perosis) – manganese, biotin, pantothenic acid or folic acid deficiencies
- 4 Enlargement of the hock (without tendon slipping) – zinc or niacin deficiency
- 5 Spastic leg paralysis – vitamin E, calcium, chloride or riboflavin deficiencies.

### Neurological signs

Neurological signs associated with nutritional imbalances include:

- 1 Sudden collapse, fainting or seizures
  - hypoglycaemia in starved raptors and other species
  - hypocalcaemia, particularly in African grey parrots or egg-laying birds
- 2 Opisthotonus and seizures – characteristic of thiamine deficiency
- 3 Aggressiveness and nervousness – high protein diets.

Change to formulated diets is sometimes associated with decreased biting and screaming and increased activity and playfulness.

### Reproductive disorders

Many nutritional disorders may result in poor reproductive performance. Calcium, vitamin E and selenium deficiencies may be associated with egg binding.

### General ill health or sudden death

This may be caused by:

- 1 Fatty infiltration of the liver
  - high energy diets in exercise deprived birds
  - high fat diets
  - vitamin B deficiencies
- 2 Ascites – an iron storage disease which may be associated with high dietary levels of iron in susceptible birds
- 3 Gout
  - high dietary protein or calcium, hypovitaminosis D<sub>3</sub>
  - dehydration and vitamin A deficiency causing squamous metaplasia of the ureters
- 4 Arteriosclerosis – high fat and cholesterol
- 5 Aortic rupture – copper deficiency.

### Specific nutritional disorders

#### *Obesity/lipomas*

Birds gain weight if the energy content of the diet is excessive for the energy demands of normal metabolic functions and the amount of exercise. This can occur if the energy content of the food is too high or if birds overeat either to satisfy deficiencies of other essential nutrients (e.g. a protein deficiency in a seed diet) or simply for behavioural reasons. Restricted exercise will exacerbate the problem. Many (but not all) lipomas are the result of obesity and can be addressed simply by dietary and lifestyle change without the need for surgery (Plate 3).

Strategies to address obesity will vary with the individual patient and owner, but the following are general principles:

- 1 The diet should be balanced and the kilojoule intake decreased by using food of

lower kilojoule content (for example millet seed and fresh fruit and vegetables) or by restricting feeding to meal times rather than *ad lib*. Using appropriate formulated diets can make a dramatic difference in some cases.

- 2 Exercise should be increased – move the bird to a larger cage or aviary and encourage flight.

### ***Low body weight/poor growth***

This may be caused by inadequate or inappropriate food intake, infrequent feeding, progressing to an adult diet too early, loss of appetite, maldigestion or malassimilation. The underlying problem should be corrected and the bird placed on a balanced, high-energy diet. Digestive enzymes and fibre hemicellulose (Metamucil®) may be useful in increasing digestibility.

### ***Polyphagia***

Young birds suddenly introduced to new food items may overeat fibrous food or grit, causing proventricular or gizzard impactions. Vitamin E and selenium deficiencies, hepatopathies, renal dysfunction and exocrine pancreatic deficiency have also been suggested as causes of polyphagia. Feigned polyphagia, where a bird hulls seed and appears to be eating but the crop remains empty, may occur with birds that are weak or offered inappropriate food items. Faecal output and weight-gain, rather than apparent eating, should be used to determine food consumption. The underlying cause of the problem should be corrected and the bird placed on an appropriate balanced diet. Laxatives or surgery may be necessary in the case of impactions. Treatment with multivitamins or pancreatic enzymes should be considered if needed.

### ***Immune response***

Low vitamin A levels may result in a sub-optimal immune response, and have been associated with the occurrence of aspergilliosis in psittacines. Adequate levels of B vitamins (particularly pantothenic acid and ribo-

flavin) and vitamin E have been shown to improve the body's response to pathogens.

### ***Plumage abnormalities associated with nutritional imbalances***

Fault (stress) marks, which are horizontal linear defects across the vane, are associated with cortisone release at the time of feather formation, and can be caused by disrupted feeding schedules and nutritional deficiencies – particularly methionine (Plate 1).

Muted feather colours may be caused by deficiencies of carotenoids and xanthophyll pigments, which originate from plant material. These pigments are found in fat globules in the feathers, and give rise to yellow, red and orange colours.

Dark coloured feathers may become lighter in birds on tyrosine- or copper-deficient diets, as these nutrients are required for melanin formation.

### ***Blue/green/grey feather colour changes***

Blue is a structural colour, and depends on the scattering of light by the spongy layer of the feather rami rather than the occurrence of pigments. Amino acid deficiencies that alter the structure of keratin may alter blue feather coloration, but the exact nature of the deficiency has not been clarified. Green coloration is generally due to a combination of structural blue and yellow combined. A green to yellow colour change is a common occurrence in birds, and can be due to loss of structural blue coloration. Most often this is associated with liver disease, but it may also be associated with nutritional deficiencies. A blue or grey to black colour change is sometimes seen with liver disease or malnutrition, and is thought to be due to altered keratin structure in the spongy layer preventing normal light scattering; hence melanin granules (if present) absorb all wavelengths of light to give the visual effect of black (Macwhirter, 1994).

Feather picking may be initiated by dry, flaky pruritic skin, which may be associated with deficiencies of vitamin A, sulphur-containing amino acids, arginine, niacin, pantothenic acid, biotin, folic acid and salt. Fatty acid imbalance or excessive dietary fat have also been incriminated as a cause of self-mutilation, along with many other causes.

## References

- BRUE, R. N. (1994a). Nutrition. In: *Avian Medicine: Principles and Application* (B. Ritchie, G. Harrison and L. Harrison, eds), pp. 70–73. Wingers Publishing.
- BRUE, R. N. (1994b). Nutrition. In: *Avian Medicine: Principles and Application* (B. Ritchie, G. Harrison and L. Harrison, eds), p. 85. Wingers Publishing.
- CALNEK, W. B., BARNES, H. J., BEARD, C. W. *et al.* (1991). *Diseases of Poultry*, 9th edn. Iowa State University Press.
- CAMPBELL, T. W. (1987). Hypovitaminosis E: its effects on birds. In: *Proceedings of the 1st International Conference on Zoo and Avian Medicine, Hawaii*, pp. 75–78. Issued by the Association of Avian Veterinarians.
- EVANS, H. E. (1982). Anatomy of the budgerigar. In: *Diseases of Cage and Aviary Birds*, 2nd edn (M. L. Petrak, ed.), pp. 111–187. Lea & Febiger.
- HARRISON, G. L. and HARRISON, L. R. (1986). Nutritional diseases. In: *Clinical Avian Medicine and Surgery* (G. L. Harrison and L. R. Harrison, eds), pp. 397–407. W. B. Saunders.
- HAWKEY, C. M. and DENNETT, T. B. (1989). *Comparative Avian Haematology*. Iowa State University Press.
- KING, A. S. and MCLELLAND, J. (1984). *Birds – Their Structure and Function*, 2nd edn. Baillière Tindall.
- KRAUTWALD, M., TELLHELM, B., HUMMEL, G. *et al.* (1992). *Atlas of Radiographic Anatomy and Diagnosis of Cage Birds*. Paul Parey Scientific Publishers.
- LOWENSTEINE, L. J. (1986). Nutritional disorders of birds. In: *Zoo and Wild Animal Medicine* (M. Fowler, ed.), pp. 202–12. W. B. Saunders.
- MACWHIRTER, P. J. (1994). Malnutrition. In: *Avian Medicine: Principles and Application* (B. Ritchie, G. Harrison and L. Harrison, eds), pp. 842–61. Wingers Publishing.
- MCLELLAND, J. (1991). *A Color Atlas of Avian Anatomy*. W. B. Saunders.
- MYER, D. B. (1986). Sense organs. In: *Avian Physiology*, 4th edn (P. D. Sturkie, ed.), pp. 37–73. Springer-Verlag.
- GROSZ, S., ENSLEY, P. and HAYNES, C. (1992). *Avian Surgical Anatomy, Thoracic and Pelvic Limbs*. WB Saunders.
- ROUDYBUSH, T. (1986). Growth, signs of deficiency and weaning in cockatiels fed deficient diets. *Proc. Assoc. Avian Vet.*, 333–40.
- RUBELS, G. A., ISENBUGAL, E. and WOLVEKAMP, P. (1992). *Atlas of Diagnostic Radiology of Exotic Pets*. W. B. Saunders.
- SCHUBOT, R. M., CLUBB, K., CLUBB, S. *et al.* (1992). Analysis of psittacine diets fed at ABRC. In: *Psittacine Aviculture, Perspectives, Techniques and Research* (R. M. Schubot *et al.*, eds), pp. 52–9. ABRC.
- SMITH, S. A. and SMITH, B. J. (1992). *Atlas of Avian Radiographic Anatomy*. W. B. Saunders.
- UNDERWOOD, M. S., POLIN, D., O'HANDLEY, P. and WIGGERS, P. (1991). Short term energy and protein utilization in budgerigars (*Melopsittacus undulatus*) fed isocaloric diets of varying protein concentration. *Proc. Assoc. Avian Vet.*, 227–36.
- WILSON, P. (1994). Nutritional myopathy in free-living lorikeets. *Proc. Assoc. Avian Vet.*, 229–34.



# The physical examination

*Martin P. C. Lawton*

## Introduction

Although this chapter concentrates on the sick bird, it applies equally to the new bird health check or well bird examination. A veterinarian presented with an avian patient should obtain a detailed case history in order to assess the suitability of the diet and environment of the bird and an assessment of the knowledge (and suitability) of the owner. Examination of the cage, and particularly the bird's droppings, will provide much useful information. Where possible any in contact birds should also be seen and examined, as these may also provide important information. All birds should be handled and subjected to a full and thorough physical examination. This physical examination should be undertaken in a systematic fashion so as not to miss any organ system. As part of the examination, it may be necessary to obtain additional samples for laboratory investigation.

All birds can be considered as being in one of three groups:

- 1 **Birds showing signs of clinical disease.** This may be associated with infectious agents, parasites, diet (obesity, inanition or deficiencies), metabolic or reproductive abnormalities, neoplasia, trauma, behavioural traits, toxicity or improper care.
- 2 **Birds that are showing no signs of clinical disease but have a subclinical condition.** This may involve the incubation period of an infectious agent, which, although subclinical, may eventually result in clinical signs. There are also many infectious agents that could cause the bird to be a carrier, although never showing clinical signs or having made a full recovery from the clinical condition. Then there are the many conditions that require a prolonged length

of exposure before clinical signs are noted (such as dietary deficiencies or toxicities).

- 3 **Birds that are free of clinical disease and subclinical conditions and are, in essence, healthy.**

It is only following the physical examination and further investigations that the group into which a bird falls can be established.

## Considerations prior to avian examination

### Timing of consultation

Avian cases, with the exception of those for routine procedures such as nail clipping or wing trimming, should not be examined during a normal small animal clinic. Most birds will view a dog, cat or bird of prey as a predator, thereby increasing the stress of the visit. The avian consultation generally requires more time than the average small animal case. Attempting to deal with any case when rushed will probably not do the veterinarian or the bird justice. In view of the extra time required, a realistic practice policy should be sought on charging for such visits. Although most pet bird owners are prepared to pay for a thorough examination and comprehensive therapy, there is a tendency for the keepers of small cage-birds to believe that they are doing the veterinarian a favour by bringing the bird in, and to resent any form of charge at all! The quoting of realistic fees in advance (especially for possible diagnostic tests) is strongly recommended, as this can avoid many misunderstandings.

The receptionist should be trained to assess correctly the urgency of any case and to be able to advise the client on travelling and the samples (of food and droppings) required. A sick bird should always be considered as serious and urgent, as opposed to a budgerigar needing its nails clipped or a chronic feather plucker. The receptionist booking an appointment should always make a note of the species and a brief description of the problem(s) so that the veterinarian is forewarned and may, if necessary, do some basic reading on the species and the condition before the visit.

## Handling and transportation

A veterinary surgeon who wishes to gain experience with birds should consider approaching a professional breeder, handler or keeper of the various families. These specialists are usually only too happy to encourage further avian interest and knowledge. This is time well spent, and allows the opportunity to learn the important aspects of handling, feeding and restraining, as well as the finer points of aviculture. Owners vary in their ability to handle their birds. Falconers are usually very competent, whereas psittacine owners may think they can handle their bird (i.e. it sits on their hand/shoulder/head) but they are often incapable of restraining it for a thorough examination or to give medication. As such they are not only no help to the veterinarian but are often a hindrance, despite having great expectations of the professional.

Psittacine owners are often reluctant to be involved in the direct medication or treatment of their birds. This is because of the excellent memory of psittacines, and the fear that they will bear a grudge against any persons who they feel have invaded their privacy, caught them or in any way inflicted pain upon them. If the owner is present at the time a bird is restrained, that bird may well consider the owner responsible. For this reason, owners should be offered the opportunity to leave the room prior to handling, examination, medicating etc.

A caged bird must be caught and removed from its cage before being examined. It is advisable for the inexperienced veterinarian to be forewarned of the species before the

consultation, and to read-up on their weaknesses and any dangers of handling (such as beak- or talon-orientated). Diurnal species are best approached or handled in a darkened room or in a dull room with only a blue or red light. Avian clinicians must have access to a darkened room. Before any bird is handled, all windows and doors must be shut and extractor fans turned off. No member of staff should open the door unannounced; having 'peep hole' devices fitted into the doors is an advantage. All equipment for restraint and treatment should be prepared and available prior to attempting to catch the bird. A cloth or paper towel is the best form of protection when catching a bird; gloves are of little value, as they are too thick to feel or manipulate through and yet often not strong enough to give true protection. In view of the risk of disease transmission, a towel or cloth should only be used for handling one bird before being disinfected and washed thoroughly.

Where possible, depending on species, the bird should be transported to the clinic in its normal cage. If this is not possible, then the owner should be encouraged to bring photographs to allow visual assessment of the environment (see below). Most owners and breeders will have photographs and be delighted to bring these. The cage should not have been cleaned out prior to the visit, and should be wrapped with a cloth in order to darken the environment, reduce stress and prevent drafts. If the bird is to be brought to the practice in a container other than the cage, then this should be suitable. For all species it should be escape-proof and unlikely to cause damage during transportation. Cardboard boxes are seldom suitable, as larger birds may be able to 'eat' through them, and trying to capture a small bird from a cardboard box is likely to lead to an escape and embarrassment as a veterinarian chases a bird around the consultation room. A small fishing net in each consultation room is advised to help the capture of any escapees.

## Examination of the cage

### *Environment*

Before the routine physical examination, wherever possible, the cage should be assessed for suitability, the size and types of

perches used, and the appropriateness of food and water containers. A great deal of information can be obtained from thorough examination of the bird's cage and its contents. This allows an assessment of the level of hygiene, the knowledge of the owner, diet, and water availability. The food in bowls (or scattered on the floor of the cage) also helps to confirm the owner's description of the diet offered. Many owners believe the bird's diet is exactly what they give the bird rather than just what the bird eats. There is a clear distinction, as many birds are selective feeders even when given what appears to be a perfectly adequate diet, and this can often be established by what is on the bottom of the cage.

Unsuitable toys may cause trauma, gastrointestinal obstruction or even toxicosis. If the cage is custom-made bear in mind the possibility of 'new cage' disease, which is associated with zinc toxicity and is more likely to occur when galvanized wire has been used. Most countries will also have their own legislation about cage sizes, usually with regard to wing span.

### ***Droppings***

Many important aspects of the bird's health can be assessed from a thorough inspection of the droppings. Smaller birds defecate more frequently (budgerigars 25–50 times per day compared with macaws 8–15 times per day; Harrison and Ritchie, 1994). The substrate may often affect the appearance of the droppings, although this can be overcome by placing an impervious sheet in the cage under the bird for a 3–4 hour period. Droppings are comprised of three portions:

- 1 Faeces
- 2 Urates (white to creamy white)
- 3 Urine (clear and watery).

### ***Faeces***

The faeces should be formed and uniform in character, without any obvious blood or undigested food. The colour, volume and consistency of the faeces will vary with species and, more importantly, with dietary content and composition. Other factors, such as age, reproductive status, state of health, stress and medication, will all have an influence. It is important to be able to recognize normal avian faeces, taking into account all these variables.

Only when recognition of all the normal states has been mastered can the aetiological interpretation of abnormalities be made. One of the most difficult issues is to establish true diarrhoea. Loose faeces may be true diarrhoea or may be associated with other problems as it is mixed with any excess urine in the cloaca or after being void. It is common for the faecal component to be loose or almost absent at times of stress, such as travelling to a veterinarian or after medication.

The colour of faeces can vary for many reasons, particularly the type of food eaten. Dark discoloration may be indicative of melanaemia or associated with certain food stains (e.g. blackberries). The evidence of blood is always important, and can signify gastrointestinal disease (enteritis, neoplasia etc.), renal disease, testicular or ovarian tumours, coagulopathies, cloacal papilloma, calculus, cloacitis or other cloacal pathology, oviduct abnormalities (pre- or post-laying), liver disease, heavy metal toxicity or malnutrition. Acute haemorrhagic syndrome should be considered in Amazon species. If the faeces are clay-coloured, this may indicate maldigestion or malabsorption. Kaolin medication or a barium meal, however, may also cause this appearance.

Assessment of faecal volume is the most useful indicator of the state of health:

- 1 Reduced faecal volume usually indicates a decreased food intake, a decreased gastrointestinal transit time or food deprivation. This should be distinguished from small dry faeces, which are usually associated with water deprivation or liver disease.
- 2 Voluminous faeces can be normal and occur in situations where there is a high vegetable or fluid content in the diet. However, any cause of malabsorption (e.g. gastrointestinal disease, pancreatitis, parasitism, peritonitis, diabetes, renal disease or neoplasia, or liver disease) can also cause an increase in bulk. However the presence of any undigested food (to be differentiated from regurgitation) is always abnormal and is an indication for further investigation and confirmation of malabsorption, maldigestion, hypermotility (due to inflammation, infection or parasitism), pancreatitis, proventriculitis or ventriculitis psittacine proventricular dilatation syndrome (PPDS).

At every opportunity a faecal sample should be examined under a microscope:

- a wet preparation should be examined for motile protozoa, fluke, etc.
- a flotation technique may be used for the identification of parasite ova
- a Gram's stained sample should be examined for bacteria, fungi and anti-inflammatory cells.

Faecal samples are seldom worth culturing, however, where there is true diarrhoea; a Gram's stain yields an assessment of the number of bacteria and whether there are predominantly Gram-positive or Gram-negative organisms.

Faecal samples can also be tested for evidence of chlamydial shedding and this should be undertaken for all sick birds.

#### *Urates*

These can vary from white to creamy in colour. Green or yellow/brown urates indicate the increased presence of pigments such as biliverdin, and this always indicates abnormalities such as haemolysis or hepatitis caused by malnutrition, toxic damage, or chlamydial, bacterial or viral infections. A green urate, no matter how lightly pigmented, is an indication for further investigation as to the cause and extent of the hepatopathy. The absence of urates may indicate, among other things, renal or liver disease.

#### *Urine*

It is normal for a small amount of urine to be produced as part of each dropping. The amount that is passed is extremely variable. The abundance of a watery component may be indicative of many problems, including psychogenic drinking, renal disease, hepatic disease or diabetes mellitus (especially common in cockatiels). Abundance of urine can also be noted in a stressed bird, such as one that has travelled to the surgery and is being examined. Markedly excessive urine should always be investigated further to confirm if the cause is physiological or pathological, and whether it is a primary or secondary polyurea. Primary polyurea may be indicative of renal failure, which can be associated with infection, neoplasia, immune-mediated complexes (such as can occur with chronic chlamydiosis) or toxic damage. Secondary

polyurea is associated with any cause of polydipsia, for example: diabetes mellitus or insipidus; pituitary disease or neoplasia; adrenal disorders or neoplasia; hyperthyroidism; iatrogenic causes (e.g. corticosteroids, aminoglycosides, progestergens); hyper- or hypocalcaemia; vitamin A deficiency; excess dietary protein; hypervitaminosis D<sub>3</sub>; or excess dietary salt.

Urine should always be examined on an impervious surface as soon as possible after voiding. It should be tested for pH, glucose, sediment, ketones, colour and specific gravity using a standard dip stick test.

## Clinical history

As in all species, obtaining a detailed clinical history is essential and its importance cannot be overstressed. Any time employed in questioning the owner and obtaining vital information is well spent, and may save much time later. The history may be backed up or disputed by the following physical examination. The clinician should establish how long the owner has had the bird and if it was imported or captive bred. The origin of the bird and any contact with others has a bearing on possible diseases and allows elimination of others. The site where the bird is being kept also influences possible diseases; an outdoor aviary bird may harbour parasites while those bred and kept entirely indoors are less likely to do so.

For all newly acquired sick birds it is important to establish the origin and, where possible, any history. These birds may have been mixed with many others at the place of origin or purchase. Many young parrots (including cockatiels) are advertised as SHRT (soppy, hand-reared, tame); these command a higher price and are often more acceptable solo cage birds, however they are also more demanding pets. Some of these birds are intensively reared, not always on the site of breeding; this may also carry a higher risk of disease, especially from conditions such as polyomavirus, psittacine beak and feather disease or PPDS. Veterinarians should always suspect that these birds might have been carrying a subclinical disease that has now become overt.

Although imported parrots in particular are less common than they were, they do still occur within the European community and in North America. Infectious diseases associated with imported birds must therefore be considered, such as Pacheco's disease, chlamydiosis or salmonellosis.

A different approach is required for ill birds from an established collection. By inquiring into the basic husbandry, it is possible to assess how good the breeder's management is – especially in relation to hygiene, quarantine of imported birds and isolation of newly purchased birds. It is important to establish how recently the present bird had contact with other new arrivals or existing birds on the premises. When dealing with a collection, a very full diagnostic work-up (including post-mortem examinations) should always be carried out. It is imperative to discover immediately whether the condition is infectious. The bird and any in-contacts should be isolated. If an infection of unknown aetiology is suspected, it may be prudent to suggest a cull of a sick bird for post-mortem examination and sampling. This facilitates a more rapid complete diagnosis.

Clientele that have one pet bird commonly utilize veterinary services if the animal becomes ill. These patients have often been owned by the same family for a considerable period, and have rarely come in contact with other birds. However, it is still useful to establish if there are or have been other birds in the household, if they have had full or partial contact, and when the last bird was brought into the home. Single birds are more likely to be affected by malnutrition or chronic diseases, although it should be remembered that some psittacine diseases can be transmitted readily by fomites (including human clothing, etc.) – e.g. Pacheco's disease and chlamydiosis. It is also important to consider any diseases that can remain dormant or involve the carrier state on the differential list, e.g. chlamydiosis, psittacine beak and feather disease (PBFD) or polyomavirus.

Full details of the diet and any supplementation that is given to the bird may provide essential information. It is important to establish if there have been any recent changes to the diet and, wherever possible, the food should be inspected (even if it is a proprietary diet). A whole-seed diet (mainly

sunflower seeds) is still the most common diet for medium to large parrots. Sunflower seeds do not provide a balanced diet, and the feeding of these will lead to 'seed junkies' that will not eat other items even if offered. A solely seed diet, unless well supplemented, will lead to range of problems such as calcium deficiency, vitamin A deficiency and obesity associated with the high oil diet. For the smaller cage birds, the use of cheap or 'loose' seed may result in iodine deficiencies. There are now many balanced proprietary diets available and owners should be encouraged to use these, although correct storage and expiry dates have to be observed. If abnormal titbits are offered, such as alcohol or chocolate, these could result in illness or fatality.

## Physical examination

The thought of a physical examination of any bird may fill both the owner and the veterinarian with dread. Although it is possible for a small bird to die in the hand, this should really only occur with an extremely sick or respiratory distressed bird. The most common reason for a bird to die during handling by an inexperienced veterinarian is the method of restraint, which results in the inability of the bird to move its keel and thus prevents adequate respiration. Avoid chasing a bird (especially if sick) around a cage prior to handling. The use of a darkened room or one with subdued lighting, as previously suggested, will reduce the flight of a bird to the minimum and aid in its capture.

Before embarking on a full clinical examination, the veterinarian should first consider if any of the serious infectious diseases or zoonosis are possible differential diagnoses. Consulting or examination areas should be easily cleaned, and fomites (including towels for handling) that might spread disease should be discarded after each case. Particular caution should be taken when chlamydiosis is a possibility, bearing in mind the potential for airborne spread and zoonotic implications. Any bird showing signs of ocular or nasal discharge, respiratory distress, a fluffed up miserable appearance, bright green faeces or green discoloration of the urates should be considered as a potential case of chlamydiosis, and should be screened prior to further

examination, handling or mixing with other birds. A history of long-term isolation from other birds should not be relied upon to exclude possible chlamydiosis. It is also possible that humans can pass chlamydiosis to parrots as well as *vice versa*. There are a number of rapid faecal in-house test kits that can be used for screening. All positives, or even cases that are negative but with suspicious clinical signs, should have faecal samples sent for PCR examination.

Prior to the physical examination, it is important to note the bird's attitude and demeanour, conformation and contour, the condition of the feathers, beak, cere and feet, the appearance of the eye (round and bright or ovoid and slit-like) and the rate, depth and nature of breathing. These observations should be undertaken over several minutes, thus allowing the bird to settle down and establish a normal state; all these parameters are affected by handling.

The owner often asks the age of the bird, but this is one of the most difficult things to assess in most cases – especially when the bird is fully fledged. For some psittacine birds, the eyes may be a different colour in young birds than adults (i.e. blue in African grey parrots) or the cere may be very pale (budgerigars). There is often a closed ring band on the leg of raptors and psittacines that should have the year of hatch and other details, such as breeder's initials. The dates and details on a closed ring are reliable, as the ring is slipped over the foot within a few days of hatching and the bird quickly grows into it so that it cannot thereafter be removed (or replaced) without cutting the ring or the leg. Dates on split rings or cable ties are not reliable, as they can be placed at any time or even moved from one bird to another.

There is no secret to the successful examination, recognition and diagnosis of diseases or injury in birds. Once the bird is restrained, the clinical examination should be carried out in exactly the same way as with a cat or dog. A methodical approach must be employed, starting with the head and working down the body. Once the clinician is experienced at examining birds, it should take no more than 3–4 minutes. All parts of the body should, where relevant, be symmetrical; one side should always be compared with the other.

## The head

The eyes, sinuses and rhinarium are all anatomically inter-related, hence infection of any one may lead to or be indicative of infection in all three. The eyes should be clear, round, centrally placed, moist and shining, with no epiphora or ocular discharge or caking around the eyelids. There should be evidence of normal tear production. An abnormal tear film could indicate xerophthalmia associated with hypovitaminosis A. There should be no evidence of periocular or periorbital swellings. Swelling medial to the eye may be associated with a primary sinusitis; swellings above or below the eye are usually associated with hypovitaminosis A and sterile inspissated material associated with squamous cell metaplasia of the lacrimal glandular epithelial tissues. Any swelling should be investigated further by taking swabs, a needle biopsy or flushings to submit for cytology, bacteriology or histopathology. A routine examination with an ophthalmoscope should disclose abnormalities of the lens or the cornea; however, assessment of fundic lesions requires more experience.

The nares should be clear and open, with a centrally placed shiny operculum. The shape does vary with the species being examined, and in some it may not be possible to visualize the operculum. Discharge, occlusion or rhinoliths may be present (chlamydiosis is always a differential diagnosis). Any rhinoliths should be removed for a further examination of the nares and the taking of samples, if considered necessary. Any abnormal discharge from the nostrils warrants further sampling for cytology and culture and sensitivity as required. The cere, where present, should show no sign of trauma or excessive scaling as occurs with *Cnemidoptes* spp. infestation in budgerigars.

The beak, although there is much variation between families, should be healthy and shiny. In cockatoos there should be evidence of a white powder down, as excessively shiny beaks may be an indication of lack of down feathers and possibly an early suggestion of psittacine beak and feather disease. The maxillary and mandibular portions of the beak should meet evenly. The beak should then be examined for signs of excessive growth or abnormal wear. Cracks in the keratin may be

indicative of nutritional deficiencies. Abnormal positioning (malocclusion) of the beak is commonly associated with incorrect diet early in growth, and may require surgical intervention or lifelong trimming. Aspergillosis and candidiasis of the beak are not uncommon, frequently secondary to vitamin A deficiency.

The beak should then be opened and the mouth examined. The oral cavity is easiest examined with the assistance of an auroscope operculum or paper clip gag (Plate 4). All areas of the mouth, especially the tongue, sublingual tissues, choana, oral membrane and glottis, should be visualized. In cases of hypovitaminosis A, there may be abscesses on the tongue or between the mandibles; this is particularly common in psittacines. The choana should be clear with no sign of inflammation or discharge. If there is a discharge, samples should be taken for further cytological and microbiological investigation. In pigeons and raptors, any caseous material should be examined as a wet preparation under a microscope to rule out trichomoniasis.

Birds' ears have no pinnae but consist of an auricular opening and aural canal situated ventro-caudal to the lateral canthus. The auricular openings should be assessed for signs of inflammation or discharge. Clinical problems are usually polyps, neoplasia or infections.

At this time, the feathers on the rest of the head should also be examined and assessed (Figure 2.1). Abnormalities of the head feathers in a bird with body feather abnormalities indicate it is not a behavioural problem, and suggests that further investigation should be undertaken. In budgerigars, the presence of



**Figure 2.1** Feather abnormalities in a cockatoo.

large amounts of unsheathed pinfeathers could indicate a very sick bird that is not grooming itself.

## The neck

The neck should be examined systematically and always palpated, especially on the right side, for any abnormal swellings, the presence of fluid or reduced emptying of the crop (in birds where this is present). The oesophagus should be palpated and the mucosal thickness assessed. In cases of doubt, the overlying skin can be wetted with surgical spirit and, if necessary, transilluminated; alternatively, endoscopy can be performed. If on palpation regurgitation occurs, this should be examined as a wet preparation microscopically for the presence of protozoa. Trichomonads are particularly common in budgerigars. If no protozoa are revealed, a Gram's-stained slide should be examined for evidence of megabacteriosis.

## The wings and limbs

The wings should be stretched out to assess mobility, and should be of even length. There should be no drooping at rest. If there is any drooping then radiographs must be taken to assess the shoulder joint, clavicular, coracoid and scapula bones. The feathers should be examined for signs of damage or loss. The carpal areas should be free of trauma or swelling. Any white or yellowish swelling of the wing joints should be treated as suspected gout, and appropriate blood samples obtained to assess the uric acid, calcium and phosphorus levels.

The keel musculature should then be assessed, as this is an indication of body condition. Different species will normally have varying degrees of pectoral covering over their sternum (keel). The clinician should be familiar with expected degrees of pectoral mass for the species being examined. Loss of condition will give some indication of the severity and chronicity of the process. All patients should be routinely weighed and recorded at each consultation, as this provides base line data for that individual (Figure 2.2). In obese birds the keel bone will not be easily felt and the skin may assume a yellowish



**Figure 2.2** All birds should be routinely weighed and measured at each consultation.

tinge, which is associated with subcutaneous fat deposition or, in extreme cases, xanthomata. In birds with a very prominent keel, this could be an indication of poor condition or underlying disease. Due to the presence of the feathers, it is often possible for a bird to lose substantial weight without this change becoming obvious to the owner. All birds should be scanned at this time to assess if a microchip is present.

The limbs should then be examined, and particular attention paid to the joints of the digits so that lesions consistent with articular gout may then be noticed. There should be no sign of self-mutilation or pain on extension or flexion of the limbs. Any abnormalities or swellings require radiographic evaluation and further investigation. The plantar aspect of the foot should be examined for signs of bumblefoot, calluses or excessive wear. Raptors, waterfowl and cockatiels appear to be particularly prone to bumblefoot associated with incorrect environment or perches. Any rings present should be noted and checked to ensure that they are freely movable on the leg and there is no build up of keratin under the ring that could eventually lead to constriction of the blood supply.

## The body

The abdomen should then be palpated for signs of abnormalities or swellings (especially in females). If there is a swelling of the abdomen, it should be established if this is fluid or a solid mass. If there is fluid, then

aspiration and examination of the fluid is indicated. Any other abnormalities should be investigated using radiography or endoscopy.

Examination of the cloaca can often reveal signs not evident on examination of the faeces. Chronic soiling of the vent plumage may be caused by cloacitis, cloacal uroliths, cloacal papillomata, diarrhoea, polydipsia, etc. Following gentle eversion, the cloacal mucosa can be examined for signs of papillomata. *Per cloacum* digital examinations may also be useful, especially in larger birds, for palpation of the kidneys. Endoscopy may be useful for the further investigation.

Prior to turning the bird over, the pectoral and abdominal areas should be auscultated with a stethoscope. Auscultation is relatively unrewarding in avian patients. Very few sounds are heard over the abdominal area, unless there is an air sacculitis. The heart can also be assessed, although the rapid heart rate usually makes it difficult to distinguish murmurs unless they are severe. The heart is better assessed by an electrocardiogram (ECG) (100 mm/sec paper speed is required) or heart monitor, should the clinical history or physical examination indicate a possible cardiovascular problem.

On turning the bird over, the lungs should be further evaluated by placing the stethoscope diaphragm between the wings; this is usually the best area for listening to the lungs. The lung field of birds is small and fixed compared to that of mammals. It is often possible to hear a faint short inspiratory noise in the normal bird. If other noises are heard they are likely to be associated with diseases of the nares or sinuses, restricted airflow in the trachea (e.g. syringeal aspergilloma) or severe air sac disease (always suspect chlamydiosis or aspergillosis). Upper respiratory disease should be clinically differentiable from air sac disease. If the latter is suspected, radiography and endoscopy are indicated. If air sacculitis is present and endoscopy is performed, an air sac swab or biopsy should be taken for bacteriology, histopathology, cytology or ELISA. Any bird showing respiratory signs should always be screened for chlamydiosis.

The back and tail base should then be examined. The gland is present and well-developed in most species, but is absent in some others (e.g. Amazons). In species with a



urophygial gland, this should be examined by parting the feathers. The uropygial gland, otherwise known as the preen gland, is situated on the rostral body wall, immediately anterior to the insertion of the central tail feathers. The gland is responsible for producing the oil used during preening to assist with feather condition and waterproofing. When present, the gland should be symmetrical and smooth, and it should be possible to express a small volume of oily secretion. Birds can suffer from dysfunction, abscessation or neoplasia of the gland.

### Plumage and skin

Throughout the whole of the physical examination, the condition of the feathers and skin should be assessed for any signs of abnormality or loss. The condition of the plumage and skin may give clues as to the overall health of the bird or if there is evidence of underlying disease such as PBF, hepatopathy or nutritional deficiencies (essential amino acids or vitamin A). Feathers vary at different sites of the body. Over the head, trunk and limbs they are known as general feathers, while those found over the wings and tail are flight feathers. A basic understanding of a normal feather is required in order to assess any abnormal feathers. All feathers emerge from the skin as a calamus or quill. The shaft (or rachis) is the main body of the feather; fine branches (barbs) arise from the shaft at 45° on either side and from these barbs smaller branches (barbules) arise at an angle of 45°. Flight feather barbules are locked together by small hooks, resulting in a flat, firm feather. If the barbules are not locked together, then the feather appears as a 'fluffy' feather. Down powder is produced by disintegration of the tips of the powder down feathers. This powder helps to make the rest of the feathers waterproof, and also helps to lubricate them. At the time of examination, check for the presence of new growing (pin) feathers. If they are present, then it is unlikely that a hormonal disturbance is the cause of any feather loss. New growing feathers show that the normal feather growth cycle is active following feather loss or moults.

Feather loss is one of the most common reasons for bringing pet birds (especially

psittacines) to the veterinary surgeon. At the time of examination it should be established whether the feather loss is throughout the body or located to certain areas. The areas that are showing signs of feather loss must be carefully examined for signs of damage or deformity to the remaining feathers. Signs of trauma to the feathers or the skin are often associated with neurosis and self-inflicted mutilation. Deformation of feathers, however, can be associated with viral infection or nutritional problems. Where there is damage to the skin, this should be assessed to determine whether it is self-inflicted or due to parasitic or infectious causes (see later). In behavioural feather plucking, the head is likely to show normal feathering while the rest of the body shows varying degrees of feather loss or damage (Figure 2.3).

If there is generalized feather loss with deformed feathers in psittacine birds (especially cockatoos), which also involves the head, the papovavirus associated with psittacine feather and beak disease (PFB) should be suspected. Diagnosis is by a PCR test on a



Figure 2.3 Feather plucking in an African grey parrot.

blood sample, examination of a biopsy specimen or electron microscopy of a plucked feather (some epithelial tissue should still be attached to the feather follicle to allow examination of macrophages for the viral intranuclear inclusion bodies).

Owners often consider parasites to be the cause of any feather loss. In single pet birds, which have not had recent contact with other birds, this is an unlikely possibility. Where parasites are suspected, it is a good idea to use some form of magnification to examine the bird's skin and feathers. Only on finding a parasite (or the type of pathology associated with a particular parasite) can a diagnosis of parasitism be made. The parasite *Cnemidocoptis piliæ* produces classic hyperkeratosis of the skin and excessive scaliness, usually around the beak and eyes or legs and feet, and results in a substantial feather loss. While *C. piliæ* is the most common species of *Cnemidocoptis* found, passerines may be infested with *Cnemidocoptes mutans* or *Cnemidocoptes jamaicensis*, and *C. laevis* is the depluming mite of parrots (especially macaws). Other parasites that may be found include the quill mites (*Csyringophilus bipectinatus* and *Dermoglyphys elongatus*), which destroy feathers early in development. These may also cause dermal cysts. The mites are easily seen, as they are quite large and deposit their eggs along the feather shaft.

The red mite (*Dermanyssus gallinae*) is not usually found on the bird during the physical examination, as it only feeds at night. During the day the mite lives within the cage in recesses or even under droppings. Diagnosis during the day requires very careful examination of the cage. Nocturnal examination of the bird may demonstrate the mite, but is not normally appreciated by the veterinarian! Even without seeing the mite, there are often signs of pruritus and restlessness in the bird.

Whenever there are any noted abnormalities of the skin, biopsy samples can be helpful. They should always be full thickness and include one or two feather follicles. Although routine H&E staining, and light-microscopic examination is helpful, electron microscopy is invaluable for diagnosing viral causes. Bacterial skin infection or folliculitis is less common; however, it can be diagnosed on examination of biopsy specimens or a Gram's stain of the feather pulp.

Dermatophytes (mainly *Microsporum gallinae*) may also be encountered in fowl (Galliformes), ducks (Anseriformes), pigeons (Columbiformes) and turkeys (Galliformes), but are very rare. Lesions are limited to fleshy or thin-skinned areas of the head, and are seen as scabs, crust or alopecia. *Candida albicans* can cause similar lesions. Microsurgical examination of skin scrapings gives a definitive diagnosis.

## Basic requirements for the avian practice

In order to deal with avian cases in the most appropriate manner, there are a number of items required that may not be routinely used in small animal practice. Some of these may already be available if the practice currently deals with other exotics, and some investigations may involve the use of equipment already used for dogs and cats (such as radiography and an in-house laboratory or access to an outside lab that can provide fast but accurate results and interpretations). Although it is advantageous in an avian practice to have endoscopes, radiographic restraining devices, radiotherapy, operating microscopes, ophthalmic surgical instruments and nebulizers, to name but a few, these are not included here because they are not considered 'basic'.

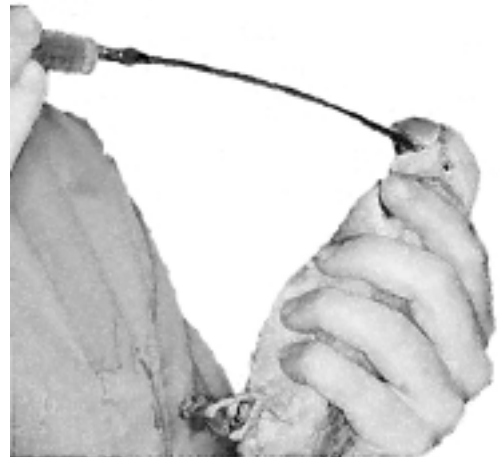Those items required to practice avian medicine at an acceptable basic standard include:

- 1 *Towels*. There should be a ready supply of towels for the examination and handling of birds. A new, clean towel should be used for each bird to prevent the possibility of disease spread. It is acceptable to keep a towel (provided it remains clean) for an individual bird if it is to be hospitalized.
- 2 *Digital scales*. These should be of various ranges and sensitivity. The standard platform scales used for dogs and cats are not accurate enough for smaller patients. Scales should have an accuracy of 1 g for weight ranges up to 100 g, and 2–5 g for weight ranges up to 500 g. An accuracy of 5–10 g may be acceptable for body weights

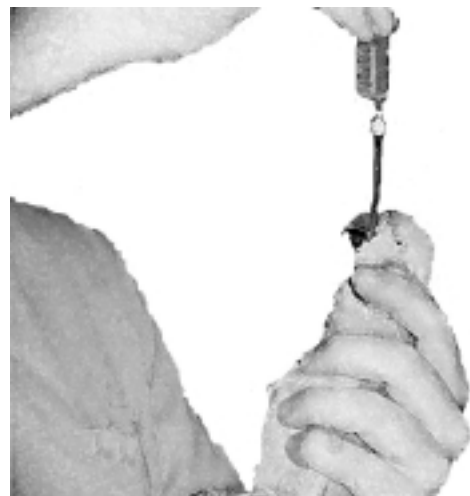over 500 g. These scales are required in order to record accurate weights of all avian patients. This is not only essential for accurate dosing with medicaments or injectable anaesthetics, but also enables weight loss or gain to be monitored. All hospitalized patients should be weighed at least once a day to establish if they are eating and indicate any requirement for supplementary feeding or fluid therapy. It is also necessary to have some means to support the bird whilst it is being weighed. Hand-reared psittacines may be placed directly onto the platform of the scales. However, for many others a small cage, bag or perch is required. Ideally all the scales should have the ability to be zeroed on placement of the reciprocal, and maintain this 'memory' when removed. If this facility is not available, then the weight of the container should be written on for ease of working out the weight of the bird. The weight of a bird should never be guessed, as inaccuracy could lead to under- or overdosing – often with dire consequences.

- 3 *Insulin syringes or other low-dose syringes.* These should allow small but accurate doses of drugs to be administered, based on the calculations made using the correct weight of the birds. The needle used should also be the smallest available that allows administration, to reduce the trauma involved in the injection process.
- 4 *Paediatric blood tubes and swabs.* It is inappropriate to place small blood samples in standard mammalian blood tubes, as the amount of anticoagulant is calculated for a set volume. There are now many suppliers of tubes designed to take 0.5 ml or less, and these should be used at every opportunity. Where it is necessary to take swabs from small areas the use of paediatric or nasopharyngeal swabs is advised, as the head of the swab is smaller than that of a standard bacteriological swab and allows more accurate sampling.
- 5 *Cages.* These are essential for the confinement of birds, especially during periods of hospitalization. Although many clinical patients will be brought in their own cage, sometimes birds will be brought in a box or cage unsuitable except for travelling, either because the owner ignored the

advice of your receptionist or because the cage was just too big to bring to the surgery. It is therefore a requirement that caging is available for the hospitalization of avian patients. Although not a basic requirement, it is advantageous to have a cage that can be used for nebulization of any bird with respiratory disease.



**Figure 2.4** Demonstration of holding (usually through a towel, which is not shown for clarification) and introduction of a curved metal crop tube into the side of a parakeet's mouth.



**Figure 2.5** Demonstration of crop tube placed into the crop of a parakeet.

- 6 *Nets.* Any veterinary practice intending to see avian patients should have a net suitable for the species likely to be encountered. This may mean that several sizes are required. There will be occasions when avian patients escape from the cage and must be caught, and there is nothing more embarrassing and time consuming than chasing a bird around a consulting room, with the owner losing faith in proportion to the length of time that it takes to catch the bird. The availability of a suitable net will greatly help in recapturing the escaped patient, and also substantially reduce the chances of injury associated with the capture process. Although there are many specialized avian nets available, there are also many cheaper fishing nets that will do the job equally well.
- 7 *Heat.* An appropriate supply of additional heat is frequently required for the sick bird. All birds have a higher metabolism than mammals of the same body weight, and this increased metabolism means that there is a greater risk of chilling, especially in the sick bird. Suitable heating sources may range from the dedicated hospital cages with built-in heating and thermostats to an infrared heat lamp pointed at a cage. Where an external heat source without a thermostat is used it is important to prevent overheating, which can also be very stressful to the patient.
- 8 *Crop tubes.* These may be purpose purchased or practice prepared. For many avian species it is advantageous to use a metal crop tube to reduce the risk of cutting through plastic tubing and thus avoid the need to retrieve part of the tube from the oesophagus or crop – or worse still, surgical retrieval. The technique of crop tubing is easy (Figures 2.4, 2.5), and is invaluable in the treatment of avian patients.
- 9 *Spinal needles.* The suggestion that spinal needles should be considered a ‘basic’ requirement may at first seem strange; however, these are essential for the provision of intraosseous fluid therapy. No veterinary practice should consider it is ready for avian patients unless it is also prepared to deal with the dehydrated or moribund case. Although it is possible to use standard hypodermic needles, they will frequently be blocked with osseous material associated with the placement and therefore require repeated ‘stabs’ or will completely prevent establishment of a patent intraosseous route.
- 10 *Microscope.* Access to a microscope is essential to allow the investigation and diagnosis of many avian conditions. It is not acceptable solely to use an outside laboratory, as the assessment of protozoal infections (including trichomonads), for example, requires evaluation of a fresh wet preparation. Whenever a bird passes a faecal sample this should be evaluated (as mentioned above) by performing a direct smear (looking for evidence of parasites) and a Gram’s stain.
- 11 *A library and access to further information.* All practices should have a basic in-house library. It is important to remember that some textbooks considered ‘small animal’ (such as the Kirk’s *Current Veterinary Therapy* series) may often contain useful chapters or information on avian conditions. It is not essential for every practice to have all the avian textbooks or publications, but it is vital to know how to obtain further information. All veterinary practices should have the ability to perform a basic literature search (this may include access to the Internet or a subscription service via a veterinary library). It is also of utmost importance that staff should be aware of where to refer cases that are beyond their expertise or unresponsive to treatment. Very few veterinarians lose clients by referring early or at an appropriate time – unlike those that do not refer or leave it too late.
- 12 *Isoflurane.* This is an essential basic requirement for safe avian anaesthesia (see later).
- 13 *Trained staff.* Although it is accepted that almost all veterinary practices have trained nurses/technicians, these staff may not be experienced in the handling, care and treatment of avian patients. Any practice that intends to hospitalize and treat avian patients should ensure that staff are trained in the basics of handling, administering medication (including fluid therapy) and the nutritional requirements of the common species.

## Basic anaesthesia

Isoflurane has made anaesthesia of birds a safe and uneventful procedure. Rosskopf and Woerpel (1996) consider that if veterinary surgeons are unwilling to invest in isoflurane and the necessary equipment to use it, they should refer cases for surgery to a practice that is properly equipped. The unique avian anatomy and physiology should be understood, as these affect anaesthesia and (should the need arise) the emergency procedures necessary for resuscitation. The aims of anaesthesia should be to provide a smooth, reliable induction with adequate restraint, muscle relaxation and analgesia, followed by a fast, full, uneventful recovery (Lawton, 1996a, 1996b).

There are a number of other volatile anaesthetic agents that have been used for the induction and maintenance of birds. Possible alternatives to isoflurane are methoxyflurane and halothane. The lack of availability of methoxyflurane and the requirement for a dedicated vaporizer, together with disadvantage of the hangover effect (50 per cent being metabolized), has virtually removed its use from avian practice. Halothane, although available in most veterinary practices, has a lower safety margin (3.0) than isoflurane (5.7) and is contraindicated in birds with underlying hepatopathies (a common finding), as well as being more depressive on respiration and of lower analgesic potential than isoflurane.

The main advantages of isoflurane are two-fold:

- 1 The low blood gas partition coefficient (1.4 at 37°C) means that there is a low solubility of isoflurane in blood and tissues, which leads to a rapid induction and recovery due to less retention following tissue distribution
- 2 The low metabolism (0.3 per cent) speeds up the elimination of isoflurane from the body solely by expiration and without the production of potentially toxic metabolite products that can cause a hangover effect.

## Induction and maintenance

The use of a dedicated vaporizer is recommended for all volatile anaesthetics to allow an exact concentration to be given, immaterial of temperature or air pressure, within certain

ranges. It is not possible to use the same vaporizer for both halothane and isoflurane due to the differences in these volatile fluids, unless the vaporizer is cleaned and recalibrated prior to each change.

Isoflurane allows a relatively easy method of induction by face mask (Figure 2.6) (other than for diving birds), reducing many of the complications of handling and injecting and the stresses that are involved with these procedures. Face masks can be purchased or self-made from disposable items such as syringe cases (for small birds) or soft drink bottles (for macaws or long-beaked birds). The advantage of using disposable face masks is the elimination of the risk of spread of infection between birds; they also often provide a more suitable mask for an avian patient than those currently on the market. If the face mask is not a disposable item, then it is important that it is cleaned well before re-using. A face mask does have disadvantages, especially if examining or operating around the head.

Once induced, it is possible to maintain anaesthesia just with a face mask, although endotracheal intubation should be considered for anything other than the shortest procedure. Intubation of birds is easy, due to the forward placement of the glottis behind the base of the tongue. With the mouth held open and, in the case of psittacines, the tongue gently pulled forward, a suitably sized tube can be introduced through the glottis. Various sized endotracheal tubes can be produced using cut down urinary or intravenous cannulae or catheters, although small diameter tubes may become blocked with respiratory



**Figure 2.6** Demonstration of restraint and mask induction with isoflurane.

secretions. Once intubated, a bird should be maintained on a Bethune or Ayre's T-piece system.

An endotracheal tube is likely to restrict access when operating around the beak, head or face. When there is an obstruction, such as that seen with a syringeal foreign body or aspergillic granulomata, intubation may not be adequate for ventilation and maintenance of anaesthesia. In both these situations, the air sac system may be utilized to maintain oxygenation and anaesthesia. The site for placement of an air sac tube is one of preference, but is usually similar to the site chosen for endoscopic examination. Traditionally this is the left side just behind the ribs, although Sinn (1994) has suggested the insertion of short endotracheal tubes or rubber tubes into the clavicular or caudal thoracic air sacs. The placement of the air sac tube is usually performed after induction by face mask or injection of a suitable anaesthetic agent, although in cases of severe airway obstruction it is possible to place the tube in a physically restrained conscious bird. The placement of the tube in a conscious bird is quick and appears to cause little discomfort or distress; the bird may be restrained with its head in a mask into which 100 per cent oxygen is being delivered (Lawton, 1996b). As large a tube as possible (French gauge 14) should be placed and attached to the anaesthetic circuit.

Intermittent positive pressure ventilation (IPPV) via the placed air sac tube or endotracheal tube has a lot of advantages (Figure 2.7). Birds with air sac intubation will usually stop breathing spontaneously due to the expulsion of all carbon dioxide from the respiratory system (Korbel *et al.*, 1993). IPPV for any anaesthetized bird allows not only control of the rate and depth of respiration, but also control of oxygenation and the prevention of hypercapnoea. The gaseous flow rate should be a minimum of three times the normal minute volume, i.e. approximately 3 ml/g bodyweight (a 400 g Amazon parrot needs 1.2 l/min), although the author uses 2–3 l/min irrespective of size. Ventilated birds will not breathe again spontaneously until after perfusion via the air sac is terminated and the blood carbon dioxide levels rise. The tube can be removed postoperatively, or left *in situ* in cases of dyspnoea (e.g. after surgery to the neck or in cases of aspergillosis plugs of the syrinx).

### Alternative injectable anaesthetic agents

Despite the ease and safety of isoflurane anaesthesia, there are occasions when an injectable agent is needed. Such occasions include induction of diving birds, lack of gaseous anaesthetic equipment (such as in

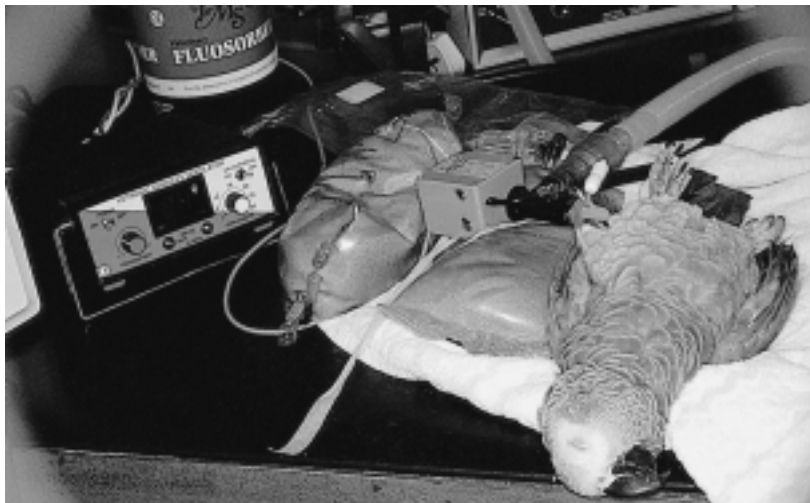

Figure 2.7 Air sac intubation.

**Table 2.1** Injectable anaesthetic agents

<i>Agent</i>	<i>Dose and route</i>	<i>Comments on use</i>
Alphaxalone/alphadalone	5–10 mg/kg i.v.; 36 mg/kg i.m. or i.p.	A wide safety margin but only a short length of action. Following i.v. administration there is often a transient apnoea
Ketamine	18–50 mg/kg s.c., i.m. or i.v.	Ketamine, historically, was the drug of choice; it is now used less often in avian practice, although it is useful for reducing stress when handling larger species such as swans or other waterfowl. A good sedative but a poor anaesthetic with poor muscle relaxation and little analgesia, although there is little respiratory or cardiovascular depression. There is often wing flapping during recovery, even when used in combination with tranquilizers
Ketamine/diazepam or midazolam	Ketamine 10–30 mg/kg i.v. and diazepam 1–1.5 mg/kg i.m. or 0.2 mg/kg midazolam s.c., i.m.	This combination allows a smooth induction and recovery when compared to ketamine by itself
Ketamine/medetomidine	1.5–2 mg/kg ketamine + 60–85 µg/kg medetomidine i.m. (reversed by atipamezole 250–380 µg/kg i.m.)	Sedative and analgesic properties, with good muscle relaxation but no arrhythmias or respiratory depression. This combination is particularly good in waterfowl
Ketamine/xylazine	4.4 mg/kg ketamine + 2.2 mg/kg xylazine i.v. (reversed by yohimbine 0.1 mg). (Atipamezole 250–380 µg/kg i.m. can be used to reverse the effects of xylazine)	Synergistic action of the combination produces a smooth induction and improved muscle relaxation, without difficulties in recovery due to residual ketamine effect. Unreversed, there is a prolonged recovery and post-operative depression
Propofol	1.33–14 mg/kg i.v.	Very high safety margin and easily metabolized. A very smoother rapid induction; good muscle relaxation with a short duration of 2–7 minutes
Tiletamine/zolazepam	5–10 mg/kg i.m.	Tiletamine is more potent than ketamine. Good immobilization
Xylazine	1–20 mg/kg i.m. or i.v. (reversed with yohimbine hydrochloride, 0.1–0.2 mg/kg i.v. or atipamezole 250–380 µg/kg i.m.)	By itself, is unreliable, causes bradycardia and A/V block, and is extremely respiratory depressant

the field), and excitability or aggression on handling for face mask induction. In all cases where an injectable agent is to be used, the bird should be accurately weighed. Without an accurate weight it is not possible to calculate an accurate dose, and the possibility of an overdose and even a fatality could occur. Suitable injectable agents are listed in Table 2.1.

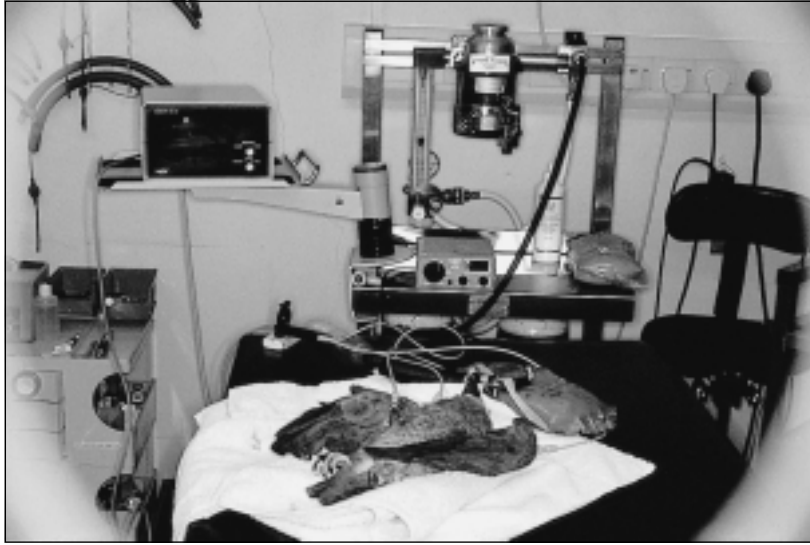## Anaesthesia monitoring

Despite the safety of isoflurane, there is no excuse for complacency over monitoring during anaesthesia (Lawton, 1993). The depth of

anaesthesia may only be correctly controlled if the bird is carefully and continuously monitored. Monitoring of birds should be approached in exactly the same way as monitoring of any other mammalian species, although it is considered to be more challenging (Flammer, 1989).

In any anaesthetized bird, the following should be monitored:

- 1 *Reflexes*. The best reflexes to monitor are the palpebral, corneal, cere, toe pinch and wing twitch reflexes. As the bird becomes more deeply anaesthetized, the standard reflexes usually slow and decrease in strength or eventually disappear.



**Figure 2.8** African Grey Parrot maintained and monitored under general anaesthesia.

- 2 *Circulatory volume.* Birds are thought to be better able to tolerate blood loss than mammals (Heard, 1997), although haemorrhage is still a problem. The amount of blood loss during surgery should be carefully monitored, if necessary by measuring swabs, and fluid therapy or even a blood transfusion should be considered. In an emergency situation pigeon blood can be used for most species, although there are always risks involved in this procedure – not least from viral infections.
- 3 *Heart rate.* Cardiac monitor use is recommended, although an oesophageal stethoscope can be of use (Lawton, 1993). The standard lead placements are over the distal lateral tarsometatarsus and the carpal joints of each wing (Figure 2.8), using atraumatic clamps or silver needles. As an aid to the assessment of pain, the heart rate is dramatically effective. It is not uncommon for a cockatiel, on feeling pain, to increase its heart rate from 300 bpm to over 700 bpm (Lawton, 1996a). The heart rate should never fall below 120 bpm (Doolen and Jackson, 1991).
- 4 *Respiration.* Electronic monitoring of respiration is considered the best indicator of the depth and stability of anaesthesia in the absence of response to pain. However, the majority of respiratory monitors work on thermal changes between inspired and

expired gases, and this can lead to difficulty in measurement in small birds – especially when the flow rates of the cold carrier gases are high. The pattern of respiration is also important; it should be stable and continually monitored during anaesthesia (Lawton, 1993). A sudden change in pattern, especially in the depth of respiration (from shallow to deep), may indicate that the bird's plane of anaesthesia is lightening or the bird is feeling pain. Depending on the bird's body size, the respiratory rate should not fall below 25–50 breaths per minute (Doolen and Jackson, 1991); below this there is a risk of hypercapnoea. Pulse oximeters with a cloacal probe are useful for assess the oxygenation of the blood and also the rate of respiration.

- 5 *Temperature.* Warmth should be provided before induction, during anaesthesia, and in the recovery period. Sick or anaesthetized birds may not be able to maintain their core body temperature adequately, and sick birds attempting to maintain their high core temperature may become hypoglycaemic due to hypothermia. Hypothermia can cause peripheral vasoconstriction, bradycardia, hypotension and, when severe, ventricular fibrillation (Heard, 1997). The core body temperature of birds is usually between 40 and 44°C (Carter-Storm, 1988), with that of



smaller birds being 41°C (Cooper, 1989). Anaesthetized birds should be placed on a towel or an insulated 'Vet-bed'; the use of heating pads or lights can also help to reduce heat loss, but care must be taken to prevent overheating or burns. Bubble wrap or space blankets can also be used for wrapping most of the bird to prevent unnecessary heat loss. Cold anaesthetic gases will also have a chilling effect on the bird, but there is little that can be done to prevent this other than keeping the overall length of anaesthesia to the shortest possible.

## References

- CARTER-STORM, A. (1988). Special considerations for general anaesthesia of birds. *Clin. Insight*, **2**(3), 61–62.
- COOPER, J. E. (1989). Anaesthesia of exotic species. In: *Manual of Anaesthesia for Small Animal Practice*, 3rd edn (A. D. R. Hilbery, A. E. Waterman and G. J. Brouwer, eds), pp. 182–191. BSAVA.
- DOOLEN, M. D. and JACKSON, L. (1991). Anaesthesia in caged birds. *Iowa State Uni. Vet.*, **53**(2), 76.
- FLAMMER, K. (1989). Update on avian anaesthesia. In: *Current Veterinary Therapy X* (R. W. Kirk and J. D. Bonagura, eds), pp. 776–779. W.B. Saunders.
- HARRISON, G. J. and RITCHIE, B. W. (1994). Making distinctions in the physical examination. In: *Avian Medicine: Principles and Application* (B. W. Ritchie, G. J. Harrison and L. R. Harrison, eds), pp. 144–175. Wingers.
- HEARD, D. J. (1977). Anaesthesia and analgesia. In: *Avian Medicine and Surgery* (R. B. Altman, S. L. Clubb, G. M. Dorrestein and K. Quesenberry, eds), pp. 807–828. W.B. Saunders, Philadelphia.
- KORBEL, R., MILOVANOVIC, A., ERHARDT, W. *et al.* (1993). Aerosaccular perfusion with isoflurane – an anaesthetic procedure for head surgery in birds. In: *Proceedings of the European Conference of the Association of Avian Veterinarians*, pp. 9–42. AAV.
- LAWTON, M. P. C. (1993). Monitoring the anaesthetized bird. In: *Proceedings of the European Conference of the Association of Avian Veterinarians*, 1–8. AAV.
- LAWTON, M. P. C. (1996a). *Anesthesiae*. In: *Manual of Psittacine Birds* (P. H. Beynon, N. A. Forbes and M. P. C. Lawton, eds), pp. 49–59. BSAVA.
- LAWTON, M. P. C. (1996b). *Anesthesiae*. In: *Manual of Raptors, Pigeons and Waterfowl* (P. H. Beynon, N. A. Forbes and N. Harcourt-Brown, eds), pp. 79–88. BSAVA.
- ROSSKOPF, W. J. and WOERPEL, R. W. (1996). *Practical Anesthesia Administration. Disease of Cage and Aviary Birds*, 3rd edn. Williams & Wilkins.
- SINN, L. C. (1994). Anesthesiology. In: *Avian Medicine: Principles and Applications* (B. W. Ritchie, G. J. Harrison and L. R. Harrison, eds), pp. 1066–1080. Wingers.
- BENYON, P. H., FORBES, N. A. and LAWTON, M. P. C. (1996). *Manual of Psittacine Birds*. British Small Animal Veterinary Association.
- BOEVER, W. J. and WRIGHT, W. (1975). Use of ketamine for restraint and anaesthesia of birds. *Vet. Med./Small Animal Clin.*, **70**, 86.
- BORZIO, F. (1973). Ketamine hydrochloride as an anesthetic for wildfowl. *Vet. Med./Small Animal Clin.*, **35**, 1364.
- BURR, E. W. (1987). *Companion Bird Medicine*. Iowa State University Press.
- COLES, B. H. (1985). *Avian Medicine and Surgery*. Blackwell Scientific Publications.
- COLES, B. H. (1997). *Avian Medicine and Surgery*, 2nd edn. Blackwell Science Ltd.
- COOPER, J. E. and FRANK, L. G. (1973). The use of the steroid anaesthetic CT 1341 in birds. *Vet. Record*, **92**, 474.
- DEGERNES, L. A., KREEGER, T. J., MANDSAGER, R. and REDIG, P. T. (1988). Ketamine-xylazine anaesthesia in red-tailed hawks with antagonism by yohimbine. *J. Wildlife Dis.*, **24**(2), 322.
- DOHOO, S. E. (1990). Isoflurane as an inhalational anaesthetic agent in clinical practice. *Can. Vet. J.*, **31**, 847.
- ENSLEY, P. (1979). Cage bird medicine and husbandry. *Vet. Clin. North Am., Small Animal Pract.*, **9**(3), 391.
- FITZGERALD, G. and BLAIS, D. (1993). Inhalation anaesthesia in birds of prey. In: *Raptor Biomedicine* (P. T. Redig, J. E. Cooper, J. D. Remple *et al.*, eds), pp. 128–135. Chiron Publications.
- FREED, D. and BAKER, B. (1989). Antagonism of xylazine hydrochloride sedation in raptors by yohimbine hydrochloride. *J. Wildlife Dis.*, **25**(1), 136.
- HARCOURT-BROWN, N. H. (1978). Avian anaesthesia in general practice. *J. Small Animal Pract.*, **19**, 573.
- HARRISON, G. J. (1984). Caged bird medicine. *Vet. Clin. North Am.*, **14**(2).
- KING, A. S. and MCLELLAND, J. (1975). *Outline of Avian Anatomy*. Baillière Tindall.
- KREEGER, T. J., DEGERNES L. A., KREEGER, J. S. and REDIG, P. T. (1993). Immobilization of raptors with tiletamine and zolazepam (Telazol). In: *Raptor Biomedicine* (P. T. Redig, J. E. Cooper, J. D. Remple *et al.*, eds), pp. 141–144. Chiron Publications.
- LAWTON, M. P. C. (1984). Avian anaesthesia. *Vet. Record.*, **115**(3), 71.
- LAWTON, M. P. C. (1997). Anaesthesia. In: *Proceedings of the European Association of Avian Veterinarians Conference, Core Session, London*, pp. 30–37. AAV.
- MANDELKER, L. (1972). Ketamine hydrochloride as an anaesthetic for parakeets. *Vet. Med./Small Animal Clin.*, **67**, 55.
- MANDELKER, L. (1987). Anaesthesia and surgery. In: *Companion Bird Medicine* (E. W. Burr, ed.), pp. 148–154. Iowa State University Press.
- MANDELKER, L. (1988). Avian anaesthesia, part II: injectable agents. *Comp. Animal Pract.*, **2**(10), 21.
- PETRUZZI, V., CODA, S., XIMENES, L. A. and NAITANA, P. (1988). L'associazione ketamina-xilazina nell'anestesia generale dei rapaci. *Valutazione di alcuni parametri vitali. Documenti Veterinari*, **6**, 59–62.
- REDIG, P. T. and DUKE, G. E. (1976). Intravenously administered ketamine HCl and diazepam for anaesthesia of raptors. *J. Am. Vet. Med. Assoc.*, **169**(9), 886.
- RITCHIE, B. W., HARRISON, G. J. and HARRISON, L. R. (1994). *Avian Medicine: Principles and Applications*. Wingers.
- ROSSKOPF, W. J. and WOERPEL, R. W. (1996). *Diseases of Cage and Aviary Birds*. Williams & Wilkins.
- ROSSKOPF, W. J., WOERPEL, R. W., REED, S. *et al.* (1992). Part 1: Anaesthetic agents: anaesthesia administration for pet birds. *Vet. Pract. Staff*, **4**(2), 34.

## Further reading

- BAUCK, L. (1990). Analgesics in avian medicine. In: *Proceeding of the Association of Avian Veterinarians Annual Conference*, pp. 239–244. AAV.
- BAUCK, L. (1993). *A Practitioner's Guide to Avian Medicine*. American Animal Hospital Association.

# Clinical tests

---

*Don J. Harris*

## Introduction

Clinical pathology holds the key to unravelling much of the mystery surrounding the sick avian patient. Although many avian diseases present with identical clinical signs, laboratory data can often distinguish between infectious and metabolic diseases, bacterial vs. fungal, renal vs. hepatic, etc. As this is a handbook, the focus of this chapter is to guide the practitioner in the practical organization of diagnostic protocols. In a specified clinical situation, selection of the appropriate laboratory tests will most directly reveal the nature of the patient's problem. Minimal attention will be paid to the materials, methods, biochemistry and physiology behind the tests themselves, except where it serves to clarify the test's usefulness.

## Overview

For the sake of organization, laboratory tests can be divided into several basic groups:

- 1 Indicators of immune system activity – the complete blood count (CBC) and electrophoresis (EPH)
- 2 Serum biochemistries – indicate the condition or function of various organ systems
- 3 Serology – tests for antibodies to various diseases
- 4 Antigen detection tests – tests for the antigens specific to infectious agents
- 5 Microbiology – methods of propagating and identifying infectious agents
- 6 Miscellaneous – randomly utilized tests such as urinalysis, heavy metals, cytology, etc.

It is advisable for individuals attempting to formulate a diagnostic protocol always to

begin the laboratory profile with general indicators of immune or organ system functions, then to progress toward specific tests for suspect aetiologies.

## Complete blood count

The complete blood count (CBC) is one of the most important components of an avian diagnostic panel. Perhaps no other single test provides as much information regarding the health of the avian patient. For analytical purposes the CBC may be divided into components describing: the volume and character of the red blood cells; the numbers, percentages, and characteristics of the white blood cells; the concentration of solids in the plasma; the relative number of thrombocytes; and the presence or absence of blood-borne parasites. While many other tests provide information not demonstrated by the CBC, no other single test provides such a broad range of information. Differences exist between avian and mammalian blood but, once these differences are recognized, the similarity in functions of the various components becomes evident.

The primary differences between mammalian and avian blood are that:

- normal mature avian red blood cells are nucleated, and regenerative anaemia is therefore demonstrated by polychromasia among the red cells in a stained smear
- white blood cell types parallel mammalian cells except that instead of neutrophils, birds possess heterophils
- platelets are replaced in avian blood by thrombocytes.

Unlike dogs and cats, total cell counts of birds may vary widely among members of a given species. To determine normal total cell count

values for an individual, baseline data must be collected during periods of apparent good health. Reference values for various species have been published, but these tables should only be used as rough guidelines. Published ranges will typically be wide, therefore subtle patient variations may not be apparent.

Beyond these differences, the functions of the various cellular components in avian blood are roughly comparable to those of mammals. Infections, non-infectious inflammation, necrosis, neoplasia, etc. may cause a leucocytosis. A moderate heterophilia often indicates the presence of infections or cellular necrosis, and an extremely high heterophil counts often accompany chlamydiosis, aspergillosis or tuberculosis. These changes are usually characterized by varying degrees of toxic changes in the white cells. Subtle-to-moderate heterophilias, without toxic changes in the white cells, may reflect stress leucograms.

An overwhelming bacterial infection or a severe viral infection may result in a leucopenia with a heteropenia or occasionally a lymphopenia. The leucopenia may be due to decreased production or increased consumption of the cell line. Increased consumption is evidenced by the presence of immature and toxic cells, findings not present with decreased production.

In some avian species the relative lymphocyte count may be higher than in others. An absolute lymphocytosis suggests a viral infection or certain stages of chlamydiosis. Certain leucaemias may produce an elevation of a particular line of lymphocytes.

A lymphopenia may occur in severe viral infections, such as avian circovirus in young African grey parrots.

A monocytosis implies the presence of granulomatous disease or extensive necrosis in which a large amount of phagocytosis is necessary. Classic examples of this include chronic inflammatory diseases such as aspergillosis, tuberculosis, and chlamydiosis.

Eosinophil functions have not been clearly defined. Intestinal parasitism may produce an eosinophilia, but not consistently. Peripheral eosinophilia does not appear to occur in allergic conditions.

Basophils are uncommon findings in normal avian haemograms. Conditions that cause their appearance include respiratory infec-

tions, resolution of tissue damage, parasitism and some chlamydial infections.

## **Electrophoresis (EPH, SPE)**

The fractionation of serum proteins via serum electrophoresis is analogous to the separation and identification of white blood cells in the differential cell count. Just as different families of white cells are separately quantitated, so the relative percentages of the serum proteins are measured. It should be realized that the technique of performing an electrophoresis does not provide absolute values of each protein extracted; rather, it reveals the percentage of each as part of total protein. The absolute values must be calculated after the total protein has been determined through some other method. This then yields information regarding a variety of physiological and immunological states of the patient. The primary categorization of avian serum proteins includes pre-albumin, albumin and globulin fractions, and each is further subdivided as discussed below.

One aspect of protein determinations that should always be considered is the albumin:globulin (A:G) ratio. More important than the patient's total serum protein are the relative quantities of pre-albumin, albumin and globulin. The ratio is calculated using the formula  $(\text{pre-albumin} + \text{albumin}) / \text{globulins}$ , and the normal A:G ratio ranges from 1.6–4.5. The importance of this ratio is illustrated by the following example. Patient A and Patient B have total serum proteins of 4.0; therefore, at first glance, there appears to be no abnormality in either patient's value. If, however, Patient A's A:G ratio is 3.5 while Patient B's is 0.14, it is apparent that Patient B's serum albumin level is very low while his or her globulins are very high – indicating a serious condition. Patient B is losing or failing to manufacture albumin, while at the same time some portion of the globulins is being produced at an accelerated rate.

## **Pre-albumin and albumin fractions**

The significance of the pre-albumin fraction of the serum protein in birds is unknown. It may function as a transport protein, similar to albumin. There does not appear to be a

comparable component in mammalian blood. In avian samples it may comprise as much as 40 per cent of the total serum protein. In some species, it appears that low pre-albumin values may have the same significance as low albumin values in other species.

The albumin fraction typically comprises 45–70 per cent of avian serum protein in species that have high pre-albumin values, and tends to be lower in species with low pre-albumin values. Albumin functions primarily as an osmotic pressure regulator and a transport protein, as it does in mammalian species.

## Globulin fraction

The globulin fraction has alpha ( $\alpha$ ), beta ( $\beta$ ) and gamma ( $\gamma$ ) subdivisions, and high-resolution electrophoresis will divide the globulins into the protein components listed under the  $\alpha$ ,  $\beta$  and  $\gamma$  subgroups discussed below. Each of the three primary globulin fractions contains proteins active in different pathophysiological conditions.

### Alpha globulins

Alpha globulins consist of two principal fractions;  $\alpha_1$  and  $\alpha_2$ . Contained within this group of globulins are acute phase inflammatory proteins such as  $\alpha$ -lipoprotein,  $\alpha_1$ -antitrypsin,  $\alpha_2$ -macroglobin and haptoglobin. The  $\alpha_2$ -macroglobin sometimes migrates into the  $\beta$  range. The main condition associated with elevated  $\alpha$  globulin levels in birds is parasitism.

### Beta globulins

Beta globulins constitute other acute phase inflammatory proteins, including  $\beta_2$ -macroglobulin, fibronectin, transferrin and  $\beta$ -lipoprotein. In some species, namely the African grey parrot, the  $\beta$  component of the EPH consists of two primary components;  $\beta_1$  and  $\beta_2$ . Elevated globulin levels suggest liver or kidney disease, or chronic inflammatory diseases such as aspergillosis or chlamydiosis.

### Gamma globulins

In mammals,  $\gamma$  globulins appear as two primary fractions;  $\gamma_1$  and  $\gamma_2$ . In avian species, only one fraction is demonstrated. The

primary protein components of the  $\gamma$  globulins are the antibodies, complement and complement degradation products. Elevated  $\gamma$  globulins are a common finding in birds suffering from acute *Chlamydia psittaci* infection.

## Serum biochemistries

### Alanine aminotransferase (ALT, SGPT)

Alanine aminotransferase is an enzyme found in the cells of many avian tissues. In other animals elevations have been shown to be associated with hepatocellular disruption, but no such association has been consistently demonstrated in birds. Little clinical significance can therefore be applied to ALT values in avian patients.

### Albumin

The function of albumin is discussed above. It should be noted here that an accurate albumin determination can only be calculated through electrophoresis. Currently utilized dry chemistry assays do not provide accurate avian dry chemistry albumin measurement.

### Amylase

In birds, the pancreas, liver and small intestine produce amylase. Elevations have been associated principally with acute pancreatitis and, to a lesser extent, enteritis. Because more than one source of amylase exists, an elevation is not in itself diagnostic. Some investigators question the usefulness of amylase in avian diagnostics because of its lack of specificity.

### Alkaline phosphatase (AP, SAP)

Alkaline phosphatase is found in bone, kidneys, intestine and liver. The hepatic fraction composes only a very small proportion of the total reported in routine testing. Because changes in the hepatic fraction have little and inconsistent influence on the overall value, no correlation can be made between liver disease and AP levels. The inconsistent elevations from variable sources cause AP to be of almost no value in avian diagnostics. Disruption of bone probably causes elevations of AP more than other sources.

**Aspartate aminotransferase (AST, SGOT)**

The intracellular enzyme most useful for diagnosing hepatocellular disruption in avian species is aspartate aminotransferase. Although present in liver, skeletal muscle, kidney, heart and brain, elevations are frequently associated with liver disease or muscle damage. When an elevation in AST is detected, a creatinine kinase (CK) level should be measured. An elevated AST without a concurrent elevation in CK is highly suggestive of hepatocellular disruption. It should be emphasized that this does not confirm liver disease; nor does a normal AST positively rule out liver disease. As with all diagnostics, the AST lends evidence towards a diagnosis but does not in itself determine the diagnosis. Also, the AST in no way indicates the functional capacity of the liver. The bile acids test is more appropriately used to evaluate hepatic function.

**Bicarbonate**

Measurement of bicarbonate levels provides an indication of the patient's acid-base status. Increases in bicarbonate imply alkalosis, while decreases imply acidosis.

**Bile acids**

Bile acids are produced by the liver to aid in the digestion of fats. After excretion into the intestinal tract, bile acids are reabsorbed and returned to the liver via the portal circulation. The liver then extracts the bile acids from the blood and recycles them. The amount not extracted is therefore inversely proportional to liver function. Elevation of bile acids in the general circulation implies decreased ability of the liver to extract the bile acids from the portal circulation.

Confusion arises when it is noted that the liver is the organ of bile acid synthesis. It would seem logical that hepatic insufficiency would result in decreased production of bile acids, and therefore in decreased circulating levels. However, hepatic extraction of bile acids from the portal circulation is apparently more dependent on efficient liver function than is the synthesis of bile acids. It is reasonable to presume (and it does appear to happen) that at some point the production of

bile acids does diminish and values fall. As with aspartate aminotransferase, a normal bile acid level does not absolutely rule out hepatic disease.

It is important to distinguish between the information provided by the AST and bile acids. Aspartate aminotransferase is a leakage enzyme, and therefore an indicator of hepatocellular integrity, while bile acids are indicators of liver function. One is not necessarily dependent on the other. For example, a patient may exhibit a normal AST but elevated bile acids. This would imply impaired liver function, even though the cells were intact, and such conditions include hepatic lipidosis, chronic fibrosis, etc. Conversely, many diseases such as salmonellosis or acute chlamydiosis may cause hepatocellular damage without impairing overall liver function. Marked elevations in the AST may be observed without concurrent elevations in bile acids. Again, normal values of either or both do not rule out hepatic disease. A totally fibrotic end-stage liver lacks enough functional hepatocytes to produce measurable AST or bile acids.

**Bilirubin**

Since biliverdin is the major avian bile pigment, bilirubin is uncommonly observed in avian serum samples. In occasional cases of severe liver disease, significant bilirubin levels are present; therefore, hepatic pathology may be suspected in patients demonstrating elevated bilirubin levels.

**Calcium**

Calcium levels are profoundly influenced by a number of non-pathological as well as pathological conditions, and great care should be exercised in the interpretation of abnormal findings. Almost all pathological changes are secondary to conditions not associated with dietary levels. Because of the effectiveness of the parathyroid gland, dietary deficiencies of calcium will rarely cause subnormal blood levels. Blood calcium levels are also directly linked to albumin levels. Hypoalbuminaemia will result in artifactual depression of measured calcium levels, as will sample transport in certain anticoagulants. Other causes of

lowered blood calcium levels include hypoparathyroidism in African grey parrots, and glucocorticoid administration.

Dehydration will sometimes elevate albumin, and therefore blood calcium. Two-fold or greater elevations typically occur with ovulation. Elevated levels of calcium have been associated with vitamin D<sub>3</sub> toxicity, osteolytic bone tumours, renal adenocarcinoma and dehydration.

### ***Cholesterol***

Cholesterol levels in birds may accompany various physiological or pathological conditions, but there is inconsistency and a lack of specificity associated with abnormal findings. Generally, elevations are associated with liver disease, hypothyroidism, high fat diets and starvation, especially in obese birds. Sub-normal levels may be observed with endotoxaemia, aflatoxicosis, spirochaetosis and low dietary fat. Unfortunately, there are no clear indicators to determine whether or not an abnormal cholesterol level is associated with a particular condition. For example, if an obese bird were to display elevated cholesterol, it would be unclear whether the elevation was a result of hypothyroidism, excessive dietary fat, hepatic lipidosis, or mobilization of body stores during anorexia. Other tests and observations usually provide evidence of these conditions, with or without the support of the cholesterol level. Again, normal values do not rule out the aforementioned conditions.

### ***Chloride***

Changes in chloride levels are rarely observed in avian samples.

### ***Creatinine***

Creatinine levels in avian serum samples typically fall below a measurable range, and are rarely useful in avian clinical pathology. Also, certain technical factors contribute to a high incidence of artifactual changes. Elevations have been associated with kidney disease, but creatinine is not considered to be a reliable indicator of renal function.

### ***Creatinine kinase (CK, CPK)***

The primary sources of creatinine kinase include skeletal muscle, cardiac muscle and nervous tissue, and elevations are associated with significant disruptions of these tissues. The primary usefulness of this enzyme is in distinguishing between hepatic and non-hepatic causes of an elevated AST. Any elevation in AST should be compared with the patient's CK level. If the CK is normal, it is relatively safe to conclude that the liver is the source of the elevated AST. If the CK is elevated, muscle should be considered a possible source of the elevated AST. Other possibilities for the dual elevations would of course be concurrent liver and muscle or liver and neurological disease.

### ***Delta-aminolevulinic acid dehydratase (ALAD)***

Aminolevulinic acid dehydratase is an enzyme that is affected by the presence of heavy metals. Heavy metal toxicity in birds consistently causes a decrease in blood levels. A major problem with this assay, which limits its usefulness, is its short half-life in serum samples. This can be overcome by submitting a control sample at the time of submission. If the suspect sample ALAD level is significantly less than the control, a presumptive diagnosis of heavy metal toxicity can be made.

### ***Gamma glutamyl transferase (GGT)***

Gamma glutamyl transferase activity in birds is low. Various observations have been made by different investigators, giving inconsistent findings. It does not appear to be useful as a diagnostic aid in birds.

### ***Glucose***

Pathological changes in avian blood glucose levels principally involve elevations. Hypoglycaemia is extremely rare in birds and, when present, is almost never associated with starvation. The primary cause of hypoglycaemia in pet birds is septicaemia.

Hyperglycaemia occurs commonly due to stress or after meals and, occasionally, owing to diabetes mellitus. Because of the frequency with which hyperglycaemia is caused by

stress, a diagnosis of diabetes mellitus should be considered carefully and only if other evidence supports it. A visibly normal hyperglycaemic patient displaying no polydipsia, no polyuria and no weight loss, etc. should not automatically be considered diabetic. Repeat testing, other diagnostic investigative tests and observation are necessary to confirm a diagnosis.

### ***Glutamate dehydrogenase (GLDH)***

Sources of GLDH in birds include the kidney, liver and brain. Although not widely available, the GLDH level can provide significant information in the investigation of hepatic disease. Elevations are observed when significant cellular destruction occurs.

### ***Iron***

While iron storage disease is a common problem in some avian species, serum iron levels have no diagnostic value. Poor correlation exists between blood iron levels and the presence or absence of haemochromatosis.

### ***Lactate dehydrogenase (LDH)***

LDH is found in skeletal and cardiac muscle, liver, kidney, bone and erythrocytes. Elevations can be observed with disruption of any of these tissues or in haemolysis, and are therefore extremely non-specific. One benefit of measuring LDH levels may be in following the progress of liver disease, in which LDH levels apparently change more quickly than SGOT levels; lowering LDH values may imply improvement even though SGOT levels remain elevated.

### ***Lipase***

Serum lipase levels may be elevated in cases of acute pancreatitis. Currently, the only reliable ante-mortem confirmation of pancreatitis is by pancreatic biopsy.

### ***Phosphorus***

Less common than in other species, elevated serum phosphorus is occasionally observed in renal failure. Elevations are also observed in hypoparathyroidism and nutritional sec-

ondary hyperparathyroidism. Haemolysis may also artifactually elevate serum samples. Malabsorption and vitamin D deficiencies may cause lowered blood phosphorus levels.

### ***Potassium***

As with sodium, pathological changes in potassium levels indicate a serious and usually life-threatening clinical situation. Hyperkalaemia develops with advanced kidney disease, adrenal disease, and during episodes of acidosis. Hypokalaemia may result from loss through diarrhoea, and during states of alkalosis.

### ***Sodium***

Changes in sodium values usually reflect serious conditions. Elevated levels occur with salt poisoning, water deprivation and dehydration. Decreased levels occur due to sodium loss in kidney disease or diarrhoea.

### ***Total protein (TP)***

A total serum protein level must be considered in light of its components, albumin and globulin. The total value is influenced by various factors but, as discussed above, a normal value does not rule out abnormalities of the individual protein components. Overall, dehydration and immune stimulation may cause a hyperproteinaemia. A hypoproteinaemia may be caused by overhydration, protein loss in kidney disease, starvation, liver disease or intestinal disease. As stated earlier, the protein should never be considered normal until the A:G ratio is known to be normal. A patient's serum protein can only reliably be evaluated through electrophoresis.

### ***Urea (BUN)***

Because of the low level of urea in avian blood, its usefulness is limited. Also, the avian kidney appears able to excrete most urea as long as the patient's hydration is adequate. Therefore, blood urea may be a better indicator of hydration than renal function, where an elevated urea would imply dehydration.

**Uric acid**

The serum uric acid level is the primary indicator of renal dysfunction in birds. An elevated uric acid level is a reliable indicator that kidney function is impaired. With many tests, substantial elevations are necessary before there is reason for concern; however, even a subtle elevation in the uric acid warrants suspicion of renal disease. Conversely, serial determinations should be made after adequately hydrating the patient before concluding a diagnosis of renal disease. It must be noted that uric acid levels may be artifactually elevated if blood is collected via a toenail trim, due to uric acid contamination of the nail.

**Serology*****Chlamydia***

Several serological tests for antibodies against chlamydia have been developed. Various technologies are currently used, including complement fixation, latex agglutination and immunofluorescent antibody. Although each utilizes a different method for detecting antibodies, the presence of antibodies must be interpreted with the same degree of care for each. Specifically, the presence of antibodies does not necessarily relate to the status of infection; a positive antibody titre may indicate present or past exposure in a given patient. Paired serum samples may provide more information, with a rising or falling titre more significant than an unchanging one.

***Aspergillus***

The detection of antibodies to *Aspergillus* spp. provides inconsistent evidence towards a diagnosis. A positive titre may imply infection, but false positives and negatives are common.

**Antigen detection*****Chlamydia***

There are two primary technologies (excluding culture) currently used for the detection of chlamydial antigen. Various manufacturers have marketed an in-house ELISA test, which with reasonable consistency demonstrates

chlamydial antigen in specimens such as mucosal swabs, faecal samples or tissue preparations. However, the absence of antigen in no way rules out the presence of *Chlamydia* spp. in the host. Since Chlamydial organisms may be shed only for brief periods, a negative test means only that antigen is not present in the sample tested. False positives do exist but, in conjunction with other data, the ELISA can be useful.

The second technology currently being utilized involves a DNA probe that theoretically detects a portion of the *Chlamydia* spp. genome. Because this technology focuses on the agent's unique DNA, it dramatically reduces the incidence of false positives and false negatives. While the technology is sound, the accuracy of the test in clinical settings is unproven.

***Aspergillus***

An IFA test for *Aspergillus* spp. antigen is currently being developed. Theoretically, this test offers the advantage of detecting circulating antigen instead of antibodies. The presence of antigen in addition to antibodies would provide strong evidence of an active infection, while the presence of antigen in the absence of antibodies could represent either background levels of antigen or an immunosuppressed patient with an active infection. Clinical trials will indicate whether either of these scenarios holds true.

***Polyoma***

The suspected presence of polyomavirus in a patient is best detected through a DNA probe. The technology behind this test is probably one of the most reliable with regard to specificity. In essence, viral DNA patterns are as unique as fingerprints. The probe technology amplifies and labels only the viral DNA for which the test is designed, and the persistence of the label in the suspect sample confirms the presence of the viral DNA.

The test is performed either on cloacal swabs or whole blood, each having different clinical implications. A bird that tests positive via a cloacal swab is infected, shedding the virulent virus, in danger of dying, and represents a threat to susceptible birds. A patient that demonstrates circulating polyoma DNA may



either be in the very early phase of infection with active circulating virus, or in a post-infection phase where only inactivated viral particles remain. These post-infection patients usually recover fully and cease to act as a source of infection for other birds. Birds that have been vaccinated for polyomavirus may test positive with the polyoma probe.

### ***Psittacine beak and feather disease (PBFD)***

The technology behind PBFD testing is identical to that for polyoma, the primary difference being that cloacal swabs are not useful in the diagnosis of PBFD. The PBFD probe may be performed on either whole blood or follicle biopsies, and a positive feather biopsy is prognostically more grave than a positive blood test. In the absence of clinical signs, a patient testing positive via a blood sample should be treated as a suspect only and retested 30+ days later. Many of these patients revert to negative and do not pose a threat to themselves or other birds. Feather follicle biopsies that test positive indicate infected patients, which carry very poor prognoses and are highly infective to other birds.

## **Microbiology**

### ***Bacterial culture and sensitivity testing***

The harvesting of bacteria from a particular site and their subsequent identification and testing for antibiotic susceptibility is an easy process; more difficult is determining the significance of the findings. Bacterial culture/sensitivity have been grossly misused as an indicator of avian health. In the early days of avian medicine it was believed that all Gram positive organisms were beneficial and all Gram negative were harmful, but experience has demonstrated that the separation of beneficial from harmful organisms is far less clear. A few species of Gram negative bacteria such as *Salmonella* spp. are recognized as obligate pathogens, but most are variably pathogenic if at all. There are also instances where Gram positive bacteria such as *Staphylococcus aureus* can be markedly pathogenic.

The best way to interpret bacterial findings is closely to examine the patient, even before attempting to identify a possible pathogen.

This first question to be addressed is whether or not there are any visible clinical signs of infection. A bacterial culture from a perfectly normal oropharynx may be irrelevant, regardless of the bacteria that might be isolated. If, however, visible pathology is present, a culture may identify causative agents. Rarely should a patient be treated with antibiotics merely because of the presence of suspect bacteria. Allegedly undesirable bacteria may actually be harmless, or they may be present secondary to another condition such as malnutrition, contamination of the water source, etc. Only when a specific disease condition can be directly linked to a possible pathogen should a culture be considered significant.

### ***Fungal culture***

The primary fungi of concern to the avian practitioner are *Candida albicans* and *Aspergillus fumigatus*. Other species can be significant but more often exist as contaminants, and standard culture techniques should allow for the appearance of these organisms. When isolated, their significance must be interpreted in light of clinical signs, haematological data etc. Their mere presence does not confirm disease.

### ***Chlamydia***

The only absolute established confirmation of the presence of *Chlamydia psittaci* in an avian sample is its growth and identification in culture. All other tests carry risks of false positive or negative results. However, culture for the *Chlamydia psittaci* organism can produce false negatives.

### ***Mycoplasma***

Investigations into infectious causes of avian respiratory disease should always include the consideration of mycoplasma as a possible contributing agent. Although not difficult to propagate, it is usually necessary to specifically request that this organism be cultured. Most laboratories will overlook the possibility of its presence.

### ***Virology***

The true cause of an avian illness is often a virus, and it seems as though a new one is

identified every few years. Virus isolation will always have a role in the investigation of avian illness.

## Miscellaneous

### *Urinalysis*

Because avian urine and faeces are mixed in the cloaca, pure avian urine samples are difficult to obtain. The most useful aspect of avian urinalysis is the analysis of the urine sediment. Sometimes the only clinicopathological evidence of renal disease is the presence of granular or hyaline casts, and polyuria that cannot be explained through other means should be investigated by carefully examining the urine sediment for these casts.

### *Heavy metal assays*

Lead and zinc are common causes of heavy metal intoxication in birds. Assays are available for each of these, as well as for copper. Unfortunately other metals also cause toxicity and illness, so the absence of lead, zinc and copper in a suspect sample does not absolutely rule out heavy metal toxicity in a patient.

### *Cytology*

Cytological preparations of avian samples, both ante-mortem and post-mortem examinations, can be extremely useful. By carefully examining the cellular and microbiological content of a given specimen, a tentative diagnosis is sometimes immediately possible.

### *Faecal examinations for parasites*

Gastrointestinal parasites, while rare in pet birds, are occasionally significant causes of avian illness and death. Suspect cases should be examined through the use of direct saline smears, flotation techniques and certain specialized assays.

*Giardia* spp. is one parasite for which there are a variety of diagnostic techniques available. Direct saline smears are occasionally revealing, although the organisms may be more clearly visible when stained with Lugol's iodine. Trichrome staining will sometimes display the organisms more readily. An ELISA test is now available that shows great promise in identifying difficult cases

### *Gram's staining*

At one time, the Gram's stain was the most commonly utilized test in avian medicine. Much controversy now surrounds its significance in assessing avian health.

The Gram's stain itself will always be a useful test; the problem lies not in the test but in its interpretation. Many birds are erroneously diagnosed with Gram negative bacterial infections due to artifact from poor staining techniques. The findings of a correctly performed test are often misinterpreted as abnormal when in fact they may be acceptable. An understanding of avian bacteriology is a prerequisite for accurate interpretation of avian Gram's stains. The Gram's stain may then be used to determine the major flora in a given faecal sample.

# 4

## Imaging techniques

*Maria-Elisabeth Krautwald-Junghanns and Katja Trinkaus*

### Radiography

High-quality radiographs are a basic requirement in the use of radiographic imaging as a diagnostic procedure in avian medicine and surgery. The small size of avian patients and their delicate anatomical structures necessitate a high degree of detail in order to recognize and correctly interpret the diagnostic images. To correctly produce and interpret avian radiographs, specific technical factors (such as the type of X-ray machine, film–screen combination and film processing) and an experienced clinician are necessary.

Movement is a problem with avian patients, causing poor radiographic detail. Anaesthesia reduces patient motion but does not reduce the high respiratory rates; therefore a short exposure time (0.015–0.05 s) should be used. This is achieved by using a powerful X-ray machine of at least 200–300 mA (a two- or multi-phase generator). Low kilovolt values are recommended in order to obtain radiographs with high contrast and as many shades of grey as possible. Depending on the screen chosen, values of 10–20 KV are necessary. Increasing the kV output in order to reduce the exposure time is not advisable, since this leads to a reduction in contrast. Lowering the dosage by decreasing the focal–film distance is also of limited value (a minimum of 60–70 cm should be used with a high definition film–screen combination), since this leads to a significant loss of definition due to the large size of the focal spot in low performance machines.

High-definition screen–film combinations have proved most efficient for avian radiographic studies. Significantly higher dosages are required when using non-screen films or dental films, and this means more radiation exposure to the operator as well as a longer

exposure time. These films are therefore inappropriate for radiographing the bird's body, despite their advantage of recording greater detail.

The use of screens with a greater intensifying capacity is strongly recommended in order to minimize the exposure time. However, a higher intensifying capacity of the screen is associated with a decrease in sharpness of the image. The development of rare-earth screens has proven to be a major advance when compared to normal calcium tungstate screens. Rare-earth screens have a similar intensifying capacity but significantly improved definition (sensitivity 100), and are routinely combined with films giving high resolution and the best possible contrast. The best combination for use in avian radiology seems to be a rare-earth screen at the back of the cassette, providing high definition, and a film emulsified on one side, such as those used to record monitor images in computerized tomography. More intensifying rare-earth screens (sensitivity of 200) may be advisable when working with very low performance machines, as the resulting decrease in picture quality will not be as distracting as the motion artifacts incurred with long exposure times. Calcium tungstate screens, which are even more intensifying, are inadequate because of the loss of image detail.

### Restraint

There are several possible methods of restraining birds for radiography. It is always best to restrain the patient in a way that does not expose veterinary medical personnel to radiation, and this is possible with the help of a Plexiglas® plate. If the Plexiglas® plate is not

thicker than 0.5 cm, it does not adversely affect the definition of the radiograph. Another method for restraining small birds is with adhesive tape, and crepe tape is used for feathered parts of the body to avoid damage of the skin and feathers when the tape is removed.

It may not always be possible to avoid restraint using the hands, and in these situations it is important adequately to protect the hands of the person holding the bird. It may be impossible to wear lead gloves for manual restraint procedures, particularly when working with very small patients; and in these cases the diaphragm must be adjusted so that the hands are out of the primary beam. Lead gloves can then be laid over the operator's hands to help protect them.

The question of whether or not sedation is indicated for radiography in birds must be decided on a case-by-case basis. In routine practice it is often not necessary to sedate an avian patient for radiography. If an inhalation anaesthetic unit is available, isoflurane is the drug of choice. If no inhalation apparatus is available, the radiographic procedures may be finished more quickly in routine practice

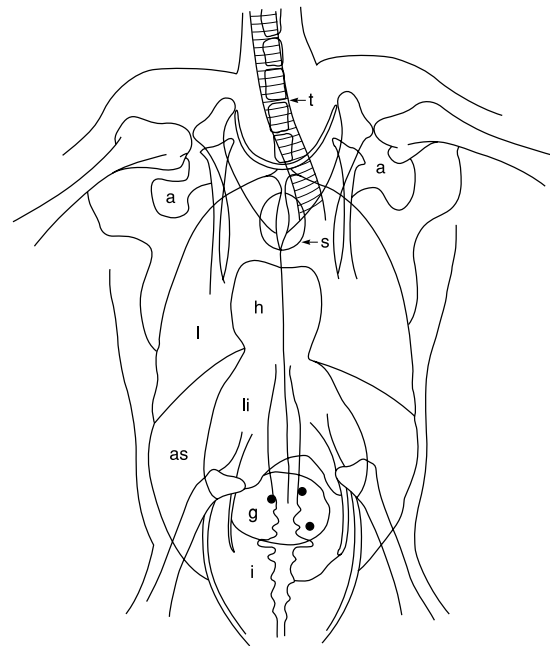
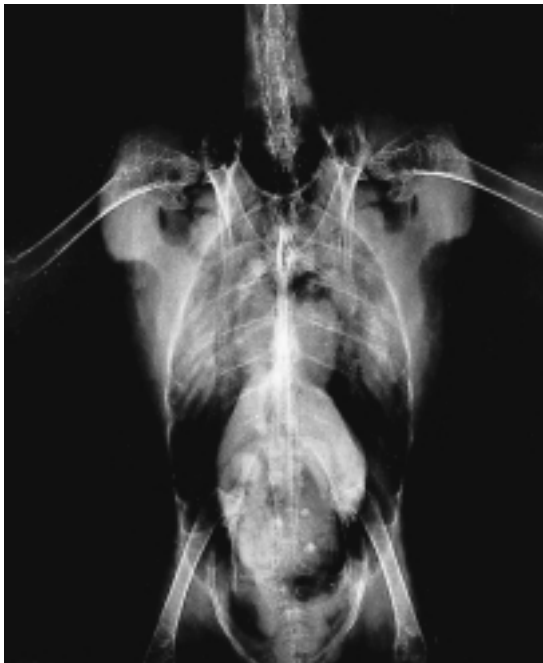without spending time on parenteral anaesthesia (weighing the bird, post-anaesthetic supervision, possible over-sensitivities, etc.).

If contrast a medium is administered orally for a radiograph of the gastrointestinal tract, inhalation anaesthesia should be avoided because it can lead to a reduction in the peristalsis of the alimentary tract (xylazine and most barbiturates can have the same effect). On the other hand, blurring due to movement can be avoided with sedation. Sedation may be necessary in birds unaccustomed to human contact, and especially in raptors, to avoid powerful defense reactions. In cases where birds are restrained by adhesive tape, and in most head/skull evaluations, sedation is advantageous.

## Standard views

At least two projections, taken at 90° angles to one another, are recommended for all studies. The following standard views are suggested:

- Body (plus neck and proximal limbs) – latero-lateral, ventro-dorsal



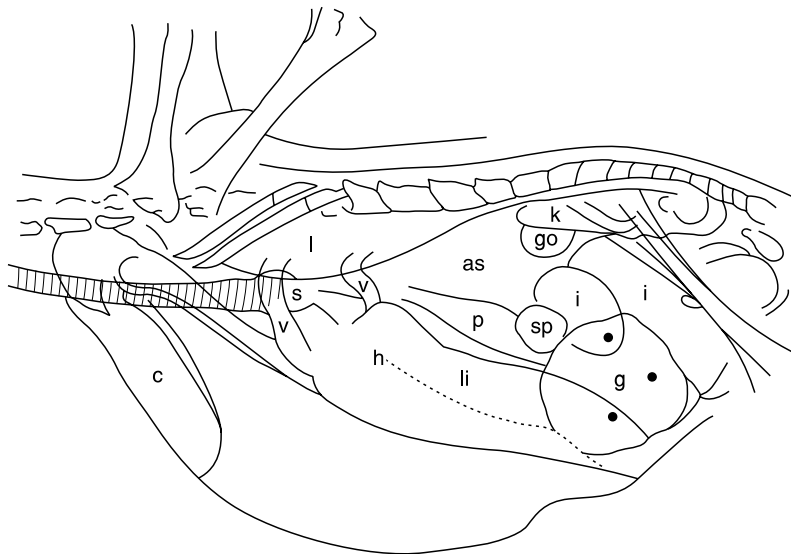
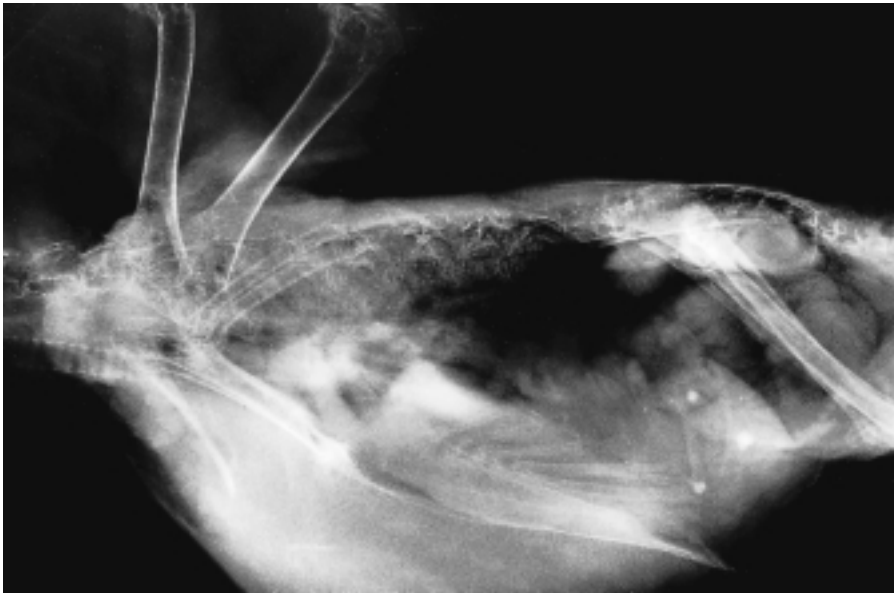
**Figure 4.1** Blue-fronted Amazon, ventro-dorsal projection: t = trachea; a = axillary air sac; s = syrinx; h = heart; l = lung; li = liver; as = thoracic and abdominal air sac region; g = gizzard containing grit particles; i = intestines.

- Head/neck – latero-lateral, ventro-dorsal, dorso-ventral, rostral
- Wing – medio-lateral, cranio-caudal
- Leg – medio-lateral, caudo-cranial.

For the ventro-dorsal projection (Figure 4.1) of the body, the bird is laid in dorsal recumbency on the table; the wings are drawn outwards

from the body and the legs extended caudally to avoid superimposition. The sternum and the vertebral column should be directly aligned if the patient is correctly and symmetrically positioned.

For the latero-lateral projection (Figure 4.2) of the body, the bird is usually restrained in right lateral recumbency with the legs ex-



**Figure 4.2** Blue-fronted Amazon, latero-lateral projection: c = crop; v = large vessels; s = syrinx; h = heart; l = lung; li = liver; p = proventriculus; sp = spleen; g = gizzard containing grit particles; go = gonad; as = thoracic and abdominal air sac region; i = intestine; k = kidneys.

tended caudally and the wings pulled dorsally over the body. If the correct symmetrical position has been achieved, the two hip joints should be superimposed in the radiograph.

Sedation is usually necessary to radiograph the head. Restraining the patient with a Plexiglas® plate has a disadvantage in that the shadows of the radio-opaque head clamps obscure the first cervical vertebra and the occipital part of the skull. For the dorso-ventral and the ventro-dorsal projection of the head, the bird is laid in either ventral or dorsal recumbency on the table with the neck stretched and the head placed straight and in a symmetrical position. In the correct symmetrical position, the two rami of the mandible are parallel to the surface of the table. For the latero-lateral projection of the head, the bird is placed in right or left lateral recumbency on the table with the neck stretched. If the patient is correctly and symmetrically positioned, the rami of the mandible should overlap.

Radiographs of the bird in both dorsal and lateral recumbency show the wings in the same plane (medio-lateral, Figure 4.3). For the caudo-cranial projection of the wing, the bird is turned downward at right angles to the table. The wing must be extended laterally as far as possible, so that the cranial border of the wing lies parallel to the edge of the table.

Positioning for the radiography of the legs is easy. Adhesive tape is used to hold the legs. The shadow produced by the tape can be ignored.

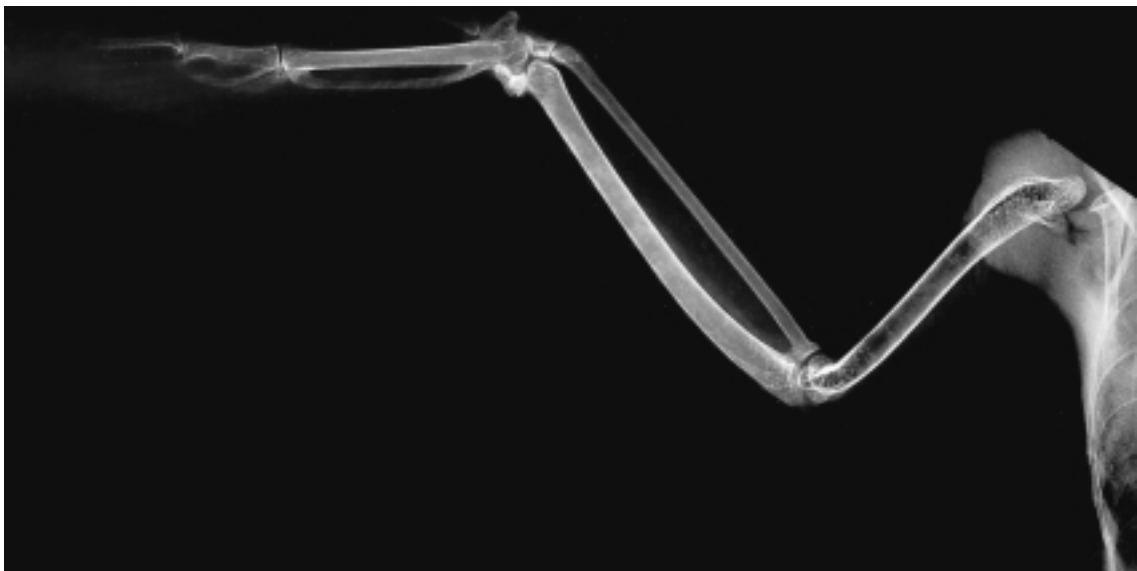
## Radiographic contrast studies

### *Gastrointestinal contrast*

In addition to the plain radiograph, gastrointestinal contrast investigations with barium sulphate and, in individual cases, double-contrast of the digestive tract with barium sulphate and air, are important diagnostic procedures.

A suspension of barium sulphate, using a dosage of 20 ml/kg body weight and a concentration of 25–45 per cent, is administered as a contrast agent directly into the crop or oesophagus. The concentration of the suspension used depends on the indication; a higher concentration is more effective for demonstrating lesions in the wall of the gastrointestinal tract, while a liquid contrast agent with a more rapid transit time is sufficient for outlining the intestines against neighbouring organs.

A survey radiograph must always be taken before beginning a contrast study. This is of particular importance for the demonstration



**Figure 4.3** Right wing of an African grey parrot, medio-lateral projection.

of radiodense heavy metal particles, since these could be disguised by the contrast agent. If birds are not severely ill, they should be fasted for about 2 hours prior to the administration of the contrast medium. In dehydrated birds adequate fluid replacement must be achieved prior to the administration of the contrast medium, otherwise inspissation of the contrast medium due to dehydration may occur, leading to delayed passage or even obstruction of the intestines. There is considerable species and individual variation in the emptying time of the gastrointestinal tract in barium studies. The transit time depends on the species' diet, size and length of the digestive tract. It is also influenced by numerous other factors, such as age, nutritional status and stress. Regurgitation of the contrast medium may occur in severely stressed birds, predisposing the patient to aspiration pneumonia. A rapid or accelerated transit is seen in birds living on a soft food diet, in small songbirds, and in cachectic and stressed birds. A slow or prolonged transit of contrast medium occurs in large seed-eating birds, young birds, obese birds and when the stomach is congested with food, as well as in sedated or anaesthetized birds. Prolonged fasting prior to administration of the contrast medium leads to a reduced transit time to the ventriculus and an increased transit time through the rest of the gastrointestinal tract, prolonging the elimination of the contrast medium.

A double-contrast study of the gastrointestinal tract is rarely used in avian practice, but it can be helpful in diagnosing non-perforating wall lesions as well as other changes in the thickness and condition of the gastrointestinal wall. The contrast agents can be administered orally or as an enema; 10 ml/kg positive contrast medium (25 per cent barium sulphate suspension) are given *per os* or via the cloaca. Air is used as a negative contrast medium, and is introduced immediately after administration of the positive contrast medium. The volume of air used is double that of the positive contrast agent, i.e. 20 ml/kg body weight (oral or cloacal). For better dispersion, the bird is carefully rotated around its own longitudinal axis several times immediately after administration of the contrast medium. For double-contrast radiographs in large birds, the kV is lowered one

step. If excessive amounts of contrast agents are used complications may occur, including rupture of the gastrointestinal tract.

### **Urography**

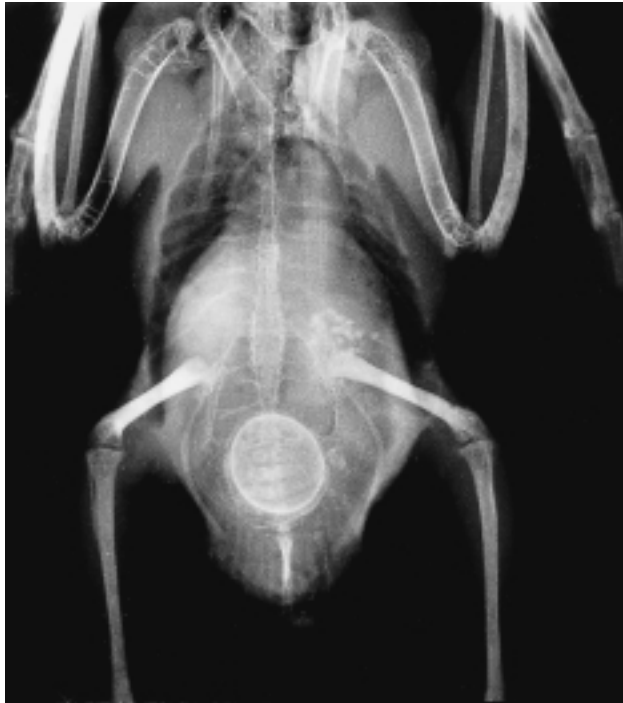The application of urography in birds is limited; there are significant differences between the urogenital tracts of birds and mammals in that birds do not have a bladder, urethra or renal pelvis, and there is no distinct difference between renal medulla and renal cortex. Therefore there are very few indications for urography in birds, and the demonstration of the kidneys by this method is not clear as in mammals. Because of the bird's renal portal system, the contrast medium is eliminated very quickly.

Iodine compounds are the best contrast media for urography, and should be warmed to body temperature and administered slowly into the basilic vein. The dosage is 700–800 mg iodine/kg body weight, using a 70–80 per cent organic iodine compound or a compound with 300–400 mg iodine/ml of solution.

The patient should be fasted for about 2 hours prior to administration of the contrast medium. Sedation or anaesthesia is necessary, and in avian patients with renal insufficiency there may be problems since some anaesthetic agents (e.g. ketamine hydrochloride) impose an additional stress on the kidneys. The quality of contrast obtained depends on the renal concentrating ability of the preparation applied and on the iodine concentration of the contrast agent.

### **Radiography of the skeletal system**

Avian bones are characterized by a thin cortex and a very delicate pattern of trabeculae. The long bones of most birds are pneumatized – as are, to a lesser extent, other parts of the skeleton (e.g. skull, pelvis, vertebrae, coracoid). In young birds the skeleton is poorly demonstrated by radiography, because persistent cartilaginous parts are typical in growing birds (e.g. the distal sternum, the scapula and the diaphyses). Ossification of the skeletal system occurs earlier in smaller avian species. Avian bones have no ossification centres in the epiphyses such as in mammalian bones.



**Figure 4.4** Cockatiel, ventro-dorsal projection. Note: 'medullary bone' (increased radiodensity) of the ulna, the femur and the tibiotarsus on both sides; old egg with roughened calcified shell in the caudal abdominal region; displacement of the ventriculus (grit filled) to the left cranial side; soft tissue shadow in the mid-abdominal region. The soft tissue shadow was due to three laminated eggs in the oviduct.

Homogeneous hypercalcification (medullary bone, Figure 4.4) is a physiological characteristic seen in female birds prior to egg production. This is a physiological calcium storage site, whereas irregular hyperostosis is a result of excessive hypercalcification, often caused by an abnormally high oestrogen level and associated with pathological findings such as laminated eggs, gonadal tumours or cysts.

Periosteal reactions and osteolysis indicate an inflammatory process. Periostitis may occur with fracture healing, or in conjunction with other inflammatory processes – for example, rhinitis and sinusitis with oversecretion may be seen as increased radiodensity of the infra-orbital sinus. Surrounding bones may show osteolytic changes. Septic pododermatitis is visible on radiographs as various degrees of arthritic and osteolytic lesions of the toes, joints and tarso-metatarsae.

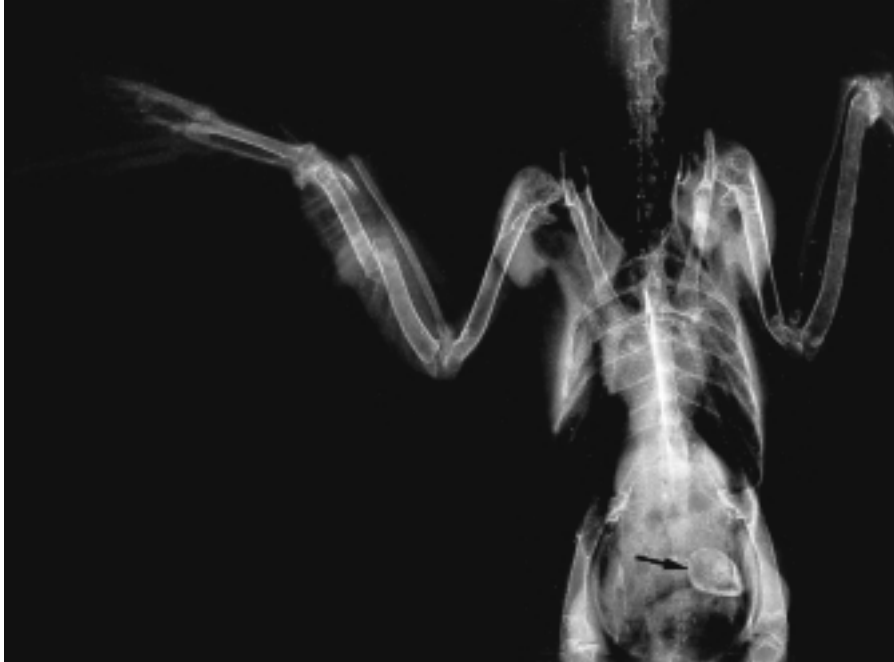The diagnosis of fractures or pathological changes of the bones of the shoulder girdle is more difficult than in long bones because of the muscle mass found in this area of a bird's

body. In the lateral view it is impossible to distinguish the coracoid from the scapula, but asymmetrical positioning may help radiographic interpretation. Fractures of the vertebral column usually involve the last two thoracic vertebrae and the synsacrum.

Fracture healing in birds (Figure 4.5) should be assessed by the extent of the endosteal callus formation (Bush *et al.*, 1976). A large formation of callus is not necessarily a sign of progressing stability, but may be an indication of movement at the fracture site. Increased radiodensity as a result of calcium deposition at the fracture site followed by the formation of new bone, in the absence of signs of inflammation, indicates primary healing.

Multiple deformities of the skeleton are often a consequence of calcium, phosphorus and vitamin D<sub>3</sub> imbalance at the nestling age. The typical appearance in the bird is that of a convex vertebral column (kyphosis) and malformed long bones with pathological fractures. Older birds can also succumb to osteomalacia or secondary hyperparathyroidism;





**Figure 4.5** Small songbird, ventro-dorsal projection. Note: 1-week-old fracture of the left ulna with formation of endosteal callus; distal fracture of the left radius; deformed, thin-shelled egg in the caudal abdominal region (arrow).

the latter can be recognized by increased radiodensity in various parts of the skeleton, mainly in the shoulder girdle and the skull.

### **Radiography of the respiratory tract**

The cartilaginous rings of the trachea are easily demonstrated in radiographs, and the lungs have a typical honeycomb structure. Radiographically, the air sacs have almost the same radiodensity as the surrounding air. Absolute absence of movement blur is necessary to be able to interpret changes of the respiratory tract in a radiograph.

A homogeneous increased density of the lung field and the air sacs can be caused by fat deposits or pneumonia, requiring comparison with a radiograph of a normal bird of the same species for a definitive diagnosis. Mycotic infections manifest as irregularly distributed areas of increased pulmonary density.

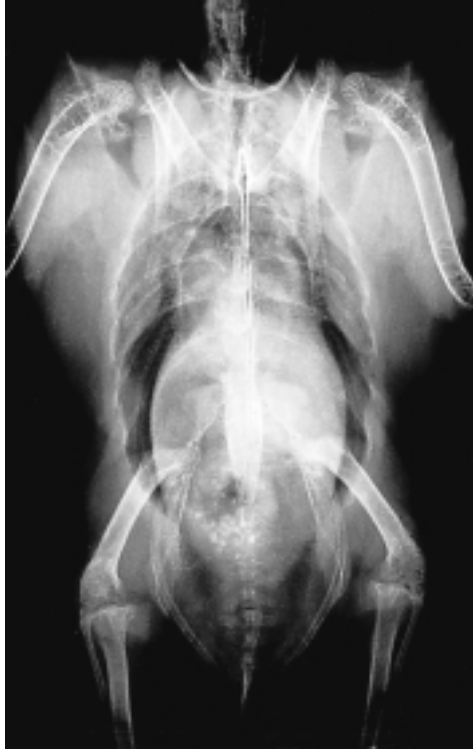Mycobacterial or mycotic granulomata can be seen as irregular focal dense areas.

Overdistension of the axillary air sacs is sometimes seen in birds due to a stenosis of

the lower respiratory tract, whereas overdistension of the abdominal air sacs is typical of a stenosis of the upper respiratory tract. The membranes of normal air sacs cannot be demonstrated in radiographs, but in later stages of chronic inflammatory disease, including airsacculitis, they may be well defined. Air sac walls may be thickened by bacterial, chlamydial or fungal infections.

### **Radiography of the liver**

The liver is visible in a ventro-dorsal view of the body, along with the heart, as an hour-glass-shaped shadow. Hepatic enlargement is easily demonstrated in radiographs (Figure 4.6). Hepatomegaly due to neoplasia is one of the most common diseases in budgerigars. In order to differentiate a tumour from an enlarged liver of a different aetiology, ultrasonography is necessary. Infections that lead to an enlarged liver include psittacosis, tuberculosis and Pacheco's disease, as well as other bacterial or viral infections. The proventriculus is often displaced dorsally in patients exhibiting hepatomegaly.



**Figure 4.6** Yellow-cheeked Amazon, ventro-dorsal projection. This female bird presented with a body weight of 830 g. Due to massive adiposity, the liver shadow is enlarged; lungs and air sacs show an increased radiodensity.

Diseases such as haemochromatosis are commonly considered clinically because of the extensive massive ascites. Radiographically, the entire abdomen (except for the air-filled lungs) is uniformly radiodense, and no differentiation of various organs is possible.

### Radiography of the spleen

The spleen can sometimes be seen in the indentation between the proventriculus and the ventriculus on a lateral view. An enlargement of the spleen can be suggestive of psittacosis, especially if the liver is also enlarged. Splenic enlargement can also be a sign of mycobacterial or viral disease. Neoplasia of the spleen is occasionally seen in budgerigars, but rarely in larger psittacines.

### Radiography of the gastrointestinal tract

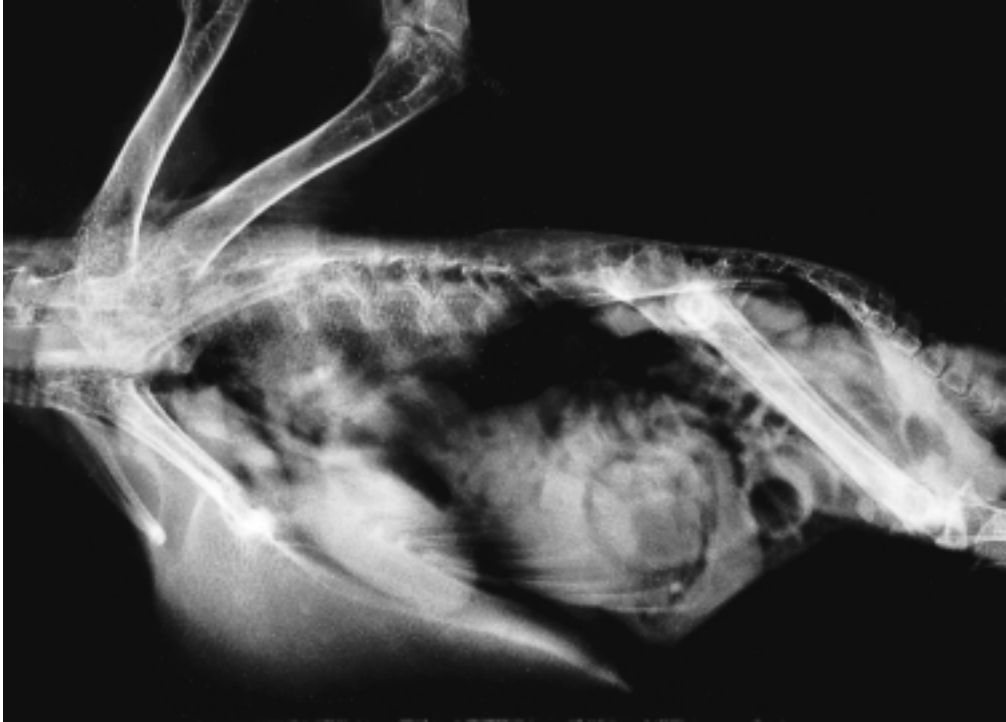
The gastrointestinal tract of birds can best be identified on the lateral view – especially in seed-eaters, where the grit-filled (radio-opaque stones) ventriculus is easily identified. Its physiological location is between the two acetabuli, paramedian on the left-hand side of the body. The proventriculus can be found dorso-cranially above the ventriculus. In birds that prefer soft food, it is not always possible to distinguish the proventriculus from the ventriculus. Use of a contrast medium allows differentiation of the gut from other internal organs, tumours and products of the reproductive tract.

Metallic foreign bodies in the alimentary tract are easy to identify, and must be distinguished from normal grit. They are typically found in the ventriculus. In most cases foreign bodies are more radiodense than grit, and identification is straightforward. Excessive grit in the ventriculus may pass into the intestines, and this may be a result of nutritional deficiency or malabsorption caused by infections.

Extensive gas in the intestines may be indicative of parasitic ileus, but it can also be caused by bacterial gastroenteritis or an obstruction of a different aetiology (Figure 4.7).

Displacement of the ventriculus (Figure 4.4) always indicates enlargement, swelling or neoplasia of a neighbouring organ. Dorso-cranial or caudal displacement suggest hepatic enlargement, ventro-cranial or caudal displacement suggest renal or gonadal enlargement. Ventro-cranial displacement can also be caused by a laminated egg in the oviduct, ovarian cysts or enlarged intestinal loops.

Dilatation of the digestive tract is easily identified in contrast radiographs. It can be caused by neurogenic infections, neurotoxic poisons, food stasis or ileus of the distal segments (Figure 4.7). A massive dilatation of the proventriculus can be a symptom of proventricular dilatation disease (PDD). Other characteristics of PDD include a retarded passage time, thinning of the proventricular wall, atrophy and deformation of the ventriculus. Candidiasis should be considered as a less serious differential diagnosis, as the



**Figure 4.7** Orange-crested cockatoo, latero-lateral projection. Note: dilatation of the proventriculus; dilated partly gas filled intestinal loops (worm infestation).

radiographic image produced by this disease is similar to that of PDD.

### **Radiography of the heart and vascular system**

In radiographs the heart is partially overlaid by the liver, and these two organs form the shape of an hourglass in the ventro-dorsal view. The cardiac apex is directed ventro-caudally and lies between the fifth and sixth ribs. The aorta and other large vessels are projected in an oblique direction, and may be seen as round radiodense structures in the ventro-dorsal view. In the lateral view, the brachiocephalic trunk, the *arteria pulmonalis* and the caudal vena cava are visible.

An enlargement and/or increased radiodensity of the heart shadow can be caused by different cardiac diseases, and the use of radiography for the diagnosis of pathological processes in the heart is limited. Ultrasonography and electrocardiography are

better methods for diagnosing heart and circulatory disturbances.

### **Radiography of the urogenital tract**

The kidneys are only visible in the lateral view. They lie caudo-dorsally along the vertebral column.

Enlargement of the kidney shadow is frequently seen in combination with an enlargement of other organs as a sign of generalized infection, e.g. psittacosis, or in connection with vitamin A deficiency or renal neoplasia. Kidney cysts may cause changes in the shape of the kidneys; however, cysts can be better diagnosed by ultrasonography. The use of a contrast medium using organic iodine compounds is indicated if functional disturbances of the urinary organs are suspected, or simply to highlight expected defects.

The gonads are particularly easy to visualize in their active state. On a lateral view, they are seen cranial to the anterior pole of the kidneys. Homogeneous hypercalcification of

the bone (medullary bone) is common in females before they begin laying eggs. Eggs can be clearly differentiated by the radio-density of the calcified shell (Figures 4.4, 4.5). When impacted with radiodense crystalline deposits, the kidneys are easily visualized. This is a sign of renal insufficiency, and may be the result of temporary dehydration or chronic bacterial infection.

Laminated non-shelled eggs cannot be clearly demonstrated in radiographs. Like other pathological alterations of these organs (e.g. salpingitis, ovarian cysts or tumours), they present as an indistinct soft tissue mass in the abdomen, often accompanied by the presence of medullary bone (Figure 4.4). An additional ultrasonographic examination may help to differentiate between salpingitis, laminated eggs, tumours and cysts.

## Ultrasonography

Ultrasonography is a useful non-invasive diagnostic tool in pet birds, especially in diagnosing soft tissue alterations. Diseases of the liver, heart and urogenital tract in particular are important indications for the use of ultrasonography in avian medicine.

The technical equipment used can be the same computerized ultrasound apparatus as that used for small mammals (Figure 4.8). The transducer required is a sector scanner with a frequency of 7.5 MHz. The use of a very small scanner is necessary because the area of contact with the bird is normally severely limited. Most of the scanners used in pet bird medicine were originally developed for intra-operative sonography in humans. Bird species from 40 g to 1 kg body weight can be sonographically examined with the equipment described. A stand-off consisting of a semi-solid gel is also necessary for the examination of small birds, in order to obtain a clear image of the upper tissues.

### Patient preparation

The bird should be fasted for at least 3 hours prior to the ultrasound examination. This period should be extended to 1–2 days for birds of prey. An anaesthetic is usually not



**Figure 4.8** Sonographic examination of an avian patient, ventro-medial approach.

necessary; the birds are either held by an assistant (Figure 4.8) or placed on a Plexiglas® plate in dorsal or lateral recumbency. Birds with severe circulatory problems should be examined in an upright position. The area of contact is extremely small in most pet birds, and is situated between the xiphoid process of the sternum and the pubic bone of the pelvis (in the ventro-medial approach) with lateral extension to the right- or left-hand caudal area of the last rib (in the lateral approach). The feathers are either parted in this area or, depending on the species of bird, plucked if necessary. An acoustic gel is then applied to ensure good contact between the scanner and the skin.

### Ultrasonography of the liver

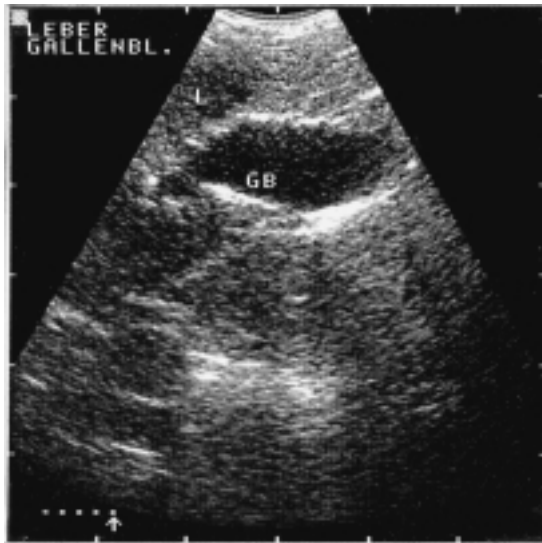In many cases, the indications for sonography are similar in both birds and mammals. Any

clinical symptom or laboratory result indicating abnormal liver function can be followed-up and further clarified by a sonographic examination of the liver.

Enlargement of the liver is frequently visible on radiographs, and further clarification by means of radiography is not possible. Ultrasound provides more information, especially regarding the internal structure of the organ. A radiological evaluation of the internal organs (with the exception of the air-containing lungs) is not possible if the patient has ascites; however, this fluid provides an ideal contrast medium for sonography, and makes examination of the liver easy.

The physiological echotexture of the liver is homogeneous (Figure 4.9), delicately granulated and of average reflex intensity. The inner structure is interrupted by blood vessels passing transversally and longitudinally. These are seen as anechoic channels.

Sonography is mainly used in suspected liver diseases in order to differentiate inflammatory processes from tumours, in the diagnosis of ascites or cysts, and to estimate the degree of alterations with regard to the prognosis. The sonographic image of a fatty liver degeneration shows a higher reflex intensity and hepatomegaly. Hepatic neoplasms may be seen as obviously non-homogeneous liver



**Figure 4.9** Sonogram of a goshawk, ventro-medial approach, showing liver parenchyma (L) and gall bladder (GB).

tissue; the parenchymal alterations can be focal or diffuse. Diffuse necrosis is typically seen as a spotted non-homogeneous pattern. Separate abscesses, granulomata or necroses are sharply separated from the normal liver tissue. Depending on their content, these areas may be hypoechoic with corpuscular parts, or hyperechoic, sometimes separated into small cavernae. Haematomata are sometimes found in hypoechoic parts of the liver and tend to organize after several days. This is associated with an increase in the reflex intensity.

### Ultrasonography of the gall bladder

Patients may have to fast for 1–2 days for examination of the gall bladder. A filled gall bladder in birds is easily recognized sonographically as a round-to-oval structure within the liver parenchyma. It normally appears as a smooth, clearly defined organ, with thin, reflex-intense walls and echolucent contents (Figure 4.9). It causes acoustic enhancement, as do other fluid-filled structures. Some large vessels, such as the right portal vein and the right hepatic artery, may be seen adjacent to the gall bladder. Alterations of the gall bladder seem to be rare in birds; however, with the help of ultrasonography neoplasia of the wall or the bile ducts as well as abnormal concretum content can be diagnosed.

### Ultrasonography of the spleen

Alterations of the splenic parenchyma cannot be diagnosed radiographically. Although the normal spleen is also very difficult to identify in sonography, indications for a sonographic examination may consist of any case of supposed splenic disease where the radiological diagnosis is insufficient. For example, examination may be indicated in the case of splenomegaly in order to differentiate inflammatory processes from tumours or post-traumatic reaction.

The lateral approach is used for the examination. The identification of the normal spleen can be difficult, as mentioned before. The size and shape of the spleen varies greatly between the various species. The spleen is slightly more echogenic, compared to the

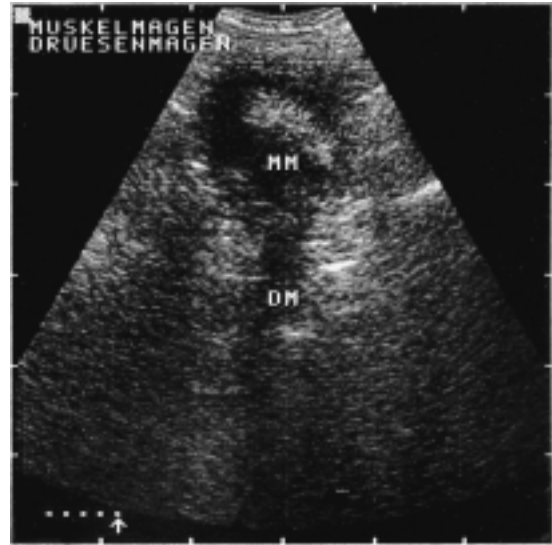relative hepatic echogenicity. The parenchyma is of fine and dense granularity, and is of even texture throughout.

The spleen is often markedly enlarged in pathological alterations. In these cases, the organ is also easily visualized from the ventro-dorsal approach. Homogeneous enlargement is frequently seen due to infectious or traumatic causes. Post-traumatic bleeding can be seen as hypoechoic areas. Splenic tumours are usually of mixed echogenicity, and this may be seen as a marked focal or diffuse inhomogeneous echotexture.

### Ultrasonography of the gastrointestinal tract

There are only a few indications for sonographic examination of the digestive tract. A survey radiograph and a radiographic contrast or double-contrast study of the gastrointestinal tract usually provide sufficient information on pathological alterations or functional disorders.

The ventriculus of seed-eaters is usually easily identified, from either the ventro-medial or the lateral approach. Grit content is readily visible as hyperechoic particles, usually surrounded by an area of lower echogenicity (dependent on the type of food eaten). The wall of the ventriculus is seen as a round echogenic margin. The proventriculus and the intestinal loops, as well as the cloaca, can also be identified on the sonographic image (echogenic wall, hypoechoic content, typical shape; Figure 4.10). The motility of the intestinal loops is clearly visible on the screen, and the duodenal loop is especially easy to identify by its position and shape. A stand-off is necessary for the examination of the pancreas. The cloaca is seen in the ventro-medial approach by sweeping the scanner caudally. The wall of the gastrointestinal tract may be difficult to examine sonographically, but this is facilitated when the tract is nearly empty and is then filled with fluid for contrast purposes. Food particles, especially bones in carnivorous species and gas content, make it impossible for the sound beam to penetrate, precluding an adequate evaluation of the gastrointestinal tract.



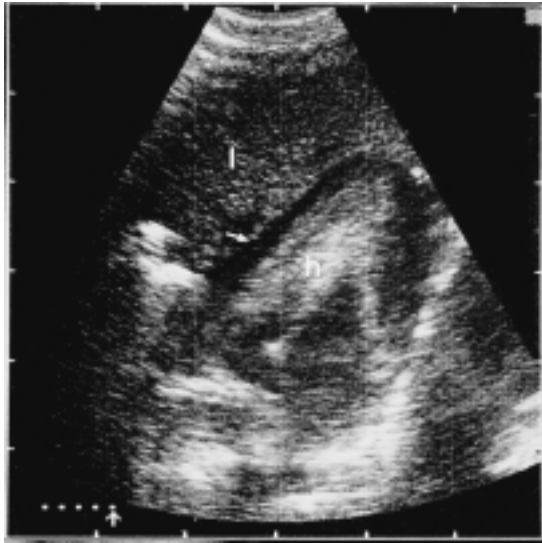**Figure 4.10** Sonogram of a sulphur-crested cockatoo, ventro-medial approach, showing the ventriculus (MM) and the proventriculus (DM).

### Ultrasonography of the heart

Echocardiography has much to offer in the cardiac evaluation of birds. It is an excellent diagnostic tool for obtaining information on the heart's function and on pathological alterations. Any clinical sign indicative of cardiac insufficiency should be followed-up by a sonographic examination. Another indication is radiographic evidence of heart disease, such as alterations in the heart's size, shape and radiographic density.

The B-mode technique can be used for sonographic examination of the heart. Due to anatomical peculiarities of the class aves standard M-mode traces cannot be interpreted correctly in birds.

The chambers, valves and large vessels and the motility of the heart and the valves can all be identified sonographically. A standardized schedule for routine echocardiography in birds was provided by Krautwald-Junghanns *et al.* (1995) using the following views and approaches: the apical four-chamber view and the apical longitudinal view from the ventro-medial approach, and the lateral four-chamber view and the transverse view from the lateral approach.



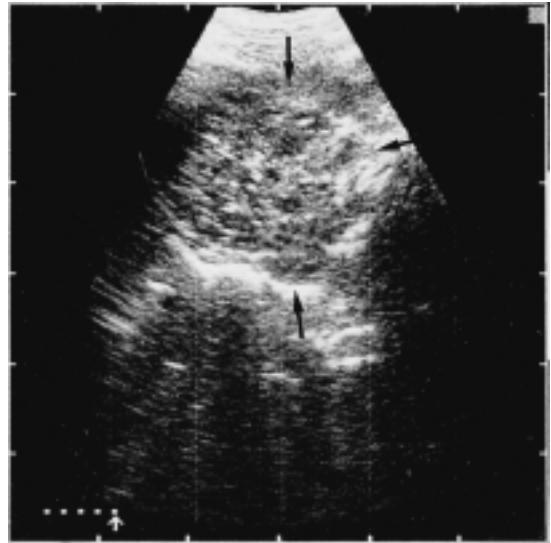
**Figure 4.11** Sonogram of a common buzzard, ventro-medial approach, showing the heart (h). Fluid is seen as an anechoic band (arrow) around the heart representing a hydropericard. Liver = li.

Many pathological alterations of the heart are caused by secondary factors. A cardiac hypertrophy, for example, is seen relatively often in the course of chronic respiratory disease. The enlarged heart is easily recognized sonographically. Furthermore, alterations of the pericardium, especially pericardial effusion, can be diagnosed by sonographic examination. Ultrasound is the method of choice for differentiating pericardial effusion from cardiomegaly. The fluid is recognized as an anechoic band separating the epicardium and the pericardium (Figure 4.11).

### Ultrasonography of the urogenital tract

Ultrasonography can be used to differentiate renal tumours, inflammatory processes and cystic alterations of the kidneys. Sonography of the reproductive tract is indicated in suspected egg-binding, salpingitis, and ovarian or oviductal cysts or neoplasms. Both the ventro-medial and the lateral approach can be used.

At this time, it is not possible to demonstrate the normal kidneys in birds by transcutaneous sonography. The inactive testes and



**Figure 4.12** Budgerigar, ventro-medial approach; massive enlargement of the kidneys (arrows) showing inhomogenous echogenicities. This bird suffered from a renal neoplasia.

ovaries are also difficult to identify in birds; they cannot be visualized sonographically because the intestinal loops (ventro-medial approach) and the abdominal air sacs (lateral approach) prevent their examination. The determination of a bird's sex with the help of ultrasonography has been successful with the use of intraclonal transducers. Active gonads may also be demonstrated via transcutaneous ultrasonography.

Developing follicles can be seen as round areas with an echogenic content (the yolk). Later, the strongly echogenic shell is easily differentiated from the surrounding tissue; the egg content is divided into two parts of differing echogenicity.

Renal neoplasia (Figure 4.12) are frequently accompanied by massive enlargement and parenchymal lesions. In these cases the kidneys are easily demonstrated by using the ventro-medial approach to show round, non-homogeneous structures.

Cysts can also be diagnosed sonographically. The characteristic appearance of a cyst is a clearly defined, rounded, echolucent structure, with marked posterior acoustic enhancement.

Egg-binding is easily diagnosed if the eggs have a shell. The demonstration of laminated

eggs without a shell is also possible by sonographic means. They are easily differentiated from the surrounding tissue, and appear as oval or round areas with varying echogenicity.

## Endoscopy

Rigid and flexible endoscopes were originally developed for humans. The rigid endoscopes made for arthroscopy of human joints have a diameter of 1.7–2.7 mm, and are commonly used in avian endoscopy. In avian medicine, endoscopy is used for diagnostic procedures and for surgical sexing.

## Diagnostic procedures

The endoscope can be used for the visual examination of any body orifice large enough to allow the insertion of this instrument. Apart from laparoscopy, which will be discussed under surgical sexing, tracheoscopy is the most common endoscopic procedure in avian medicine. It is used as an additional diagnostic tool for the detection of inflammation, occlusion or other lesions.

### *Tracheoscopy*

Tracheoscopy is indicated in birds showing clinical signs of dyspnoea presumably caused by an obstacle in the trachea or syrinx. Tracheoscopy is limited by the diameter of the patient's tracheal lumen and by the length of the patient's neck. In birds the size of cockatiels, the tracheal lumen does not allow the insertion of an endoscope. In birds with long necks, such as swans or storks, only the proximal portion of the trachea can be examined endoscopically. Because of the length of the neck, it is impossible to get a view of the syrinx with the rigid endoscope in these birds.

Tracheoscopy must be performed under anaesthesia. Most patients requiring this procedure show signs of dyspnoea, and trying to insert an endoscope into the trachea of a bird which is already having trouble breathing is difficult. In cases of severe dyspnoea, the patient's condition has to be stabilized with the aid of an abdominal air sac breathing tube

before the endoscope can be inserted into the trachea. The bird is positioned in dorsal or vertical recumbency. Dorsal recumbency is better for establishing the bird's condition. The neck has to be extended, and the operator opens the beak, pulls the tongue forward and carefully inserts the endoscope through the glottis. Scraping the tracheal wall with the endoscope can cause lesions and stimulate coughing, and this is minimized if the tip of the endoscope is always directed towards the centre of the tracheal lumen while the instrument is gently pushed downwards. In most cases, reflexive coughing stops when the endoscope is in place.

The tracheal examination can be used to diagnose foreign bodies, parasites and any kind of plaques obstructing the tracheal airway. Parasites are rarely seen in pet birds. If diagnosed they have to be treated medically, as their presence must be assumed throughout the whole respiratory tract. Foreign bodies and plaques are seen particularly in the region of the tracheal bifurcation. Seed hulls or whole seeds are commonly aspirated as foreign bodies. Plaques can be caused by hypovitaminosis A, are composed of squamous material, and may provoke secondary infections. Bacterial or fungal infections of the respiratory tract can also lead to inflammatory reactions and cell debris in the form of plaques in the respiratory tract. At the beginning of such an infection the process may be limited to the area of the bifurcation, but these infections usually spread very quickly over the whole respiratory tract. The extent of this expansion determines the bird's prognosis and the veterinarian's chance of treating the problem.

Any plaques observed in the trachea should be removed and examined if possible. Ideally, biopsy forceps can be passed alongside the endoscope and reach the plaque. If this is impossible because of the limited size of the tracheal lumen, an attempt can be made to loosen the plaque with the tip of the endoscope and remove it by suction with the help of a small catheter. With this method there is the risk of losing pieces of plaque into the deeper parts of the trachea while exchanging the endoscope for the catheter, and the bird should therefore be positioned horizontally before loosening plaque material. If this method is also unsuccessful, surgical removal



by opening the trachea is necessary. After the obstruction is removed, medication should be administered.

### ***Liver examination and biopsy***

The endoscope has proved to be a useful tool for the examination and biopsy of the liver. This organ is involved in many infectious avian diseases. Although examination of the liver with the aid of radiographs, ultrasonograms and blood chemistries can provide information regarding the liver function, these methods are not always exact enough to diagnose the cause of changes; in these cases, a biopsy may be necessary.

The liver is approached from the ventral aspect of the patient. The bird is placed in dorsal recumbency and its legs are pulled caudally. Just behind the sternum, in the midline, a 1 cm skin incision is made, followed by a smaller incision or puncture of the abdominal musculature before the abdominal cavity is opened bluntly. Underneath the abdominal muscles, the ventral hepatic peritoneal cavity membrane appears; this is held up with forceps in order to avoid lesions of the liver, and then carefully punctured with a blade or scissors. The hole is extended by inserting forceps and spreading them.

Having opened the peritoneal cavity, the operator can insert the endoscope and examine the ventral surface of both liver lobes. For the liver biopsy, small spoon-shaped biopsy forceps originally designed for otolaryngological examination are used. The forceps are passed alongside the endoscope until the jaws are visible through the scope. When they reach the area that is to be sampled, the jaws of the forceps are opened and a small piece of the liver is grasped. The jaws are held closed in this position for about 30 s, to prevent excessive bleeding, and the forceps are then removed with the sample between the jaws. At the end of the procedure, muscles and skin are closed with separate sutures. The bird should be kept under recovery conditions for about 2 days to minimize the risk of haemorrhage.

Another method for taking a liver biopsy which is also less traumatic and therefore preferable if the equipment is available is the ultrasound guided fine needle biopsy. Using a 20 G true-cut needle hepatic material is obtained for a histological examination.

### ***Oesophagus, crop and cloaca examination***

The oesophagus, crop and cloaca are the parts of the alimentary tract that are accessible to endoscopic examination. Indications are palpable structures of unknown origin, supposed obstruction, and other conditions in which neither palpation nor radiographs lead to a conclusive diagnosis. Infectious agents such as trichomonas, bacteria or fungi can be diagnosed with the aid of swabs taken from the crop or from the cloaca, and do not require endoscopic examination under anaesthesia.

For the endoscopic examination of the upper alimentary tract, the patient must be fasted until the crop is empty. The bird is then anaesthetized and held vertically with the neck extended. The beak is opened and the endoscope gently pushed into the crop like a crop cannula. Since the lumen of the oesophagus is normally closed, mucus will cover the lens of the endoscope and blur the view. The lens can be cleaned by wiping it against the oesophagus or crop wall. The view in the oesophagus is usually less blurred when the instrument is withdrawn rather than moved forward. Once the crop has been entered, an assistant can gently pull the skin over the thoracic inlet and upward in order to increase the view within the crop.

It is almost impossible to pass the endoscope into the proventriculus when entering from the oral cavity. If it is necessary, the crop can be surgically opened and the endoscope passed down the remainder of the oesophagus into the proventriculus. A small catheter can be inserted along with the endoscope and used to inflate the proventriculus. This makes operation easier, even when there are large amounts of secretions in the proventriculus.

### ***Examination of the nares and ears***

Depending on the size of the bird, the nares and ears can also be examined endoscopically, but deep penetration of these sites is not possible even in large birds.

### ***Surgical sexing***

A laparoscopic examination with accentuation of the reproductive tract is performed for

surgical sexing. This is the most common indication for endoscopy in avian medicine, and because of this laparoscopy and surgical sexing are not described separately.

## Presurgical considerations and anaesthesia

Surgical sexing or laparoscopy should be performed under general anaesthesia. Performing this operation without general anaesthesia carries a high risk of puncturing organs within the abdominal cavity when the bird moves and struggles. The danger of shock due to hyperventilation and an excessively increased heartbeat is also greater without general anaesthesia. Also, it cannot be considered humane to puncture the abdominal wall of a conscious bird.

Surgical sexing is a routine operation, and appears to the owner be a very low risk – especially since the bird concerned is generally healthy. Therefore, if any complications arise, the owner is likely to believe that the veterinarian is at fault regardless of the actual cause. This means that the risks of the surgery must be explained to each owner, and that the veterinarian must examine every patient carefully to determine whether or not the bird is in fact healthy and a good surgical candidate. A healthy bird appears alert and active, and is not emaciated. Ruffled feathers and apathy, diarrhoea, dyspnoea or similar pathological signs should not be detectable; if they are, the procedure should be delayed.

The operator has to make sure that the bird's crop does not contain palpable amounts of water or food, because passive regurgitation into the oropharynx under general anaesthesia can cause aspiration and asphyxia. The bird should have fasted in order to guarantee that neither the proventriculus nor parts of the intestine are at increased risk of being punctured accidentally with the trocar or the endoscope. The duration of fasting depends on the species; for example, birds with a slow transit time of the alimentary tract, such as raptors, should fast longer than psittacines. Furthermore, it is advisable to examine the bird's skeleton for old fractures or other abnormalities, since

these can cause injury when the bird is positioned for surgery. The abdomen should also be examined by palpation. A bird with ascites, severe adiposity or palpable abdominal tissue masses can have difficulties during the procedure.

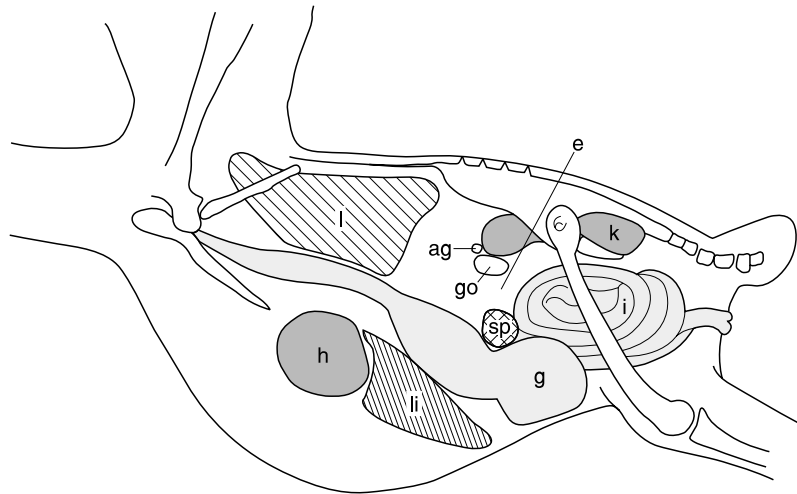
The endoscope should be sterilized in a liquid disinfectant that not only inactivates fungi and bacteria in general, but is also effective against mycobacteria and viral agents. It must be rinsed in sterile water before contact with the bird's abdomen, since most disinfectants cause irritation.

Gas anaesthesia is the most comfortable method of anaesthetizing a bird for surgical sexing or laparoscopy, as it allows a very quick recovery of the patient. The anaesthetic gas of choice is isoflurane, and the patient is usually induced through a face mask. Since routine surgical sexing only takes a few minutes, assuming no complications arise, the bird is usually not intubated for this procedure. The initial introduction is done with 5 per cent isoflurane, and anaesthesia is maintained at 1–2 per cent with an oxygen flow rate of 1–2 l/min.

## Surgical procedure

Three different entry sites can be recommended for sexing procedures or laparoscopy, and it is important to position the bird correctly for each approach used for surgical sexing. Improper positioning of the patient can lead to a different anatomical arrangement of the organs within the abdominal cavity, which not only increases the risk of puncturing organs but can also prevent an adequate view of the gonads.

All three entry sites are on the left side of the patient. This is important because females only have a functional left ovary, and when this is inactive it is small and difficult to find from the right side. The bird is placed in right lateral recumbency. Its head is grasped from behind and held in position by supporting the mandibular joints with the thumb and the index finger of the right hand. The position of the legs depends on the entry site preferred for the procedure. The feet are held with the left hand; the right leg can be left unsecured. The wings are pulled dorsally over the body and held



**Figure 4.13** Correct position of the endoscope in the most commonly used entry site for surgical sexing: ag=adrenal gland; e=endoscope; g=gizzard; go=gonad; i=intestine; k=kidney; l=lung; li=liver; sp=spleen; h=heart.

down in this position, with the forearm of the hand restraining the head.

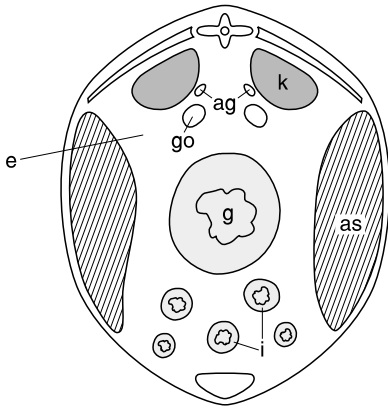
In the most commonly used approach, the legs are extended caudally. This position reveals the entry site in a depression between the ribs cranially, the synsacrum dorsally and the greater trochanter with the femur caudally (Figure 4.13). In psittacines, the insertion site is located directly anterior to the proximal one-third to one-quarter of the imaginary line between the greater trochanter and the knee. In mynah birds the kidneys are found in a more ventral position than in psittacines, and this means the entry site must be moved more ventrally in order to avoid a contusion of the kidney. The second possible approach is made just caudal to the pubis and ventral to the ischium. The leg must be pulled slightly forward.

The bird's position for the third entry site is the same as for the second, but the left leg is pulled forward more strongly. The lateral pelvic aperture is located, and the last rib is palpated. At this point, an inverted V-shaped landmark is seen where the semitendinosus muscle (*flexor cruvis medialis*) passes over the rib. The skin incision is made just caudal to this point. The fascial attachment of the semitendinosus is bluntly separated to reflect the muscle dorsally; the lateral body wall then becomes visible and allows the operator

direct access with either a trocar or blunt dissection.

After disinfecting the skin, an incision of 3–5 mm is made without injuring the underlying muscle in order to avoid diffuse bleeding, which could disturb the view later on. Then a probe, a trocar or fine closed mosquito forceps can be used to puncture the abdominal wall. A trocar should not be used in birds that weigh less than 100 g because it increases the diameter of the endoscope by at least 1 mm, which can make a large difference in the narrow abdominal cavity of a small bird.

A growing resistance is felt when attempting to penetrate the abdominal wall, and a characteristic 'pop' can usually be heard when penetration occurs. The probe is directed downward and has to pierce the abdominal air sac membrane gently so that the abdominal air sac cavity can be entered. Its medial membrane is then penetrated and the intestinal peritoneal cavity is reached. Since it is not easy to introduce the endoscope through the punctured hole, it can be inserted alongside the probe, allowing the end of the probe to guide the endoscope. The operator can then examine the area in which the abdomen has been penetrated and ensure that no damage has occurred during the process.



**Figure 4.14** Transverse abdominal section showing the correct position of the endoscope for surgical sexing: ag = adrenal gland; e = endoscope; g = gizzard; go = gonad; i = intestine; k = kidney; as = air sac.

The probe is then removed in order for the visual examination can begin. It may take a few moments to get a clear view through the endoscope. Sometimes the lens may be in direct contact with the air sac membrane or an organ, and in this case the position of the endoscope has to be corrected by gently withdrawing the instrument. If viscera are clearly visible, the endoscope has entered the intestinal peritoneal cavity. If only air sac membranes are seen, the tip of the endoscope is inside the abdominal air sac cavity. In this case, the lens of the endoscope is pushed gently against the air sac membrane until it is punctured (Figure 4.14).

With a clear view of the viscera, the operator first becomes orientated (Figure 4.13). In most cases the left kidney is easily recognizable; it is reddish-brown in colour and is located in the dorsal part of the visual field. Following the kidney to the left, its cranial pole becomes visible through the endoscope. Physiologically it has a rounded and smooth surface, and is generally larger than either the adrenal gland or the gonad. The adrenal glands are located anterior to the cranial poles of the kidneys, and are yellowish-orange in colour and highly vascular. In the most cranial part of the field of vision, the pink tissue of the lung is visible.

Gonads, adrenal glands, spleen, intestines and the dorsal portion of the proventriculus are situated within the intestinal peritoneal

cavity that runs along the midline from the cranial pole of the kidney to the cloaca. The kidneys are located retroperitoneal to this cavity.

In the male, the testes are located slightly ventrally to the cranial pole of the kidneys and the adrenal glands (Plates 5 and 6). In the female, the ovary's position is similar to that of the left testis. In the adult female, the active ovary may completely or partially cover the left adrenal gland.

When the examination is over, muscle and skin are sutured together and the bird is put in quiet place for recovery. Antibiotics are not routinely administered after this surgery. When several birds from one owner are surgically sexed, they are often put together in a single box during recovery. However, this should be avoided since the most heavily sedated bird is often bitten by the others.

### **The gonads**

The testes have a bean-shaped or cylindrical appearance, a smooth surface, and are creamy-white in colour (Plate 5) although they can be melanistic in some species. In psittacine birds, all male white cockatoos and many of the Australian parakeet species have melanistic testes. Sometimes a black gonad will be seen in a species that does not normally have melanistic gonads, but this should not be interpreted as a pathological finding.

The testes can vary in size, depending on the age of the bird and the stage of the reproductive cycle. In immature individuals they are very small and usually avascular. Testes that are just becoming active may appear pink due to the superficial vessels, which increase in diameter in this functional stage. In a mature bird the testes can vary in size, and may be as much as 500 times their normal size during the breeding season. In general, they are larger than the adjacent adrenal gland and more vascular on the surface. Under physiological conditions, both the testes are the same size. In the mature male they atrophy after a period of sexual stimulation, but never become as small as they were in the immature stage.

Like the testes, the ovary is usually creamy-white but may be pigmented. In the immature

bird it is comma-shaped and dorso-ventrally flattened, and it may resemble a piece of fat. The inactive ovary of a mature bird has many small follicles; the active ovary has a grape-like cluster of small but prominent follicles that are easy to identify.

Ovarian cysts are common, and they appear in the form of clear vesicles that can be larger than the rest of the ovary. When they occur, they usually represent the only follicular activity detectable. These patients should not be mistaken for successfully breeding birds.

Sometimes the testes appear to have a rough surface. This is caused by the development of testicular cysts, which are less than 1 mm in diameter and do not appear to enlarge. They do not seem to affect the function of the organ. Small or misshapen testes can sometimes be seen in successfully breeding birds.

Shrunken, fibrotic gonads can be found in both sexes, and seem to affect the function of the gonads, since these birds generally show poor breeding results.

Hermaphrodites are very rarely encountered in birds. The author has seen one bird with one testicle and an ovary which showed constant feather picking and self-mutilation.

Some pathological findings are not directly associated with the gonads but can nevertheless affect breeding results – for example, opaque air sac membranes with or without plaques, and the presence of plaques on the surface of non-gonadal structures. These findings are not always significant for breeding, especially when no adhesions are visible. However, if the plaques or granulomata are large and adhere to the gonads or surrounding structures, the female's ability to ovulate may be disturbed. The oocyst may be hindered in entering the infundibulum of the oviduct because the opening is physically closed by adhesions. Similar lesions are not believed to affect the ability of males to breed.

Another abnormality frequently seen is the enlargement of the spleen. This organ is normally no more than 1 cm in diameter in large psittacine birds, and is bright red in colour. An obvious enlargement in size or change in colour to an intense red can be caused by a systemic infection. Psittacosis should always be considered as a differential diagnosis in such cases, especially in a newly

imported bird. Multiple white urate deposits of about 1 mm in diameter may be detected in the kidney. In most cases these are not linked with clinical or functional pathological symptoms.

### ***Complications and errors***

Haemorrhage is the most frequently encountered problem, preventing adequate viewing of the viscera. When a small amount of blood covers the lens of the endoscope, it can be cleaned by blotting the tip gently against an intraabdominal organ or by withdrawing the instrument and rinsing the tip with sterile water. If bleeding persists, the procedure should be discontinued and repeated another day.

Fat or air sacculitis can also restrict the view. Obese birds frequently have large amounts of abdominal fat that can partially cover the gonads or other organs or limit the space in which to manoeuvre the endoscope. Tachypnea occurs from time to time in extremely excited birds, during initial anaesthetic induction or throughout the entire laparoscopy. Excessive ventilation through the air sacs causes the loosely attached digestive organs to move rapidly, making it difficult to position the endoscope properly. Altered anatomy, as found in neoplastic diseases of the kidneys, liver or spleen, can cause lesions during the procedure as well as obstructing the operator's view.

As well as the risk of complications originating from the bird, possible iatrogenic errors should also be considered. One of the most common errors is to confuse an immature female with a male. The young female ovary looks more like a piece of fat and is flattened with indistinct edges. It usually has sulci on its surface. A testicle is smooth with rounded ends. In the female, the supporting ligament of the infundibulum of the oviduct crosses the cranial portion of the kidney. This structure is absent in males. Furthermore, only one ovary but two testicles can be found. Therefore in young birds, if two gonads are visible, even though their shape may be relatively indistinct, the bird is most probably a male. Nevertheless, the operator should bear in mind that in young psittacines the remnant of the right ovary may be

visible for at least several months after weaning. It sometimes appears cylindrical and smooth like a testicle.

Another mistake is to confuse a section of intestine with a testicle. A loop of intestine can appear round, smooth and white or yellow, and may lie directly at the cranial pole of the left kidney. Its extent may not be initially apparent.

## Explorative laparotomy

Explorative laparotomy is a form of abdominal surgery carried out for diagnostic purposes. Since it is invasive, this procedure constitutes a high risk for the patient. It should therefore only be performed if all other non-invasive methods have proved ineffective.

Radiography plays an important role within the spectrum of non-invasive diagnostic methods. It can help to determine the position of the organs within the bird's abdomen, especially when performed with contrast media. Ultrasound examination probably represents the greatest opportunity for limiting the indications for explorative laparotomy. If the patient is not in an emergency condition, haematology, blood chemistry and microbiological examination of cloacal and crop swabs should also be performed before deciding to carry out an explorative laparotomy. These can provide important information regarding the state of the patient's immune system and the presence of infectious agents. Endoscopic examination should also be mentioned here. Although this is an invasive procedure, it is considered to carry a lower risk for the patient than conservative surgery. The disadvantages of endoscopy are that it requires anaesthesia, and that laparoscopy may reveal a cause of disease that can only be treated by laparotomy. The advantage lies in the opportunity to have a direct look at the viscera within the abdominal cavity through a very small incision with a minimum of tissue damage.

## Presurgical considerations

Before explorative laparotomy, presurgical considerations should include taking a quiet 5 minutes in order to collect all of the patient's

findings. It is worth making sure that no fact has been overlooked up to this point. An experienced avian practitioner will decide very carefully whether to perform an explorative laparotomy – more carefully than a less experienced colleague who has not yet been in the frustrating situation of doing an explorative laparotomy without finding the solution to the bird's problem! Having decided to perform the surgery, a sixth quiet minute is useful to consider what to look for and what to expect in the bird's abdomen. A planned operation leads to a faster and more successful procedure, which is important for the bird's prognosis.

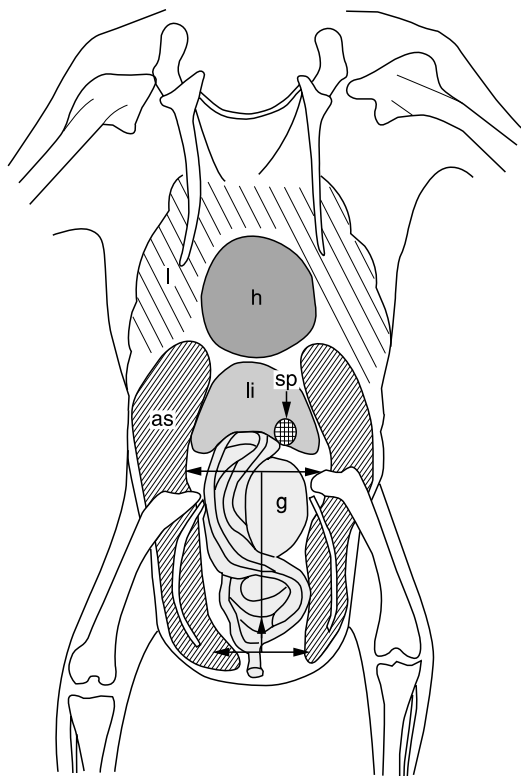
The patient should be given enough time to recover from the journey to the surgery. If a process of bacterial inflammation is presumed, antibiotics should be given before surgery.

As in endoscopy, the anaesthetic gas of choice is isoflurane. For a laparotomy, the use of an anaesthetic agent with good relaxing qualities is advisable, since it is better to perform surgery in a relaxed abdomen than in a tense one. A relaxed bird also uses less energy. This is an important fact, since patients have often not eaten regularly for several days.

## Surgical procedure

The patient should be positioned with the cranial part of the body elevated at approximately 40° to prevent irrigation fluids from flowing cranially and entering the respiratory tract if the air sacs are opened. For the same reason, the fluid should be removed from the abdominal cavity of patients with ascites prior to opening the air sacs.

The means of entry to the avian abdomen include the ventral midline, the left lateral and the transversal approaches. Midline celiotomy or laparoscopy is used for surgery of the small intestine, for egg-binding and egg-related peritonitis, and to reach diffuse abdominal masses (Figure 4.15). It allows access to both sides of the coelomic cavity. The skin incision is made along the linea alba from the sternum to the interpubic space. It must be incised carefully, because the duodenum crosses from left to right just inside the body wall and a loop of the intestine can be pressed between



**Figure 4.15** Incision for the ventral midline approach used for laparotomy: as = thoracic and abdominal air sac region; g = gizzard; h = heart; l = lung; li = liver; sp = spleen.

the bird's peritoneum and underlying tissue. In small birds, such empty loops are hardly visible and can easily be cut during the incision. In most cases, the safest method is to initiate the incision between the pubic bones over the cloaca. Once an abdominal opening of a few millimetres has been made, the incision can be extended cranially to the level of the sternum.

If the view is limited, the incision can be extended to one or to both sides. The cranial extension is made by a sideways incision approximately 5 mm from the sternal border. The incision is extended caudally along one or both sides of the pubic bones in a similar manner (Figure 4.15). The left lateral celiotomy provides the best exposure of the proventriculus, the ventriculus, the spleen, the female reproductive tract and the left kidney. With the patient in right lateral recumbency, the caudal border of the sternum can be palpated. The pelvic bones, especially the

cranial part of the pubis, should be identified, and the left leg should be pulled as far caudally as possible. The skin incision reaches from the cranial part of the pubis to just dorsal of the uncinat process of the fifth or sixth rib. The branch of the superficial medial femoral artery and vein coursing over the lumbar fossa toward the pubis should be ligated prior to incising the musculature, and the intercostal vessels passing along the cranial border of the last ribs should be ligated or coagulated. In small birds, transection of the ribs may not be required to get a sufficient survey of the bird's abdominal cavity. After having incised the musculature of the abdominal wall, a small retractor should be positioned to maintain retraction of the body wall. The air sacs are then opened and crossed in order to reach the coelomic cavity. The intestines are fragile and should not be manipulated with toothed instruments, which can easily cause severe contusions and potential perforation.

For the transverse celiotomy, the patient is positioned in dorsal recumbency. A transverse incision is made centrally between the sternum and cloaca. It is more difficult to extend the incision in this approach than in the ventral midline approach. The body wall is closed using simple synthetic monofilament absorbable suture material. Skin closure is performed routinely.

## References

- BUSH, M., MONTALI, R. I., NOVAK, R. G. and JAMES, F. A. (1976). The healing of avian fractures – a histological xero-radiographic study. *Am. Animal Hosp. Assoc. J.*, **12**(6), 768.
- KRAUTWALD-JUNGHANNS, M. E., SCHULZ, M., HAGENER, D. *et al.* (1995). Transcoelomic two-dimensional echocardiography in the avian patient. *J. Avian Med. Surg.*, **9**(1), 19–31.

## Suggested reading

- BENNETT, R. A. and HARRISON, G. J. (1994). Soft tissue surgery. In: *Avian Medicine: Principles and Application* (B. W. Ritchie, G. J. Harrison and L. R. Harrison, eds), pp. 1096–36. Wingers.
- ENDERS, F., KRAUTWALD-JUNGHANNS, M. E. and DUEHR, D. (1993). Sonographic evaluation of liver diseases in birds. In: *Proceedings of 1993 European Conference on Avian Medicine and Surgery*, pp. 155–63.

- INGRAM, I. A. (1990). Proventricular foreign body mimicking proventricular dilatation in an umbrella cockatoo. *Proceedings AAV Meeting*, published by Association of Avian Veterinarians, pp. 314–15. Phoenix, Arizona.
- KRAUTWALD-JUNGHANNS, M. E., RIEDEL, U. and NEUMANN, W. (1991). Diagnostic use of ultrasonography in birds. *Proceedings AAV Meeting*, published by Association of Avian Veterinarians, p. 269. Chicago, Illinois.
- KRAUTWALD-JUNGHANNS, M. E., TELLHELM, B., HUMMEL, G. H. *et al.* (1992). *Atlas of Radiographic Anatomy and Diagnosis of Cage Birds*. Paul Parey Company.
- MCDONALD, S. E. (1996). Endoscopy. In: *Diseases of Cage and Aviary Birds* (W. Roskopf and R. Woerpel, eds), pp. 699–717. Williams & Wilkins.
- MCMILLAN, M. (1994). Imaging techniques. In: *Avian Medicine: Principles and Application* (B. W. Ritchie, G. J. Harrison and L. R. Harrison, eds), pp. 246–61. Wingers.
- MURPHY, J. P., KOBLIK, P., STEIN, G. and PENNINGCK, D. (1986). Psittacine skull radiography. *Proceedings AAV Meeting*, published by Association of Avian Veterinarians, p. 81. Miami, Florida.
- ROSSKOPF, W. J. and WOERPEL, R. W. (1996). Soft tissue surgery. In: *Diseases of Cage and Aviary Birds* (W. Roskopf and R. Woerpel, eds), pp. 675–93. Williams & Wilkins.
- RUEBEL, A., ISENBÜGEL, E. and WOLVEKAMP, P. (1991). *Atlas der Röntgendiagnostik bei Heimtieren*. Schlütersche Buchhandlung.
- SILVERMAN, S. (1980). Avian radiographic technique and interpretation. In: *Current Veterinary Therapy VII* (R. W. Kirk, ed.), p. 649. W. B. Saunders.
- TAYLOR, M. (1990). Endoscopy. *Proceedings AAV Meeting*, published by Association of Avian Veterinarians, pp. 319–24. Phoenix, Arizona.
- TAYLOR, M. (1994). Endoscopic examination and biopsy techniques. In: *Avian Medicine: Principles and Application* (B. W. Ritchie, G. J. Harrison and L. R. Harrison, eds), pp. 327–47. Wingers.



# Nursing the sick bird

*Gerry M. Dorrestein*

## Introduction

Many avian patients require emergency treatment and critical care. They accept our care and love, or tolerate it, and may welcome us into their lives. At the same time, companion birds are reluctant to reveal their frailties, 'hiding' their ailments until they are unable to compensate any longer. If veterinarians are to care for these patients, they must be prepared for emergency and critical cases (Jenkins, 1994).

Live birds are generally presented to a veterinary practice in one of three conditions; healthy (or apparently so), injured or ill. Often the injured bird can be specifically treated with emphasis on the injury while supportive measures are initiated. The sick patient requires an approach that addresses immediate medical needs and at the same time investigates the nature of the illness; therein lies the greatest challenge in avian medicine (Harris, 1994). The advances in medical equipment and diagnostics have allowed the avian veterinarian greater opportunities to treat the critical avian patient properly (Loudis and Sutherland-Smith, 1994). All drugs, supplies and equipment should be preassembled at a central location to facilitate their application (Murray, 1994).

## Environmental requirements

Much of the equipment needed to accommodate sick birds is available in the average companion animal practice. In order to transform a traditional small animal clinic into an 'avian friendly' clinic, a number of modifications should be considered. A separate avian waiting room would be ideal, but if that is not possible an area that is not in direct contact

with dogs, cats and children should be designated for bulky bird enclosures and carriers (Johnson-Delaney, 1994).

Admitting a sick bird to the veterinary hospital for intensive care has many advantages and few disadvantages (Coles, 1996a).

Advantages of hospitalization include the following:

- 1 The bird is under the direct observation of the veterinary surgeon and his/her experienced staff, and its condition can be monitored
- 2 The bird receives regular therapy if necessary
- 3 Immediate action can be taken if the bird's condition deteriorates
- 4 The veterinary surgeon has time to think about the case, to carry out any necessary laboratory tests, etc., and to reconsider the differential diagnosis list
- 5 The bird can be kept in a controlled microclimate under optimal conditions during its recovery
- 6 Birds are usually by nature members of a flock, and the sight of other hospitalized birds often has a beneficial psychological effect
- 7 Many owners are totally unable to medicate their birds or give the supplementary feeding required.

Disadvantages of hospitalization include the following:

- 1 The bird is in unfamiliar surroundings with an unfamiliar routine; this may increase stress and the bird may be less willing to eat
- 2 There may be a strong bond between the owner and the bird; this is broken and may increase stress
- 3 The owner is often prepared to give the bird 24-hour tender loving care; however, an

overanxious owner may cause more stress to an already sick bird

- 4 There is a risk of infection to other patients and to members of staff.


## Housing of the sick bird

Appropriate enclosures for avian patients are a necessity. Severely ill birds or those requiring more intensive treatment, including tube feeding, fluid therapy, nebulization therapy, oxygen supplementation or monitoring, are hospitalized (Figure 5.1, 5.2) (Rupley, 1997).

The success of treating a critical avian patient relies very heavily on the environment in which the bird must recover (Loudis and Sutherland-Smith, 1994). A separate avian housing area that can be maintained at 25–30°C is preferable but not essential. Avian enclosures should be easily viewed from across the room or through a window, thereby minimizing the need to approach the enclosure in order to evaluate a patient. The staff member who feeds, cleans and interacts with the birds should preferably be different from the person who provides 'threatening' medical treatment. The bird is less likely to be defensive around a non-threatening person, and a more accurate assessment of changes in its daily condition can be made (Johnson-Delaney, 1994).

A simple warming cage can be made using a glass aquarium with a screened cover, a heating pad and a 60W bulb in a utility fixture. Aquariums are relatively inexpensive and easy to clean and disinfect. Screen-covered tops provide good ventilation, while the aquariums themselves hold heat and reduce hospital contamination from discarded food and droppings. They offer complete visibility and easy access to the patient (Johnson-Delaney, 1994; Jenkins, 1997a). Instead of the light bulb, an Elstein infrared element can be used. The main advantage with this is that there is no light, only heat. A 24-hour visible light may interfere with the day–night rhythm of the bird, inducing a hormonal disturbance that can result in moulting and/or influence other hormones in many bird species.

Both the floor and air temperature should be monitored to ensure that the patient is not burned or overheated. A simple indoor/outdoor thermometer placed inside the cage will provide both readings and, when equipped with a maximum/minimum reading, a permanent record of the temperature range during the day and night will be available. Clean towels or surgical drapes can be used to cover portions of the aquarium in order to reduce heat loss and allow the bird a more private convalescent area. The temperature of the floor of the aquarium may be further



**Figure 5.1** An infant nebulizer and a sealed container typically make up an avian nebulizing unit.



**Figure 5.2** A simple warming plate and oxygen chamber used to treat critical patients.

modified by layering towels between the heating pad and the glass.

Avian isolation units, as seen in more specialized hospitals, are easily built, complete with separate heat and ventilation for each 'cage'. When the inside floor area is at least 50 × 50 cm, the average parrot cage (without the bottom part) can easily be fitted inside. Underpressured ventilation prevents spread of airborne diseases inside the hospital area. A heating system (e.g. Elstein bulbs of 100 W) can be mounted under a stainless steel bottom plate that supports the inside cage, with a removable perch (PVC) placed over newspaper or brown wrapping paper as bottom cover (Figure 5.3).

Keeping the patient in a cage inside the 'hospital unit' has the advantage that cleaning the enclosure and transporting the bird is possible without catching the bird; also, most of the companion birds are used to being housed in such cages. Food and water can be provided in hard plastic containers fitted at perch height, so there is easy access to the container for the bird.

For extremely ill birds, low perches can be constructed from PVC pipe. This material is easy to clean and disinfect. To prevent foot and leg problems from long-term perching (longer than 2 weeks), the diameter of the perch should be modified to fit the grasp of the patient's foot. The perch should be

wrapped with a layer of self-adherent bandage material to improve traction. The bandage material is changed when dirty and between patients.

Existing small animal kennels can be converted by installing a removable perch and covering the bottom of the kennel with paper. Heating pads or clamp-lamps provide supplemental heat, and towels, plastic wrap, acryl or Plexiglas® sheets can be placed over the front of the enclosure to retain heat. Enclosure doors should be removed, scrubbed and soaked in disinfectant after each bird. Spraying a light coat of Pam® cooking oil or silicone on the bars will facilitate the removal of excrement (Johnson-Delaney, 1994).

Intensive care units are essential for critically ill patients or birds recovering from severe surgery. Many commercial intensive care units are available, and each has advantages and disadvantages. These units ideally can supply controllable heat, humidity and oxygen (Figure 5.4). A dehydrated bird cannot regulate hypothermic and hyperthermic challenges, due to lack of control of evaporative heat loss and poor tissue perfusion. The incubator must also provide moisture because dry heat will increase fluid loss in the avian patient. Many commercial units are designed to provide heat and oxygen, without regard to humidity. Although the exact levels have not been researched, it is




**Figure 5.3** A parrot hospitalization unit with underpressure air system on top, heating unit with thermostat in the bottom, and grey glass doors for quietness and observation.

suggested that a relatively humid environment (50–80 per cent humidity) within the intensive care unit is beneficial. In the dyspnoeic bird presenting with open-mouthed breathing, uncontrolled water loss can contribute greatly to further dehydration and hypovolaemia (Whittow, 1986). A simple and practical method of providing heat and humidity is to place a pan of hot water covered by a rubber grill inside the intensive care unit. The bird is placed on the grill, allowing the mild steam to envelop its body (Harris, 1994). The patient should be visible through a door or wall of the incubator, and there should be a port through which oxygen and fluids can be administered.

### Preventing the spread of diseases

Many avian pathogens can spread through aerosol and feather particulates, and an efficient ventilation system of laminar flow design will minimize hospital contamination. Air filtration systems (purifiers) designed to decrease particulates and pathogens to the 0.1–1.0  $\mu\text{m}$  range are recommended for use in the housing area as well as in the reception, examination and treatment areas. In initial



**Figure 5.4** An avian veterinarian intensive care unit that regulates temperature and humidity.

hospital design, areas with separate airflow systems should be incorporated to allow for separation of patients requiring routine care from those that may have infectious diseases. Hospital suites for housing sick birds should be divided into small, easily cleaned areas that also have separate ventilation systems (Figure 5.3).

All materials used on avian patients should be thoroughly cleaned and disinfected between patients. It should be stressed that all disinfectants are toxic and must be handled with care to prevent problems both in the hospital premises and in patients. Birds, in most cases, are more sensitive to environmental toxins than dogs or cats are. Good ventilation is important when using any disinfectant, and instruments, utensils and surfaces must be thoroughly rinsed and dried before coming in contact with patients again.

The order in which hospitalized avian patients should be maintained follows the same pattern as with other animals: clean, feed, and treat; beginning with the healthiest and ending with the most highly contagious and critically ill. Any bird within the hospital that is sick for an unconfirmed reason should be considered highly contagious until proven otherwise. When working with a patient with a highly contagious disease or a suspected zoonosis, it is advisable for the attendant to wear a mask and hospital gown that can be readily changed. In these cases, attendants should also use a disinfectant spray on their clothing and hair between birds. Hospital counters, shelves and tables should be wiped down with disinfectant after each use (Johnson-Delaney, 1994).

## Equipment

Special equipment needed to practice avian medicine is minimal. Many small animal practices already have isoflurane anaesthesia capabilities (mandatory for an avian practice), ophthalmic-sized surgical instruments and suture materials, an endoscope (2.7 mm diameter or less), a binocular microscope with oil immersion capability, a radiosurgery unit and radiographic equipment.

Laboratory equipment, such as a centrifuge, a haemocytometre and a biochemistry testing system, must be present, or the clinician must



**Figure 5.5** A digital gram scale is one of the most important pieces of equipment in an avian practice.

have access to a quick laboratory service near the practice.

A gram scale with an accuracy of  $\pm 1$  g is necessary to calculate correct dosages and monitor patients' weight changes (Figure 5.5). Both mechanical and electronic scales work well, but electronic scales are recommended. Electronic units that have an automatic tare feature are easiest and fastest to use. Scales can be fitted with perches or a container for ease of weighing avian patients. A clear, transparent, lightweight plastic box (such as a bread bin) or a container (such as a weight-box) can be used to facilitate weighing and allows observation of the patient.

Additional equipment should include a variety of syringes (including low dose insulin syringes), small hypodermic needles, spinal needles, small butterfly catheters, avian mouth speculae, gavage needles, small cuffed and Cole endotracheal tubes, and a radiographic positioner (a Plexiglas® positioning board). A quick-staining kit for smears and cytology should be available in the outpatient laboratory. Bandaging and splinting supplies, protective collars and dental acrylics for orthopaedics and beak repair are also necessary in the general avian practice.

Other equipment required for patient maintenance includes heavy ceramic, stainless steel, hard plastic or crockery feeding and drinking containers that fit to the hospital cages, and a variety of perches that can be easily cleaned and disinfected. It is important that hospital perches be made of non-porous material such as heavy plastic or PVC.

## Mental support

The intelligence and attitude of avian patients demands special attention. The hospitalized patient undergoes changes due to stress, and these can delay healing and inhibit proper immunological response. Stress can involve many factors, and the following help in reducing it (Loudis and Sutherland-Smith, 1994):

- 1 Avoid handling the bird more than necessary
- 2 If possible, allow recovery to continue at home or in familiar surroundings
- 3 The cage mate of the patient may be brought to the hospital if the clinician can determine that the new bird will not be harmed or cause harm to the patient
- 4 Avoid 'high traffic' areas, where the bird will be exposed to unfamiliar people, pets and possible predators such as snake and cat patients
- 5 Respect the diurnal cycle of the patient and try to maintain a 12-hour light cycle
- 6 Consider sounds and smell as well as sight; encourage clients to bring a familiar toy or perch to the hospital
- 7 Barking, bird calls and predator odour can be distractions to the recovering patients.

## Feeding

The success of emergency therapy is largely dependent on the long-term management of the recovered patient. Partial or complete anorexia is a prominent feature of many diseases, occurring at a time when the sick bird often has increased nutritional requirements and can least afford an inadequate feed intake. The nutritional management of debilitated avian patients can be the most frustrating component of a case (Loudis and Sutherland-Smith, 1994). The route, composition and frequency of feeding must be considered, especially if the patient has primary gastrointestinal disease. For a quick overview, see Appendices 5.1 and 5.2 to this chapter. Iatrogenic complications can also occur, including trauma to the force-fed patient, bacterial and/or yeast ingluvitis, and osmotic diarrhoea.

Provision of small quantities of highly palatable food at frequent intervals is often helpful in restoring the appetite of a sick or recovering bird. Familiar foods should be offered, and clients encouraged to bring in the patient's regular food. Clients will often help to feed the bird if it is hospitalized, because the patients are often more responsive to their owners.

Prevention or treatment of inappetence is an important facet of therapeutics that is often neglected. Several agents are commonly used to promote appetite in mammals, although no definitive evidence is available to prove their worth in either mammals or birds. Vitamin B supplementation, corticosteroids and anabolic steroids have been advocated as appetite stimulants, but they may simply make the animal feel better rather than having any specific action to stimulate the appetite.

In mammals, inappetence is a prominent and early feature of zinc deficiency; this element is necessary for normal taste acuity, and the response to zinc supplementation is often excellent (Jenkins, 1997a).

During tube feeding, daily attempts should be made to help regain the normal eating habits of the patient. Familiar foods should be left with the patient, or offered by the staff or client on a regular basis.

## Liquefied diets and force-feeding

Composition of supportive formulae is a matter of individual preference. Different bird species require different food types. Psittacine patients will fare well on a number of commercial avian dietary and paediatric formulae. Human diets used for enteral feeding can also be used, and have good caloric value and appreciable fat content (Quesenberry *et al.*, 1991). Maintaining or increasing body weight during recovery is the main supportive goal after the first emergency is over (Appendices 5.2 and 5.3). A safe volume of formula for feeding directly into the crop is roughly 3–5 per cent of the bird's normal body weight (Quesenberry and Hillyer, 1994).

A variety of commercial products have been developed in an attempt to provide an easy-to-use diet for sick birds (Plate 7). These products, as well as home-made diets, must be evaluated for use in a given situation. The

calorific value of foods can be estimated by calculating 4.49 kcal/g of protein, 4.09 kcal/g of carbohydrate and 9.29 kcal/g of fat. Not all of this energy will be used; the actual amount available for metabolism is influenced by the digestibility of the specific ingredients, the amount lost through urination and defaecation, and the temperature of the environment (Quesenberry *et al.*, 1991).

Once an efficient diet has been selected, the caloric requirement of the patient – basal metabolic rate (BMR) plus maintenance requirement (MER) – may be calculated through allometric scaling (Appendices 5.2 and 5.4). The MER may be 1.3–7.2 times the BMR, while ill birds may require up to 1.5 times the MER. All situations where force-feeding is necessary require a diet that is easy to administer, highly digestible and contains sufficient energy.

Birds that do not drink must have fluid supplementation (Appendix 5.5), and the maximum suggested volumes and frequencies are presented in Appendices 5.3 and 5.6. However, even when a bird does not drink, fresh water (without additives) must always be available. For an illustrative case, see Box 5.1.

The following therapeutic agents can be added to the semi-liquid diet used for crop feeding (Coles, 1996a):

- 1 Methylcellulose or ispaghula husk may help to slow down the gastrointestinal transit time. Also, this product may absorb enterotoxins
- 2 Lactulose is another product that may help to absorb enterotoxins, but it has a mild laxative action.

Various foodstuffs can also be homogenized with a blender. For parrots, blending fruits and vegetables with peanut butter for calories will facilitate gavage. Bottled pureed baby food can be used, but keeping these products fresh may be a problem (Coles, 1996a). Pelleted diets can be fine-ground and mixed with water or electrolyte solutions, and Columbiformes, Gruiformes and Galliformes will do well with blended pelleted feeds. Water should be added to provide the desired consistency. Ratites can be fed a gruel of pellets or blended dog food (Honnas *et al.*, 1993). Carnivorous water birds can be force-fed whole prey, and if regurgitation occurs a liquefied fish formula can be pre-

pared. Raptors can often be force-fed parts of whole prey, and canned feline diet and raptor meat products can be made into a liquid diet although delicacy items such as skinned young mice and chicks may be preferred. Insectivores can be fed cereal or insect gruels or dog food for a short period of time. Nectivores should be fed a 15–20 per cent dextrose solution if found down, and switched to their regular nectar substitute when hospitalized. Nectivores generally do not handle large volumes well, so a fine needle feeding tube should be used for gavage or the bird offered the food on the end of a small syringe.

Frequency of feeding is variable depending on each case, and the total daily requirement is divided into an equal number of daily feedings (Loudis and Sutherland-Smith, 1994).

### **Gavage or tube feeding (oral alimentation)**

Nutritional support is most commonly provided via tube feeding. Contraindications to tube feeding include crop stasis, ileus, gastrointestinal impaction, or other gastrointestinal abnormalities that do not allow the passage of ingesta or nutrient absorption (Rupley, 1997).

For gavage feeding, curved ball-tipped metal feeding tubes are good choices for psittacine patients. The tube can be inserted near the left commissure of the beak, sliding the tube over the tongue toward the right side of the bird's neck and gently into the crop without causing beak trauma. The crop should be palpated to verify that the tube or the feeding needle is in the correct place (Plate 8). The neck is maintained in extension while the food is injected to deter regurgitation.

For waterfowl and passerines, plastic or size 14 French red rubber feeding tubes are recommended, and metal speculums are rarely needed. The relative absence of the crop in many passerines demands using smaller, softer feeding tubes.

When crop gavage is not desirable due to stasis or trauma, a red rubber feeding tube can be passed directly into the proventriculus and small boluses of supplement administered. Extreme caution should be taken with this procedure because the distal oesophagus and

**Box 5.1 Causes with gavage treatment**

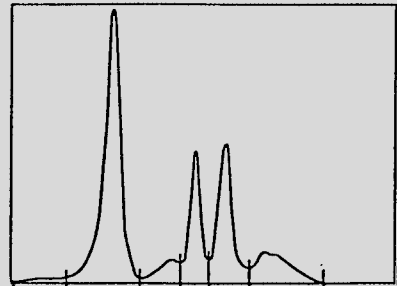
A 400 g African grey parrot, 23 years old, easy to handle, is debilitated, eating very little and approximately 5 per cent dehydrated because of diarrhoea

**Faecal smear:** Gram-neg rods (+++) and yeasts (+)  
**Blood results:**

Ht	0.39	TP	15 g/l
WBC	14.0	A/G ratio	0.87
Lymfo's	16%	Ca	1.91 mmol/l
Leuco's	84%	P	2.05 mmol/l

**Preliminary diagnosis:**

Multideficient bird with secondary intestinal bacterial and yeast infection (hypoproteinaemia, hypocalcaemia, slight anaemia, elevated WBC with left shift).



Protein electrophoresis

**Treatment:**

- Starting directly after blood collection: 0.3 ml i.m. multivitamins (vitamin A = 15 000 IU/kg)
- Gavage feeding with antibiotic, antimycotic and protein supplementation
  - Amoxicillin-clavulanic acid 50 mg/kg PO q8h 0.4 ml q8h  
(synulox® (Pfizer) oral suspension: amoxicillin 40 mg/ml, clav acid 10 mg/ml)
  - Amphotericin B 5–10 mg/kg PO q8h 1 gtt q8h  
(Fungizone® (Bristo–Myers Squibb) oral suspension 1 mg/ml)
  - **Fluid requirement**  
50 ml/kg/day = 20 ml/day  
+ 5% dehydration = 20 ml
 

D1	20 ml + 10 ml = 30 ml	10.0 ml q8h
D2/3	20 ml + 5 ml = 25 ml	12.5 ml q12h
  - Fluids as extra amino acids: Aminoplasmol 10%® 400 kcal/l  
caloric value D1 30.0 × 0.4 = 12.9 kcal/day plus 3.0 g protein  
D2/3 25.0 × 0.4 = 10.0 kcal/day plus 2.5 g protein
  - **Caloric requirement**  
MER = (1.5) BMR = 1.5 × 39.2 = 58.8 kccal/day  
Nutrilon Soya® (5.1 kcal/g)
 

D1	(58.8 – 12.9)/5.1 = 9.1 g/day	3.0 g q8h
D2/3	(58.8 – 10.0)/5.1 = 9.6 g/day	4.8 g q12h
- R/D1 Nutrilon Soya® (approximately 3/4 measure spoon) 3.0 g  
 Aminoplasmol 10%® 10.0 ml  
 Synulox® oral suspension 0.4 ml  
 Fungizone® oral suspension 1 gtt
- S: As gavage q8h for 1 day
- After the blood results indicated a hypocalcaemia, the gavage was supplemented q24h with calcitriologum 0.025 µg/kg (Rocaltrol® (Roche)) and CA<sup>++</sup> 50 mg/kg (calcium-Sandoz® forte) for 5 days.

proventriculus are thin-walled and rupture will occur with overfeeding or improper tube placement.

Before fluids or food are administered via oral gavage the crop should be palpated, and if food is present in the crop, tube feeding should be deferred (Rupley, 1997). Tube feeds are preferably fed warmed to prevent delayed

crop emptying. The bird should be weighed before tube feeding, and any other procedures performed at this stage because restraint after tube feeding may result in regurgitation and aspiration. If food refluxes into the oral cavity during the procedure, the bird should be released and allowed to clear its mouth on its own.



## Oesophagostomy

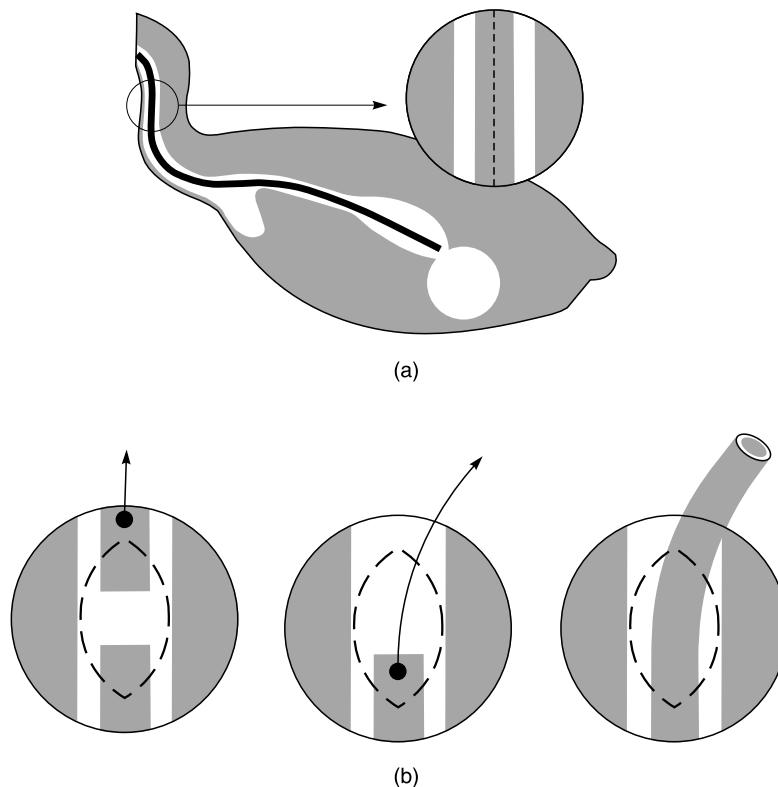
Certain situations require that the crop is bypassed and food deposited directly into the proventriculus or beyond. This can be done with a tube via the mouth into the proventriculus. However, babies suffering from crop burns or those with refractory crop dysfunction, and birds with severe beak injuries, benefit greatly from an indwelling proventricular feeding tube installed via the oesophagus (Bennett and Harrison, 1994; Altman, 1997). To perform this procedure, a size 14 French red rubber feeding tube is passed down the oesophagus of an anaesthetized bird, manipulated through the crop and into the thoracic oesophagus and inserted to the proventriculus, where resistance is felt. A 2–3 cm longitudinal incision is then made on the right side of the neck over the feeding tube, which can be identified within the oesophagus (Figure 5.6). The tube is isolated through the incision and transected, the oral end is removed completely, and the proven-

tricular end is extracted 2–3 cm from the incision.

A 1×5 cm strip of Elastikon® is then wrapped around the protruding end of the feeding tube, and it is sutured in place on the neck. If the incision is large it may be sutured, but suturing is not generally necessary. A male adapter plug can be used to cap the tube between the feedings. Such a device has been left in place for as long as 7 weeks without complications, and removal is accomplished simply by cutting the stay sutures and extracting the tube. Debridement and surgical closure of the wound is not necessary (Harris, 1997).

## Duodenostomy

In cases where it is desirable to bypass the entire upper gastrointestinal tract, an indwelling feeding tube can be installed directly into the ascending limb of the duodenum. For a more detailed description, the reader is



**Figure 5.6** Schematic diagram of an oesophagostomy.

referred to specialized books (Bennett and Harrison, 1994; Altman, 1997; Harris, 1997).

## Monitoring

It is essential to monitoring a patient to follow progress and assess the effects of treatment; monitoring also provides information regarding adapting the treatment if necessary. Record keeping is essential for evaluation, and also for future reference. Progress may be assessed by observation and clinical signs but, when the status of the patient allows, serial monitoring of the packed cell volume (PCV), total protein (TP) and urine output, along with short-term evaluation of weight, will provide more reliable data.

## Record keeping

The (computerized) medical record system used in most small animal hospitals can be modified for avian patients. An admission form should be produced for each hospitalized bird, for daily assessment, containing the following information:

- 1 Name of the responsible veterinarian, the record code, date of hospitalization and reason for hospitalization
- 2 The name of the bird and of the owner
- 3 Identification of the patient – species, breed, colour, gender, weight on admission, age
- 4 Information regarding the owner – address, telephone number, fax number, etc. (means of contact)
- 5 Information about the referring veterinarian – name, address and phone number
- 6 Special remarks or warnings related to the patient
- 7 A summary of the history, initial examination, laboratory results and initial treatment
- 8 Estimate of the costs
- 9 (Preliminary) diagnosis and medical plan.

For daily assessment of the hospitalized bird's condition, the following information should be recorded on this admission form along with the staff member's signature and the date:

- 1 Food and water intake, dietary support
- 2 Droppings – quantity and appearance

- 3 Clinical observations
- 4 Medication – quantities and administration route
- 5 Medical operations.

During hospitalization, all findings and treatments should be added to the patient's record to keep track of progress, for future reference, and for preparing the bill.

A label or sticker should be attached to the hospital cage, with information identifying the patient, client and referring veterinarian. All items in use for the patient (such as drugs, special food, feeding tubes etc.) are best kept in a separate container marked with the patient's details. All personal belongings that do not go home and that have to be kept until the bird is discharged from the hospital should be labelled with the owner's name as well.

## Preliminary evaluation

To ascertain the patient's stability, meaningful information should be obtained from the owner and the bird observed on presentation. Although it may seem that a chronically ill bird might be closer to death than an acutely ill patient, the opposite is often true. Birds that display signs of illness for several days to weeks often compensate for their disease and consequently become stable. Those that develop serious clinical signs acutely may be seriously affected by the disease process (Harris, 1994).

Whatever the background information provided by the client, the clinician must observe the patient before attempting to handle it. This may seem straightforward, but it cannot be overemphasized that the bird's life may depend on this 'hands off' assessment. A thorough step-by-step visual examination provides preliminary information that minimizes the chances of unexpected deaths (Harris, 1994).

## Observation

When possible, the hospitalized bird should be observed from a distance. A bird will often appear more alert and responsive when approached, giving the illusion of wellness.

Observations made from a distance reveal the bird's condition and its clinical developments more accurately. A resting bird that displays open-mouth breathing, tail-bobbing, closed eyes and ruffling of the feathers will tolerate little (if any) stress. The same bird may perk up and seem less critical when examined closely. The patient's behaviour when noted from a distance may warn the clinician to proceed with caution. The bird that brightens when approached may be stronger than the one that continues to show significant signs, but a false sense of security may exist when an examiner fails to realize the ability of many avian species to mask signs of clinical illness (Harris, 1994).

After the bird is visually examined, it may be removed from the original cage or carrier for further evaluation. Any evidence of distress should prompt immediate release of the bird into a suitable intensive care unit. The physical examination, at this point, should focus on indicators of the patient's hydration, thermal condition, acute clinical signs, etc. In many situations it will be necessary to treat dehydration and hypothermia prior to further manipulations. Care must be taken not to over-handle the bird (Harris, 1994).

Once fluids have been administered, the patient may be placed in an intensive care unit that ideally supplies heat, humidity and oxygen.

A critically ill bird handled in the proper manner will often show clinical improvement within a short period of time – sometimes in less than an hour. At this time, the clinician may choose to examine the bird further, collect diagnostic samples, or implement further therapy.

After a bird has been observed from a distance, it may be examined more closely. Attention should be paid to the bird's response upon approach, the feed and water intake, the droppings and other (ab)normal signs such as blood, feather loss, etc.

All signs found at the initial physical examination, as well as new observations, must be assessed and recorded on the patient's hospitalization form. Based on the information that has been collected from physical examination, the clinician must decide whether to continue, adapt or modify the treatment protocol. It is also necessary to decide whether to:

- place the bird in (or release it from) a supportive intensive care chamber
- administer basic supportive treatment before proceeding further
- perform additional physical examinations, with or without collecting diagnostic samples
- discharge the patient as healthy or for further treatment at home.

Experience will fine-tune the clinician's ability to determine which route to follow.

## Laboratory monitoring

A blood sample should be taken from every sick hospitalized bird, preferably immediately after hospitalization and before taking any other tests or starting treatment. Using a heparinized syringe, a sample of 0.5 per cent of the body weight (or 2 ml from a parrot heavier than 400 g) will be sufficient for most routine tests. The surplus of plasma should be frozen and stored for additional biochemical tests or future reference. A CBC is useful for monitoring the patient's progress and response during therapy. When treating a metabolic acidosis, blood bicarbonate should be tested.

The progress or improvement of critical initial blood values should be monitored regularly after beginning treatment.

Monitoring the patient's faecal material may aid in assessing treatment response. Faecal examination includes gross evaluation and direct and faecal parasite evaluations. Microscopic examination of a stained smear (cytology) is an easy and valuable technique for following the progress of lesions and the bacterial status of the intestines. In species without functional caeca (e.g. psittacines, pigeons and doves, and passerines), only a very small number of micro-organisms visible by staining are acceptable. Large numbers indicate poor hygiene, impaired gastric secretion, immunosuppression or bacterial enteritis. The effect of antibiotic treatments can easily be evaluated by looking at follow-up smears.

To help determine caloric intake, examination of droppings for faecal material will alert the clinician to the anorectic bird. Anorectic birds commonly have scant, slimy, dark green

faeces. Birds exhibiting these signs may require supplemental gavage feeding.

The urine in the droppings of normal birds is clear, and the urates white. An increase or decrease of urine or a change of colour is abnormal and should be assessed.

## Physical monitoring

### *Body temperature*

The average adult bird has a core body temperature of 38–42.5°C. Regulation of internal body temperature relies upon many factors – feather condition, adipose and muscle condition, hydration, food intake and respiration (Whittow, 1986). Wet, oil-fouled, destroyed or plucked feathers will cause greater heat loss through the skin. Poor body condition also hinders effective heat regulation. Dehydration will interfere with the evaporative heat loss system in birds, from the respiratory tract as well as from the skin. If capable, overheated birds will pant to help cool themselves.

Monitoring the body temperature directly is stressful and even dangerous if the patient is fractious or if a rigid thermometer is not handled carefully. A flexible temperature probe inserted in the cloaca in comatose birds allows a permanent monitoring of the body

temperature, which at this location is mostly 2–3°C lower than the internal core temperature. Overheating (as evidenced by panting) can become a problem if the patient is not monitored while in the intensive care unit.

### *Body weight*

Monitoring the body weight is a major concern in ill birds. Sick birds are often malnourished, anorectic and dehydrated. Avian patients should be weighed daily if possible, especially when tube feeding. Weights should be recorded at the same time every day, preferably in the morning or evening before feeding.

## Surgical nursing

The staff should make sure that all hospitalized birds have a clean cloaca if they are passing abnormal fluid droppings or have cloacitis. Some birds will irritate wounds or tear sutures, so patients should be monitored during hospitalization. A restraining collar (e.g. Elizabethan collar) may need to be fitted (Figure 5.7). A bird with an oesophagotomy tube or an auxiliary airway tube inserted should have the tubes kept clean and unblocked. If splints have been applied to a



**Figure 5.7** Special avian Elizabethan collars.

leg or wing, a careful watch should be made that the foot or wing tip does not become swollen. Birds should be kept on clean perches to prevent foot problems. The technicians should make a habit of examining the bird's droppings rather than just clearing them away, and should look for signs of blood, undigested seed or the occasional tapeworm segment, and note any changes in the normal colour or character of the droppings (Coles, 1996a).

## Fluid therapy

Fluid therapy is extremely important in the critical avian patient. Parenteral fluids will restore effective blood volume, normalize cardiac output and optimize tissue oxygenation. Most metabolic imbalances can be corrected with proper fluid therapy (Redig, 1984). An additional benefit is enhanced diuresis, which facilitates the elimination of toxic by-products and metabolites (e.g. urates). Deciding the route of administration depends on patient status and co-operation, fluid type and cost (Loudis and Sutherland-Smith, 1994). Oral and subcutaneous routes are inappropriate when dealing with critically ill patients. The routes of choice for a patient in shock are intravenous and intraosseous (Plate 9). Intraosseous catheters are less stressful than repeated venepuncture, and are the favoured route in cases of shock (Hernandez and Aguilar, 1994). Close monitoring of the avian patient is required during fluid administration to ensure tolerance of the process. Heart rate, respiration rate and overall condition must be monitored during the procedure (Redig, 1984).

Anaemia and hypoproteinaemia are common sequelae of aggressive fluid therapy (Redig, 1984). If the PCV falls to less than 10–20 per cent, a whole blood transfusion should be considered. When total plasma protein values fall below 15 g/l, the decreased plasma osmotic pressure will allow fluids into the interstitial space and pulmonary oedema and compromised organ function may follow (Hernandez and Aguilar, 1994). For calculation of the fluid requirement, see Dehydration and Appendix 5.5.

## Choice of fluids

Crystalloids are the initial fluids of choice in avian shock or dehydration because they are effective, easy to administer and inexpensive. In birds, only one-fourth of the total fluids administered remain in the vascular compartment 30 minutes after treatment. The circulatory benefits obtained from fluid therapy are transient, and additional fluid therapy is required (Appendix 5.5).

Lactated Ringer's solution (Hartmann's) is the favoured fluid because metabolic acidosis is present in most situations. Lactate is metabolized to bicarbonate by the liver. In severe acidotic states, lactated Ringer's solution should be supplemented with bicarbonate. Bicarbonate supplementation may be estimated by subtracting the blood bicarbonate value obtained from the 'normal' avian bicarbonate value as follows:

$$\begin{array}{l} \text{Bicarbonate} \\ \text{deficit} \\ \text{(mmol/l)} \end{array} = \begin{array}{l} 20 \text{ mmol/l} - \\ \text{blood bicarbonate (mmol/l)} \end{array}$$

$$\begin{array}{l} \text{Bicarbonate} \\ \text{dose} \\ \text{(mmol/l)} \end{array} = \frac{\text{deficit} \times \text{body weight (kg)}}{0.4}$$

Alternatively, when no means are available for determining blood bicarbonate, a dose of 1 mmol/kg can be given every 15–30 minutes to a maximum of 4 mmol/kg/day (Hernandez and Aguilar, 1994). The first dose should be given intravenously, followed by the remainder subcutaneously (Redig, 1984). Commercially available bicarbonate solutions include an 8.4 per cent solution containing 1 mmol/ml and a 1.4 per cent solution containing 0.17 mmol/ml. Calcium gluconate (50–100 mg/kg, administered slowly) as a cardioprotectant and glucose to facilitate the movement of potassium across cell membranes are advisable in cases of severe tissue injury, extreme catabolic state or severe renal impairment (hyperkalaemia). Lactated Ringer's solution does not contain enough potassium to aggravate such a situation (Redig, 1984).

Potassium chloride can be added to lactated Ringer's solution in cases of aggressive fluid therapy or persistent vomiting. The fluid therapy can be supplemented with a

potassium chloride solution (0.1–0.3 mmol/kg), to a maximum of 11 mmol/day.

Hypertonic saline (7.5 per cent) solution can be used as an adjunct to therapy to re-establish circulatory function. Its use should be followed by the administration of isotonic fluids. In mammals, a small volume (4–5 ml/kg) induces a rapid improvement in cardiovascular function as a result of osmotic expansion of the vasculature. Hypertonic saline is particularly useful in cases of hydropericardium, pulmonary oedema or increased intracranial pressure. Its use is contraindicated in dehydration, hypernatraemia and head trauma, because of the possibility of an intracranial haemorrhage.

### Colloids

Dextran is a polysaccharide of high molecular weight with a size similar to that of albumin. Their effect is similar to that of hypertonic saline, but with a longer half-life (approximately 24 hours). A dramatic improvement in birds in shock, using 6 per cent dextran administered at a rate of 10–20 ml/kg, was reported (Redig, 1984). Adverse effects include hypervolaemia, haemorrhagic diathesis and anaphylaxis.

Blood transfusions appear to be beneficial for birds with chronic anaemia for the purpose of stabilizing the bird while the cause of the anaemia is being pursued (Rupley, 1997). Birds with a PCV less than 20 per cent as a result of acute blood loss may benefit from a homologous blood transfusion (Dorrestein, 1997). Approximately 1 per cent of the donor bird's body weight in blood volume can be safely collected using a small-gauge butterfly catheter (anticoagulant citrate dextrose, 0.15 ml/ml blood). Following collection, the donor should be given an amount of saline or Ringer's solution, or an equivalent amount of colloid fluids, equal to one to three times the quantity of blood donated (Jenkins, 1997a). Transfusion of approximately 10–20 per cent of the calculated total blood volume of the recipient is usually ideal.

There is evidence that heterologous transfusion may be of no benefit (red blood survival is approximately 12 hours in some species), and homologous transfusions (with a red blood survival in pigeons of 7.1 days) may be of only limited benefit (Murray, 1994).

### Antibiotics

Antibiotics or steroids may be added to the fluids if indicated. If bacterial sepsis is suspected, antibiotics such as cefotaxime (40–80 mg/kg) or sodium amoxicillin (50–100 mg/kg) may be given directly either i.v. or via i.v. fluids. When adding drugs to the fluids, incompatibilities (precipitation of the solution) should be avoided. Amikacin or other aminoglycosides should be avoided in dehydrated birds. Laboratory samples for culturing should be collected before administration of antibiotics and antifungals whenever possible.

### Corticosteroids

In situations where the patient is possibly in shock, steroids may be indicated. Despite conflicting opinions concerning the efficacy of steroids in critical situations, they remain a viable choice in cases involving trauma, lead poisoning and central nervous system compromise (Hernandez and Aguilar, 1994). In emergencies, steroids with a rapid effect and a short half-life are preferred. Non-steroidal anti-inflammatory drugs (NSAIDs) may also be of benefit to the critical patient.

In a dose-response study in pigeons, dexamethasone proved to be the most potent glucocorticoid, resulting in the longest suppression of plasma corticosterone concentration. Following the highest dose of dexamethasone that was tested (0.5 mg/kg), plasma corticosterone concentrations were restored within 5 days, and within 48 hours following the highest doses of cortisol (15 mg/kg) and prednisolone (3.5 mg/kg). The lowest doses that resulted in suppression of the plasma corticosterone concentrations were 0.5 µg dexamethasone/kg, 15 µg cortisol/kg and 0.7 µg prednisolone/kg. Following these doses, plasma corticosterone concentrations were restored within 24 hours (Westerhof, *et al.*, 1994). It took 30–60 minutes before the onset of suppression of plasma cortisone concentration following 1 µg dexamethasone/kg, 30 µg cortisol/kg or 7 µg prednisolone/kg.

Of the non-steroidal anti-inflammatory drugs, ketoprofen, flunixin and carprofen can all be used at a dose rate of 2 mg/kg. However, they are all contraindicated when renal disease, hypotension or dehydration is

suspected, and they may occasionally cause vomiting. Carprofen probably has the least side effects of the NSAIDs previously mentioned (Coles, 1996a).

Adverse effects of glucocorticosteroids include severe immunosuppression, water and salt retention, delayed wound healing, adrenal insufficiency, hypertension, weakness, retarded growth and a decrease in the intestinal absorption of calcium. However, in most critical avian patients the benefits of administering glucocorticosteroids far outweigh the adverse effects.

## **Intravenous approach**

For any patient requiring moderate to heavy fluid supplementation (see dehydration) or serious cardiovascular support, intravenous fluid support is necessary. Fluids containing glucose may be of great benefit in anorectic patients. Long-term catheterization or short-term bolusing can be performed, but bolus therapy is not recommended for long-term support due to the fragility of avian veins.

The basilic (wing) vein is easy to access in all species, but it is fragile and injection usually results in the formation of a large haematoma at the administration site (Harris, 1997). This can be minimized by removing the needle from the vein but not the skin after fluid administration, and injecting a large volume of fluid subcutaneously. The fluid compression then lessens vascular leakage.

The medial metatarsal vein can be used most easily in long-legged species. The jugular vein can be accessed in most birds, but not easily in pigeons and doves.

Intravenous fluids may be administered in birds as a bolus at the fastest rate the needle will allow. The syringe and fluids should be warmed to approximately body temperature (37–39°C) prior to administration (Harris, 1994). Devices are available to keep fluids warm while they are being administered. Heating pads may be used to wrap the syringe on a syringe pump (Jenkins, 1997b).

### ***Syringe and infusion pumps***

The ability to administer intravenous or intraosseous fluids to a small patient over an extended period of time depends on equip-

ment that allows a very low rate of administration along with a high degree of safety and accuracy. Intravenous infusion pumps work well for infusion rates higher than 60–100 ml/hour. Syringe pumps allow infusion rates much lower than those of infusion pumps – it is possible to use a syringe pump to administer maintenance fluids to a budgerigar at 0.006–0.10 ml/hour via an intraosseous catheter (Jenkins, 1997b).

Appendix 5.5 advises how to calculate the fluid requirement in birds. Appendix 5.6 gives the maximum suggested volumes of fluids to be administered to psittacines as an initial i.v. bolus.

### ***Contraindications***

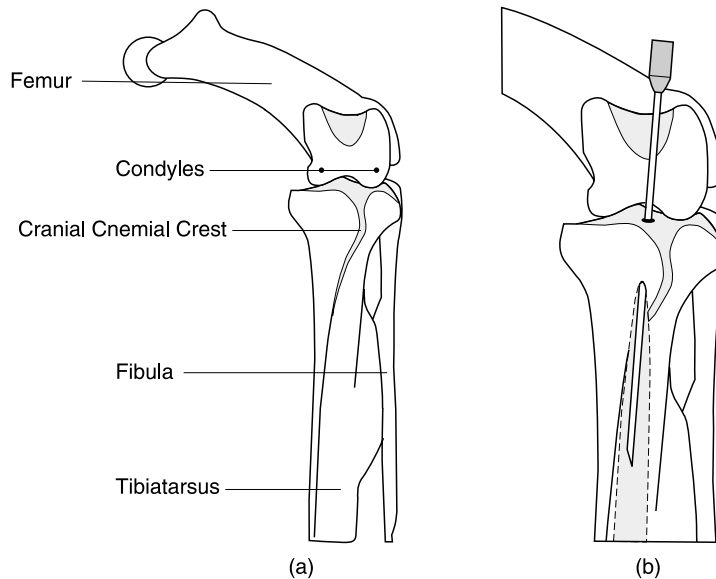
Contraindications to intravenous fluid support include diagnosis or history of coagulopathy, lack of equipment and technical skill, and self-inflicted trauma by the patient resulting in loss of catheter patency.

### ***Technique of intravenous jugular placement***

A 20-gauge, 25 mm Teflon over-the-needle i.v. catheter is required. The patient is placed in left lateral recumbency and the feathers over the right jugular vein parted. The skin is cleansed with a gentle surgical scrub and, in some species, feathers may have to be plucked. The head is grasped and the catheter threaded into the jugular vein; the vein may have to be held off proximally to aid in venous distension. It is important to place the catheter as near to the thoracic inlet as possible to avoid kinking when the neck is in normal flexion. Once blood is seen in the hub, the catheter is advanced fully into the vein. A male T-port adapter that has been filled with saline flush is applied, and the catheter is checked for patency and gently flushed (Figure 5.8). The catheter may be sutured to the neck or held in place by a non-constricting bandage.

## **Intraosseous approach**

The intraosseous route has proved to be a very effective and stable method of accessing the avian circulatory system. A 20–22-gauge, 35 mm spinal needle with a stylet (Monoject



**Figure 5.8** (a) and (b) Schematic diagram of intraosseous catheter placed into the proximal tibiotarsus.

spinal needle) is often used. If these are unavailable, 28–30-gauge wire may be placed inside the cannula to avoid occlusion of the needle by bone. For smaller birds, a 25-gauge needle may be used. Indications are the same as for intravenous therapy. The patient is usually anaesthetized, but the procedure can be performed with restraint and local anaesthesia. Aseptic technique is essential. The fluids should be administered slowly in order to avoid leakage (which will be minimal with careful technique) and pain (which can be significant with high pressure).

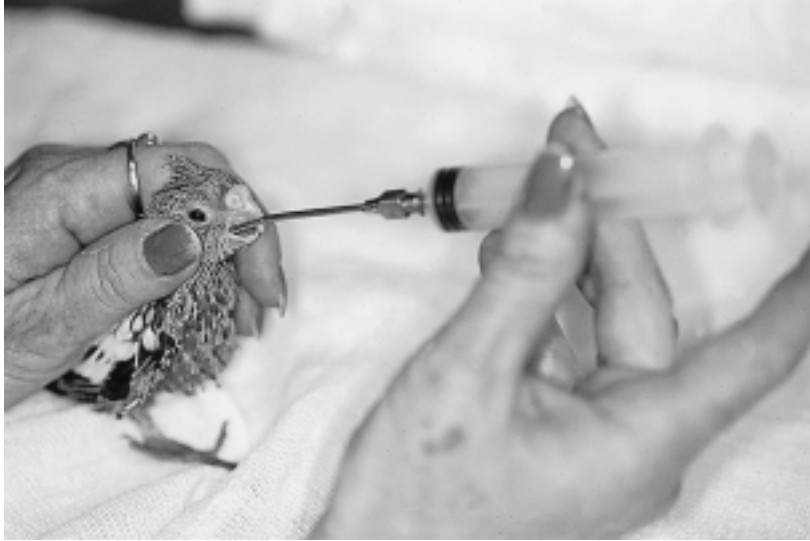#### ***Intraosseous catheterization of the ulna and tibiotarsus***

For catheterization of the distal ulna, the bird is placed in dorsal recumbency – although ventral recumbency or the standing position may be more beneficial in the severely compromised patient. The feathers over the carpus are plucked, and the area over the distal ulna is sterilized. The ulna is grasped in one hand as the needle is placed over the distal bony protuberance of the ulna, and the needle is directed parallel to the median plane of the ulna. The spinal needle is gently rotated to help facilitate its passage through

the cortex, and once the needle penetrates the cortex the needle can be directed further with less force. Resistance after entering the medullary cavity can indicate contact with cortical bone; if this happens, reposition the needle (Rupley, 1997). A taped butterfly can be used to help secure the catheter with a suture to the soft tissue of the distal ulna. A pre-flushed male T-port adapter is applied, and the wing wrapped in a figure-of-eight bandage. Care must be taken to avoid the ligaments of the carpus, which pass near the insertion point. These can often be visualized through the thin skin of the bird (Plate 9).

For catheterization of the proximal tibiotarsus, the patient is placed in dorsal recumbency. The area around the cnemial crest is plucked and prepped for asepsis, and towel-lining off the area helps to prevent contamination. The cranial cnemial crest is located and the tibiotarsus grasped with the other hand. The needle is directed parallel to the plane of the tibiotarsus, and slightly rotated with moderate pressure; it will slide in easily once the cortex is penetrated (Figure 5.8). A taped butterfly is applied and the pre-filled T-port connector is attached. Suture stabilization and light bandaging are warranted if the catheter is to remain *in situ* after surgery (Loudis and Sutherland-Smith, 1994).





**Figure 5.9** Medicating with a crop cannula.

### Subcutaneous approach

Subcutaneous fluid administration should be used only in cases of mild dehydration. Patients with circulatory compromise and under adverse environmental conditions will have reduced circulation through the vessels of the skin. Due to the paucity of vessels in bird skin, large volumes may not be readily absorbed from this site. The sites include the propretagium (wing-web), dorsally between the wings, the axilla and the inguinal fold (groin). Close association of the cervico-cephalic air sac system warrants avoidance of fluid administration to the neck area. Only isotonic fluids heated to body temperature should be used, in small increments (5–10 ml/kg/site) and via small needles (23–27 gauge).

### Abdominal approach

Warm, isotonic fluids can be given within the abdominal coelom. Because of the close anatomical association of the air sacs, this technique is not recommended. A ventral midline approach with a small (25–27) gauge catheter is used.

### Oral approach

If the patient is alert and active, oral alimentation is the route of choice. It is safe, effective and causes minimal stress. Contraindications include primary gastrointestinal disease (diseases causing vomiting or stasis), poor patient reflexes or recumbency (to avoid regurgitation and aspiration), and oral and upper gastrointestinal trauma. Offering unlimited water and foodstuffs high in water content is important. Oral fluid therapy can be accomplished with gavage tubes. Appendix 5.5 advises on calculating the fluid requirement in birds. In Appendices 5.3 and 5.6, the maximum suggested volumes of fluids and the frequency of gavage feeding are presented.

### Medication

Medication may be administered to birds orally (medicated water or food); by injection (intramuscular, intravenous, subcutaneous, intraosseous, intratracheal); topically; by nebulization; and as sinus and nasal flushes. Selection of the route of administration is based on the severity of infection, the number of birds to be treated, the ability of the owner to administer the medication, and the for-

mulation available. Parenteral administration of medication is suggested for critically ill birds. Birds maintained in flocks or aviaries are often treated with medicated food or water, but therapeutic drug concentrations are seldom achieved in companion and aviary birds (Rupley, 1997). Availability and absorption after oral administration are influenced by crop, crop flora, crop pH, gizzard function and morphology, the presence of grit, the form and function of the intestines, the presence of functional caeca, and the indigenous microflora (Dorrestein, 1997).

### Individual oral medication

Direct oral administration is difficult in psittacines because it is difficult to get them to open their mouths and some birds refuse to swallow medication, but this method is commonly used in pigeons, waterfowl and gallinaceous birds. Oral medication should not be used in critically ill birds.

#### *Tablets and capsules*

Many birds have a crop, which acts as a storage organ. The unpredictable emptying time of the crop, the lack of a large volume of fluid and the relative high pH mean that the crop cannot be compared with the mammalian stomach, resulting in unpredictable pharmacokinetic behaviour of the drug. However, administration into an empty crop improves the uniformity of the pharmacokinetics. The problem can be overcome by grinding the tablet, making a suspension and feeding it by crop cannula (Figure 5.9).

Coated tablets are of no use in birds with a muscular gizzard, which will destroy the coating and give hydrochloric acid and pepsin full access to the drug.

Capsules are good alternative dosage forms to tablets, and again are best administered into an empty crop. Capsules are especially useful for the treatment of individual birds. In psittacines this dosage form will be difficult to deliver because of the beak anatomy.

#### *Solutions and suspensions*

Solutions and suspensions are seldom used on a large scale for direct administration to birds.

A disadvantage of all liquid drug forms is that direct administration may result in regurgitation or inhalation, and part of the dose may be lost or aspiration pneumonia may occur. These preparations can be mixed with food or administered by gavage, especially in hand-fed baby birds or in sick birds requiring oral fluids and nutrients (Figure 5.9).

### Medication of feed or water

The major method of administering drugs to poultry and many other birds is via feed and water. This is largely for convenience and because of the difficulties associated with individual administration to large numbers of birds. However, for the majority of drugs water medication is unreliable for psittacines, passerines, pigeons and most other birds, and it should not be used except under specific circumstances.

Feed medication is a reliable way of administering drugs to companion birds, as long as the birds are still eating normally. The total intake of the drug with the food during the day should be equal to the desired daily dose calculated on an individual base. Crushed tablets, oral suspensions and powders can be mixed with moist foods. However, the interactions between a drug and food cannot be entirely predicted, and the energy content and palatability of the diet affect the amount consumed and therefore the dose of medicine ingested. The only proof of bioavailability is a pharmacokinetic study in various species. Because of the negative influence of calcium and magnesium on the bioavailability of tetracycline, grit-mineral administration has to be stopped during treatment. During egg production and breeding this can lead to nutrient deficiencies, resulting in soft-shelled eggs and rickets in the chicks.

A practical method of adding drugs to a grain mixture is by coating a moist food that is then added to the mixture. This method is often used for pigeons and backyard poultry. Pharmacologically, food medication can simulate a slow-release system, which provides decreased fluctuations in drug concentrations in tissues.

Medication in water is controversial in companion avian medicine, but is often considered the only practical means of drug

administration. It is the least stressful method for medicating birds, especially using drugs that are palatable. Theoretically, the bird will frequently self-dose during the day. However, studies in parrots, pigeons and chickens show that therapeutic blood levels for many drugs were not attained via the drinking water because of factors such as lack of acceptance, poor solubility and day length. Many birds refuse to drink water with an abnormal taste, and this may result in dehydration. As a guide, the volume of water consumed by the bird needs to contain the calculated daily dose in mg/kg body weight. Many drugs are stable for only a short time in water, which necessitates frequent changes.

While therapeutic blood levels may not be achieved with many drugs, levels in the intestine may be sufficient to control enteric infections. The use of medicated water can be valuable for reducing the spread of diseases that have arisen through contaminated water.

## Parenteral dosage forms

Parenteral administration is the most exact and effective method for administering drugs to companion birds. This route is used mainly in individual birds that are difficult to handle (like many psittacines), critically ill birds, or birds that are unconscious.

Intramuscular injection, especially in many psittacines, is often easier than oral administration (Rupley, 1997). A problem with intramuscular antibiotic usage on parrot patients is the short dosing intervals required with many products. An exception to this statement is treatment for chlamydiosis using doxycycline or long-acting oxytetracycline, because an injection will provide blood levels for almost 1 week. The parenteral preparations are most commonly administered into the pectoral or leg muscles. The venous plexus, which lies between the superficial and deep pectoral muscle, should not be punctured. A disadvantage is the relatively large volume that may have to be injected, and individual birds should therefore be carefully weighed and appropriate dilutions and syringes used for accurate dosing. General guidelines for maximum injection volumes in psittacines and small passerines include: macaw and cockatoo, 1 ml; Amazon and African grey, 0.8 ml;

cockatiel and small conures, 0.2 ml; and budgerigars, canaries and finches, 0.1 ml (Rupley, 1997). Repeated injections in the same side of the breast or the use of irritating drugs i.m. may result in muscle necrosis or atrophy. The i.m. injection of irritating formulations increases the creatine phosphokinase (CK) activity, the activity of alanine-aminotransferase (ASAT), and aspartate-aminotransferase (ALAT). Drugs administered in the posterior pectoral muscle or legs may pass through the renal portal system prior to entering the general circulation. Sympathetic stimulation tends to open the valves in the renal portal system, resulting in a direct flow of the blood from the caudal part of the bird to the vena cava caudalis.

Subcutaneous injections in the axillary area are often a preferable alternative when 'large' volumes are injected (Appendix 5.6). However, because of the minimal amounts of dermis and the low elasticity of the skin, part of the fluid may flow out and irritating drugs may cause skin necrosis and ulceration.

Intravenous injections should be reserved for emergencies and single dose drug administration. Haematomas are common when administering therapeutic agents i.v., and veins may also be needed for blood withdrawal for diagnostic tests. Intraosseous administration allows stable access to the intravascular space if repeated 'i.v.' drug administration is required.

## Other injection sites

Air spaces may be effectively reached by intratracheal or air sac injections. Joint injections, nasal flushes and infra-orbital sinus flushes and injections are other areas where direct application of drugs may be useful.

### *Intratracheal or air sac injections*

Intratracheal injections are a route for delivery of drugs to the lungs and airways of birds (Jenkins, 1997a). Volumes up to 2 ml/kg of water-soluble medication may be administered safely. A small-diameter metal feeding needle is used to administer the drug. The bird is restrained in a towel and the beak held open using a speculum or gauze loops. The medication is injected into

the trachea with some force, and the bird is then released and allowed to cough and clear its throat.

### ***Nasal and sinus flushes***

A nasal flush is often important in the successful treatment of infra-orbital sinus infections. Antibiotics or antifungals can be used in a lower dose than recommended for nebulization (Appendix 5.7). The bird is restrained and the head held lower than the body; the syringe is pressed against the nostril and the fluid is flushed into the sinuses, and the fluid exits via the opposite nostril and through the choana and mouth. Isotonic solutions and minimal pressure should be used (Figure 5.10). The amounts of fluids for nasal flushing are 1–3 ml for a budgerigar and up to 10–15 ml for a large macaw or cockatoo (Rupley, 1997; Jenkins, 1997a).

A sinus flush is used to deliver medication directly into the infra-orbital sinus for treatment of sinusitis. A sinus flush can also be used to dislodge exudate and foreign bodies from the sinuses, or to obtain samples for cytology, culture and sensitivity testing.

The bird is restrained with the head secured, and a needle inserted midway between the commissure of the beak and the medial canthus of the eye. The needle is

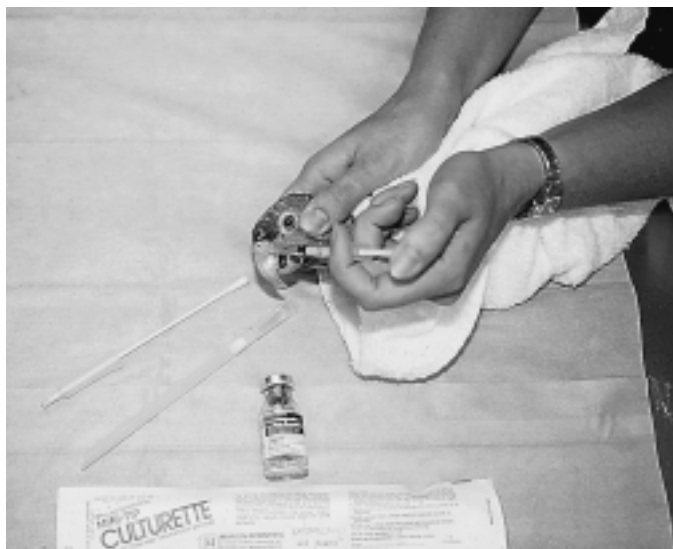directed under the zygomatic arch at a 45° angle to the side of the head. The sinus is more easily entered if the mouth is held open. Once the sinus has been entered, sterile water and an antibiotic or antifungal solution may be used for treatment of sinusitis. The same concentration can be used as recommended for a nasal flush (Appendix 5.7). Only non-irritating solutions should be injected (Rupley, 1997).

### **Topical medication**

Topical medications include skin applications, eye drops and ointments. External applications should be careful and sparing, because they will stick the feathers together and may be ingested when the bird preens, leading to toxicity. Topical corticosteroid ointments or combination ointments with antibiotics should never be used on avian patients. There have been numerous reports of avian patient death after application of a topical steroid ointment.

### **Nebulization**

Nebulization can be an important adjunct to the management of respiratory disease (Jenkins, 1997a). A particle size of less than 3 µm is



**Figure 5.10** Nasal flushing can be utilized for treating upper respiratory infections or obtaining samples for diagnosis.

required in order to have a local effect in the lungs and air sacs. Several inexpensive nebulization units are available (Acorn II nebulizer, Marquest Medical) that produce suspended particles in the size range of 0.5–6  $\mu\text{m}$  (Figure 5.1). Many commercial humidifiers and vaporizers do not produce particles this small. The parabronchi of birds range in size between 0.5 and 2 mm, and the air capillaries vary in size from 3–10  $\mu\text{m}$  in diameter. Because the avian lung differs from that of mammals in that the air capillaries are not dead-end saccules, nebulization therapy can be an effective treatment (Loudis and Sutherland-Smith, 1994). However, if there is considerable airway congestion or lack of flow, this form of treatment may not reach the tissues needing it the most.

Most intravenous antibiotics and some antifungal medications can be mixed with saline for nebulization. Nebulization should be initiated before culture and sensitivity tests are known, using a broad-spectrum antibiotic (Appendix 5.7), but the selection of antibiotics can be altered based on sensitivity testing. The patient should be nebulized for 10–30 minutes, two to four times daily, in conjunction with systemic therapy (Rupley, 1997).

## Basic emergency treatment

In non-emergency situations, laboratory and ancillary diagnostics are essential for establishing a diagnosis and determining appropriate treatment. Unfortunately, the delicate condition of a critically ill bird may prohibit the use of usual diagnostic protocols. Often the stress of sample collection or the time needed to process the samples is more than the patient can endure. Managing the case becomes a matter of careful, precise and efficient use of therapeutic and diagnostic options in order simultaneously to stabilize the patient and diagnose the disorder. Successful management depends on an accurate assessment of the severity of the patient's condition and the degree to which the patient will tolerate handling (Harris, 1994).

The goal of supportive therapy is to stabilize the patient until specific therapy can be established. Initially, therapy concentrates on correcting fluid deficits and hypothermia. As

the diagnosis is delineated, treatment becomes more focused. Supportive care may be withdrawn after the patient demonstrates a satisfactory degree of self-sufficiency. Successful management means providing aggressive support carefully, one step at a time.

## Medical management of the critically ill patient

Because it is frequently difficult to establish an accurate diagnosis, supportive care is an essential component of companion bird medicine. A checklist of supportive care is given in Appendix 5.1. Not all these steps should be applied at once or in the given sequence; it is better to move step by step, giving the bird time to react to each action and evaluating the effects! It is the practitioner's primary responsibility to assess 'how much is too much' with regard to critical patients.

A critically ill bird is defined as a patient that requires immediate medical attention (Harris, 1994). Such patients must be provided with some form of medical support either before or after diagnostic procedures, but definitely cannot wait days or even hours for test results prior to receiving crucial medical attention.

Before handling the bird for any reason, a detailed plan based on the findings of preliminary observations must be formulated. This plan must account for all the diagnostic and therapeutic actions warranted by the patient's condition while identifying the degree to which the bird is expected to tolerate handling. More delicate patients require greater care in handling. These birds, however, are the ones that need the most support. A difficult situation then exists, in which the patient needing most help is the one least capable of tolerating stress. The key to managing these birds is conservative progression – gently performing one manoeuvre at a time, prioritizing relative to estimated needs, then waiting for the clinical effect before proceeding. It is imperative that every detail of the diagnostic/therapeutic plan is anticipated and accounted for in advance. It could be fatal to remember a necessary item after the process has begun (Harris, 1994).

Specific supportive measures depend on actual needs; these may be estimated in

critically ill patients without background clinical data (see also Appendix 5.1).

Birds that are collapsed on the bottom of the cage, and/or have been ill for a long period of time, are probably severely dehydrated and hypothermic. A bird that collapsed within the previous hour or so may not suffer from either condition.

Dehydration can be assessed by closely observing the eyes and skin of the face and keel. The eyes may appear dull and dry, and the skin of the lower legs and feet may appear discoloured, withered and wrinkled. PCV, TP and WBC are useful tools in determining the patient's degree of dehydration and clinical status (Appendix 5.8).

In general, any bird presenting in critical condition due to illness (as opposed to injury) can be presumed to be at least 7–10 per cent dehydrated and acidotic; those that have been regurgitating may be alkalotic. The following signs will give an indication of the grade of dehydration:

- 1 A bird that is 5 per cent dehydrated will demonstrate brief tenting of the skin over the tarsometatarsus, face, or between the shoulders, dryness of the eyes and a dullness to the skin
- 2 At 10 per cent dehydration, the patient will show persistent tenting, mild hypothermia and thick oral secretions
- 3 At 15 per cent dehydration, the above signs will be seen plus profound weakness, tachycardia and collapse.

Fluids (at 37–39°C) may be administered via the jugular, basilic or medial metatarsal veins, or through an intraosseous catheter. If the patient is significantly dehydrated, the oral or subcutaneous approach may not be beneficial. Intraperitoneal approaches are not advised, and may be hazardous due to the risk of fluids entering the air sac system (Harris, 1994).

### **Hypothermia**

A bird that is fluffed and trembling on the perch or huddled on the cage bottom can be presumed to be hypothermic. This includes most avian patients in critical condition. A hypothermic bird will have a cold beak and feet, and often feels noticeably cool when handled.

Use of warmed i.v. fluids and a heated intensive care unit (25–30°C) will simultaneously elevate the core and peripheral body temperatures effectively. Overheating, especially with severe hypotension, may cause peripheral vasodilation; this may exacerbate the hypovolaemia, further lowering body core temperature, and may aggravate metabolic acidosis. It is important that the hypothermia is not attended to without recognition of the fluid needs (Harris, 1994).

Warm, moist air in an intensive care unit appears to reverse hypothermia safely and effectively, possibly because of its effect of reducing evaporation from the extensive internal respiratory surface area. Also, the drying tendency of oxygen (when used) is nullified. Monitoring hypothermia is a matter of clinical perception.

### **Circulatory condition**

The circulatory condition can be assessed by evaluating the turgidity of the basilic (median ulnar) vein as it crosses the ventral elbow. Circulatory collapse will be indicated by slower refilling of this vein after digital compression (it normally takes less than 0.5 s). A circulatory collapse needs direct attention (see Shock and Appendix 5.9).

### **Oxygen**

The administration of oxygen is often beneficial and is rarely contraindicated. A critical patient, especially one in shock, may suffer from diminished cardiac output. Providing oxygen maximizes the efficiency of the cardiorespiratory system. If the bird is dyspnoeic for any reason, oxygen is recommended. Over-oxygenating the patient prior to handling may also decrease the risk of handling (Harris, 1994).

When possible, it is best to humidify and warm the oxygen before delivery to the patient. This is best accomplished by bubbling the gas through warmed isotonic or half-strength saline solution (Harris, 1997). Methods of oxygen supplementation include using an oxygen chamber (Figure 5.2)/cage or direct delivery via a face mask. A 30–40 per cent oxygen saturation is recommended when using an oxygen cage for prolonged oxygen therapy. A flow rate of 50 ml/kg/min will

provide the same oxygen saturation with a face mask (Hernandez and Aguilar, 1994). One hundred per cent oxygen may be used for periods up to 12 hours, but this has been shown to be toxic within 3–4 days. Additionally, carbon dioxide levels should be maintained at a level less than 1.5 per cent by the use of a CO<sub>2</sub> absorber or maintained adequate gas flow rates to flush out accumulating carbon dioxide (Murray, 1994).

### **Continued care**

Once the patient has begun to stabilize, it may be possible to use routine handling methods. Supportive care should never be abruptly stopped, but diagnostic procedures may be initiated to establish a diagnosis for instituting more specific therapy. Fluid therapy should be continued (or hydration monitored) for 3–4 days to be sure that the deficit is fully corrected and the patient has re-established a normal maintenance intake. Supplemental heat is usually not necessary for adult birds once they have stabilized, and oxygen is only needed where specifically indicated. Caloric and nutritional support is a major consideration once the bird has stabilized. It is not practical in avian medicine to supply a bird's total nutritional needs parenterally, and oral alimentation is therefore necessary as soon as the patient's status allows if spontaneous food intake is absent.

## **Specific conditions and treatments**

### **Hypocalcaemia syndrome in African grey parrots**

Hypocalcaemia is most common in African grey parrots, but it may also occur in other psittacines and raptors. The aetiology is uncertain; however, affected birds are often on diets deficient in calcium, phosphorus or vitamin D<sub>3</sub> or with an inappropriate Ca:P ratio (all-seed diets). In African grey parrots, skeletal mineralization often appears normal with hypocalcaemia. Clinical signs include seizures, ataxia, opisthotonos, weakness or tetany.

Diagnosis is based on history, clinical signs, low blood calcium levels and response to calcium therapy. Blood calcium levels below 1.8 mmol (N = 2.1–2.9 mmol) may result in clinical signs.

After an initial blood sample has been submitted, parenteral administration of 10 per cent calcium gluconate, 0.5–2.0 ml/kg (50–200 mg/kg calcium), preferably slowly and intravenously, will control seizures. This enables the diagnosis to be confirmed retrospectively, and facilitates subsequent monitoring of any dietary changes and supplementation. Diazepam (0.6–1.5 mg/kg i.m.) will help to control the convulsions (Coles, 1996a; Jenkins, 1997b). Hydration must be maintained and corticosteroids should not be used in these patients. The bird should be given a proper diet, and calcium and vitamin D<sub>3</sub> supplementation provided (see Box 5.1).

### **Cardiopulmonary arrest**

The prognosis following respiratory and cardiac arrest varies according to the cause. Patients that arrest due to an isoflurane anaesthetic overdose or acute illness (e.g. acute tracheal obstruction) often respond well to cardiopulmonary resuscitation (CPR), but those that arrest during a chronic illness rarely do so (Rupley, 1997).

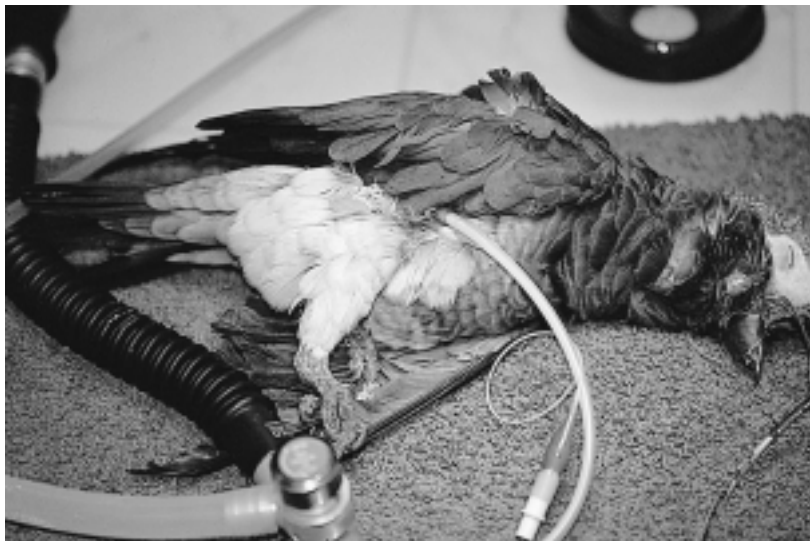The same basic rules of resuscitation apply to birds as in mammals. Most birds can be easily intubated. A speculum may be needed to hold the beak open if the bird arouses. If an obvious upper airway obstruction is found or there is tracheal damage, air sac tubing should be performed. An open anaesthesia circuit should be used to deliver 100 per cent oxygen, and the anaesthesia system designed to allow the operator good control in delivery of positive pressure ventilation (a rate of once every 4–5 s). Care must be taken not to overinflate the bird, as rupturing of air sacs can occur. Respiratory assistance via the operator's mouth to the endotracheal tube is not recommended due to the zoonotic potential of some avian diseases (e.g. campylobacter, psittacosis, TB). If needed, unidirectional respiration can be attempted by increasing the air flow through the trachea and allowing the gas to escape through an air sac breathing tube, or *vice versa* (Figure 5.11).

Cardiac and pulmonary auscultation can be performed during assisted respiration. If time permits, an electrocardiogram can be established; however, measurements are difficult to obtain if the patient is small or moving. In critical cases, quick access to the circulatory system should be made (see fluid therapy). If there is no heart beat or peripheral pulse, firm and rapid compressions of the sternum should be started, ventilation continued and epinephrine (0.5–1.0 mg/kg i.m., i.v., i.o.) and atropine (0.5 mg/kg i.m., s.c., i.v., i.o., i.t.) administered. Epinephrine and atropine can be given intravenously, followed by a bolus of saline or sterile water to encourage transport of the drugs to the heart. Intratracheal administration, through the tracheal wall into the lumen, is often the easiest route in arrested birds (Rupley, 1997). Doxapram (20 mg/kg i.m., i.v., i.o. or dropped on the tongue) and sodium bicarbonate (5 mmol/kg i.v., i.o., once) are also used in birds in situations of cardiopulmonary resuscitation (see Appendix 5.10) (Carpenter *et al.*, 1996). Although it is not likely that direct pressure has an effect on the heart itself, changes in the blood pressure and cardiac output can be made by altering the intrapulmonic and abdominal pressures (Loudis and Sutherland-Smith, 1994).

## Respiratory disease

The majority of critical avian patients present with respiratory disease. After administering oxygen or establishing an airway and providing adequate ventilation, the bird's respiratory tract must be evaluated (Jenkins, 1997b). It is important to differentiate between upper airway, pulmonary and air sac disease. A thorough oral examination is necessary to ensure that the oral cavity and larynx are clear of debris, abscesses or other discharges. The rate and pattern of breathing, as well as the patient's stance and character of breathing (tail pumping, etc.) can help to differentiate. Auscultation of many areas can also help; the head and neck should be auscultated as well as the trachea. Lung sounds can best be heard on the dorsal aspect of the body beneath the wing, and abdominal placement of the stethoscope may help in the localization of air sac disease.

Pulmonary disease can be difficult to differentiate from air sac and tracheal disease. If the condition of the patient permits, auscultation and radiology may be helpful to localize the pathology. Laparoscopy is a useful procedure for the culture and biopsy of respiratory disease. Oxygen and humidity are important



**Figure 5.11** The placement of an air sac breathing tube is helpful to maintain airflow during surgical procedures involving the head area and/or tracheal obstructions.



factors, as mentioned before. Therapeutic strategies for respiratory disease include systemic treatment and/or aerosol therapy (nebulization).

### ***Air sac breathing tube***

The physiology of the avian respiration is complex, and the unique respiratory anatomy of birds has allowed us to treat airway disease with unique methods. The placement of the air sac breathing tube is extremely helpful in the management of upper airway obstructions and surgery. It is very important to have a definite diagnosis of upper airway obstruction; pulmonary parenchymal disease can resemble airway obstruction, and air sac cannulation has little effect with parenchymal disease.

The procedure can be performed in the awake bird, but anaesthesia is highly recommended when time permits (Figure 5.11).

The patient is placed in right lateral recumbency, and the tube is most often inserted into the left abdominal or caudal thoracic air sac because of its relatively greater size (Jenkins, 1997a). Feathers are removed from the stifle to the vent, and from the ventral midline to the ischium. The independent leg is gently stretched cranially (Loudis and Sutherland-Smith, 1994), or is flexed and abducted to expose the last rib (Harris, 1997). After cleaning and disinfecting the skin, a small incision is made caudal to the tight muscle, midway down the thigh. Using a sterile haemostat, blunt dissection is directed medially and cranially into the coelom. The breathing tube can be installed into the caudal thoracic air sac, just dorsal to the caudal edge of the pectoral muscle. The breathing tube can be fashioned from a red rubber feeding tube and a tape butterfly, or a strip of Elastikon may be used to help facilitate attachment. Small (3 mm inside diameter) cuffed endotracheal tubes can be adjusted (Harris, 1997). The tube is gently guided through the incision, and airflow should be felt and heard at this time. Patency can be tested by holding a microscopic slide at the tube opening to observe for breathing-induced fogging (Harris, 1997). If the tube is inserted too deeply, it may press against the lung or an abdominal organ. The tube is

anchored to the skin with small non-absorbable sutures (Loudis and Sutherland-Smith, 1994).

If inhalation anaesthesia is used, the air sac tube should be attached to the circuit so the bird will remain anaesthetized. Careful attention should be paid to the flow rate, because air sac and pulmonary damage may occur if the bird is overinflated. The oxygen flow should be started at 0.5–1.0 l/kg body weight per minute, and the patient's breathing and appearance of the anaesthesia rebreathing bag closely observed.

Air sac cannulae have been left in place for more than 7 days, but the clinician should be aware of complications arising from this procedure, including abdominal organ damage, secondary bacterial infections and inadvertent occlusion of the breathing tube. The normal filtration devices of the nasal passage are absent, and a direct pathway to the pulmonary tissue is present. The incubator should be kept clean and free of faeces and debris. During normal respiration, a large amount of water loss is regained in the nasal conchae; therefore, a high amount of fluid replenishment should be administered while the cannula is in place.

On removal of the cannula, the abdominal muscles and the skin are surgically closed; in some cases, these have been left to heal by second intention.

## **Shock**

Although shock has not been clearly defined in birds, several debilitated birds in a shock-like state are often seen in practice. Shock is defined as a state in which, regardless of the cause, inadequate distribution of systemic blood flow causes diminished delivery of oxygen and nutrients to tissues (Hernandez and Aguilar, 1994). The classification of shock by aetiology includes haemorrhagic, cardiogenic, traumatic, septic and anaphylactic syndromes. Because the ultimate result of these states is circulatory compromise, shock is more aptly classified functionally, according to its haemodynamic effects, as hypovolaemic, cardiogenic or vasogenic.

Hypovolaemic shock is caused by a decrease of circulating blood volume due

to haemorrhage or, indirectly, fluid losses secondary to vomiting, diarrhoea or polyuria. There is evidence to support the statement that haemorrhagic shock does not occur in birds (Sturkie and Griminger, 1986; Murray, 1994). Hypovolaemic shock is frequently accompanied by a significant degree of dehydration and (especially after vomiting and diarrhoea) with acid–base imbalances.

Cardiogenic shock is the result of impaired cardiac function and a decrease in cardiac output. This is often associated with the administration of certain anaesthetics and drugs.

Vasogenic shock is more often associated with sepsis, endotoxaemia and toxicosis.

Regardless of the cause, the ultimate result of shock is a circulatory compromise. This may be evidenced as follows:

- 1 Poor capillary refill time in a weak, depressed bird with a rapid, weak peripheral pulse (Murray, 1994). The normal refill time for the basilic vein is less than 0.5 s (Quesenberry and Hillyer, 1994).
- 2 Dehydration. The degree of dehydration is estimated based on clinical signs and baseline blood samples – PCV, TP and WBC (Appendix 5.8). The buffy coat can give a rough quick estimate of the total leucocyte count.
- 3 Metabolic acidosis. The measurement of plasma bicarbonate is the most practical means of characterizing metabolic acidosis in birds (Redig, 1984). ‘Normal’ avian bicarbonate is 20 mmol/l.
- 4 High uric acid values, which are common in severely ill patients. Hyperuricaemia occurs as a result of either renal failure or accelerated tissue metabolism.
- 5 Plasma glucose levels, which may vary on a case by case basis.
- 6 Hyperkalaemia (a common cause of bradycardia and cardiac arrhythmias) or hypokalaemia and hyponatraemia (in cases of profuse vomiting or diarrhoea).

The recommended steps for treating birds with shock are given in Appendix 5.9. Because hypotension and hypoxaemia are detrimental, restoring effective blood volume and pressure and improving tissue oxygenation are immediate therapeutic requirements in the treatment of shock.

## Trauma

The avian practitioner may encounter a variety of clinical presentations associated with the avian trauma patient. An understanding of the physiological response to trauma and the therapeutic means necessary to control inappropriate compensatory mechanisms is critically important in successful management of trauma cases (Murray, 1994). As with all animals (including humans), it is important to initiate therapy of the traumatized avian patient within the ‘golden period’. This is defined as the period of time following the injury during which appropriate therapy will result in the most satisfactory outcome (Jenkins, 1997b).

Central to the concept of trauma management is hospital preparedness. All drugs, supplies and equipment should be pre-assembled in a central area such as the anaesthetic induction area (Appendix 5.10). Generic drug dosage charts for the most commonly encountered species should be prepared and readily accessible. Such charts should contain precalculated volumes of drugs to be administered, including fluids, corticosteroids, diuretics, analeptics and antibiotics. Effective and complete hospital and staff preparation before the presentation of the avian trauma case is important in the management of the patient during the first few hours following injury.

In the trauma patient, despite the condition of the bird presented, a thorough and complete physical examination is critically important (Murray, 1994). Before handling the injured bird, the attitude and posture should be noted. Injuries to the appendicular skeleton are often more readily identified with the bird in its cage or standing on the examination table. The exact order and technique of examination is a matter of clinical preference, but the clinician should not overlook a complete ophthalmic examination. Cases of suspected head trauma should be subjected to a thorough neurological examination (Bennett, 1994; Williams, 1994). The diagnosis of shock is often difficult. Clinical evidence of shock mandates immediate and aggressive therapy (Appendix 5.9). Although the clinician is encouraged to perform a complete and thorough examination on all trauma cases presented, such examination should, of course, be accomplished within the

limits of the patient. Additionally, clinicians must be aware of the possibility of pretrauma disease in these patients (Murray, 1994).

### **Control of haemorrhage**

One of the first priorities in the therapeutic management of the trauma patient is the control of haemorrhage (Murray, 1994):

- 1 Damage to developing feathers can result in active haemorrhage. The feather should be removed, taking care to hold the surrounding skin, and direct pressure applied. Should the haemorrhage continue, judicious surgical glue (Superglue®) should be applied to the distal part of the follicle. Chemical or electrocautery should not be used, as they can result in permanent follicle damage.
- 2 Haemorrhage from horny structures, such as the beak and claws, is typically controlled with chemical cautery using such as ferric chloride, ferric subsulphate or silver nitrate, talc or wound powder, or even flour or radiosurgery (Coles, 1996a).
- 3 For soft tissue wounds with haemorrhage, direct pressure is the treatment of choice. In refractory cases, the use of bipolar radiosurgery on individual vessels or the use of tissue glue may be required. Chemical cautery agents should be avoided because of tremendous local tissue necrosis and a subsequent inflammatory reaction.

Quantification of the degree of blood loss may be quite difficult. In general, a bird can easily tolerate a loss of 30 per cent of its blood volume, which is approximately equivalent to 2 per cent of its body weight. As a result of the rapid movement of the interstitial fluid into the vascular compartment, the PCV tends not to stabilize for 24 hours (Quesenberry and Hillyer, 1994). Therefore, this parameter should not be used for diagnosis or prognosis until 24–48 hours after the blood loss.

Blood transfusions, either heterologous or homologous, may be required in cases of severe blood loss. However, generally the bird benefits most from the volume expansion accomplished with fluid therapy (Appendices 5.5, 5.9 and 5.11). Of particular

importance is the delivery of the fluid directly into the vascular network via the intravenous or intraosseous route. Oral or subcutaneous routes are of limited value in the traumatized patient (Murray, 1994).

In cases of respiratory compromise, physical restraint should be limited and oxygen used during handling.

The trauma patient should be housed in quiet and warm surroundings within the veterinary facility. Antimicrobials may be indicated in infected wounds or in those cases where the clinician anticipates a secondary immunosuppression resulting from the stress associated with prolonged hospitalization.

### **Blood loss**

Blood volume (cells and plasma) in birds ranges from 4.5 per cent of the body weight in ostriches to 9.2 per cent in pigeons (Jenkins, 1997b). In response to blood loss, baroreceptor and catecholamine-induced arteriolar vasoconstriction tend to maintain normal blood pressure and adequate perfusion of vital organs, and this process is aided by movement of interstitial fluid into vascular spaces. The efficiency of these processes makes birds substantially more tolerant of blood loss than mammals (Murray, 1994).

### **Stress**

Trauma is obviously quite stressful to the bird, and this stress results in the release of catecholamines (noradrenaline and dopamine). There are documented differences between birds and mammals in their response to catecholamines; however, the catecholamine release has several profound effects, all of which are directed at the patient's preservation. These include:

- 1 Elevation of the heart rate and peripheral arteriolar vasoconstriction to maintain adequate perfusion of the heart, brains and lungs.
- 2 A hyperglycaemic effect – therefore, most traumatized birds will have normal to elevated blood glucose levels, alleviating the need for supplemental glucose administration (Quesenberry and Hillyer, 1994).

- 3 Raising the pain threshold, which may cause complications in relatively simple injuries during the struggle associated with the 'fight or flight' response.

### **Pain and analgesia**

Pain is almost certainly a physiological response to trauma. Unfortunately, the typically stoical nature of most avian patients precludes clinical recognition of pain or distress in all but the most serious injuries. Other than the previously mentioned effects of catecholamines on the pain threshold, most of the changes associated with pain are probably associated with recovery and rehabilitation from the traumatic injury. During the recovery phase, pain may preclude normal food and water consumption. Additionally, pain may prevent normal function of injured regions of the body, thus delaying recovery and return to normal use.

Most analgesic drugs and dosages have been extrapolated from non-avian species:

- 1 Butorphanol tartrate (Torbugesic®) 3–4 mg/kg i.m. has shown much clinical promise (Murray, 1994; Paul-Murphy, 1997). Other authors have recommended a dose of 0.5–2.0 mg/kg i.m. (Jenkins, 1997b). It has little effect on the cardiovascular function of budgerigars, but may result in slight motor deficits.
- 2 Flunixin meglumine (Banamine®) appears to be safe at 1–5 (10) mg/kg i.m. (Jenkins, 1997b); however, its analgesic effects are, at this point, uncertain. Flunixin may cause regurgitation following administration.
- 3 Buprenorphine hydrochloride (Buprenex®) at a dose of 0.1–0.5 mg/kg i.m. was considered ineffective (Paul-Murphy, 1997). Recent studies showed a good analgesic effect at a dose of 0.5 mg/kg QID in pigeons (Gaggermeir *et al.*, 2000).
- 4 Acetylsalicylic acid may provide analgesia; however, its use is limited to the oral route (325 mg/l water). This route of administration may be of limited use in the traumatic patient.

### **Commonly encountered traumatic injuries**

#### **Beak injury**

Beak injuries are generally caused as a result of aggressive bird-to-bird interaction. The

primary goals of the repair are to restore the beak to normal function and appearance and to preserve and protect the soft tissue and osteoid underlying structures present in both the rhinotheca and gnathotheca. To do this, the clinician should be familiar with the normal anatomy and growth patterns of the beak of the species involved.

During the initial examination of a traumatized beak, the extent and severity of the beak injury should be examined as well as the function of the various articulations between the beak and the skull. The age of the injury is important, because older wounds are likely to be contaminated. Under no circumstances should definitive repair be attempted in infected traumatic beak injuries (Murray, 1994). Following examination and the patient's stabilization, repair of the beak injury may be initiated. In most cases judicious use of general anaesthesia is indicated, using an air sac tube, to facilitate the repair process. Bulky face masks and endotracheal tubes are difficult to work around at the operative site. Basic wound treatment should be applied, cleansing and debriding the wound. Heavily infected wounds should be allowed to heal by second intention prior to applying a semi-permanent cyanoacrylate patch.

A modified 'wet-to-dry' bandage has proved quite beneficial in infected beak injuries. The wound should be gently flushed with a sterile saline solution, and sterile gauze sponges of an appropriate size used to pack the defect. Following moistening with sterile saline or diluted chlorhexidine (0.05 per cent), the wound is then covered with a semi-occlusive dressing (Tegaderm®, 3M) which is changed every 12–24 hours as indicated by the discharge and debris that adheres to the gauze.

Systemic antibiotics are indicated to protect the surrounding vascular network and dermis from bacterial infection. Wounds treated in this manner tend to granulate quickly, allowing definitive treatment with a cyanoacrylate patch (Murray, 1994). The manufacturer's instructions should be followed when applying a cyanoacrylate patch.

Most traumatic beak injuries heal nicely, with a return to normal function. During the rehabilitation period, birds should be monitored closely to assure adequate caloric intake.

### Lacerations

Treatment of lacerations depends upon the site and age of the injury. As in all animals, infected or contaminated injuries should not be closed until these aspects have been addressed. Radical surgical debridement is not practical in most avian wounds. In most cases the use of a series of wet-to-dry bandages, as previously described, facilitates granulation tissue formation. Wounds may then be allowed to heal by secondary intention, or a delayed secondary closure may be used. An exception to this conservative approach may be necessary when vital structures are exposed by the laceration. If at all possible, an early attempt at closure should be made to protect viscera, large vessels, tendons and joints. If primary closure is not practical, bandaging techniques that preclude tissue desiccation and infection should be used (Murray, 1994).

Suture selection is generally dependent upon clinicians' preferences. Surprisingly, most birds are very tolerant of skin sutures, and restraint devices are generally not required.

Any injury or suspected injury that occurs as the result of an interaction between a bird and a dog or cat should be addressed as an emergency. Not only are these predators capable of inducing serious crushing and internal injuries, but the presence of *Pasteurella multocida* within the oral cavity may contaminate wounds. The use of betalactams is always indicated, and is typically continued for 14 days post-injury.

### Contusions

Serious muscle contusions frequently occur as a result of wall or window crashing. Such injuries may result in skeletal, CNS or visceral damage. Affected birds should be treated as for any bird suffering blood loss – i.e. fluids, heat and, potentially, corticosteroids.

Another frequent contusion presented to the avian practitioner is that suffered by a bird during a 'panic attack' within its cage. Affected appendages are swollen, painful, and contain various amounts of subcutaneous blood. Following the administration of appropriate supportive care, such injuries should be addressed to protect the skin and soft tissues of the wings. A self-adhering semi-occlusive

bandage should be applied in a sandwich fashion with the wing in between two layers of material, and the dressings changed daily for 5–7 days and then as needed.

### Fractures of the appendicular skeleton

Birds presented with fractures of either the pectoral or pelvic limb should receive appropriate therapy in a timely fashion. Several considerations in the management of fractures warrant discussion:

- 1 Fractured bones may potentially result in significant blood loss into the surrounding soft tissue. Therefore, fluid replacement is indicated to aid the maintenance of circulatory blood volume.
- 2 Most of the appendicular skeleton has little regional soft tissue support, and this predisposes the avian patient to the development of open fractures. Many initially closed fractures are complicated by bone penetrating the skin during the bird's inappropriate movements and anxiety.
- 3 The lack of extensive soft tissue support results in a close anatomical relationship between fracture fragments and regional arteries, veins and nerves. Preservation of these structures is critically important to the eventual recovery of the fracture patient.

To prevent the above mentioned complications, as well as the degree of pain associated with the movement of fractured fragments, some form of temporary external fixation may be necessary. This should be applied as soon as possible and left in place until radiography and a proper evaluation can be carried out. However, it is often wiser to do nothing at this stage unless a wing is trailing badly, in which case a temporary figure-of-eight bandage using Vetrap® or similar material may be used (Coles, 1996b).

As with any trauma patient, supportive care should include an appropriate hospital environment and the administration of fluids and drugs. Should the use of intraosseous fluids be contemplated, the fractured bone and the contralateral limb should not be used as sites of catheter placement.

Orthopaedic techniques need skill, practice and experience. Therefore, after temporary external fixation and stabilization to the point of tolerance of orthopaedic intervention, an

orthopaedic surgeon should be consulted or specific literature studied (Degernes, 1994; Coles, 1996b; Harcourt-Brown, 1996; Bennett, 1997; Rupley, 1997). Regardless of the type of fixation or splint used, the affected limb requires close monitoring. Bandages may need to be replaced within 48 hours, because they tend to loosen as local swelling is reduced. Generally, analgesia is not recommended in fracture cases because elimination of the pain associated with excessive use of the affected limb predisposes the limb to additional stress and subsequent injury (Murray, 1994).

### **Head trauma**

Head trauma is common. Window, ceiling fan, wall and mirror crashing are the most common incidents resulting in significant cranial trauma. Affected birds are typically depressed, there may be haemorrhages, and clinical evidence of CNS trauma may be present. Birds with CNS trauma should be treated aggressively to prevent irreversible damage. They should be kept relatively cool (for the treatment protocol, see Appendix 5.11). Longstanding injuries or those that fail to respond within 48 hours carry a poor prognosis, and neurological deficiencies may be permanent (Murray, 1994).

### **Burns**

Most burns are due to contact with hot liquids such as water or cooking oil, hot formula fed to unweaned birds, or electrical causes such as chewing on electric wires (Jenkins, 1997b). Burns may be classified according to their severity as superficial, partial thickness or full thickness.

There is likely to be smoke exposure in situations where smoke accompanied the burn, especially in enclosed spaces or involving materials likely to produce toxic fumes (fat, Teflon®).

If more than 50 per cent of the body surface is affected by partial or full thickness burns, the prognosis is grave and the client may consider euthanasia.

Birds with severe or extensive burns need emergency treatment. Dyspnoeic birds often have laryngeal oedema and accumulation of

upper airway secretions, and may benefit from an air sac tube and oxygen. Other treatments include an intraosseous catheter and treatment for shock. Systemic bactericidal antibiotics should be started in birds with severe burns, to prevent sepsis. Renal function should be monitored by the quantity of droppings and the urine volume, uric acid concentration and serum electrolytes. Fluids and diuretics (furosemide at 1–2 mg/kg) should be continued, and analgesics are indicated for birds that appear to be in pain. The burns should be cleansed gently, debrided daily and treated with a water-soluble antibiotic dressing. This procedure can be very painful and may be done under general anaesthesia.

Complications most likely to occur include circulatory collapse, oliguria, renal failure (most likely to occur within the first 24–48 hours) and sepsis (in birds surviving the initial injury).

Crop burns in young birds and chemical burns in adult birds are similar to other burns. Many partial thickness burns result in the formation of an eschar that will later open to form a fistula. These fistulae should be closed surgically as soon as the patient's condition allows.

### **Foreign body in the upper alimentary canal**

Owners are notoriously careless with regard to the objects they let their birds play with. Larger psittacines can chew up and splinter wood, metal (especially aluminium) and bone (particularly poultry bones). They may also play with cotton or wool attached to needles, and with large cactus houseplants. In waterfowl, impacted hooks and/or line may be found in the oesophagus. Foreign bodies can become lodged in the tongue, oesophagus or crop. Metal or plastic crop feeding tubes can be lost down the upper alimentary canal unless care is taken.

In many cases, it will be known what type of foreign body has been swallowed. The bird may be presented trying to regurgitate the offending object, which can sometimes be palpated in the oesophagus or crop or demonstrated on radiography.

In some cases, e.g. a swallowed metal or plastic catheter, the foreign body can be gently

'milked' back out of the oesophagus with the bird conscious. However, general anaesthesia or deep narcosis and forceps removal is easier. Inguviotomy (crop surgery) may be required in some cases. If the foreign body has been present for some time, ulceration and fistula of the crop may occur (Coles, 1996a).

## Discharge and follow-up

Before a bird is discharged from the hospital the client should be instructed on how to administer medication and provide the recommended care, including provision for keeping the bird warm on the way home. It is usually advisable that written home care instructions, the hospital bill and the recheck appointment are discussed prior to reuniting the bird and the client, to prevent the client from being distracted by the bird (Johnson-Delaney, 1994).

Maintaining a good line of communication with the client is very important because the status of the patient can change very quickly. The client should be informed of the unpredictable outcome of the critical avian patient. Telephoning the client the day after discharge allows the veterinarian to evaluate the patient's condition and gives the client an opportunity to ask questions.

In multi-bird households and aviaries, the diagnosis of many avian diseases must be made rapidly. The best diagnostic approach is often by post-mortem examination and histopathology. Organ cytology can often help to lead the clinician in the right direction.

## References

- ALTMAN, R. B. (1997). Soft tissue surgical procedures. In: *Avian Medicine and Surgery* (R. B. Altman, S. L. Clubb, G. M. Dorrestein and K. E. Quesenberry, eds), pp. 713–15. W. B. Saunders.
- BENNETT, A. (1994). Neurology. In: *Avian Medicine: Principles and Application* (B. W. Ritchie, G. J. Harrison and L. R. Harrison, eds), pp. 723–47. Wingers.
- BENNETT, A. (1997). Orthopedic Surgery. In: *Avian Medicine and Surgery* (R. B. Altman, ed.) pp. 933–66. W. B. Saunders.
- BENNETT, A. and HARRISON, G. H. (1994). Soft tissue surgery. In: *Avian Medicine: Principles and Application* (B. W. Ritchie, G. J. Harrison and L. R. Harrison, eds), pp. 1124–5. Wingers.
- CARPENTER, J. W., MASHIMA, T. Y. and RUIPIPER, D. J. (1996). *Exotic Animal Formulary*. Greystone Publications.
- COLES, B. H. (1996a). Nursing the sick bird. In: *Manual of Psittacine Birds* (P. H. Beynon, N. A. Forbes and M. P. C. Lawton, eds), pp. 87–95. BSAVA.
- COLES, B. H. (1996b). Wing problems. In: *Manual of Psittacine Birds* (P. H. Beynon, N. A. Forbes and M. P. C. Lawton, eds), pp. 134–46. BSAVA.
- DEGERNES, L. A. (1994). Trauma medicine. In: *Avian Medicine: Principles and Application* (B. W. Ritchie, G. J. Harrison and L. R. Harrison, eds), pp. 417–33. Wingers.
- DORRESTEIN, G. M. (1997). Metabolism, pharmacology and therapy. In: *Avian Medicine and Surgery* (R. B. Altman, S. L. Clubb, G. M. Dorrestein and K. E. Quesenberry, eds), pp. 661–70. W. B. Saunders.
- GAGGERMEIER, B., HENKE, J., SCHATZMANN, H. *et al.* (2000). Lihtersachunjen en Schmerzlinderung unit Buprenorphin bei Hanstauben Columba livia, Gurel, 1739, var. dornestica Proc. XII Conf. on Avian Disease, Munich, p. 21.
- HARCOURT-BROWN, N. H. (1996). Pelvic limb problems. In: *Manual of Psittacine Birds* (P. H. Beynon, N. A. Forbes and M. P. C. Lawton, eds), pp. 123–33. BSAVA.
- HARRIS, D. J. (1994). Care of the critically ill patient. *Seminars in Avian and Exotic Pet Medicine*, 3, 175–79.
- HARRIS, D. J. (1997). Therapeutic avian techniques. *Seminars in Avian and Exotic Pet Medicine*, 6, 55–62.
- HERNANDEZ, M. and AGUILAR, R. F. (1994). Steroid and fluid therapy for treatment of shock in the critical avian patient. *Seminars in Avian and Exotic Pet Medicine*, 3, 190–99.
- HONNAS, C. M., JENSEN, J., CORNICK, J. L. *et al.* (1993). Proventriculotomy to relieve foreign body impaction in ostriches. *J. Am. Vet. Med. Assoc.*, 202, 1989–1992.
- JENKINS, J. R. (1994). Critical care, introduction. *Seminars in Avian and Exotic Pet Medicine*, 3, 176–8.
- JENKINS, R. J. (1997a). Hospital techniques and supportive care. In: *Avian Medicine and Surgery* (R. B. Altman, S. L. Clubb, G. M. Dorrestein and K. E. Quesenberry, eds), pp. 232–52. W. B. Saunders.
- JENKINS, R. J. (1997b). Avian critical care and emergency medicine. In: *Avian Medicine and Surgery* (R. B. Altman, S. L. Clubb, G. M. Dorrestein and K. E. Quesenberry, eds), pp. 839–63. W. B. Saunders.
- JOHNSON-DELANEY, C. (1994). Practice dynamics. In: *Avian Medicine: Principles and Application* (B. W. Ritchie, G. J. Harrison and L. R. Harrison, eds), pp. 131–43. Wingers.
- KOLLIAS, G. V. (1993). Nutritional support for captive wild birds. In: *Proc. Annu. Conf. Assoc. Avian Vet.*, pp. 23–4. Association of Avian Veterinarians.
- LOUDIS, B. G. and SUTHERLAND-SMITH, M. (1994). Methods used in the critical care of avian patients. *Seminars in Avian and Exotic Pet Medicine*, 3, 180–89.
- MURRAY, M. J. (1994). Management of the avian trauma case. *Seminars in Avian and Exotic Pet Medicine*, 3, 200–209.
- PAUL-MURPHY, J. (1997). Evaluation of analgesic properties of butorphanol and buprenorphine for the psittacine bird. In: *Proc. Assoc. Avian Vet.*, pp. 125–7.

- QUESENBERRY, K. E., MAULDIN, G. and HILLYER, E. (1991). Review of methods of nutritional support in hospitalized birds. In: *First Conf. Euro. Comm. Assoc. Avian Vet.*, pp. 243–54. European Association of Avian Veterinarians.
- QUESENBERRY, K. E. and HILLYER, E. (1994). Supportive care and emergency therapy. In: *Avian Medicine: Principles and Application* (B. W. Ritchie, G. J. Harrison and L. R. Harrison, eds), pp. 382–416. Wingers.
- REDIG, P. T. (1984). Fluid therapy and acid–base balance in the critically ill avian patient. In: *Proc. Ann. Conf. Assoc. Avian Vet.*, pp. 59–74. European Association of Avian Veterinarians.
- RUPLEY, A. E. (1997). *Manual of Avian Practice*. W.B. Saunders.
- SEDGEWICK, C., POKRAS, M. and KAUFMAN, G. (1990). Metabolic scaling using estimated energy costs to extrapolate drug doses between different species and different individuals of diverse body size. *Proc. Annu. Conf. Am. Assoc. Zoo Vet.*, pp. 249–54. American Association of Zoo Veterinarians.
- STURKIE, P. D. and GRIMINGER, P. (1986). Body fluids; blood. In: *Avian Physiology*, 4th edn (P. D. Sturkie, ed.), pp. 102–29. Springer-Verlag.
- WESTERHOF, I., VAN DER BROM, W. E., MOL, J. A. *et al.* (1994). Sensitivity of the hypothalamic–pituitary–adrenal system of pigeons (*Columba livia domestica*) to suppression by dexamethasone, cortisol and prednisolone. *Avian Diseases*, **38**, 435–45.
- WHITTOW, G. C. (1986). Regulation of the body temperature. In: *Avian Physiology*, 4th edn (P. D. Sturkie, ed.), pp. 222–46. Springer-Verlag.
- WILLIAMS, D. (1994). Ophthalmology. In: *Avian Medicine: Principles and Application* (B. W. Ritchie, G. J. Harrison and L. R. Harrison, eds), pp. 673–94. Wingers.

## Appendix 5.1 Checklist of supportive care used in companion bird medicine (after Carpenter *et al.*, 1996)

Because it is frequently difficult to establish an accurate diagnosis, supportive care is an essential component of companion bird medicine. Supportive care includes:

- 1 Minimizing handling and other stressors.
- 2 Hospitalization
  - a Patient should be placed in a warm, quiet, well-ventilated environment with minimal disturbance
  - b Heating should be supplementing (30–32°C) because debilitated birds are often hypothermic.
- 3 Administration of fluid therapy (see Appendices 5.5, 5.6).
- 4 Use of corticosteroids (with caution, because of their immunosuppressive effects, etc.) in cases of:
  - a Shock and poor vascular perfusion
  - b Extreme stress
  - c CNS trauma
  - d Toxicity and selected toxaeemias.
- 5 Vitamin therapy
  - a Multivitamins (including vitamin A) as needed
  - b B complex (base on 10 mg/kg of thiamine) in selected cases of injury, anorexia, cachexia, CNS disorders or blood loss
  - c Use of lipotropic agents (choline, methionine, cysteine, betaine, lecithin, hydroxycobalamin) to increase mobilization of hepatic lipids has proved valuable only in cases where deficiencies of these substances exist.
- 6 Use of antibiotics and/or antimycotics to control primary infections and for injured or debilitated birds where secondary infections may result (use stained faecal smears for evaluation).
- 7 Iron dextran (6 per cent iron dextran 20 ml/kg i.m. (Redig, 1984)
  - a In cases of iron deficiency or following haemorrhage
  - b Care must be taken with mynahs, toucans and toucanettes, because of iron storage disease.
- 8 Organizing normal photoperiods (or subdued lighting, if needed).
- 9 Administration of oxygen (for dyspnoea, hypoxia, or severe pneumonia and aerossacculitis).
- 10 Maintenance of body weight
  - a Bird should be weighed daily if possible
  - b A variety of favourite foods should be offered; the bird's diet should not be changed when it is ill.
- 11 Gavage when necessary
  - a In cases of malnourishment, anorexia, cachexia and dehydration
  - b A high carbohydrate formula is initially recommended.
  - c High protein/high caloric formulae may be used to increase body weight during recovery.



## Appendix 5.2 Calculation of enteral feeding requirements for birds (after Carpenter *et al.*, 1996)

This appendix will aid the practitioner in calculating caloric requirements for birds (see Appendix 5.4 regarding calculation of basal metabolic rate and maintenance requirements; Appendix 5.5 regarding calculation of the fluid requirement; Appendices 5.3 and 5.6 regarding the maximum suggested volumes of fluids and frequency of gavage feeding).

Caloric values for the three food types are:

Protein	4.29 kcal/g
Carbohydrate	4.09 kcal/g
Fat	9.29 kcal/g

Animals are unable to use all the calories in these nutrients, but efficiency is estimated at between 80 and 90 per cent, depending on the type of nutrient. Commercial enteral solutions are estimated to have a high digestibility of 95 per cent, and some commercially available enteral products are listed below. Each product has varying levels of fat, carbohydrate, protein and water. Other food sources can be used, as long as nutrient levels and digestibility can be determined. The following is an example of a calculation of nutrient requirements based on BMR.

### Example

A 250 g lilac-crowned Amazon is debilitated and not eating because of a bacterial infection.

$$\begin{aligned} \text{BMR (kcal/day)} &= kW^{0.75} \\ \text{MER (kcal/day)} &= (1.5 \times \text{BMR}) \end{aligned}$$

where  $k$  = kcal/kg/day constant (non-passerines = 78; passerines = 129; placental mammals = 70; marsupials = 49; reptiles at 37°C = 10).

First calculate MER:

$$\text{MER (kcal/day)} = (1.5)(78 \text{ kcal/kg/day})(0.250 \text{ kg})^{0.75} = 41.4 \text{ kcal/day}$$

An adjustment for sepsis is made by multiplying by 1.5 (see BMR, Appendix 5.4):

$$\text{Sepsis} = 1.5 \times \text{MER} = (1.5)(41.4 \text{ kcal/day}) = 62.1 \text{ kcal/day}$$

Isocal® HCN (2 kcal/ml) is selected as the nutrient source:

$$\text{Volume of Isocal®} = (62.1 \text{ kcal/day}) / (2 \text{ kcal/ml}) = 31 \text{ ml/day}$$

The average Amazon parrot can be gavaged 2.5 per cent of its body weight, so:

$$\text{Volume that can be gavaged} = (0.025)(250 \text{ g}) = 6.25 \text{ ml}$$

Therefore, 31 ml/day of Isocal® HCN can be administered via gavage feeding of 6.25 ml every 5 hours. However, this volume may need to be reduced initially depending on the bird's degree of debilitation.

(Refer to Appendix 5.3 for suggested volumes and frequencies of gavage feeding anorectic birds.)

**Nutrient values for selected nutritional products (Kollias, 1993)**

<i>Product</i>	<i>Protein</i> (g/l)	<i>Fat</i> (g/l)	<i>Carbohydrate</i> (g/l)	<i>Water</i> (ml/l)	<i>kcal/ml</i>
CliniCare® Feline (Pet Ag)	70	46	57	830	0.92
CliniCare® Canine (Pet Ag)	50	61	60	820	0.98
Isocal® (Mead Johnson)	34	44	133	840	1.0
Traumacal® (Mead Johnson)	55	45	95	520	1.5
Pulmocare® (Ross)	42	61	70	520	1.5
Isocal® HCN (Mead Johnson)	38	51	100	355	2.0
Nutrilon soya® (Nutricia) <sup>a</sup>	102	203	378	667	3.7
Emerald-II® (Lafeber) <sup>b</sup>	108	22.5	281	450	1.53

<sup>a</sup>72 g + 67 ml H<sub>2</sub>O = 100 ml (1 spoon (4.3 g) + 4 ml <sup>a</sup> H<sub>2</sub>O = 6 ml ~22 kcal) = 5.1 kcal/g

<sup>b</sup>45 g + 45 ml H<sub>2</sub>O = 100 ml.

**Saccharide contents (percentage of dry weight)**

<i>Product</i>	<i>Monosaccharide</i>	<i>Disaccharide</i>	<i>Trisaccharide</i>	<i>Tetrasaccharide</i>	<i>kcal/ml</i>
Emerald-I® (Lafeber) <sup>a</sup>	19.7	14.4	11.2	54.7	2.0
Dextro Energy®	90.1	-	-	-	12 <sup>b</sup>

<sup>a</sup>15 g + 30 ml H<sub>2</sub>O = 30 ml

<sup>b</sup>12 kcal/tablet = 370 kcal/100 g.

### Appendix 5.3 Suggested volume and frequency of gavage feeding<sup>a</sup> in anorectic birds (after Carpenter *et al.*, 1996)

<i>Species</i>	<i>Volume (ml)</i>	<i>Frequency</i>
Finch	0.1–0.3	q4h
Budgerigar	0.5–1.0	q6h
Cockatiel	1.0–2.5	q6h
Conure	2.5–5.0	q6h
Amazon parrot	5–8	q8h
African grey parrot	5–10	q8h
Cockatoo	8–12	q12h
Macaw	10–20	q12h

<sup>a</sup>Beware that there can be a large difference in size of a certain species within a species group. Always check with Appendix 5.6.

### Appendix 5.4 Determining the basal metabolic rate of animals (after Carpenter *et al.*, 1996)

The following information is provided so the drugs can be allometrically scaled for different species, and to assist in calculating metabolic needs for nutritional requirements and fluid therapy.

#### BMR (basal metabolic rate)

BMR differs between species.

The general equation to calculate BMR is (Sedgewick *et al.*, 1990):

$$\text{BRM} = kW^{0.75}$$

where BMR = kcal/kg/day, *k* = kcal/kg constant (non-passerines = 78; passerines = 129; placental mammals = 70; marsupials = 49; reptiles at 37°C = 10) and *W* = weight in kg.

Other equations have been determined for passerine and non-passerine birds in relation to the daylight cycle. These cycles are termed

'active phase' and 'rest phase'. However, results are similar to the above formula.

Phase	Passerine	Non-passerine
Active phase	$BMR = (140.7)W^{0.704}$	$BMR = (91)W^{0.729}$
Rest phase	$BMR = (113.8)W^{0.726}$	$BMR = (72)W^{0.734}$

## Maintenance energy requirement (MER)

The maintenance energy requirement (MER) = (kcal/day) =  $(1.5 \times BMR)$ . In birds, the MER can then be adjusted for health status as follows (Quesenberry and Hillyer, 1994):

Physical inactivity	$0.7-0.9 \times MER$
Starvation	$0.5-0.7 \times MER$
Hypometabolism	$0.5-0.9 \times MER$
Elective surgery	$1.0-1.2 \times MER$
Mild trauma	$1.0-1.2 \times MER$
Severe trauma	$1.1-2.0 \times MER$
Growth	$1.5-3.0 \times MER$
Sepsis	$1.2-1.5 \times MER$
Burns	$1.2-2.0 \times MER$
Head injuries	$1.0-2.0 \times MER$

## Appendix 5.5 Fluid therapy recommended for use in birds (after Carpenter *et al.*, 1996)

- 1 Ideally, when evaluating a patient for fluid therapy, the following factors should be considered:
  - hydration status
  - electrolyte balance
  - acid-base status
  - haematological and biochemical values
  - caloric balance.
- 2 Combinations of routes (p.o., s.c., i.o., i.v.) are recommended if high fluid volumes are to be administered.
- 3 Calculating the fluid volume using the BMR method usually gives a higher result than other methods of fluid calculation.
- 4 Fluids can be administered by slow i.v. or i.o. infusion, by a combination of i.v. bolus and s.c. administration, or by repeated s.c.

administration. A volume of 10 ml/kg/h can be infused into healthy patients for the first 2 h, then this should be reduced to 5–8 ml/kg/h to avoid fluid overload.

- 5 Although fluid requirements can be met in part by administering 10–15 ml/kg (and up to 25 ml/kg if over a 5–7 min period) of warm lactated Ringer's solution (or 50:50 with 2.5–5 per cent dextrose if the patient is hypoglycaemic or caloric deficient) i.v. as a bolus q8–12h; maintenance fluid is generally administered s.c., p.o. or, occasionally, through an intraosseous catheter. Oral administration of 5 per cent dextrose appears to be very effective in restoring fluid deficits rapidly.
- 6 Warming of fluids to 38–39°C prior to administration can help prevent or correct hypothermia.

## Calculation of fluids using the body weight percentage method

Fluid replacement in ml = body weight (g)  $\times$  2.5 per cent q8–12h as needed for dehydration

### Example

A 250 g lilac-crowned Amazon is dehydrated.

$$\begin{aligned} (250)(0.025) &= 6.25 \text{ ml q8-12h} \\ &= 8.75 \text{ ml/day;} \\ &\text{after 3 days, } 56.25 \text{ ml} \end{aligned}$$

## Maintenance and deficit replacement method

Determine fluid deficit:

$$\text{Fluid deficit (ml)} = \text{body weight (g)} \times \text{per cent dehydration}$$

Determine daily maintenance:

$$\text{Daily maintenance} = 50 \text{ ml (range: } 40-60 \text{ ml)/kg/day}$$

If possible, replace 50 per cent of the deficit in the first 12–24 h and the remainder over the next 24–48 h; some clinicians recommend replacing 20–25 per cent of the deficit in the first 4–6 h and the remaining volume during the next 20–28 h.

**Example**

A 250 g lilac-crowned Amazon is 10 per cent dehydrated.

Weight	250 g
10 per cent dehydration	25 ml
Maintenance at 5 per cent body weight/day	12.5 ml

1st day fluid requirements = (maintenance + 0.5 of deficit)  
= (12.5 + 12.5) = 25 ml/day.

2nd day fluid requirements = (maintenance + 0.25 of deficit)  
= (12.5 + 6.25) = 18.75 ml/day.

3rd day fluid requirements = (maintenance + 0.25 of deficit)  
= (12.5 + 6.25) = 18.75 ml/day.

Total amount of fluid administered after 3 days is 62.5 ml.

**BMR method**

This method holds some merit despite the large fluid volume the calculations generate. By assuming that the amount of water a bird requires is similar to that of a mammal (1 ml/kcal/day), then fluid requirements (based on BMR) can be determined using metabolic scaling. BMR is calculated from the equation:

$$\text{BMR (kcal/day)} = kW^{0.75}$$

where W = weight in kg and k = kcal/kg/day constant (non-passerines = 78; passerines = 129).

Maintenance fluid required = 1 ml/kcal/day.

**Example**

A 250 g lilac-crowned Amazon is 10 per cent dehydrated. After 3 days of fluid administration, the bird would receive approximately 1.5 times the amount calculated using other two methods.

$$\begin{aligned} \text{BMR} &= (78 \text{ kcal/kg/day})(0.250 \text{ kg})^{0.75} \\ &= 27.6 \text{ kcal/day} \end{aligned}$$

Fluid requirement is assumed to be 1 ml/kcal = 27.6 ml/day

Accounting for the 10 per cent dehydration, total fluid requirement = 27.6 + (25/3) = 35.9 ml/day.

Total amount of fluid administered after 3 days is 107.7 ml.

## Appendix 5.6. Routes of administration and maximum suggested volumes of fluids to be administered to psittacines<sup>a</sup> (after Carpenter *et al.*, 1996).

Bird's weight (g)	Volume (ml) by route of administration		
	Gavage <sup>b</sup>	i.v. bolus (initial)	Subcutaneous
10-25	0.4-0.75	0.5-0.75	1-2
25-50	0.75-3.0	0.75-1.0	2-5
50-75	3-6	1.0-1.5	5-7
75-100	6-8	1.5-2.0	7-12
100-250	8-15	2-5	12-18
250-500	15-20	5-8	18-24
500-750	20-30	8-12	24-28
750-1000	30-40	12-15	28-30

<sup>a</sup>Use lower dose in lighter birds

<sup>b</sup>Initial volume should be much less in critically ill and anorexic patients. Adults take less, proportionally, than neonatal or juvenile birds.

## Appendix 5.7 Some commonly nebulized medicines<sup>a</sup> (after Rupley, 1997)

Medication	Dosage <sup>a</sup>	Administration <sup>b</sup>
Amikacin sulphate	50	15 min BID
Amphotericin B <sup>d</sup>	10	15 min BID
Carbenicillin <sup>d</sup>	200	15 min BID
Cefotaxime <sup>d</sup>	100	10-30 min BID-QID
Erythromycin <sup>d</sup>	100	15 min BID
Gentamycin <sup>c</sup>	50	15 min BID
Piperacillin <sup>d</sup>	100	10-30 min BID-QID
Tylosin	100	10-60 min BID

<sup>a</sup>Dosage in mg in 10 ml saline; <sup>b</sup>Administration time and frequency; <sup>c</sup>Discontinue use if polyuria develops; <sup>d</sup>Injectable. For nasal flush and sinus flush use dosage in 250 ml.

## Appendix 5.8 Interpretation of changes in the avian packed cell volume (PCV) (after Hernandez and Aguilar, 1994)

PCV	PCV changes		Interpretation
	TP	TWC	
Decrease	Normal	Normal	Anaemia
	Decreased	Normal	Recent blood loss
	Increased	Increased	Anaemia of chronic disease
Normal	Normal	Normal	Healthy
	Normal	Increased	Acute infection
	Increased	Increased	Dehydration; masked anaemia; acute infection
Increased	Normal	Normal	Polycythaemia
	Increased	Normal	Dehydration and leucopenia
	Increased	Increased	Dehydration

## Appendix 5.9 Recommended steps for treating birds with shock (after Hernandez and Aguilar, 1994)

- 1 Presumptively diagnose shock.
- 2 Take baseline blood sample for packed cell volume, total protein and bicarbonate. Record weight. Additional glucose determination may be performed. Other laboratory tests can be postponed.
- 3 Place an intraosseous or intravenous catheter.
- 4 Calculate degree of dehydration and fluid requirements (Appendix 5.5).
- 5 Initiate lactated Ringer's solution at half of the fluid deficit over the first 12 hours and give as bolus.
- 6 Give vitamin B complex (10 mg/kg thiamine), steroids (dexamethasone 0.1–0.5 mg/kg) or non-steroidal anti-inflammatory drugs (ketoprofen, flunixin and carprofen 2 mg/kg) and iron dextran (20 ml/kg 6 per cent i.m.). Provide parenteral nutritional support if necessary.
- 7 Initiate antibiotics if fractures, open wounds or soft tissue injuries are found, or if (bacterial) infectious disease is suspected (cytology faecal smear).
- 8 Monitor PCV, TP, bicarbonate, and urine output.
- 9 Obtain a complete history and initiate diagnostic testing.
- 10 Begin maintenance fluids and start force feeding (Appendices 5.2, 5.3, 5.5, 5.6).
- 11 Monitor weight until bird is able to self-feed.

## Appendix 5.10 Agents used in emergencies in birds (after Carpenter *et al.*, 1996)

<i>Agent</i>	<i>Dosage</i>	<i>Species/comments</i>
Atropine	0.5 mg/kg i.m., i.v., i.o., i.t.	CPR
Calcium gluconate	50–100 mg/kg i.v. slowly, i.m. diluted	Hypocalcaemia, cardiac protection
Dexamethasone sodium phosphate	0.1–0.5 mg/kg i.m., i.v. q12h	Head trauma (until signs abate); shock (one dose); hyperthermia (until stable)
Dextrose (50 per cent)	1.0 ml/kg i.v. slowly	Can dilute with fluids
Diazepam	0.5–1.5 mg/kg i.m., i.v.	Sedation or seizures
Doxapram	20 mg/kg i.m., i.v., i.o.	CPR
Epinephrine (1:1000)	0.5–1.0 ml/kg i.m., i.v., i.o., i.t.	CPR
Fluids	0.025 × wt (g) = ml fluids i.v., i.o., s.c.	See fluid therapy
Prednisolone	1.0–3.5 mg/kg i.v., i.m., q12h	Head trauma, CPR
Sodium bicarbonate	1 mEq/kg q15–30 min to maximum of 4 mEq/kg total dose 5 mEq/kg i.v., i.o. once	Metabolic acidosis CPR

## Appendix 5.11 Recommended treatment protocol for the avian head trauma patient (after Hernandez and Aguilar, 1994)

- 1 Diagnose head trauma; check pedal reflex and cloacal tone.
- 2 Place an intraosseous or intravenous catheter.
- 3 Start oxygenation via oxygen cage (40 per cent oxygen) or face mask at 50 ml/kg/min. Check ventilation rate.
- 4 Check PCV, TP and bicarbonate.
- 5 Start emergency fluid therapy. Hypertonic saline (7.5 per cent) 4–5 ml/kg and iron dextran (6 per cent) at 20 ml/kg may be used if no dehydration exists. If critically dehydrated, initiate lactated Ringer's solution administered at 30 ml/kg as bolus.
- 6 Give dexamethasone at 0.1–0.5 mg/kg initially, followed by gradually tapering doses every 6–8 hours.
- 7 Give vitamin B complex (10 ml/kg thiamine), antibiotics and nutritional support if required.
- 8 If the situation deteriorates, use mannitol (25 per cent) at a dose of 0.25–2.0 mg/kg and furosamide at a dose of 2–5 mg/kg.

# Psittacine birds

*Nigel H. Harcourt-Brown*

## Introduction

The order Psittaciformes contains parrots, macaws, cockatoos and lorries. Forshaw (1973) suggests 81 genera containing 332 species; Sibley and Ahlquist (1990) suggest 358 species in 80 genera; other authorities suggest minor variations to these numbers.

Parrots may be defined by their distinctive well-developed, hooked rostrum (upper beak) with a prominent cere (the featherless area dorsal to the upper beak); the rostrum is hinged to the skull with a synovial joint, unique amongst birds, and there are also some unique muscles associated with the jaw. The prehensile feet are zygodactyl, having digits I and IV directed caudally and digits II and III cranially. There is a well-developed crop, proventriculus and gizzard, but there are no caecae; the gall bladder is usually absent; the preen (uropygial) gland is tufted or in some genera absent (e.g. *Amazona* and *Pionus*), and the furcula (united clavicles) is weak or absent. The syrinx has three pairs of intrinsic muscles and is tracheal and well developed, having a syringeal valve at its entrance.

Parrots nest in holes, lay white eggs and have nidicolous (stay in the nest for a long time) young, which are ptilopaedic (covered with down when hatched). Adult parrots have patches of powder down; these are areas of down feathers that fragment at their ends and cover the bird and its plumage with a soft, usually white, powder. The other more esoteric anatomical characteristics that define the order are covered comprehensively by Sibley and Ahlquist (1990), who also conclude that parrots have no close living relatives.

Psittaciformes are commonly referred to using the all-embracing term 'psittacine birds', and are very popular as either caged pet birds or aviary birds. Psittacine birds

range in size from the hyacinth macaw (*Anodorhynchus hyacinthinus*), which measures 100 cm and weighs 1500 g (the kakapo, *Strigops habroptilis*, a flightless parrot, is even bigger at 2060 g) down to pygmy parrots – for example, the buff-faced pygmy parrot (*Micrositta pusio*) is slightly less than 10 cm and weighs 11 g. The numbers within a species vary from just 37 individuals for the Spix's macaw (*Cyanopsitta spixii*), to being very numerous and considered a pest species (e.g. some cockatoos, *Cacatua* spp., in Australia). The family is mainly vegetarian and some of its members are specialized feeders, such as the lorries and lorikeets, who only eat pollen and nectar.

The attraction of parrots as companion animals is in their intelligence and potential for taming and training, their ability to mimic vocally, and their rounded faces, which most people find an attractive feature in any animal. Not every species of parrot can be kept in captivity, either because of rarity or (more usually) dietary requirements – for example, pygmy parrots (*Micrositta* spp.) eat mostly lichens and fungus. Some Psittaciform families provide the general public with many of their pets. This chapter concentrates on species that are often encountered in captivity.

## Psittaciforms encountered in captivity

### Macaws

Macaws range in size from the hyacinth macaw (*A. hyacinthinus*) at 100 cm to the

noble macaw (*Ara nobilis*) at 30 cm, and are characterized by large beaks and long tails. They are South American in origin, and eat nuts, seeds, berries and fruit. The immensely strong beaks of the larger birds, such as the green-winged macaw (*Ara chloroptera*), can easily break open Brazil nuts. Macaws are very strong and potentially destructive; they require large cages or stands, but are best kept in aviaries.

## Parrots

Parrots are short-tailed, large-beaked, stocky birds. There are a number of African parrots, the commonest in captivity being the African grey parrot (*Psittacus erithacus*) – the familiar black-beaked, red-tailed, grey parrot. There is a smaller subspecies, the Timneh grey parrot (*P. e. timneh*), which is smaller and darker, with a horn-coloured beak and a dark maroon tail. Both come from west and central Africa. They live in woodland and eat seeds, nuts and berries; they are particularly fond of palm oil nuts and will raid maize crops, causing much damage.

Another commonly encountered family of parrots is known as Amazons (*Amazona* spp.). Out of nearly 30 species, three are commonly kept: the blue-fronted Amazon (*A. aestiva*), which is mainly green with a blue and yellow face, a red carpal edge – easily visible when the bird is perching normally – and a red wing spectacle on five or more secondary feathers; the orange-winged Amazon (*A. amazonica*), which is also green with blue and yellow feathers around its face but has an orange wing spectacle and no red on its carpal edge; and, finally, the yellow-crowned Amazon (*A. ochrocephala*), which is green with a green face and a yellow patch somewhere on its head or neck, a red wing spectacle and a red carpal edge. These birds come from central and South America, where they live in forests and eat fruit, berries, nuts, blossoms and leaf buds.

There are many smaller parrots that are popular as aviary subjects. These include *Pionus* spp. and *Brotgeris* spp. from South America, and lovebirds (*Agapornis* spp.), Senegal parrots (*Poicephalus senegalus*), Meyer's (brown) parrots (*P. meyeri*) and brown-

headed parrots (*P. cryptoxanthus*) from Africa. Lovebirds are very popular, several species being completely captive bred with a huge variety of colour mutations.

## Cockatoos

Cockatoos (Cacatuidae) are medium- to large-sized birds, usually white, and nearly all have an erectile crest that can be raised when alarmed or excited. The popular pet cockatoos are the sulphur-crested cockatoo (*Cacatua galerita*), lesser sulphur-crested cockatoo (*C. sulphurea*) and the Moluccan cockatoo (*C. moluccensis*), which is pale pink in colour. There are other species of various colours – black, white, pink or even nearly red. They are very gregarious birds, and are Australo-Pacific in origin.

Cockatoos are very noisy, even by parrot standards! They eat a varied diet of fruit, berries, nuts, flowers, leaf buds and roots, and also insects and their larvae, which they may dig out of the ground or from trees. Black cockatoos are seldom kept as pets in Europe.

## Parakeets

Parakeet is a term restricted to small parrots with long graduated tails. There are many genera and are they mostly Pacific and Asian in distribution. Australia will not export any birds, but its parakeets are very popular due to their size and muted voices (compared with other Psittaciformes!); they are also less destructive in the aviary and are prettily coloured. In Europe, most parakeets are cheap to buy. They are not usually kept as pets, except for the cockatiel (*Nymphicus hollandicus*) and the budgerigar (*Melopsittacus undulatus*). Also from Australia, grass parakeets (*Neophema* spp.) and rosellas (*Platycercus* spp.) are frequently kept as aviary birds. New Zealand has provided the aviculturalist with the kakariki (*Cyanoramphus novaezelandiae*). Asian parakeets are all very similar, and are from the genus *Psittacula*; they include the rose-ringed or ring-necked parakeet (*P. krameri*), the Alexandrine parakeet (*P. eupatria*), the plum-headed parakeet (*P. cyanocephala*), the blossom-headed parakeet (*P. roseata*), etc.



## Conures

Conures are South American parakeets, and range from the small and quiet *Pyrrhura* spp. to the medium-sized, noisy and destructive *Aratinga* spp. Many *Aratinga* conures are similar in form and habits to the small macaws.

## Lories and lorikeets

Lories are larger than 30 cm and lorikeets are smaller than 15 cm, but all are from the same family: Loridae. They are typified by their brilliant colours and Australo-Pacific origin, and they have a modified brush-tipped tongue which they use to collect and compress pollen into a pellet so they can swallow it. Pollen is their main protein source, and they also eat nectar when available plus occasional insects and fruit. They are very popular amongst aviculturalists, and their dietary requirements can now be easily met by supplying proprietary 'nectar' mixtures. The main drawbacks to keeping these birds are that they produce copious quantities of very fluid and sticky droppings, and that their nectar has to be changed three or four times daily in warm weather to avoid fermentation of the mixture and death of the birds. They are not usually pet birds.

## Pet parrots

The earliest known captive pet birds were from the parrot family. There are records of Alexander the Great bringing ring-necked parakeets (*Psittacula krameri*) with him from India to Europe. Budgerigars (*Melopsittacus undulatus*) were first seen alive in Europe in 1840, and over the next 40 years many tens of thousands were imported from Australia. From the naturally found, predominantly green-coloured, yellow-faced bird a huge variety of colours have been produced, although a red budgerigar has yet to be bred! Adult male birds of most colours (but not lutinos, which have yellow feathers and pink eyes, or albinos, with white feathers and pink eyes) have a blue cere; adult females have a brown cere.

The best time for obtaining a pet budgie is when it first leaves the nest, at around 6 weeks

of age. At that time the bird has feathers edged with black or brown, which give a barred appearance to the frontal region (forehead) above the cere. These barred feathers are moulted at the first partial moult about 2 months later, leaving the forehead a plain colour. Male 'barheads' have a pinkish cere with a blue tinge; however this is not a reliable guide to gender. Also, females bite far harder than males, even when still babies in the nest! It is unfortunate that budgerigar breeders have developed what is known as a 'buff plumage' for their show birds. The buff feathers are very large and appear to have deformed barbules, as they do not unite to form a normal contour feather shape and have a hairy appearance. Breeder's budgerigars also tend to live about 4 years. 'Mongrel' pet budgerigars seem to live far longer and 8 years is average, although the author has seen a budgerigar, with a dated closed-ring, of 21 years.

The cockatiel was named as such by a bird-fancier, Mr Jamrach, being an English adaptation of a Dutch/Portuguese word for little cockatoo (Newton, 1896). By the end of the nineteenth century the cockatiel was already a popular pet caged bird, and it has remained so ever since. The general grey colour with orange cheeks and a distinct head crest is common to both males and females, but the male has a yellow face and crest while the female is grey, and tail and wing feathers are a solid grey in males whereas they are mottled grey and white (especially underneath) in females. Cockatiels of this coloration are termed normals, but there are many colour variants – lutino (yellow), white, fallow (with a brownish tint), etc. Immature birds resemble females.

The cockatiel is a peaceful, active, cheerful bird that mimics well; it deserves its popularity and would be the author's first choice for anyone wanting a pet bird. It is also relatively cheap to purchase, house and keep.

African grey parrots are very popular pets and are hardy, medium-sized (450–500 g) birds. The reason for the African grey parrot's popularity is its talking and mimicking ability. Unlike the popular mynah birds (which are not in fact mynahs but grackles, *Gracula religiosa*), these parrots will learn new words and noises throughout their lives. They are usually friendly throughout their entire lives,

but hand-reared birds do often feather-pluck, especially when sexually mature. A large cage or small indoor aviary is required to keep them happy. Like all parrots, when kept on their own they need to fly around and have a lot of human contact, but they are destructive and should not be left unattended. They tend not to like water, either as a bath or when sprayed. However, it is still necessary to spray them weekly to keep their plumage in good condition. Grey parrots also tend to become 'hooked' on a seed-only diet very quickly.

The Timneh grey parrot is smaller and more subdued in colour. It is, however, as satisfactory a pet as its close relative. Its treatment should be the same.

To some extent, the age of many species of parrot can be deduced from the iris. This structure is particularly important to the bird, as its movement is effected by skeletal muscle and is therefore under conscious control. The bird can use it to signal other birds (owners and vets) by expanding the iris to cause a flash of colour. During the first year of life of parrots such as greys, Amazons and macaws, the colour of their iris slowly changes. The newly weaned birds have blue/brown irises, which change to yellow in greys, orange in Amazons and yellow in large macaws. Some species of cockatoo have a brown iris if female and a black iris if male. As the parrots become sexually mature the iris brightens, and in later life it becomes thinner and less pigmented. In old age there are often degenerative eye changes such as cataracts (Clubb and Karpinski, 1993). Old age is considered to be 45–50 years in macaws, and 35 years in greys and amazons. Reports of a life expectancy of 100 years are rarely true.

The orange-winged Amazon is usually imported in large numbers and is not generally bred in captivity, unlike the blue-fronted Amazon; a number of ingenious owners have been sold the cheaper orange-winged Amazon as a more expensive blue-fronted Amazon. Amazon parrots like fruit and vegetables as well as a seed diet. They also enjoy being sprayed with water, and will hang upside down shouting with apparent pleasure.

Blue-fronted, orange-winged and yellow-fronted Amazons are all popular as pets. Various other species are kept as pets too. In the main they are not as talented as the grey

parrots at talking, but they are considerably more attractive. Amazons (and Pionus) all enjoy being sprayed, and will hang from the bars of their cage and fan their tails and wings to get as wet as possible. They enjoy being outside in the rain, and in the UK acclimatized parrots living in aviaries can be seen happily bathing in sleet or even snow! They much prefer to be sprayed in the morning, and seem unhappy about going to bed wet. Amazons are much less likely than the greys to feather-pluck as they get older, but they often change temperament in the breeding season and single pet birds can become quite dangerous, attacking and biting humans that they think are rivals. This behaviour is not apparent outside the breeding season. Behaviour initiated in stressful situations is manifested by apparent irritation of the skin and feathers.

Amongst the macaws, it is only the larger birds that are popular as pets; because of their size and colour; they are very striking. The green-winged macaw is very gentle and pleasant, and probably makes the best pet; the blue and gold macaw is also popular. The scarlet macaw looks very pretty and is a reasonable pet bird when young, but it becomes very spiteful and even aggressive when adult, especially when sexually active. All the macaws have loud voices and will use them, especially at first light. The macaws may have their wings clipped to prevent them flying, but they still need a very large cage or indoor aviary to exercise in. A large free-standing cage can be made quite economically by cutting 5-cm security mesh into pieces and wiring them together. These birds tolerate being sprayed, and some even like it. They can all mimic and talk to a reasonable degree.

Cockatoos are kept by some people, but these birds are the most prone to psychological disturbances and can become very unhappy on their own, even when attention is lavished on them by their owners. They are very noisy, even more so than the macaws.

## Housing

Most psittacine birds are better kept as pairs in aviaries made of stout wire mesh. There should be a space between pairs of parrots, or they will attack the toes of the birds next door

and amputate them. A convenient method of constructing an aviary is to suspend the cage above the ground. The cage should be a reasonable size for the species being housed, and should allow the birds to fly. Birds are happier being able to get higher than their keeper, so the roof should be a minimum of 2 m off the ground – even if the cage is only 1 m high and wide, which is suitable for lorries, small parrots, conures, etc. Suspended aviaries minimize contact with old food, faeces, etc., and make cleaning very easy. Ideally the suspended aviaries should be enclosed in a large netted area to prevent escape if a bird gets out of the cage whilst being caught or fed, and also to minimize contact with wild birds and their diseases or parasites.

Aviaries should be made from wire ranging from a 19-gauge 2.5×0.5 mesh for small birds to a 16-gauge 5 cm mesh for macaws, etc. The wire should be galvanized. In some parts of the world this galvanization process seems to cause zinc toxicity to the birds when they are first housed, and it is recommended that new mesh is washed in dilute acid first. This is uncommon in the UK.

## Environmental enrichment

Corvidae (crows) and Psittaciformes (parrots) have, relatively, the largest avian cerebral hemispheres; Galliformes (fowl-like birds) and Columbiformes (doves and pigeons) have the smallest. Psittacine birds (and crows) appear to be very ‘intelligent’. However, the interaction between the ability to learn and the various related reflexes means this statement is a bit of a minefield.

Mentally normal parrots prefer to be kept with others of the same species, and they must also have the facility to perform functions other than sitting, eating and sleeping. Cages must be large enough for flight, the birds should have different sized perches of different materials, and there must be a suitable environment for foraging, playing and other social interactions. Perches made of smooth hardwood will cause pressure problems on the plantar aspect of the birds’ feet, similar to bumblefoot in birds of prey. To avoid this, perches of different shapes and diameters (preferably branches covered with bark) are very useful. The birds will chew

and destroy these branches, and they must be replaced regularly. The author has tried many different woods in his aviaries (sycamore, elm, ash, hawthorn, elderberry, pine, pine treated by tannalization, etc.), and has yet to find any wood that is toxic to the parrots. However, it would be prudent not to use woods known to be poisonous to mammals, such as rhododendron or yew. Loops of hessian rope suspended from the roof of the cage also make good perches, as there is some ‘give’ in the perch as the bird lands. The same may be accomplished by anchoring one end of a branch with a hinge or hook and eye and suspending the other end from a piece of wire; again this allows the perch to move more naturally.

## Nutrition

Although parrots eat a wide range of foodstuffs, they are primarily vegetarian. Birds that live in tropical or subtropical forests and woodland eat a wide range of fruits and their seeds; those living in drier conditions eat mainly seeds, especially xerophilic (adapted to dry conditions) birds such as cockatiels and budgerigars. There are some specialized feeders; lorries and lorikeets (loridae) eat pollen and nectar and have a specialized tongue with a border of brush-like projections to aid them, and pygmy parrots (*Micropsitta* spp.) eat lichen and fungi as a staple part of their diet. Many parrots have been found with insects in their crops when examined by zoologists (Forshaw and Cooper, 1973), and in a number of species insects and grubs form a significant part of their diet.

All animals require carbohydrate, protein and fat in their diet. Psittaciformes are no different, and thought must be given to the food content of each part of the diet fed to a captive bird as well as to its palatability. Parrots require diets that contain about 20 per cent protein, and vegetarian diets must be carefully balanced to avoid major deficiencies of important foodstuffs. Finally, and most importantly, parrots must NOT be allowed to feed selectively, or a well-balanced diet becomes a deficient diet. Dietary deficiency in captive birds plays a huge part in determining the bird’s general lifelong health.

## Seeds

It must be remembered that many pet shops sell all-seed diets as 'parrot food' 'parrot-mix' or 'cockatiel food', and give this to owners who ask for parrot food. Seeds such as sunflower, peanuts and pine nuts are low in calcium, vitamins A and D and protein; they are also very high in oil. Cereals and smaller seeds, such as millet, are similar, but they have less oil and more starch; they are similarly deficient. Seeds are variably deficient in iodine. In a survey of budgerigars (Blackmore, 1963), 85 per cent had dysplasia of the thyroid gland; this will still be the situation for budgies that are fed on loose seed from the pet shop.

When given the opportunity, many pet parrots (especially the greys) become habituated to eating only seed, especially sunflower seed, and appear to refuse to eat anything else; long term, this is a life-threatening situation.

## Fruit and vegetables

Fruit and vegetables are useful in the diet but are often low in protein, calcium and vitamin D. They are high fibre, contain vitamins A and C, and are low calorie compared with seeds. It is preferable to use non-sludging fruit and vegetables, such as apples and carrots. Food pots, etc. must be kept clean, as a build-up of vegetable debris encourages the growth of *Aspergillus* spp. and various potentially pathogenic bacteria. This is especially common in warm, damp climates.

## Pulses

The seeds of leguminous food plants are known as pulses. Peas, beans and maize (sweet corn) are all very useful foods, as they contain good levels of protein (20–30 per cent). However, be aware that they contain around 60 per cent carbohydrate and are also low in calcium. Soya bean protein contains the most similar range of amino acids to those in animal protein. Soaking pulses and allowing them to germinate increases their digestibility, decreases the toxin content of some beans and improves their taste. They should be prepared by soaking for 24 hours. Too warm a tem-

perature allows fermentation, whereas too cool a temperature prevents germination. The pulses should then be washed thoroughly in clean running water, which removes any noxious metabolic products and also any potentially fermentative bacteria. After initial soaking the pulses may be kept moist and cool in the fridge for several days, but they must be washed daily and before use. In warm climates it may be better to boil the pulses just prior to feeding rather than soak them; boiling reduces the risk of fermentation.

## Minerals

Most seed-eating parrots appreciate grit to aid their grinding gizzard. Mineralized grit and oyster shell grit are both useful; oyster shell grit does not last as long in the gizzard, but both types of grit are a source of calcium. Grit sold for pigeons is satisfactory for most medium and large parrots. Mineral blocks containing calcium or iodine are produced for small pet birds and can be useful, as is cuttlefish; again, the bird has to eat this solid material, and not all birds will.

## Vitamin supplements

All parrots require a vitamin and mineral supplement with their food unless they are fed on an appropriate all-in-one commercial ration. There are a large number of supplements on the market. Water-soluble products do not seem to contain the range of compounds that powders do. Mixing powder with seed works reasonably well, but it is better to take the fruit and vegetable portion of the diet, chop it up and mix it with the seed. This gives a wet mixture, which is a very satisfactory vehicle in which to mix the powder. A specific avian vitamin and mineral supplement should be used, as this will contain a better balance of vitamins and minerals.

**BEWARE:** many owners will feed a vitamin and mineral supplement in too small a quantity, and often infrequently; occasionally owners will feed several different brands at once plus cod-liver oil, and therefore give a completely unbalanced amount of vitamin D. In either case there can be disastrous consequences.

## Commercial diets

All-in-one diets have become widely available, and are theoretically a good idea. There is no doubt that an appropriate all-in-one pelleted diet is far better than a badly balanced diet; it also overcomes the problem of selective feeding. However, self-selection from a wide range of foodstuffs can be a good way of feeding a bird, but small quantities of each food item must be offered and a sensible dietary balance struck if selective feeding leading to nutritional deficiency is to be avoided. Constraining the individual bird to eat one dietary mix long-term is certainly boring for the bird, and also may produce nutritional problems over the years. This is especially likely because so many parrot species have different and inadequately researched nutritional requirements. Very few, if any, diets have been fed unchanged to significant numbers of individual birds for even a decade. Manufacturers have relied on the fact that breeding birds show dietary deficiency much more quickly than pet caged birds. As general advice to pet bird owners, an all-in-one diet should take the place of a seed mix and a proportion of various types of fruit and vegetables should be included.

Pet African grey parrots and cockatiels are the most frequently malnourished birds. Both of these will do well on pelleted diets, but there can be major problems changing many of these birds onto their new diet. Amazons, Pionus, macaws and cockatoos have a much greater liking for fruit and vegetables, and are therefore less likely to become malnourished. However, selective feeding will cause problems even in these birds.

## Protocol for dietary change

Under veterinary or informed supervision, the bird and its droppings should be observed for a few days to assess what is normal. The owner should be encouraged to regard parrot seed as sweets, cookies and craps: treats, but not a sensible staple diet.

The bird should be weighed daily for a few days before the dietary change starts.

Once the new diet has been selected, this alone should be placed in the cage in the morning and the food intake monitored. If no food is eaten during the day, some of the previous (well-loved) diet in a SMALL quantity may be mixed in for 15 minutes in the evening. Grey parrots can get enough calories for 24 hours from about a tablespoonful of sunflower seed, so if too much seed is provided they need not eat until the following night. Each day the new diet should be given in the morning, and less seed provided in the evening.

Alternatively the new diet can be mixed with the old diet and the ratio of the mixture altered over a period of time until the bird is provided with and eating 100 per cent of the new diet and none of the old.

Throughout this time, the bird's weight should be monitored, daily if possible, and the droppings observed. A lack of faeces indicates that no food is being eaten. Owners will always worry that their bird is likely to die of starvation; this is unlikely with the larger parrots, but is a possibility with cockatiels, lovebirds and budgerigars. The author had one Amazon who did not eat for 8 days and her weight only dropped from (a too fat) 550 g to (a still fat) 500 g over this period; on day 9 she ate the new diet well and continued to do so thereafter. However, this is not an ideal method of changing the diet, and has potential dangers.

As the new diet is eaten, enzyme systems in the gut and liver will change to accommodate the new food intake. The faeces will also change. On a fruit and vegetable diet the faeces will enlarge and lighten in colour, there will also be more fluid voided. Overweight birds with fatty livers will adjust more slowly, and must be regarded as high-risk patients. In these cases fasting is a danger, and it is useful to feed these birds and birds with other sub-clinical illnesses with a hand-rearing formula twice daily using a crop tube. This provides the birds with a well balanced diet, and prevents starvation whilst the birds acclimatize to their new diet.

The following weight chart indicates average weights for various species:

Species	Average weight	Range of weight (g) (number of birds)
Blue and gold macaw		950–1175 (5)
Green-winged macaw	1200	1060–1365 (10)
Scarlet macaw		750–1000 (6)
Grey parrot	500	395–585 (26)
Timneh grey parrot	325	
Senegal parrot	120	92–160 (14)
Blue-fronted Amazon	350	
Orange-winged Amazon	400	
Yellow-crowned Amazon		500–550 (6)
Maximillian's Pionus	230	200–242 (20)
White-capped Pionus	187	166–210 (14)
Bronze-winged Pionus	210	194–228 (9)
Blue-headed Pionus	230	206–270 (11)
Lesser sulphur-crested cockatoo	450	
Greater sulphur-crested cockatoo	800	
Moluccan cockatoo	850	
Cockatiel	90–110	
Budgerigar (wild birds)	30	
Budgerigar (pet birds)		30–85
Peach-faced lovebird (wild birds)		46–63 (29)
Masked lovebird (wild birds)		m 49 (8) f 56 (9)
Maroon-bellied conure		75–80 (7)
White-eared conure		50–55 (5)
Blue-throated conure		90–100 (30)
Painted conure		55–65 (10)
Ring-necked parakeet		120–135 (20)

It can be seen from this table that although it is easy to produce a guide for an average weight, it must not be relied upon as a weight for the individual. The above weights have mostly been taken from birds in the author's clinic that were anaesthetized after having endoscopic gender determination; they were not fat and were starved. In some cases there were too few birds to give an average weight. The weights for wild birds have been taken from Dunning (1993).

## Breeding and determination of gender: 'sexing'

All parrots form a strong sexual bond. They mature sexually between 1 and 5 years of age, depending on the species; smaller birds such as budgerigars are able to breed at 1 year old. On casual inspection, the majority of Psittaciformes are sexually monomorphic; however,

there are usually subtle differences between the sexes – for example:

- grey parrots are blacker if male and more grey if female
- orange-winged male Amazons have very much broader heads than females
- most male Pionus parrots have a larger eye than the females.

Individual variation makes these slight differences difficult to discern, and for many aviculturalists the birds' gender must be determined by endoscopic examination of the gonad or genetically from DNA. Some species have very obvious differences; for example:

- in eclectus parrots the males are predominantly green and the females are red and purple
- many of the small lorikeets (*Charmosyna* spp.) or cockatiels have obvious colour differences in their adult plumage although it is difficult to differentiate them sexually when they are immature as they all tend to have the female coloration
- many species of white cockatoos, when adult, have a brown iris if female and a black one if male
- most adult male budgerigars have a blue cere and females have a brown one.

## Nesting

Parrots nest in holes. A few species use nesting material; some lovebirds (*Agapornis* spp.) line the nest cavity with bark or twigs that they carry to the nest held under their feathers, but most chew up the wood inside the nest box to make a bed for the eggs. One species, the Quaker or monk parakeet (*Myiopsitta monachus*), makes a large communal twiggy nest. Parrots lay white eggs, usually on alternate days. Incubation commences immediately, and this means that young birds in the same nest will be of different ages. Some of the smaller parrots lay six eggs, allowing 11 days between the first and last youngsters; there is therefore a dramatic difference in size between the youngsters, but this seldom seems to cause a problem within the nest. Large parrots lay only two or three eggs. Baby parrots are nidicolous (helpless when first hatched and remain in the nest)

and ptilopaedic (covered in down when hatched). The parents regurgitate food directly into the mouths of their chicks. There is no evidence of the production of crop milk as there is by pigeons (Columbiformes) but, when looking at the difference in growth rates between hand-reared and parent-reared parrots over the first few weeks of life, it is evident that there must be some factor that makes parent-reared babies grow so much more quickly and also gives them a greater level of immunity.

## Hand rearing

Many breeders take over the rôle of parent birds. Eggs may be removed for incubation as soon as they are laid, but the hatching rate increases if the parent incubates them for the first one-third of the incubation period. Correct incubation temperature, regular weight loss and turning are the important factors for successful incubation. Eggs that are incubated at too high a temperature will be born deformed and too much humidity will prevent hatching or cause oedematous chicks that do not survive; too low a temperature or too dry an atmosphere will kill the chicks. Care must be given to regular rotation of the eggs on their long axis (turning); eight times daily seems ideal. Failure to turn the eggs results in the embryo sticking to the shell membrane and hence difficulty in hatching. Artificial incubation has been fully discussed by Low (1998).

Hand rearing has been made much easier by the formulation of specific hand-rearing diets by some petfood manufacturers. All the well-known reputable brands seem to be satisfactory. Owner-made rearing diets may be very good, but there is the risk that they may be improperly balanced and have poor vitamin and mineral supplementation; they are best viewed with suspicion. There are no excuses for producing malformed parrots due to inadequate nutrition, but this is unfortunately still very common. Baby birds are fed from a specially shaped spoon or via a syringe or crop tube; each of these methods requires patience, dedication and an immense amount of time. Hand rearing should not be taken on lightly.

Imprinting occurs in parrots as in all birds. Parrots that are hand reared without contact with their own species as siblings become misimprinted. Misimprinting produces very appealing baby birds that are greatly in demand in the pet trade, but may cause immeasurable difficulties over subsequent years. Weaning by the new pet owner, as encouraged by many pet shops, is to the benefit of the pet shop and not the bird. Hand-reared birds will often take twice as long to wean as parent-reared birds.

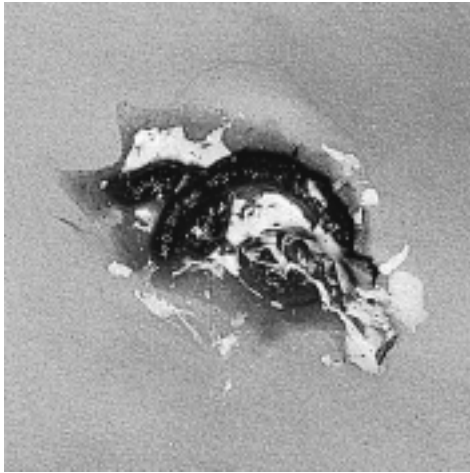
## Clinical examination of the ill parrot

The examination of the bird is described under each following disease section. However, examination of the cage and cage floor is almost as important as examining the bird. Owners should be asked, if possible, to bring the bird in its cage, and the cage should not have been cleaned out for at least 24 hours. The cage size (which gives an idea of how much activity the bird gets), the types of perches and their suitability should be noted; toys are a good guide to the 'owner type'; and food remains will prove or disprove the veracity of the owner's assurance that the bird gets a good mixed diet. Finally, the droppings and regurgitated food on the floor of the cage tell a story to the clinician.

## Droppings

Droppings consist of three portions:

- 1 Water and water-soluble products of excretion – these are initially excreted from the kidneys and refluxed into the terminal bowel, where complete or partial reabsorption takes place. The water content of the droppings can vary considerably in illness and health.
- 2 Urates – a white, pasty, colloidal solution from the kidneys. Uric acid is not water-soluble and is therefore secreted by the renal tubule and not filtered through the glomerulus. The colour of the urate portion can vary for a number of reasons.



**Figure 6.1** Normal parrot dropping (*Pionus* spp.). This bird was on a fruit, vegetable and pulse diet, which is a high-fibre, high water content diet. This is reflected in a moist, bulky dropping.

- 3 Faeces – black, brown or green in colour, usually having a solid worm-like appearance.

It is useful to become familiar with the normal droppings of the various genera, as droppings vary due to species as well as diet (Figure 6.1).

### **Abnormalities of droppings**

- 1 *Watery droppings.* The urinary portion may be very watery (the result of polyuria). Watery droppings can be normal in birds that are eating a lot of fruit or nectar, and scared birds pass droppings before reabsorption of water by the large bowel. Ill birds with polydipsia or polyuria – renal or hepatic disease, diabetes – pass very watery droppings. However, watery droppings are rarely neurogenic or behavioural. The watery portion should be tested with a (mammalian) dipstick test, the specific gravity should be measured and it should also be examined microscopically. If the urine contains particles or is flocculent, it should be centrifuged before testing. Normally, specific gravity is 1.005–1.020; pH is 6.5–8.0 and protein should be present as a trace in the urine but is present in larger amounts in the urates. Glucose is normally absent; blood, haemoglobin or myoglobin

will cause a similar reaction on a dipstick and should also be absent. Birds do not produce bilirubin but biliverdin instead.

- 2 *Discoloured urates* – usually green or yellow. Urates can be stained by faecal bile in normal birds, and this occurs especially in watery droppings (Plate 10). Discoloured urates can be caused by obstructive hepatitis of bacterial, chlamydial or viral origin; in these cases very green urates are due to biliverdin. Prehepatic overload from haemorrhage or bruising after surgery, trauma or large volume injections will cause the urates to be discoloured bronze or yellow.
- 3 *Diarrhoea.* This is a mixture of faeces, water and urates, and can be caused by worry, bacterial infections, papillomavirus or intestinal parasites. Diarrhoea on its own is rare in comparison with the condition in dogs and cats, and a diagnosis of diarrhoea must be differentiated from the polyuric bird and also the laying/incubating female. Birds laying or about to lay eggs store their droppings for longer than normal, and void a bulky, abnormal looking mass soon after leaving the nest box. This change starts a few days before laying the first egg.
- 4 *Presence of blood.* Blood may be mixed with faeces, and therefore from the bowel, or it may be in the urinary portion; it is usually difficult to tell. When seen, lead poisoning, intussusception or possibly viral, bacterial or parasitic infestations should be expected. Amazon haemorrhage syndrome is often caused by lead poisoning. Blood that is not mixed with the droppings but appears as drops or spots in or on them is usually cloacal in origin, and can be caused by an infected granuloma, urolith(s), viral papillomata, a prolapsed oviduct or large bowel and, very rarely, tumours.
- 5 *Presence of whole seed.* If seed is seen mixed in and coated with the faeces, the commonest cause is proventricular dilatation syndrome in parrots, macaws and cockatoos; however, it can also be caused by megabacteriosis, trichomoniasis and other bowel irritants. If the seed is separate from the faeces, it may be regurgitated.
- 6 *Lack of faeces but presence of urates.* This indicates starvation or an obstruction within the alimentary tract.
- 7 *Coloured faeces/urates.* Pigmented foods, such as beetroot or medications – even



topical medication – can change the colour of the faeces and/or urates.

It is important to look at the faeces microscopically: smeared, fixed and stained for bacteria, yeasts and parasites; as a wet preparation in saline for protozoa; and as a flotation preparation using a saturated solution of salt (NaCl), sucrose or zinc sulphate for parasite eggs and cysts.

## Regurgitation

As with vomiting in dogs and cats, regurgitation by birds can be frequently be a cause for presentation at the surgery (Plate 11). It may be due to:

- fear
- travel sickness
- sexual or courtship behaviour – feeding a mate, young, mirror images (male budgerigars), owners
- drug induced – handling and injections, or oral administration of various drugs
- proventricular dilatation syndrome
- poisoning or consumption of a gut irritant
- obstruction – goitre in budgerigars, intussusception, tumours (e.g. papillomatosis) or foreign bodies
- inflammation of the crop/proventriculus/gizzard – trichomoniasis, candida, megabacteriosis, fermented or hot food in hand-fed young birds.

## Sampling

A clinical examination will usually require augmenting with various samples taken for further examination.

### Blood

Blood samples may be obtained intravenously from the following sites:

- 1 The jugular vein – the right jugular vein is usually the largest, and lies beneath a featherless area of skin on the neck of the bird close to the oesophagus and trachea.
- 2 The brachial vein caudo-ventral to the humerus, or the ulnar vein on the caudo-medial aspect of the wing distal to the

elbow; both these sites usually require plucking for adequate visualization of the vein

- 3 Claws – small amounts of blood can be obtained by clipping a claw; a few drops are sufficient for a blood smear or DNA profile for sex determination. If this sample is to be used for biochemistry, make sure that there are no urates on the claw prior to collection.

Blood collected via a 25-gauge needle seems no more likely to be haemolysed than that obtained via a 23-gauge needle. Because of high venous pressure and a poorly developed dermis, haematomata are frequently formed. Haematomata can be limited by collecting blood under general anaesthesia, by manual pressure of the vein distal to the venepuncture hole using dry cotton wool, and by using the jugular vein. If the bird is conscious and struggling violently, the bleeding will continue while the bird is restrained; if the bird is replaced in its cage or box the bleeding usually stops in a few minutes. Birds can safely have 1 per cent of their body weight removed in the form of a blood sample. Using the jugular vein, budgerigars (*Melopsittacus undulatus*) can have up to 0.5 ml of blood collected; larger birds such as blue-fronted Amazons (*Amazona aestiva*) can have 1–2 ml collected from the ulnar vein or jugular vein. Very small birds can have a cleaned toenail clipped and blood can be collected, as it drips, in a heparinized capillary tube; one drop should be used to make an air-dried smear. It should always be assumed that the amount of subcutaneous bleeding will equal the sample removed. Vitamin K-deficient birds and those with lymphoma or severe liver disease can bleed to death.

Most commercial laboratories will perform haematology and biochemistry on a heparinized sample. Some authorities prefer it for biochemistry, providing the sample is centrifuged immediately and the plasma removed. A heparinized sample yields more plasma than a clotted sample yields serum; if only a small sample of blood can be taken, then place it in heparin. If a heparinized sample only is collected, then several air-dried smears should be made of whole blood, from the syringe, immediately after collection. However, whole heparinized blood is required by the lab to enable them to do a cell

count. Unfortunately the whole blood degrades in the post, and cellular components fragment and release enzymes and electrolytes into the serum. Therefore it is more satisfactory to obtain blood for haematology in EDTA and a gel heparin tube for the biochemistry. Gel tubes, which are centrifuged and separate the blood cells from plasma by a barrier of gel, are vital if the blood is to be posted to the laboratory because they prevent distortion of the results.

### ***Bacteriological samples***

Faecal samples may be obtained from the floor of the cage, and defecation on new paper is the most satisfactory method of collection. A cloacal swab is too hit-or-miss; the swab may be collected from any of the three cloacal chambers, and as it is usually faeces that are required it is more satisfactory to obtain them after defecation. Because of rapid excretion of many drugs via the kidneys and or liver, faeces should be collected prior to any medication.

### ***Samples for PCR tests in the live bird***

Cotton buds or swabs on plastic are preferred to those on wood. For chlamydia, it is best to obtain three swabs by swabbing the choana and the conjunctival sac and taking a faecal sample. No transport medium is needed. If cost is an issue, the choana should be swabbed in upper respiratory tract cases, the conjunctiva in cases of conjunctivitis, and faeces collected from ill birds with urates discoloured green with biliverdin.

Psittacine beak and feather disease requires live feather pulp, from an erupting feather quill, to be milked out of the shaft into a container of transport medium.

Polyomavirus tests are most reliable using a cloacal swab.

## **Diseases**

Diseases of psittacine birds have been studied for many years, and there are comprehensive accounts of the diseases of parrots (Zürn, 1882). Many diseases are very accurately described, even though the causes and cures

for many of them were obviously elusive and not understood by these early authors.

## **The dyspnoeic bird: diseases of the respiratory system**

Parrots are frequently presented with a combination of respiratory signs: sneezing, nasal and/or ocular discharges, noisy breathing, changes in voice and dyspnoea. Some birds will learn to mimic human coughs, and these birds do not have respiratory disease. Also, clinically normal Pionus parrots will hyperventilate when they are upset or worried.

### ***Examination***

Observe the bird in its cage, from some distance away, and note its degree of respiratory embarrassment. Birds with difficulty breathing 'bob' their tails up and down with each breath. Occasionally it is possible to see that the bird has a distended abdomen. Look for discharges, etc., and at the droppings. Ask the owner about the duration and severity of any signs, the bird's diet (with special reference to vitamin A sources), and previous treatments and their outcome.

Before catching a bird in severe respiratory distress warn the owner that this may be a risky procedure but that the bird will never get better if it is left in the cage. Catch the bird as gently as possible and keep it upright; this avoids any fluid in the air sacs swamping the lungs and drowning the bird. Birds dislike mouth breathing, and will attempt to breath through their nostrils even when these are obstructed; this means that it may be difficult to differentiate between upper and lower respiratory disease when the bird is in its cage.

To examine the upper respiratory tract, catch the bird, wrap it in a towel and look at its face. The nostrils should be cleared of discharge and checked for rhinolith masses. The nostril normally has a small piece of tissue protruding into its centre – the rostral concha. Observe the bird's face from dorsal and cranial aspects for subcutaneous masses or swellings in the infra-orbital sinus, and press gently into the sinus and around the eye to see if exudates can be forced out of the nostril or lachrymal duct. Tempt the bird with

your finger to make it open its mouth and examine around the tongue and also look at the choana; if necessary use a suitable gag. If the nostrils are not obstructed and there is no discharge, hold the beak shut and occlude first one nostril and then the other; listen for bubbling sounds, stertorous noises or lack of passage of air. All these indicate problems that need further investigation.

Some wheezing sounds can be from the larynx if this is involved in the pathological process. The entrance to the larynx can be seen with the bird's mouth held open by a gag.

Open-mouthed, apparently obstructed breathing and a change or loss of voice indicates a syringeal or possibly tracheal problem. Small birds can have their trachea transilluminated to examine for foreign bodies; part the feathers along a feather tract and damp them down prior to this examination. Larger birds can have their trachea and syrinx examined endoscopically, but this requires a general anaesthetic. In birds with tracheal obstruction, a general anaesthetic can only be administered safely via an air sac tube.

Auscultation should always be attempted, even when the bird is making a lot of noise; useful information can still be obtained that can confirm lower respiratory tract problems. Listen to the ventral, lateral and dorsal aspects of the body on both sides of the bird. Birds with lower respiratory infection often have 'crunchy' heart sounds, as if the beating heart is wrapped in crumpled cellophane. The air sacs should be auscultated ventrally and laterally. The lungs are best heard on the dorsal aspect of the bird, over the ribs.

Palpate the abdomen for abdominal distension with fluid or organ/tumour enlargements. This can cause dyspnoea by preventing the air sacs from circulating the air.

Many respiratory conditions require an anaesthetic for examination, diagnosis and treatment. Birds with apparently only upper respiratory disease frequently have a concomitant pneumonia, which may not be obvious. It is prudent to treat these birds for a few days with a broad-spectrum antibiotic such as enrofloxacin prior to an anaesthetic.

All birds with respiratory disease should be suspected of being vitamin A-deficient, and their treatment should include vitamin supplementation. An oral multivitamin and mineral supplement specifically made for birds is

preferred, but changes will take up to a year to occur fully. Injections of multivitamins are not very useful and are occasionally fatal.

### **Specific problems**

#### *Rhinoliths*

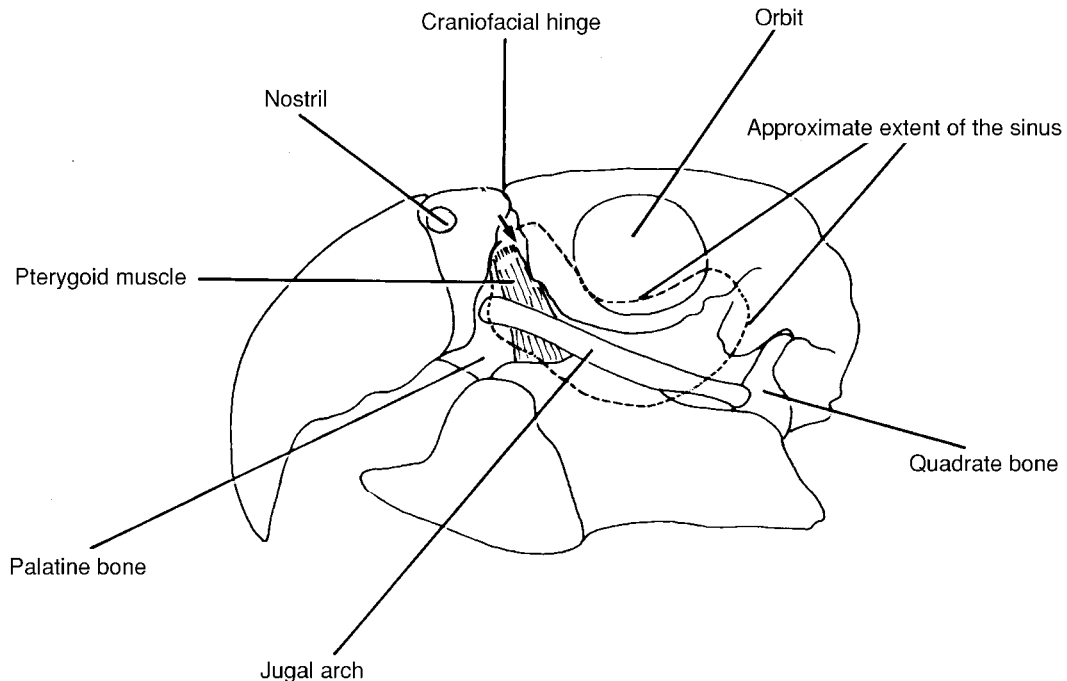
Rhinoliths are hard, crusty lumps blocking the nostrils and causing breathing difficulties. They are very common in African parrots such as the grey and the red-fronted (Jardine's) parrots (*Poicephalus gulielmi*). Hook the rhinoliths out of the nostril using a small dental osteotome, shaped like a tiny teaspoon about 1.5–2 mm in diameter (Plate 12). This instrument can be introduced behind the mass and used to lever it out. There is frequently mucopurulent discharge behind the rhinolith in the nasal cavity, and occasionally in the sinuses. Clean the discharge out and instil neomycin or gentamycin eye drops twice daily into the nostril; re-examine after a week of treatment to clean out again. Medium to large rhinoliths will have deformed the bony structure of the nostril and will often recur, requiring regular (about 3-monthly) removal (Plate 13). Vitamin A deficiency will play a significant part in this condition.

#### *Chlamydia*

Watery conjunctivitis, which may give rise to a wet nasal discharge and occasional sneezing, is typical of chlamydiosis. This manifestation of chlamydiosis is most common in Australian parakeets, including budgerigars and cockatiels. The birds are not usually unwell, but they can infect other birds, which will die of the hepatic form of chlamydiosis and are potentially zoonotic. Confirmation with a PCR test on a conjunctival or choanal swab is required. Treatment with chlortetracycline eye ointment and oral or parenteral doxycycline is usually curative within a month.

#### *Sinusitis*

Sinusitis is typified by swellings of the infra-orbital area. Nasal and ocular discharges are also possible signs. Culture of mucopurulent material obtained by aspiration of the sinus is vital for treatment. Many cases are colonized by Gram negative organisms such as *Pseudomonas*. *Mycoplasma* spp. could be involved in moist sinusitis; enrofloxacin will kill this



**Figure 6.2** A lateral view of the skull of a Blue and Gold Macaw (*Ara ararauna*) showing the approximate extent of the infra-orbital sinus (broken line), the site of insertion of a hypodermic needle for sampling or flushing the sinus (arrow), and the position of the pterygoid muscle. The pterygoid muscle has an overlying artery and vein (and nerve) which are easily punctured if the needle is inserted too deep. This will cause a profuse haemorrhage.

For injection, the nostril and eye should be noted and midway between them it is possible to palpate a bone-free depression, bordered ventrally by the jugal arch. This space is increased by opening the bird's mouth. A needle is inserted here (arrow), directed slightly caudoventrally to enter the infra-orbital sinus. Using a syringe, it is possible to aspirate the contents of the sinus, which should normally be air. In a macaw the needle should be inserted no more than 5 mm, as the sinus is subcutaneous at this point.

bacterium. Daily flushing by injecting into the sinus or flushing through the nostril is the best treatment for moist sinusitis (Figure 6.2). Some sinusitis are inspissated, palpable and too hard to flush out and must be surgically removed.

#### *Choanal abscesses*

Choanal abscesses will cause nasal discharge and difficulties breathing through the nostrils. They are best seen in an anaesthetized bird. It is usually wise to give a course of enrofloxacin for 4 or 5 days before anaesthesia and surgical removal of the abscess. The abscess is sometimes seated on the dorsal aspect of the choana, and the edge of the structure must be rolled back to reveal the abscess. A 21-gauge hypodermic needle is useful as a stylet to

open the epithelium, and a small blunt probe, such as a Dandy hook, is needed to express the inspissated pus.

#### *Laryngeal aspergillosis*

Laryngeal aspergillosis has, in the author's experience, been a cause of dyspnoea in imported *Pionus* spp. Removal of the purulent material from the *rima glottidis* and treatment with itraconazole or topical clotrimazole can be successful, but this condition carries a surprisingly poor prognosis.

#### *Foreign bodies*

Tracheal foreign bodies will cause severe dyspnoea. A millet seed is a common foreign body in a cockatiel that is having difficulty

breathing, and transillumination will show its presence. An air sac tube and general anaesthesia gives a chance of removal. Stop the seed slipping down the trachea with a 25-gauge needle through the trachea distal to the seed, then partially open the trachea with a cut between the rigs and remove the seed. Repair the trachea with fine suture material.

### *Aspergillus infection*

*Aspergillus* infection of the distal trachea, syrinx or primary bronchus is a common cause of dyspnoea; it will also affect the lungs and air sacs (see later). This condition should be suspected in a dyspnoeic bird that is wheezing and has had a change of voice. Diagnosis requires an anaesthetic and endoscopy. A 2.7 mm 0° endoscope should be used to examine this area in Amazons, cockatoos, large macaws and large grey parrots. A parrot's trachea tapers distally, and smaller birds are impossible to examine without a smaller endoscope. A general anaesthetic using an air sac tube will allow suction through a catheter placed into the syrinx. This technique can suck out the majority of the lesion. Treatment with itraconazole orally and clotrimazole by nebulization is required to prevent recurrence. The bird should be re-examined a few days later, as the *aspergillus* and caseation can regrow. This condition is common in grey parrots, and carries a poor prognosis; these birds should be referred to an avian vet.

### *Syringitis*

Syringitis can be seen in some birds that have a voice change and/or an 'asthma' attack. Endoscopy will reveal an irritated syrinx with moist swollen edges to the syringeal valve and no sign of aspergillosis. This condition can be brought on by bacterial infection or some irritant trigger, such as cooking fumes from the oven. A spasm of the syrinx can be induced during anaesthesia in some birds, causing fatal asphyxia, which may not be noticed in time to place an air sac tube.

### *PTFE poisoning*

Polytetrafluoroethane (PTFE) poisoning from overheated non-stick Teflon®-coated cooking

utensils is a common cause of severe, rapid, terminal pneumonia. Over-heating is not difficult if the pan is empty, and it causes the coating to depolymerize to form a lethal vapour; birds in the same airspace will drop off their perches, dead, within half an hour of inhaling the vapour. Some self-cleaning ovens and spotlight bulbs are also coated with Teflon®. Examination of the lungs at post-mortem shows oedematous bloody lung tissue throughout both lungs.

### *Lung and air sac aspergillosis*

Birds with generalized aspergillosis can be either acutely affected, in which case they are presented either dead or with sudden onset of severe dyspnoea, or they can be chronically affected, in which case they can be presented as unwell (to greater or lesser extent), underweight (in spite of eating reasonably well) and dyspnoeic; again the degree varies, and is usually worsened by stress and exercise. There is little change in voice, but examination with a stethoscope reveals an increase in audible respiratory sounds. Diagnosis is by clinical examination, a blood sample will reveal a very elevated heterophil count (15 000–40 000 cells/dl) and an X-ray will typically show a locular pattern in the lung and/or air sac region. Treatment using itraconazole orally and clotrimazole by nebulization can be successful in producing a cure.

### *Air sac worms*

Air sac worms can be seen in recently imported birds as an incidental finding at post-mortem examination or during endoscopic gender determination. These worms do not seem to cause disease, and can usually be safely ignored. Treatment with ivermectin should be successful, but could cause problems by producing dead worms in the air sacs.

### *Abdominal distension*

Abdominal distension (e.g. tumours, hepatic enlargement, proventricular enlargement, ascites, egg-production) will prevent the air sacs functioning and cause dyspnoea: All should be differentiated on radiography, with the use of contrast and other techniques if

required. Serositis will also cause the abdominal and hepatic peritoneal cavities to fill with fluid and will cause dyspnoea. This condition appears to be a sequel to a viral infection.

## Diseases of the digestive system

Probably the most common presenting sign for any clinician is a bird that is eating less food than usual and has loose droppings. It may have lost weight, and may also be regurgitating. Some birds may die suddenly; other birds may be more chronically affected.

### Examination

The owner should be encouraged to bring the bird to the surgery in its uncleaned cage; half the clinical signs are found on the cage floor. Examine the bird from a distance looking for signs of illness, dyspnoea, general condition, soiled feathers around the vent, etc, then examine the droppings on the cage floor. It is uncommon for birds to have diarrhoea, and common for them to be polydipsic. Normal faecal shape varies between species: Budgerigars and cockatiels produce small, dry, comma-shaped droppings; macaws produce large, moist droppings; lorikeets produce mostly liquid. Faecal consistency reflects the diet; fruit and vegetable diets give large, wet droppings, while seed diets give small drier droppings.

The presence of soft, swollen, undigested, hulled seeds with no mixing of faeces is a sign of regurgitation.

The dropping (faecal/urinary mass) may be well formed if the bird is eating, but will be small, dark green and watery with white urates if not. It may be poorly formed in birds with diarrhoea, but also in scared birds or birds with papillomatosis or granulation tissue/cloacoliths of their cloaca. It may be blood-stained, or coated or mixed with blood. Sometimes droppings contain whole undigested seeds; this is abnormal. Take a faecal portion for microscopy and possibly microbiological culture. Check for parasites, bacteria or yeasts.

Next, assess the urinary portion. In birds on a dry diet, such as parrot seed, the urates should be formed and white with little water. If there is a lot of water in the diet (fruit, vegetables, pulses, nectar) or if the bird is polydipsic, then there will be a quantity of water passed with the urates. Metabolites, etc. may be visible in the urates: light green to dark green urates indicate a hepatitis; green to bronze urates can occur after trauma and bruising and can also be caused by hepatitis; some topical medications and food colourings will be excreted in the urine (e.g. topical proflavine can give yellow urates or beetroot can give purple colouring); neither affect the bird. If the faeces contain a lot of water, use a dipstick test to check for glucose, blood and protein content. It is usually possible to avoid faecal contamination.

Next, examine the bird; catch it, look in its mouth and at the tongue; palpate the crop, thoracic inlet and abdomen; examine the cloaca. If the crop is distended, then pass a crop tube and obtain a crop contents sample. Smear this on a slide and stain, looking for bacteria, yeasts and protozoa; also look at a wet preparation. Carry out a microscopical faeces examination – wet and fixed stained preparations as well as a worm egg count.

In the author's opinion, the commonest cause of a sudden onset illness with watery droppings in a single bird is a bacterial hepatitis or enteritis. Heart blood taken at post-mortem examination within 20 minutes of death has invariably produced a pure growth of a coliform, usually *Escherichia coli* (although it could be *Klebsiella* spp. or *Pseudomonas* spp., etc.).

Clinical signs are an ill bird with watery droppings containing some or no faeces and, often, light green urates. Some birds will regurgitate food, especially after travelling or following i.m. injection. The bird should be assessed for hydration (crinkly skin around the eyes or skin pinch that remains tented; weight loss, assessed on pectoral mass and weighing; crop palpation and abdominal palpation should be unremarkable). The vent should be clean.

Faecal examination tests for birds with watery droppings, in order of preference, include:

- 1 Faecal floatation for parasites.
- 2 Microscopy for protozoa (dilute faeces with warm normal saline and watch for jerking swimming movements of single cell parasites – but note that particles smaller than a single cell can exhibit Brownian motion and may be mistaken for parasites).
- 3 Gram's stain – this may reveal lots of coliforms rather than Gram-positive cocci, indicating abnormal gut bacteria.
- 4 Bacteriology – this can be useful, but hopefully the result will arrive after the bird is better. Check for *Salmonella* spp. (*Salmonella typhimurium* is common), especially in imported grey parrots, but can be seen in any birds.

If a diagnosis of bacterial hepatitis seems likely, then inject with a broad-spectrum antibiotic (such as enrofloxacin), use a crop tube to give the bird some fluids and place the bird in a warm, darkened cage. If the bird starts to improve, it must be fed four times a day with some easily digestible food by crop tube and injected twice daily with enrofloxacin. If the bird worsens, a change of antibiotic is indicated. The author's favourite choice is a combination of lincomycin and tobramycin administered twice daily; adequate fluid must also be given.

Further investigation is required in birds that are not responding to treatment. It can be useful to combine the following procedures and possibly carry them out under anaesthetic, as it is less stressful to the bird. Take a blood sample for haematology and biochemistry; with a bacterial hepatitis there will be an elevated WBCC with increased heterophils and a left shift, and elevated gamma glutaryl transferase and bile acids but normal uric acid, urea and glucose. A low albumen level is useful as guide to chronic ill health, and a high PCV and high urea are indicators of dehydration.

After taking the blood sample, slowly inject an i.v. bolus of N/5 glucose saline; 5 ml to an Amazon or grey parrot and up to 10 ml to a large macaw. An indwelling intravenous or intraosseous catheter with continuous fluids is useful but more complicated. Intravenous catheters can be placed in the basilic vein on the ventral aspect of the wing, by the humerus. The bird must be restrained from pulling out indwelling catheters, and a collar

or wing strapping is usually necessary. If i.v. fluids are to be used, be very careful to avoid over-perfusion; use a burette or a slow injection system. Do not use a 500 ml bag of fluid, as it is only too easy to administer the whole bag, with fatal results.

Radiology should also be carried out at this time, and in cases of bacterial hepatitis there will be a normal or enlarged liver and kidneys (septicaemia/bacteraemia) or a normal liver and large spleen (enteritis). Note that green urates and a large spleen along with an enlarged liver usually indicates chlamydiosis; therefore, perform a PCR test.

The gizzard usually contains grit, but check for lead, glass or metallic foreign bodies, all of which can contribute to conditions resulting in hepatitis/enteritis.

### ***Specific problems***

#### *Proventricular dilatation disease*

Larger parrots, such as grey parrots, macaws and cockatoos, may be presented with signs of weight loss and regurgitation or weight loss and the passage of whole seeds; they may also exhibit neurological signs such as trembling and unco-ordination; many birds will appear to be hungry and make pathetic begging-for-food noises. Most of these cases have proventricular dilatation disease (PDD). This is an infectious disease, almost certainly of viral origin. PDD may be seen in birds of any age. Diagnosis in the live bird is aided by radiography (Figure 6.3). Lateral and ventro-dorsal views often show a dilated proventriculus and gizzard. A barium meal may be needed to demonstrate this or show a slowed passage of ingesta. Fluoroscopy will reveal that the normal movement of the gut has been compromised, and instead of peristalsis the wall of the proventriculus and gizzard 'flutters' (Storm and Greenwood, 1993).

Confirmation of the diagnosis in a live bird may be obtained in many cases from histopathology on a biopsy of the crop; this is relatively easy to perform. Under general anaesthesia (intubation of the trachea is vital), removal of a portion of full-thickness crop wall to include at least one large blood vessel will allow histological examination of the

autonomic nerves and associated ganglia, as they are found adjacent to the arterial supply to the bowel. Approximately 75 per cent of cases can be confirmed with this test (Gregory *et al.*, 1996). A full-thickness proventricular biopsy is probably better, but is much more invasive.

Post-mortem examination can be used to confirm the diagnosis in most outbreaks of this disease, as there is a high mortality rate. The crop, proventriculus and gizzard can be variously thin-walled, dilated and impacted with seed; surrounding tissues often exhibit peritonitis. The duodenum can also be dilated in some birds, especially cockatoos. Occasionally there is ulceration at the proventricular/ventricular junction, and this ulcer can perforate with fatal results. The lungs often show acute aspiration bronchitis and pneumonia. Histopathology is required to confirm the suspicion of this disease by the presence of lymphocytic, plasmacytic ganglioneuritis involving the autonomic ganglia at various levels in the gut wall. The brain also shows similar changes.

Treatment of this disease is possible, and some individuals recover. Treatment is empirical: a high-fibre, moist diet, with little seed; broad-spectrum antibiotics to prevent peritonitis and pneumonia (trimethoprim/sulphonamide is the author's first choice); and use of a prokinetic-cisapride (Prepulsid, Janssen), which can be very helpful. The recovered bird could be a carrier; however, apparently normal birds can also be carriers, and as there is no reliable test developed that can detect the carrier state, treatment seems a reasonable option.

### *Papillomatosis*

Weight loss, regurgitation and a soiled vent may be caused by papillomatosis. This disease usually affects the upper alimentary tract and cloaca of birds that have been imported from Central America. Hawk-headed parrots, macaws and some Amazons are those most commonly affected. The birds appear to have diarrhoea and their vent is soiled with faeces, which sticks to the feathers in lumps. Budgerigars that exhibit these signs are usually too fat to clean their vents; they do not have papillomatosis. On cleaning the vent, a protruding mass of tissue

may be seen. Check the oral cavity – papillomata are frequently found around the choana and the rima glottidis, and these papillomata can extend through the alimentary tract. Removal of the papillomata that are causing problems is helpful. Histopathology will confirm the typical appearance of the disease. Mild cautery of the lesions around the vent will often be sufficient. The disease will make the bird unwell, but this illness alternates with periods of good health in a cyclical manner; the periodicity in one closely observed case was around 4 months. Therefore, any and all treatments seem to work well for a time. Autogenous vaccines do not cure the disease. A papillomavirus has never been isolated from these cases, but a link has been made with a herpesvirus as a cause of this condition (Phalen *et al.*, 1998). In the long term, many of these birds become affected with malignant tumours of the pancreas and related structures (Graham, 1991)

### *Salmonellosis*

*Salmonella* spp. can affect parrots, especially newly imported birds. The usual isolate is *Salmonella typhimurium*. Affected birds may die suddenly, but many cases are ill for a period with signs of general septicaemia: profuse watery diarrhoea; polydipsia/polyuria; dyspnoea/pneumonia; depression; inappetence and, occasionally, neurological signs. Confirmation is on bacteriology. Treatment with a broad-spectrum antibiotic (such as enrofloxacin) with supportive nursing and feeding will often allow the bird to recover, but a number of cases remain carriers and these individuals may or may not be chronically unwell. Three samples of faeces must be found to be clear of *Salmonella* spp. to rule out the carrier state; one sample is not sufficient. Carriers may be cleared by the use of an autogenous, inactivated vaccine. Two doses of vaccine 2 weeks apart have been found to clear carriers; each dose should be given orally (1 ml) and as a subcutaneous injection (0.5 ml). This regimen gives a significant rise in antibody titre (Harcourt-Brown, 1986). Salmonellosis is a zoonosis, and appropriate measures must be taken. Other coliforms will produce similar, but usually less dramatic, signs of illness.



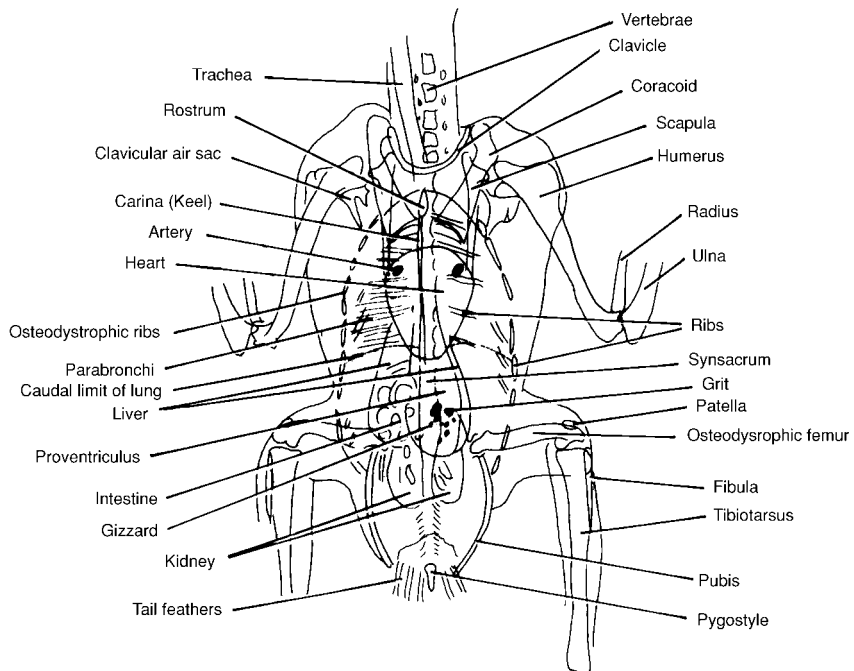
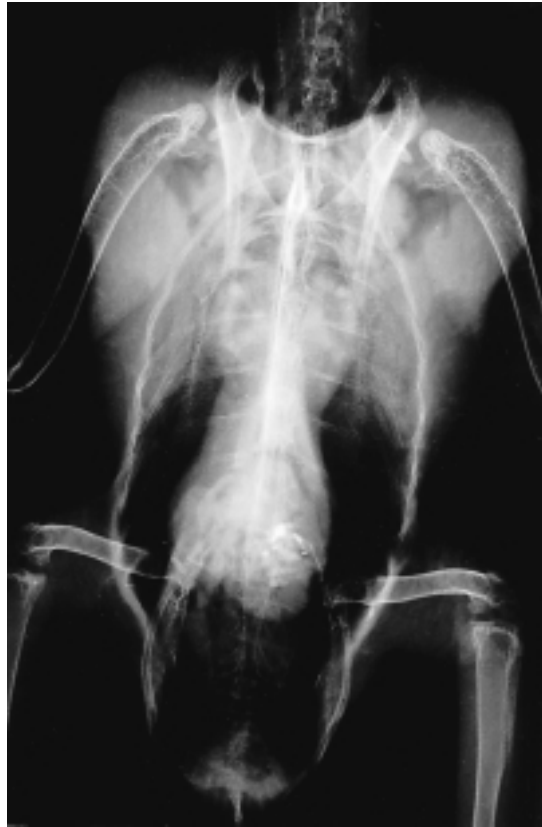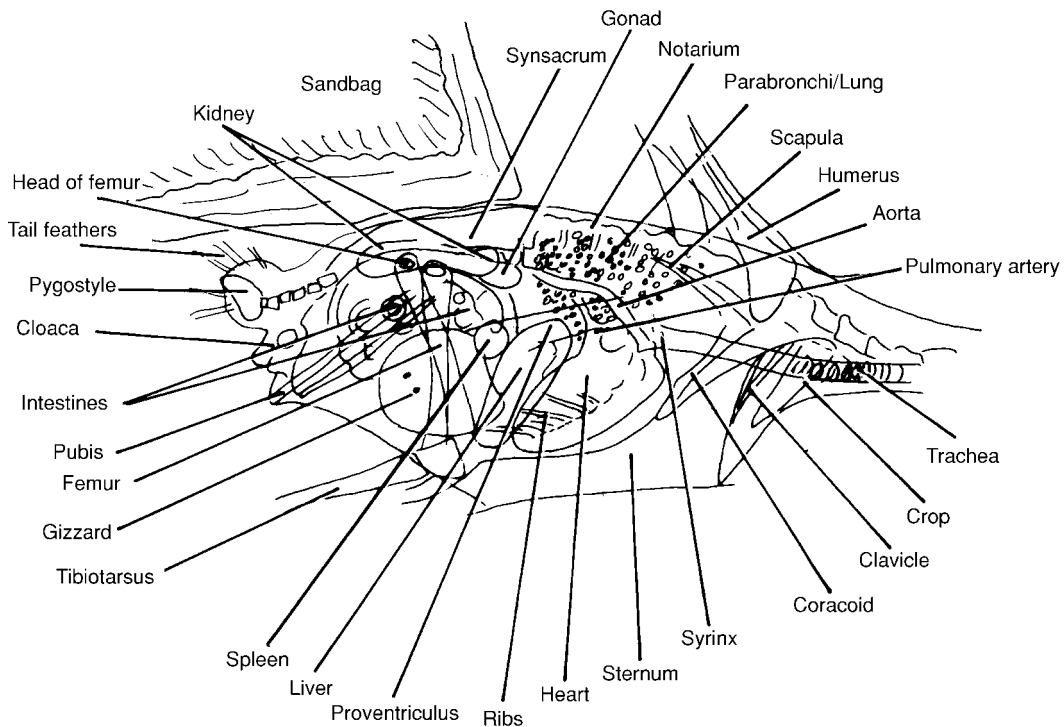
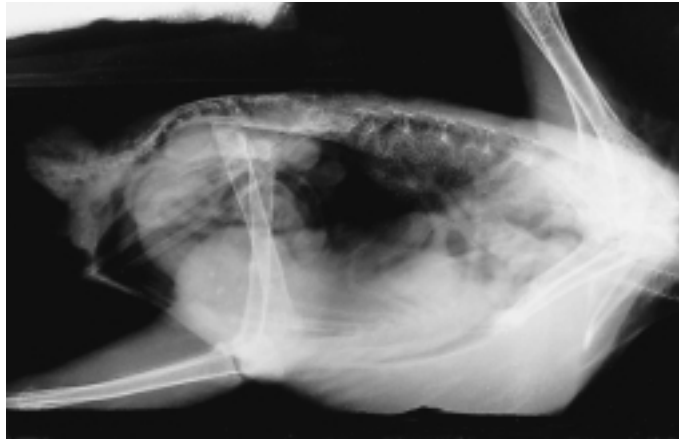


Figure 6.3 (a) Ventrodorsal views of an adult Grey Parrot (*Psittacus erithacus*)



**Figure 6.3** (b) views of an adult Grey Parrot (*Psittacus erithacus*)

### *Pseudotuberculosis*

*Yersinia pseudotuberculosis* is a common cause of outbreaks of acute illness and mortality, usually in aviary parakeets. It is transmitted via faeces from infected rodents and wild birds. The majority of affected birds die within a few days, having shown signs of

pneumonia, enteritis with wet diarrhoeic droppings, and general ill health. At post-mortem examination the most acute cases have an enlarged, patchily discoloured liver, and more chronic cases have miliary white spots throughout the liver. Similar changes are found in the kidneys and spleen. Confirmation by bacteriology is needed, and antibiotic

treatment is required. The drinking water must be kept uncontaminated, and the flock will recover more quickly if the water contains either the appropriate antibiotic or a disinfectant such as 5–6 mg/l of free iodine or chlorhexidine. Prompt treatment will limit but not completely prevent deaths in the affected birds; the organ damage in some individuals will cause their death even in the absence of the organism.

### *Digestive problems in budgerigars*

Budgerigars are often presented because they are regurgitating their seed or a white pasty substance. In many cases the birds are well, and the regurgitation is onto their mirror or some other reflective surface, or onto their owner. These birds are in breeding condition, and it is a normal part of their behaviour to try to feed their 'mate'. Budgerigars that are on an unsupplemented, shop-bought, loose-seed diet will usually be iodine deficient, and the goitres that form can block the thoracic inlet sufficiently to cause regurgitation. Goitres may also affect the action of the syrinx and cause a wheezing respiration and an altered (or lost) voice. The enlarged thyroid may occasionally be palpable at the thoracic inlet. Supplementation with iodine will quickly alleviate the problem; a stock solution of 2 ml of strong Lugol's iodine solution is added to 30 ml of water, and one drop of this is added to 250 ml of drinking water, daily for treatment and two or three times weekly for prevention.

In some cases birds are unwell, losing weight and regurgitating sporadically. These ill budgerigars will have yellowish staining on the feathers around the beak; are thin; their crop often feels thickened and may be distended with fluid; the vent is frequently soiled; and the bird's droppings are enlarged and wetter than normal. After some time with these signs, many budgerigars will die. Crop contents should be examined. It is possible to obtain crop fluid in some birds by milking the crop contents up the oesophagus, and the birds will then spit out some of the thickish fluid. If this is not possible, passing a crop tube and introducing about 1 ml of normal saline and then aspirating will give a sufficient sample for examination. Warmed wet preparations will reveal trichomonas parasites. The other cause of these signs, mega-

bacteria, will show on a dried and stained smear. Some birds have both problems. Occasionally yeasts (*Candida* spp.) are seen in the smears as well. Treatment with a mixture of amphotericin B (which will kill both yeasts and megabacteria) and metronidazole (which kills trichomonads) given via a crop tube or by mouth as a drop, twice daily for a week, will resolve the symptoms. These conditions are very common in budgerigar breeders' aviaries, and in these cases treatment of the entire flock is needed. Faecal examination may reveal megabacteria, but only very fresh faeces will contain recognizable trichomonads. In all cases, negative results do not rule out these diseases. Megabacteria are in their greatest numbers in the proventriculus; trichomonads perish and disintegrate very rapidly. Post-mortem examination of a recently dead bird will allow samples to be taken from the oesophagus, gizzard and crop and examined by the hanging drop technique and as smears stained with Gram's stain or diff quik. This will give a reliable diagnosis. The diseases caused by megabacteria, trichomonas and candida can be seen in other psittacine birds.

### *Parasitism*

Examination of faeces from psittacine birds will, on occasions, reveal various other intestinal parasites. However some species of birds are more susceptible than others. *Giardia* spp. is an infrequent cause of diarrhoea (it can also cause feather-plucking in cockatiels) and may be difficult to demonstrate in the live bird as it is found in the upper small intestine; it should be looked for at post-mortem examination of a fresh carcass, using the hanging-drop technique. Australian parakeets are frequently affected by roundworms; the birds look ill and this disease will cause sufficient weight loss for the birds to die. The worms may not be laying eggs, so a negative faecal examination should not be trusted. It is vital that every ill Australian parakeet is wormed with a dose of fenbendazole (Panacur 2.5 per cent Hoechst, at a single dose of 50 mg/kg) given by crop tube. If possible, the bird should be kept separately so that the droppings may be examined over the next 2 days for dead worms. A small parakeet may contain up to 50 large worms. Roundworms, in the author's experience, are the commonest cause of death of this group of parakeets.

Macaws (*Ara* spp.) with low-grade ill health may be seen passing large, wet droppings. Examination of the faeces by floatation in saturated salt solution will reveal the typical eggs (small with bipolar plugs) of *Capillaria* spp. In-contact birds may also be infested, and faecal samples should be checked. Affected birds must be dosed regularly with fenbendazole and great attention must be paid to hygiene, or re-infestation will result. Outdoor cages, suspended in a sunny position, with frequent showering/hosing of the birds and cage and with 2-weekly dosing with fenbendazole on an individual basis is required to remove this problem.

Post-mortem examination of psittacine birds has been covered comprehensively by Simpson (1996).

### *Chlamydiosis*

Chlamydia (or psittacosis) is the disease that is always linked with parrots. It was first reported in man and psittacine birds in 1895 (Morange, 1895). However, it has been found in many species of birds, especially in domestic ducks and pigeons.

In parrots, it can give rise to several syndromes. First, there can be symptom-free carriers that shed the organism intermittently and may remain carriers for many years. The carrier state is commonest in Amazon parrots and in commercially-bred cockatiels and budgerigars. Secondly, some birds become extremely ill with a severe hepatitis; they are depressed, lose weight, may have respiratory signs, and have droppings in which the urate portion is often a vivid green colour due to biliverdin levels in the blood rising above the renal threshold (owing to obstructive liver disease). These birds have been previously uninfected, and have then contacted the disease. In the author's experience, grey parrots seem to be uncommon as carriers but very susceptible to the disease, which is frequently caught from a symptom-free carrier such as a cockatiel. Thirdly, some birds, especially Australian parakeets, are presented with a unilateral or sometimes bilateral conjunctivitis; occasionally these birds are also unwell. Finally, some birds become chronically ill a result of chlamydiosis, and may even develop immunocomplex-linked glomerulonephritis.

Birds with chlamydiosis should be treated, as many will make a complete recovery

and, with adequate treatment, will not be carriers.

Diagnosis is best attempted using a PCR test to detect the organism. Blood samples for antibody levels and ELISA tests are less easily interpreted and less reliable. Ideally, three samples should be taken; a swab from the conjunctiva, a swab from the choana and a faeces sample. The PCR test will take some time, so treatment should be instituted immediately. Two drugs kill chlamydia *in vivo*; enrofloxacin and doxycycline. It is now considered that doxycycline is the most effective drug, and this can be given by injection, in food or in the drinking water. Doxycycline must be administered for 45 days to cure the bird in most circumstances. All birds should be checked after they are 'better', and providing that three samples taken at different times give a negative PCR result, the bird can be considered 'cured'.

### *Avian tuberculosis*

Occasionally, parrots are presented with weight loss and/or slowly growing lumps. These birds may have *Mycobacterium avium*. Smears from strange-looking masses may frequently reveal acid-fast organisms. Many of these birds are excreting the bacillus, and it is possible to pick this up using a PCR test for *M. avium*. Although some cases have been treated, there is a zoonotic potential as well as the health of other birds to consider. Birds suffering from avian tuberculosis should be euthanased.

## **Diseases of the urinary system**

The truly polydipsic bird is often presented. Budgerigars, cockatiels and grey parrots are seen most commonly, perhaps because they are the most frequently kept pets.

Examination should consist of looking at the bird in the cage for signs of general illness, dehydration, abdominal distension, dyspnoea or leg weakness. The droppings should then be examined for consistency of the faecal portion, quantity of water and colour of the urates. Finally, the bird should be removed from the cage and examined in a routine manner. Many of these birds will be on a deficient diet, and this should be borne in mind.

An important point is that birds are uricotelic. They produce uric acid in the liver as an end product of protein catabolism. The uric acid is excreted via the kidney as a colloidal solution from which all the water can be reclaimed, either within the renal tubule or by the large bowel. Uric acid is excreted by the tubule; urea and other water-soluble products are filtered via the glomerulus. After excretion via the ureter, the urine is carried by retroperistalsis from the urodeum into the large bowel, where water is reabsorbed, leaving only urates. By producing uric acid (which is insoluble) and not urea (which is water-soluble), a uricotelic animal can develop in a shelled egg without being poisoned by the waste products of protein catabolism. In embryonic birds the uric acid is deposited within in the foetal membranes, i.e. outside the foetus.

Renal disease can be very difficult to diagnose. Uric acid levels tend to remain unaltered even when there is chronic disease, because the uric acid is laid down within the body cavities. Radiography may show enlarged kidneys; an intravenous pyelogram using iohexol (Omnipaque, Nyomed) is useful to enhance their outline and show the presence of tumours. Endoscopy is useful, and an approach between the last two ribs allows visualization of the pericardium, the surface of the liver and air sacs; all common sites for deposition of uric acid (visceral gout). Puncturing the oblique septum allows the kidneys to be seen and biopsied. It is also possible to biopsy the kidney via a dorsal approach through the pelvis. All these tests may be helpful but not necessarily diagnostic in early cases of renal disease. Later stages of the disease may show elevation of phosphorus and a change in the calcium/phosphorus ratio. A blood sample in which the plasma has been separated from the cellular component within 30 minutes should be used for this assessment; delay in separation from blood cells will increase the phosphorus levels in the plasma.

Hepatitis and diabetes will both cause polyuria. In cases of diabetes, a urine dipstick will show glucose in urine. Normal urine will contain no glucose. The pancreas of birds contains little insulin, and this hormone appears to have a lesser role in glucose metabolism in birds than in mammals. Injections of mammalian insulin have little effect,

and dietary change is the most sensible method of control. Cockatiels are very commonly affected by this condition, and they tend to eat a seed diet, which is rich in carbohydrate. Changing to an all-in-one diet is very useful in these cases, and frequently makes the bird much better.

Renal tumours are common and often palpable within the abdomen. Because the lumbosacral plexus is sandwiched between the kidney and the pelvis, renal tumours often cause paralysis of a leg rather than polydipsia.

### ***Visceral and articular gout***

These syndromes are commonly seen in parrots. The birds are often unwell, and pasty white uric acid deposits may be visible under the scaly skin on the legs and feet. The uric acid will also be deposited around the viscera in the various peritoneal cavities (hepatic, pericardial, etc.). Allopurinol has been suggested as a treatment because it works in man (a 100 mg tablet crushed in 10 ml of water; 1 ml of this solution added to 30 ml of drinking water). However, its efficacy in birds has been questioned as it has been shown to cause gout.

### **Diseases of the reproductive system**

The most frequently presented reproductive problem is egg binding. Female birds that may or may not have laid previously are presented as unwell, slightly dyspnoeic and usually with a palpable abdominal mass. The bird may also have difficulty in standing and appear very weak. The most frequent cause is a lack of calcium. The egg-bound bird has frequently been on a poorly supplemented diet and may, as is the case with many pet cockatiels, be laying her tenth or even twentieth egg that year. The diagnosis should be confirmed radiographically, when an egg should be visible. The egg has usually started to form a shell, but the demand on calcium cannot be sustained. Parrots all lay an egg every other day, and the egg spends 80 per cent of this time in the shell gland. The shell gland is a part of the distal oviduct, and when it contains a shelled egg it is often palpable through the abdominal wall. It is useful to know when the last egg was laid. Oral

supplementation with calcium and a little vitamin D<sub>3</sub>; a bolus of a high-calcium powder (Nutrobal, VetArk) containing 200 mg calcium in 1 g of powder is mixed with a small amount of cereal-based baby food and placed into the crop with a crop tube. A dose of 100–500 mg of calcium (depending on the bird's size) is usually sufficient to allow the bird to be able to stand, and the egg is generally passed. If the egg is not passed after calcium administration, oxytocin and various other treatments have been suggested. Oxytocin has profound effects on birds' blood pressure, and should be used with caution in small incremental doses. It has been suggested that dinoprost (Lutalyse, Upjohn) is a better choice, but neither oxytocin nor dinoprost are favoured by the author. If the egg can be seen radiographically or palpated, an anaesthetic followed by gentle pressure on the egg will force it through the vagina and out of the cloaca. Another method of removing thin-shelled eggs is to introduce a hypodermic needle into the egg via the abdominal wall and aspirate the contents. This allows the shell to collapse, and the egg is easily expelled. Occasionally eggs are not passed out of the oviduct and a torsion of the oviduct should be suspected; this requires a laparotomy for egg removal. In cases such as this, ecobolics are contraindicated.

Birds that have been egg-bound need to have their diet and husbandry fully reviewed. Vitamin D<sub>3</sub> deficiency is just as important as calcium deficiency.

### **Diseases of the CNS: the wobbly and/or convulsant parrot**

Parrots are frequently presented unable to stand on their perch, and the clinician must differentiate those birds that are very ill from those with CNS problems.

The commonest presenting neurological sign is a bird that is exhibiting lack of co-ordination to the point of falling off its perch and having some degree of unsteady or jittery movement. Nystagmus is sometimes seen, but anisocoria is rare. Some birds convulse, and some even spin around and around continually until they die. Clinical examination is usually unrewarding.

There are many causes of neurological symptoms, including the following:

- 1 Parrots eat or chew any new object; poisoning is therefore a common cause of neurological problems. Lead from paint, solder, lead shot, etc. are all common causes of poisoning.
- 2 The next most common neurological problem is calcium/vitamin D<sub>3</sub> deficiency. This seems to occur more frequently in grey parrots. An all-seed diet, no supplementation and sunlight that is filtered through glass (which removes ultraviolet light) are all be contributory factors.
- 3 Zinc toxicity will give neurological signs, and is usually seen in aviary birds in aviaries made with new galvanized mesh.
- 4 Paramyxovirus will also cause irreversible neurological signs, and in the UK is usually seen in Australian parakeets. These birds will convulse and exhibit very abnormal movement, which is often permanent.
- 5 Dilatation disease will cause neurological signs, especially in young macaws that are making 'baby-bird' noises and are also off their food, regurgitating and looking unwell.

If a bird is presented suffering from seizures or other neurological problems, the first step is to get a good history, with poisoning and dietary deficiency in mind. If lead poisoning seems likely, then radiography will usually reveal very radiodense particles in the gizzard. These particles are more dense than grit, which may also be seen in the X-ray. A blood sample must be taken for lead (lithium heparin blood is used for this estimation) and calcium (heparin or clotted blood) estimation.

If lead poisoning is suspected, then treatment should be undertaken whilst waiting for the result. Sodium di-calcium edetate may be injected as an undiluted intramuscular bolus; this seems to work as rapidly as a diluted intravenous bolus and is very safe. Improvement will be seen within 24 hours. The intestinal tract will have been inactive prior to treatment but quickly recovers, and the lead is often ground down in the gizzard over a 2-week period, providing that the antidote is given every other day. Treatment should continue for a week after the lead is seen to have gone. If the lead is not being removed by

normal digestion, it is possible to remove it in parrots by flushing it out of the gizzard. The bird should be anaesthetized, intubated and suspended upside down at an angle of about 45°; a wide bore tube (the sheath from a 4 mm endoscope is ideal, or a 5 mm wide inflexible tube of some sort) is then introduced through the mouth and into the distal proventriculus. A small catheter is threaded through this tube until it is in the gizzard, and water from a syringe connected to the catheter is then used to flush the gizzard clear of grit and lead. Water at less than body temperature will rapidly cool the bird to a dangerous level of hypothermia.

Calcium deficiency should also be corrected without waiting for the laboratory result if this will take some time. An oral bolus of calcium-rich vitamin and mineral supplement (Nutrobal, VetArk contains 200 mg/g of calcium) should be mixed with a small amount of food such as human baby cereal or parrot hand-rearing formula. Calcium-rich solutions usually contain far less calcium than powders, and hypertonic calcium solutions are unpalatable and will also cause the bird to regurgitate. An injection of multivitamins is not necessary and may even be contraindicated; excess vitamin D can remove calcium from already depleted bones and, being fat-soluble, it will last longer than the oral calcium. Most hypocalcaemia cases are suffering from other dietary deficiencies, so twice daily crop tubing with hand-rearing formula and a calcium supplement is usually required for about 7 days for optimum results. Needless to say, correction of the diet is required in the long term.

If PMV is suspected, then a sample of serum should be sent to a laboratory for antibody levels. Paired samples may be necessary; 1 ml of clotted blood is usually sufficient, but if the birds are small then advice should be sought as to the most appropriate serotypes to test because it may not be possible to take 1 ml of blood safely.

### ***Paralysis***

Birds are frequently presented with weakness or even paralysis of their limb(s). This has usually developed over days to weeks, and is rarely acute. Budgerigars seem to be frequently affected.

First, examine the bird in its cage and ascertain which leg is involved. Catch the bird and check the limb for crepitus and muscle wastage. Examine any closed ring to make sure that it has not become too tight and trapped the limb; this will cause gangrene. If the ring is too tight, then it must be cut off. This will frequently require an anaesthetic, especially in larger birds. If there is crepitus, the leg must be examined radiographically and any fracture stabilized by internal or external fixation. If there is muscle wastage, the limb and also the whole body should be radiographed in two views.

Nerve injuries are quite a common cause of paralysis. In budgerigars the cause is often a tumour of the gonad or kidney; this may be seen radiographically, and can often be palpated through the abdominal wall. If the radiograph shows an amorphous visceral mass the tumour may be delineated by giving a barium meal, which shows the displacement of the intestines. The tumours are invariably inoperable. Kidney infections can also cause a unilateral or bilateral paralysis. The lumbosacral plexus runs between the kidney and the pelvis, and is therefore easily compressed by enlargement of the kidneys. Infection can spread from the kidney to the nerves, causing a neuritis and subsequent paresis. Most of these cases seem to be due to a coliform infection, and respond to broad-spectrum antibiotic therapy.

### ***Deficiency syndromes***

Invariably, birds that have signs of a single nutritional deficiency will have more than one deficiency problem. Treatment of a single deficiency will allow the other deficiencies to show at a later date.

Calcium and phosphorus should be present in the diet in a 1.5–2.0:1 ratio. Seed diets have low calcium and may contain phytates, which further reduce the available calcium and phosphorous levels. Vitamin D precursors are present in vegetarian diets but require metabolism by ultraviolet light to be converted to the usable form, vitamin D<sub>3</sub>.

Calcium and vitamin D<sub>3</sub> deficiencies will lead to egg-binding and osteodystrophy in growing and breeding birds. Unobstructed egg-binding may be relieved by injecting

calcium solution or administering it orally. Oxytocin may or may not be useful in these cases, as the bird is more likely to be calcium deficient than oxytocin deficient. Osteodystrophy may result in fractures of long bones in adult laying birds as well as growing babies. Although only one limb may be fractured, the whole bird should be X-rayed because other bones will be affected. Badly affected birds should be euthanased. Some cases may be repaired surgically.

Fits due to hypocalcaemia most commonly affect pet adult grey parrots that have had a seed diet and no access to sunshine except through glass windows. Blood calcium levels of 0.8–1.5 mmol/l (normal 2.1–2.8 mmol/l) will be found in these cases. Oral calcium is the best treatment. Administration of vitamin D<sub>3</sub> by injection could cause further calcium loss.

Vitamin A is essential for growth, optimum vision and maintaining the integrity of the mucous membranes. Vitamin A deficiency predisposes to upper respiratory and alimentary tract diseases by causing the mucous membrane's simple epithelium to become stratified squamous keratinized epithelium. The keratin plugs the ducts of the mucus secreting and salivary glands, causing pustule formation and even salivary gland abscesses. In breeding birds there is decreased egg hatchability, and in (poultry) chicks it prevents the kidneys from excreting uric acid, which remains visible in the kidney and ureters (this is commonly seen in post-mortem examination of grey parrots, the most vitamin A-deficient birds).

Vitamin E deficiency should be considered in pet caged birds showing muscular weakness, and also in birds that are failing to come into breeding condition. It is especially common in cockatiels.

Iodine deficiency causes delayed moulting and feather disorders, as it is the usual cause of thyroid deficiency. The thyroid will become enlarged and may cause dyspnoea, with 'squeaky' breathing and a change in vocalization.

Lack of sulphur-containing amino acids (commonly deficient in all-seed diets) and polyunsaturated fatty acids affects the plumage. The feathers appear dry and brittle. Their feather barbs fail to interlock, and the feathers look hairy rather than intact.

Hyperglycaemia and fatty liver occur in a high percentage of cockatiels and many grey parrots on all-seed diets. All-in-one diets are the best way of overcoming this problem.

## Infectious viral diseases

### *Paramyxovirus*

Newcastle disease (PMV1) and several other paramyxovirus strains have caused disease in Psittaciformes. The signs can be peracute death, respiratory disease or gastrointestinal disease or a combination of both, chronic central nervous system disease (sudden onset and incurable opisthotonus, torticollis, tremors or paralysis). It is an uncommon disease in parrots, and is not seen in single pet birds. The disease is diagnosed on virus isolation from the trachea, lung and brain. This range of viruses will cross the species barrier very readily and is highly infectious.

### *Herpesvirus*

This is the cause of Pacheco's parrot disease – a sudden-onset, usually massive, hepatitis. Many birds that are ill will die. Some that recover and some that are subclinically infected will become lifelong symptom-free carriers. In stressed or low-grade unwell birds, e.g. imported birds in quarantine, the morbidity and mortality is high. In healthy birds that are well fed the morbidity seems to be much lower, but mortality is the same. Postmortem signs include a very enlarged liver and some enlargement and darkening of spleen and kidneys. Histopathology reveals intranuclear inclusion bodies, and it is possible to isolate the virus. Treatment with Acyclovir may work, but it is not known how this affects the carrier status of recovered birds. Vaccination with a dead vaccine is available in the USA, but not legally obtainable in Europe.

This virus is not the same as those affecting owls, hawks and pigeons, and there is no cross-infection between these species.

### *Psittacine beak and feather disease (PBFD)*

This disease is caused by a circovirus that occurs in wild Australian cockatoos, but it is known to be able to infect nearly all species



of Psittaciformes. The virus typically causes signs in younger birds. Contact with the virus during the growth period is the common method of infection, and feather dust from affected birds is highly infective; faeces less so. The bird becomes unwell, and the virus affects rapidly-growing cells and causes feather loss by preventing further feather growth in the fledging birds. The feathers lose their blood supply, pinch off at the base and fall out of the follicle. The quantity of feather loss varies with the individual. The virus will reduce horn production in the beak and infects the bone marrow, causing a rapid loss of heterophils. Older birds, affected later in the disease, have less obvious clinical signs; there is a loss of powder down (especially in cockatoos) giving a shiny beak and dirty plumage. Vasa parrots grow white feathers and grey parrots grow pink feathers. The course of the disease is magnified by its immunosuppressive nature, but even when treated the affected birds always die. Haematology, especially from grey parrots, Senegal parrots and other African parrots, will often show severe depression of the heterophil numbers and, on occasions, anaemia and a general leucopenia. These birds may not necessarily show beak deformity or much feather loss.

A PCR test will confirm the presence of the virus in live feather pulp, which is the best method for clinical cases. Symptom-free carriers should be detected by a PCR test on a sample of blood as well as feather pulp.

### ***Polyomavirus***

This is a widespread infection in Psittaciformes, but was first called budgerigar fledgling disease. Budgerigars have BFDV-1; the rest of the parrots have BFDV-3 (polyomavirus will also affect finches). Budgerigar chicks can die in the first few weeks of life, either suddenly, or with abdominal distension, subcutaneous haemorrhages and ataxia. Some cases are more chronic and develop dystrophic primary and secondary wing feathers and tail feathers but do not die; this form is more commonly seen in the UK. These cases resemble PBF. The other species of psittacine birds, when affected by polyomavirus, can be very ill at weaning with non-specific weight loss, anorexia, partial paralysis

of the gut, polyuria and watery droppings. They have a tendency to haemorrhage easily, and may have CNS signs. Not all the birds get the disease and not all of those affected die; some (especially the older birds) obviously recover to become symptom-free carriers. Diagnosis using a PCR test can be made using cloacal swabs or tissues from post-mortem examination. A vaccine has become available in the USA.

## **Fungal diseases**

### ***Candida***

This yeast infection is more commonly seen in birds kept in high humidity and warm temperatures. It is more prevalent in birds being hand-reared and kept in brooders, and in birds kept in tropical climates – it is a common pathogen in Florida, but less so in Yorkshire. Affected birds develop caseous lesions in the commissure of the beak and around the tongue, and their crop lining has a gross appearance likened to a Turkish towel. Because the yeast invades below the surface, ketoconazole (Nizoral, Janssen 50 mg/kg) and itraconazole are more effective treatments than nystatin and amphotericin B.

### ***Aspergillosis***

This fungus invades the lungs and air sacs, and is a common cause of dyspnoea and weight loss in parrots. It is more common in birds that are stressed, on a poor diet or in contact with large numbers of spores due to a damp and dirty environment. It is frequently seen in imported birds. Old and dirty travelling boxes are also a source of disease. Occasionally it invades the syrinx and causes dyspnoea and a loss of or change in voice. Diagnosis is by radiography, which will show a loculated appearance of the air sacs as well as densities in the lung tissue. Confirmation using endoscopy and culture is best. Treatment is time consuming, involving long-term dosage of itraconazole orally twice daily, and nebulization three or four times daily with clotrimazole. It is necessary to continue the treatment for some months. Some cases respond to oral itraconazole alone. However, in many birds the prognosis is poor.

Syringeal aspergillosis cases should be referred to an avian veterinary specialist; they are difficult to treat because the blockage in the trachea has to be removed. These cases also have a poor prognosis.

## Poisons

### Lead

This is a very common poison in parrots. The bird becomes unwell, goes off its food, becomes unsteady on its legs and finally starts to convulse. Sources include old (usually white) painted wood, soldered joints in old repaired cages and lead from windows and other sources. Hardcore (quarry-waste) used as a base for outside aviaries may contain lead ores, and has been seen as a source of lead in Yorkshire parrots! The lead particles are often seen on a radiograph; grit is less radiodense. Some cases are not obvious, and a blood sample should be submitted to the laboratory. Much of the lead is in the erythrocytes, so 0.5 ml whole unclotted blood should be sent in lithium heparin, *not* in EDTA. Intramuscular injection of undiluted di-calcium sodium edetate is a low-risk, effective treatment (0.25–0.75 ml). An intramuscular injection works as well as an intravenous dose. Treatment should be given in all cases where lead poisoning is suspected, even prior to confirmation in doubtful cases. The dose should be administered after taking the blood sample.

### Teflon®

Overheating non-stick pans, even for a short time, causes the PTFE coating to depolymerize and form highly toxic, volatile fumes. Birds in the same air space invariably die quickly after exposure, with a dramatic pneumonia. Beware – some heat lamps are also Teflon®-coated. There is no treatment.

### Zinc

'New wire disease' is sometimes seen in birds that are placed in newly meshed aviaries, and zinc toxicity may be suspected in birds that become chronically unwell in new cages. The diagnosis may be confirmed on

blood samples, but the blood tubes must not have rubber stoppers or gaskets because some of these compounds contain enough zinc to provide a false positive result (this should be checked with the laboratory). The source of zinc is either the white powdery coating found on the new wire, known as white rust, or lumps of zinc galvanizing that are chewed off the wire. Both cause zinc toxicity (Howard, 1992). Zinc does not remain in the body, and is quickly removed once ingestion has stopped; there is no evidence that EDTA treatment is useful. Lumps of metal in the gizzard should be removed by endoscopic retrieval, flushing the gizzard under anaesthetic, or surgical exploration of the gizzard through an incision in the proventriculus – these cases should be referred! Washing the white rust off the new wire with dilute acetic acid before introducing the birds into a new aviary is preventative.

## Diseases of the integument

As in dogs and cats, the range of signs of skin disease are limited but the aetiologies for a particular set of signs may be diverse.

The bird should first be examined in its cage, and the cage itself inspected: is the bird the only inmate or is there more than one? What signs is the bird showing of skin disease? Is it pruritic, if so where, and how often is it irritated? Is there feather loss, if so have the owners brought a feather? Is the bird bald because of feather loss, or failure to regrow feathers, or both. Are there other signs of general illness – lethargy, off food, PU/PD, etc.? Once this inspection is complete, remove the bird from the cage and examine it consciously.

The head, beak and eyes should be examined first, look inside the beak too. Note any abscesses, etc. (see Vitamin A deficiency). Is the beak smooth and shiny (usually abnormal) or is it covered with a fine white powder (normal for most psittacine species)?

Each wing should be examined: spread the wing fully and inspect it both dorsally and ventrally. Examine the feather stubs if they are chewed or cut short. Hold the wing open and look through the feathers towards a light; note any pinprick holes in the feathers through which the light shines. Examine the down

feathers on the body under the wing, these are powder down feathers. Powder down is produced by the tips of these feathers breaking free and forming a fine white dust, which is a feature of healthy parrot integument. Pigeons, toucans, storks and herons also have powder down, most other birds do not. Examine the feathers and skin over the rest of the body, and the feet and claws. The scaly skin should be supple and not crusty; the claws should be smooth, dry and sharply pointed at their tips and there should be no discharge from their base. The toes should flex and extend normally. Look at the entire integument, including the preen gland. This is situated on the dorsal surface at the base of the tail, and is poorly developed in parrots and absent in some families (such as Amazons and *Pionus* parrots). Any enlargement should be viewed with suspicion.

In many case it is rewarding to examine the bird under anaesthetic. Look for external parasites; these are uncommon in parrots. Examine broken or chewed feathers, especially at the base where they enter the skin, as this can reveal pyoderma. Pluck a growing feather or two for PBFDF testing. Skin scrapings can be taken, and are a useful way of looking for fungi, yeasts, bacteria, etc. using cytology and culture.

Skin biopsies are seldom useful as the integument is very fine, and even competent dermatopathologists can fail to find signs of disease in apparently grossly affected skin. However, if a biopsy is needed, a full thickness of skin (**NB:** no preoperative preparation) should be taken with scissors and should include some normal and abnormal feather follicles. Multiple biopsies should be obtained and spread on paper or pinned to a wooden tongue depressor with 25 g hypodermic needles and fixed in formol-saline by floating the paper/wood with the skin immersed in the fixative. Usually the skin deficit is sutured using fine soluble suture material. Biopsies should be taken from specific lesions or the skin on the trunk of the body, remembering that the feathers grow from specific areas (feather tracts) separated by areas of skin with no feathers. Do not remove any major feather follicles from the wing or tail, as the feather cannot regrow.

Lateral and ventro-dorsal radiographs are useful to rule out internal diseases such as

airsacculitis, abscesses, liver disease, etc. A blood sample may do the same. Internal disease may cause birds to chew the area of their body over the internal lesion.

### **Bald birds**

Feather loss on the head is rarely self-inflicted. Some birds can become bald due to over-zealous head preening by a 'loving' mate (very common in *Pionus* spp.). Occasionally birds become bald by fighting with other birds, but other lesions are usually evident in these cases. Soft food may become matted to the facial feathers in adults or youngsters being reared, and this will cause a skin infection. The mat and feathers will be shed, giving patches of feather loss around the face.

Feather picking or plucking is a common problem in parrots, especially in grey parrots, cockatoos, cockatiels and macaws. These are nearly always hand-reared birds, even when imported, and they are usually socially deprived (kept on their own) and hormonally active (more often presented at the start of the breeding season). The birds are first presented as appearing to be irritable with parts of their integument, pulling violently at their claws or feathers. They may start chewing at the cut base of their clipped wing feathers, or even chew off normal tail and wing feathers. They may decide to pull contour feathers out completely; common sites are around the neck and over the shoulders, under the wings on the body and down the back. The feather-plucking bird often produces bilaterally symmetrical lesions. Some birds, especially cockatoos and lovebirds, will mutilate themselves so badly that they will chew through the skin into the subcutis and even into muscle. Some birds, such as conures, will pull out or chew off their feathers when stressed by an environmental change; this may happen when the bird is admitted as an inpatient, which is embarrassing for the vet.

Occasionally, unilateral bald areas are produced. These should be investigated, as they may be indicative of internal disease in that area. Amazon and *Pionus* parrots can be affected by behavioural problems too, but they seldom pluck their feathers out. They usually appear much more irritated with their integument, and will chew the skin on their

legs very violently, use their feet to scratch violently at their flanks or hang on their cage bars and rub their bodies on the cage as if very irritated by some skin problem. Again this is seen in birds that are hormonally active and socially deprived, and it is more common in hand-reared birds.

Treatment for feather pluckers should include dietary advice and environmental enrichment with toys and tree branches, etc.; companionship may be very useful if the patient is able to recognize and therefore respond to another bird. Hormonal suppression can work in many cases, but progestagens will cause polyphagia and polydipsia and may well exacerbate occult metabolic problems.

Drugs used for behavioural problems in man can be useful. Diazepam in the drinking water (three drops in 30 ml of water), Haloperidol (0.4 mg/kg) or flunexritine (Prozac) (1 mg/kg) are useful. In some cases the medication is required at times of maximum hormonal influence, and in other cases it is for life.

Many birds benefit from companionship with another bird of the same species, but some individuals are so completely convinced they are humans that they fail to recognize another bird; this can make the problem worse. It is very difficult to replace the social interaction seen in a flock of parrots within a captive pet environment.

### ***Pruritic birds***

External parasites are very uncommon in parrots. Red mites can cause problems in aviary birds and, occasionally, pet birds. The mites are only present at night, and the birds chew their legs. Mite control may be necessary on the birds, but the environment must be treated too. Fipronil (Frontline Spray, Merial) is very good; a squirt under each wing usually removes external parasites such as mites and lice. Feather lice and mites in birds tend to be species-specific, and as such are uncommon on parrots in the UK – presumably when they have been removed there is no reservoir from which they can return.

Most pruritic parrots have either a behavioural problem, a pyoderma or internal disease such as hepatitis, airsacculitis or an internal abscess.

### ***Pyoderma***

Areas of thickened, sore and crusted skin may be due to a pyoderma. Bacteriology, cytology and skin biopsy are all required for a definitive diagnosis. Appropriate antimicrobial therapy is required, often for some weeks or occasionally for months. Attention must be paid to selecting the correct antibiotic; drug sensitivity of the pathogen, method of drug administration and the pharmacodynamics of the drug must be integrated for successful results. If the lesion is not resolving in spite of adequate treatment, the bird may have a behavioural problem.

The beak may also become infected; this is more usually caused by poor nutrition and trauma rather than by a primary pathogen. The virus causing psittacine beak and feather disease is the exception, and degenerative lesions in the beak and claws are highly suspicious of this disease. A PCR test should be performed to look for the virus in all birds showing degenerative beak lesions. Dermatophytes are also able to infect birds, and these usually give a very crusty appearance. Again a scraping or cytology and culture is required. It can be difficult to know if some fungi are a secondary problem or a primary pathogen. *Aspergillus* and *Candida* should be viewed with suspicion as primary pathogens in the UK, as they are not encouraged to grow in our colder and less humid climate (unlike in most of the USA).

### ***Xanthoma***

Thickened yellow skin can occur in any permanently featherless area as a normal reaction of the body, but occasionally birds are presented with a massively swollen thickened area of yellow skin. This is a surgical condition.

### ***Feather damage and defects***

The normal feather should be able to maintain its structure with normal preening from the bird. The barbules should all be interlocked, giving the feather a firm and unbroken appearance. The growing quills should emerge from the sheath and the sheath should fall away, allowing the feather to unfurl and

form a normal shape; the colour of the feathers should be normal too. Nutritional defects are a common cause of feather problems. Seed is deficient in sulphur-containing amino acids, and this will give very poor quality feathers, as will a lack of essential fatty acids; the feathers appear a poor colour, the barbules separate and the feather fails to lock into its correct shape. In birds that are not allowed to bathe or are not sprayed, dirt will build up in the feather's structure, causing similar problems. Many birds on a poor diet become thyroid hormone-deficient, and this causes a failure to moult and grow new feathers. It is important always to check with the owner when the bird moulted last – did it change all its feathers, have they grown in normally? A parrot should have a bloom, or fine covering of powder down.

Feathers may be found to show bands of differing colour. This is usually due to dietary change or ill health whilst the feather was growing, and may be mirrored by a line of changed keratin in the beak. Breaks in nutrition in growing feathers will cause lines of weakness (fret marks). These are usually seen in young birds and occur in *all* the feathers that are growing, causing a line of weakness across all the tail or wing feathers. Fret marks can be found in isolation on feathers, and in these cases are usually formed by quill mites (*Syringophilus* spp.), which have eaten part of the growing feather when it was curled up in the erupting sheath. These mites are very difficult to demonstrate; it helps to look in a KOH-cleared squash preparation from the mid-third of the growing feather shaft of an affected feather. This mite seems to affect youngsters more frequently than adults.

### **Beak and claw diseases**

The beak can be injured by another bird. If the upper beak is bitten off completely then it is impossible to replace; the best that can be achieved is production of a fibrous pad after granulation, and these birds manage surprisingly well. Small holes through the beak or injuries caused by flying into wire mesh will heal with antibiotic therapy and good husbandry.

Loss or injury of a normal claw or the end of a digit is usually made good by the birds themselves, as they will often chew the digit

back to healthy tissue. However, birds are sometimes seen with dry gangrene of the digit or a bitten, mangled toe. The bird should be anaesthetized, the digit amputated to healthy tissue, and the skin sutured with fine, soluble suture material. The surgical site should be kept clean, dry and open to the air, and a 5-day course of antibiotic, such as lincomycin, should be given.

The virus responsible for psittacine beak and feather disease is common; it has an affinity for growing cells and will therefore affect growing feathers, causing the feathers to drop out whilst still growing. The quill will have a small, sharp, pinched-off appearance at its tip; the virus will affect the rest of the skin and powder down, giving a dirty plumage and a black shiny beak, which is particularly evident in cockatoos. It will also affect the bone marrow and cause a rapid and almost complete reduction in the heterophil count. As the disease progresses the bird becomes unwell with various infections exacerbated by the suppression of the immune system, the growing feathers fall out and fail to regrow, and feather colouring can be affected (grey parrot feathers become pink, Vasa parrot feathers become white instead of black). The beak and claws also degenerate, as the keratin is not formed at the base of the claw, allowing infection to cause a slough. The birds *always* die in the end, usually of secondary infections. It is possible for adult birds to carry the disease, especially cockatoos. Young birds are most frequently seen infected, especially when hand-reared. The earlier they are infected, the more rapid and dramatic is the disease. Diagnosis is by a DNA probe produced by Georgia University, which is available in Europe and America via commercial veterinary laboratories.

## **References**

- BLACKMORE, D. K. (1963). The incidence and aetiology of thyroid dysplasia in budgerigars. *Vet.Rec.*, **75**, 1068–72.
- CLUBB, S. L. and KARPINSKI, L. (1993). Aging in macaws. *J. Assoc. Avian Vet.*, **7**(1), 31–3.
- DUNNING, J. B. (1993). *Handbook of Avian Body Masses*. CRC Press.
- FORSHAW, J. M. and COOPER, W. T. (1973). *Parrots of the World*. Lansdowne Press.

- GRAHAM, D. L. (1991). Internal papillomatous disease – a pathologists view. In: *Proc. Conf. Assoc. Avian Vet.*, pp. 141–43. Association of Avian Veterinarians.
- GREGORY, C. R., LATIMER, K. S., CAMPAGNOLI, R. P. and RITCHIE, B. W. (1996). Histologic evaluation of the crop for diagnosis of proventricular dilatation syndrome in psittacine bird. *J. Vet. Diag. Invest.*, **8**, 76–80.
- HARCOURT-BROWN, N. H. (1986). Diseases of birds in quarantine, with special reference to the treatment of *Salmonella typhimurium* by vaccination: a novel technique. *Proc. Br. Vet. Zoolog. Soc., London*.
- HOWARD, B. R. (1992). Health risks of housing small psittacines in galvanised wire mesh cages. *JAVMA*, **200(11)**, 1667–74.
- LOW, R. (1992) *Parrots, Their Care and Breeding*. Blandford/Cassell.
- MORANGE, A. (1895) De la psittacose, ou infection speciale determine par des perruches. Thesis, Paris, 1895.
- NEWTON, A. (1896) Cockateel. In: *A Dictionary of Birds*. Black, p. 92.
- PHALEN, D. N., TOMASZEWSKI, E. and WILSON, V. G. (1998). Internal papillomatosis: a herpesvirus connection? In: *Proc. Assoc. Avian Vet., St Paul, Minn*, pp. 45–8. Association of Avian Veterinarians.
- RUSS, K. (1890). Diseases. In: *The Speaking Parrots*. Upcott Gill, pp. 52–76.
- SIBLEY, C. G. and AHLQUIST, J. E. (1990). Parrots. In: *Phylogeny and Classification of Birds*. Yale University Press, pp. 380–90.
- SIMPSON, (1996) Post mortem examination. In: *Manual of Psittacine Birds* (P. H. Beynon, N. A. Forbes and M. P. C. Lawton, eds.) BSAVA Publications, pp. 69–86.
- STORM, J. and GREENWOOD, A. G. (1993). Fluoroscopic investigation of the avian gastrointestinal tract. In: *Proc. Eur. Conf. Avian Med. Surg.*, pp. 170–77. European Committee of the Association of Avian Veterinarians.
- ZÜRN, F. A. (1892). *Krankheiten des Hausgeflügels* (The diseases of household birds). Weimar.

## Further reading

- CAREY, C. (ed.) (1996). *Avian Energetics and Nutritional Ecology*. Chapman & Hall.
- MOIZER, S. (1996) *The Complete Guide to Budgerigars*. B&S Publications.
- SCOTT, P. W. Nutrition. In: *Manual of Psittacine Birds* (1996) (P. H. Beynon, N. A. Forbes and M. P. C. Lawton, eds). BSAVA Publications.

# Passerines and exotic softbills

Gerry M. Dorrestein

## Introduction

Many veterinarians are relatively unfamiliar with the passerines and softbills. The aviculture, diagnostic procedures, and common diseases and their treatment will be discussed in this chapter, based on recent publications (Dorrestein, 1997a; Worell, 1997; Korbel and Kösters, 1998).

Owners of passerines (songbirds) and softbills (toucans and mynahs) are utilizing veterinary care in increasing numbers as aviculturists recognize the advances in avian medical and surgical treatment of these patients.

The order Passeriformes contains over 5700 species, with body weights ranging from 4.8–1350 g. Toucans and mynahs are often grouped together, but are from different taxonomic orders. Toucans are members of the family Ramphastidae (order Piciformes); mynahs are members of the family Sturnidae (order Passeriformes). The most commonly kept mynahs are the *Gracula* spp., such as the Indian Hill Mynah (*G. religiosa*).

Diseases in these avian species are often influenced by nutrition, housing and stress. For a complete understanding of diseases associated with problems of passerines and softbills, including diagnosis and treatment, clinicians must become familiar with the aviculture, housing and husbandry of their patients. Supportive care and measures to minimize stress are often needed to maintain the host's defence mechanisms.

## Biology and husbandry

Passerines (perching or song birds) constitute more than half the species of birds in the world, presently comprising approximately

5700 species assigned to 1161 genera. They represent a diverse, species-rich, monophyletic order of mostly small land birds (Gill, 1994). The most common representatives of the passerines in captivity are canaries, finches and mynahs.

### Canaries

The canary (*Serinus canaria*) is the most well-known representative of the songbirds. Canaries have been domesticated since 1600, and are bred and kept for their song (e.g. the Roller canary or the American Singer), their colours (coloured canaries) or their build and shape (frilled canaries, e.g. North Dutch frill and Gibber Italice; type breeds, e.g. the Border Fancy and the Norwich). The black-hooded red Siskin (*Spinus cucullatus*) is the source of the red pigment that is added to the canary's genetic make-up, and is clearly in evidence in the red canary. Their weight is 15–25 g. The sexes are monomorphic in colour, and their lifespan is 6–16 years.

### Finches

There are almost 1000 species of finches and other weaver relatives. They incorporate Old World granivorous and insectivorous birds, including weaver birds and estrildine finches; the ground-living wagtails, pipits, and accentors; the nectar-feeding sunbirds and flowerpeckers; sugarbirds and a few Australasian taxa; and the New World wood warblers, tanagers, and blackbirds, diagnosed by a strongly reduced tenth primary (Gill, 1994).

The more domesticated species of finches and weavers have been bred in captivity for many decades, but many finches are still imported from Asia and Africa. There is a

significant size disparity between the common finch pets (the smallest is the gold-breasted waxbill at 7 g, the largest is the Java rice sparrow at 20 g). Most common finches belonging to the family Fringillidae and Estrildidae. Some commonly kept Fringillidae (true finches, approximately 125 species) are canaries, greenfinches (*Carduelis chloris*), goldfinches (*C. carduelis*), bullfinches (*Pyrrhula pyrrhula*) and chaffinches (*Fringilla coelebs*). Estrildidae (approximately 125 species) originating from Africa, Asia and Australia include waxbills, e.g. zebra finch (*Poephila guttata*) and Lady Gouldian (*Chloebia gouldiae*), nuns, e.g. spice finch (*Lonchura punctulata*) and parrot finches, e.g. the parrot finch (*Erythrura psittacea*). The finches are kept for breeding, but also as ornamental birds. Bengalese or society finches (*Lonchura striata domestica*) and zebra finches are used as foster parents for breeding Australian finches. This gives special problems, because they can be carriers of diseases that can kill the foster-fledglings – e.g. coxallosomosis and *Campylobacter* spp. infections. By comparison, using foster parents may prevent some infectious diseases that are transmitted from infected parent to offspring. For example, colonies of Gouldian finches that are air sac mite-free have been established by using society finches, which are not susceptible to air sac mites, as foster parents (Macwhirter, 1994). One of the major disadvantages of fostered birds is that they imprint on the foster parents, and may therefore be less likely to breed with their own species. For species-specific imprinting to occur, a finch should be exposed to its own species from the fifteenth to the fortieth days of life.

## Mynahs

Mynahs (*Gracula* spp.) and starlings are members of the family Sturnidae (Passeriformes); a family of insect- and fruit/berry-eating songbirds consisting of over 110 species. They are commonly referred to as grackles. The mynahs have the unique ability to mimic the human voice, and are commonly kept as pet birds. The most common species is the hill mynah (*G. religiosa*), which has seven subspecies and originates from Southeast Asia.

Other mynah species can come from Africa, India and Southeast Asia, and they are mostly

kept as single pet birds. The veterinary approach of these pet birds is comparable to that for the psittacine birds. Other species commonly kept are the *Leucospa rothschildi* (Bali or Rothschild's mynah) and *Acridotheres* spp. (common mynahs). The Bali mynah is a critically endangered species, and is involved in an intensive captive breeding and reintroduction program (Norton *et al.*, 1995). The average body weight of the lesser Indian hill mynah (*G. r. indica*) is 110–130 g, that of the Java hill mynah (*G. r. intermedia*) is 150–200 g, and that of the greater hill mynah (*G. r. religiosa*) 210–270 g (Korbelt and Kösters, 1998).

## Starlings

The starlings include the pagoda starling (*Temenuchus pagodarum*), the superb glossy starling (*Lamprospreo superbus*) and purple glossy starling (*Lamprosporis purpureus*). These birds are predominantly kept as aviary birds.

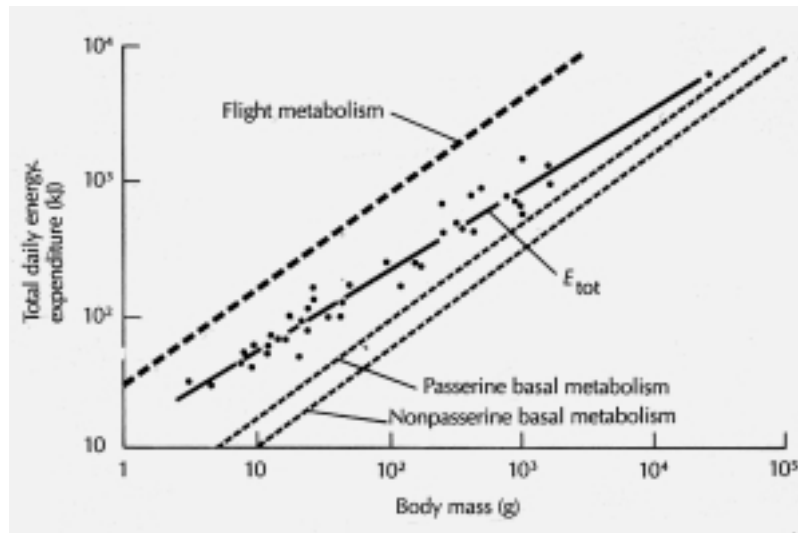
## Toucans or ramphastids

Ramphastidae (six genera, 41 species, order Piciformes) are neotropical birds and are grouped in three general categories; the large toucans, the smaller toucanettes and the small and slender aracarís (see Chapter 13). Ramphastids are distinguished by a large, elongated bill, which varies in coloration from black to multicoloured. Only a few species are frequently seen in captivity, including the Toco toucan (*Ramphastos toco*) and the sulphur-breasted or keel-billed toucan (*R. sulfuratus*). If hand-raised, these birds are tame, easily handled and highly inquisitive. These large, active birds require plenty of space for exercise and produce a voluminous moist excrement, which may account for the low numbers kept as pets. Toucans can also be loud and aggressive, particularly when untamed (Cornelissen and Ritchie, 1994).

## Basic anatomy and physiology

All birds have high basal metabolic rates (BMRs) and, for their various sizes, passerine birds have the highest rates of any group of





**Figure 7.1** Passerine birds have higher metabolic rates than nonpasserines (Gill, 1994).

vertebrate animals (Figure 7.1). The average basal metabolic rate of a passerine bird ( $k = 129$ ) is 50–60 per cent higher than that of a non-passerine ( $k = 78$ ) of the same body size (Walsberg, 1983; Gill, 1994; see also Appendices 5.5 and 5.6). The body temperature of passerines is about  $2^{\circ}\text{C}$  higher (about  $42^{\circ}\text{C}$ ) than in non-passerines.

While some desert passerines (such as the zebra finch) have been known to survive months without drinking water, most small passerine birds drink from 250–300 ml/kg body weight daily, and may eat up to 30 per cent of their body weight daily (Macwhirter, 1994).

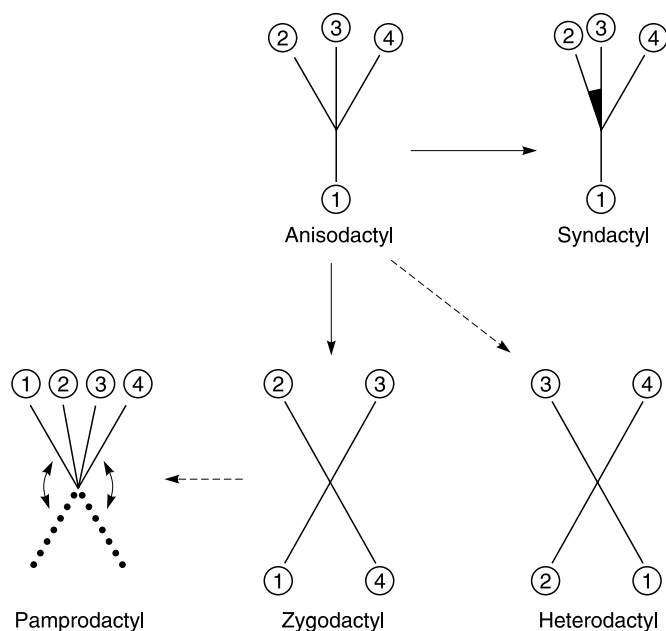
Nestling estrildid finches normally have characteristic luminous mouth markings. Mucosal patterns are species-specific, and help to guide parents to their own chicks within the recesses of dark nests. Nestlings of ramphastids have a keratinous thickening on the caudal side of the intertarsal joint (spurred heel pad), which falls off shortly after they leave the nest.

Although most perching birds have anisodactyl feet, with three forward toes and one rear toe (the hallux or first digit), at least nine groups, including Piciformes (woodpeckers and toucans), most Psittaciformes, Strigiformes (owls) and Musophagiformes (turacos), have zygodactyl feet, with two forward

(D2 and D3) and two rear toes (D1 and D4) (Gill, 1994; Figure 7.2).

The anatomy of the digestive tract varies depending on the species' feeding pattern. A bird's bill is its key adaptation for feeding, and the size, shape and strength of the beak prescribe the potential diet. Most passerines that specialize in seed-eating crack and shuck the seed husk with powerful bills. Finches extract seed kernels by either crushing or cutting the seed hull. These finches are called thick-bills, in contrast to the insect/berry-eating small-billed finches. Toucans have a large, lightweight, highly vascular bill composed of spongy bone, which is extremely sensitive.

A crop and a large, strong, muscular gizzard (ventriculus), covered on the inside with a strongly polymerized koilin layer, is present in grain/seed-eating species such as finches, but not in species such as honeyeaters that consume nectar and soft foods. In birds that are insect-eaters in the summer, the gizzard becomes smaller and less muscular at that time. In the wintertime the food consists of dry seeds, and the weight of the gizzard can increase by 25–30 per cent. In mynahs and ramphastids the crop is absent, and the ventriculus has (in contrast with seedeaters) an obvious lumen with a moderately muscular wall.



**Figure 7.2** Schematic diagrams of differing foot structures of avian species.

If present, caecae are generally small and vestigial and play no role in digestion. None of the birds of these orders have an obvious permanent bacterial intestinal flora. However, in spite of a relatively short intestinal tract (in canaries it is approximately 31.1 cm) and a fast passage of chyme, seeds show high digestibility rates of starch (88–90 per cent) and fat (97–99 per cent). Research in canaries, rice finches and budgerigars has shown that maltase, saccharase, amylase and lipase are all present at much higher activity levels than in other species such as the dog, pig, horse and poultry (Wolf *et al.*, 1997). It also appears that the activity of the enzymes is markedly influenced by different feedstuffs (Martinez del Rio *et al.*, 1996; Wolf *et al.*, 1997).

The mynahs and toucans have an intestinal tract that is shorter and wider than the seed-eating passerines, pigeons or psittacines. They also have no caecum.

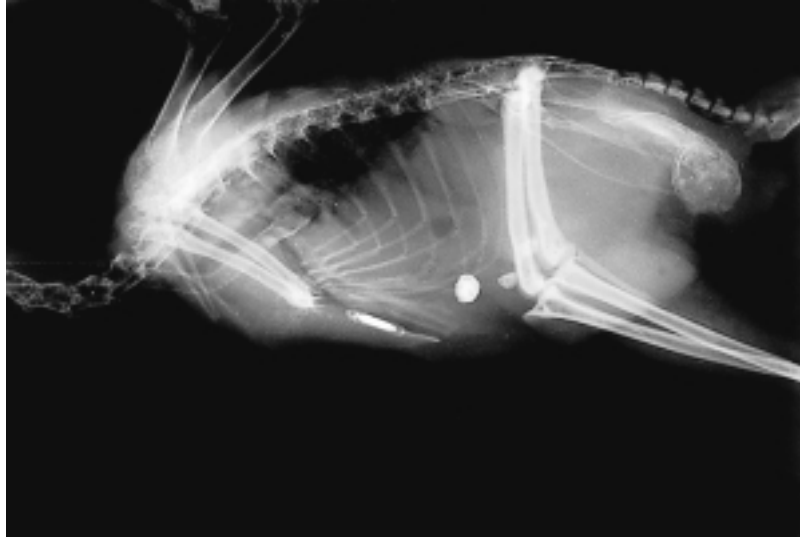Both orders have gall bladders, in contrast to Columbiformes and Psittaciformes. The spleen in most passerines and ramphastids is long rather than spherical, as it is in Galliformes and Psittaciformes.

In most Passeriformes, the right and left nasal sinuses do not communicate. In cases of

bilateral nasal discharge, a sample for cytological examination should be taken from both the left and right sinuses.

Singing ability is highly developed in many passerine species, and is related to the complexity of the syringeal anatomy. Sounds result from the vibration of a thin membrane (*membrana tympanica*), the tension and position of which are controlled by syringeal muscles and air pressure in the interclavicular air sac. Many birds can stimulate each side of the syrinx independently, and thus can sing duets with themselves (Gill, 1994). Roller canaries are specifically bred and trained for their singing ability.

Male canaries will usually sing best in the spring, in response to the endogenous testosterone 'surge'. If a bird becomes ill it may stop singing, and may not start vocalization until the following spring, even though the initial illness has resolved. In contrast, some canaries (even some females) sing all year round, and birds that stop singing because of illness begin singing as soon as their general condition improves. Testosterone injections to induce singing should be discouraged, because testosterone has a negative feedback that causes shrinking of the testes and reduced fertility (Macwhirter, 1994).



**Figure 7.3** Tracheal deviation of ramphastids at the thoracic inlet is normal anatomy, as seen here in a plate-billed mountain toucan (*Andigna laminirostris*).

The ability to mimic the human voice is well developed in some passerines, notably mynahs, starlings, mockingbirds and corvids. Fifteen to twenty per cent of the passerines in most regions of the world practice vocal mimicry (Gill, 1994).

The trachea in ramphastids deviates ventrally at the level of the thoracic inlet, and should not be misinterpreted radiographically as pathological (Cornelissen and Ritchie, 1994) (Figure 7.3).

Like psittacines (but unlike ratites and penguins), passerines and ramphastids have a highly developed neopulmic and paleopulmic parabronchi system. This allows for highly efficient oxygen exchange. In most passerines the cranial thoracic air sacs are fused to the single median clavicular sac, making a total of seven air sacs as opposed to the nine air sacs in psittacine species.

## Housing

The small passeriform birds are kept in captivity both as individual pet birds and as flocks in two different types of aviaries; mixed ornamental and breeding aviaries. The former type is usually located outside and different species are kept together, mostly for orna-

mental purposes. In the latter, large numbers of the same species are maintained, mostly indoors, for breeding and selecting. Breeders often go to shows and competitions, and there is frequently an exchange of birds (and possibly pathogens).

In mixed aviaries the bird population is less dense, and species-specific diseases are restricted to only a few of the occupants. The birds are in the aviary all year, with a shed for shelter and a flight outside. Planted aviaries are popular for these passerines, because the vegetation provides observers with a more natural view of a bird's behaviour (Plate 14). Planted aviaries can cause problems when trying to control micro-organisms and medicate diseased birds (Macwhirter, 1994). These plantings, however, are often necessary to get breeding results. For feather care in mixed ornamental aviaries, the birds should have access to water and/or sand-baths.

In breeding aviaries, the housing depends on the season. Nowadays, canaries are mostly bred indoors, and in the breeding season the birds are generally kept in couples in small box-type cages approximately  $50 \times 40 \times 40$  cm (Figure 7.4). Normally the fancier breeds two to three clutches. The weanlings are housed in communal flights, with or without outside quarters. In the winter season (resting season), the males and




Figure 7.4 Canary breeding cages.

females are housed as separate groups in pens. Singing canaries are housed individually in small sing-cages (21×20×15 cm) for more than 5 months to be trained and enter singing competitions. The breeding aviaries are relatively easy to clean.

The mynahs should be kept in aviaries because of their size and need for exercise. Mynahs make a mess with their food and produce copious amounts of fluid droppings, which makes them less suitable as indoor house pets. The best form of indoor housing is a box-cage with an open ceiling and front; it should have a minimum floor area of 100×60–70 cm, and a height of at least 70 cm (Korbelt and Kösters, 1998). The cage and wooden nestboxes, which are used as sleeping boxes, need daily cleansing to prevent fungal growth.

In flights, where mynahs can be combined with other species such as the superb glossy starling and aracaris, an area should be created with plants or blinds for the birds to retreat or escape from sight. Also, mynahs are nest-robbers and hunt small birds.

The toucans and other ramphastids are generally kept in captivity as breeding pairs in large flights with numerous, variably-sized perches. Like the mynahs, they are active, inquisitive, carnivorous birds, and if housed in mixed aviaries may consume smaller aviary inhabitants or intruding sparrows. If these birds must be mixed with other birds in the same flight, there should be sufficient room and adequate hiding places to ensure the safety of all inhabitants. Emerald toucanets are particularly aggressive, and should always be housed alone or as a couple. Most male toucans and mynahs are aggressively territorial, and should not be housed with other males (Cornelissen and Ritchie, 1994).

The aracaris are the most secretive of the ramphastidae, and require a nest box for security and privacy. They should preferably be kept in species-specific colonies, where the young from one clutch may assist the parents in caring for the subsequent chicks.

The active, curious nature of the mynahs and ramphastids often leads them to pick up and consume inedible foreign bodies found in the enclosure (rocks, pieces of wood, screws, string, coins etc.). Resulting impactions from foreign body ingestion can cause perforation or stasis of the gastrointestinal tract, which may lead to death. These birds are capable of being extremely destructive, and can injure their beaks when biting on solid objects.

The floor of a toucan or mynah enclosure should be well drained and easy to clean. The large amount of moist foods that these birds consume results in the production of voluminous, malodorous excrement and uneaten food.

## Diet and husbandry

### Small passerines

Dietary and husbandry requirements are diverse. Most passerine species are primarily seed-eating or granivorous, while others are nectivorous, frugivorous, insectivorous, omnivorous or carnivorous. Most commercially available passerine diets are seed mixes, and may therefore be deficient in specific vitamins or minerals. The composition of the basic diet will be affected by the species of bird in question – some species adapt readily

to commercially available diets, while others may require live food.

Common nutrient deficiencies from a seed-only diet include lysine, calcium, available phosphorus, sodium, manganese, zinc, iron, iodine, selenium, vitamins A, D<sub>3</sub>, E and K, riboflavin, pantothenic acid, available niacin, vitamin B<sub>12</sub> and choline. The nutrient deficiencies often found in seed diets affect the reproduction and health of adult birds.

It is commonly assumed that seed-eating birds need both soluble and insoluble grit in their diet. Most studies have been done in poultry and have not yielded any conclusive results. In a study using canaries, no significant differences in food intake were measured between two groups (one with and one without soluble grit, but both with access to cuttlebone), and insoluble grit had no effect on digestibility values (Taylor, 1996). The group of birds that were denied a source of soluble grit during the trial consumed a significantly higher amount of cuttlebone than the other birds.

When passerine birds are presented in wildlife rehabilitation with anorexia, many complicated food mixtures are advocated for nutritional supplementation. For insect-eating birds or nestling seed-eaters, a high quality puppy food soaked in water with a good vitamin and mineral supplement is recommended as a base diet (White, 1997). The author has also good experience with soya-based products (see Chapter 5). Some insectivorous birds require insects as a substantial portion of their diet (30–60 per cent). When mealworms make up a significant part of the diet, additional calcium must be added to bring the diet to the proper 2:1 calcium:phosphorus ratio. Starlings will not generally thrive on dog food unless additional fat is added.

## Mynahs and ramphastids

Free-ranging mynahs and ramphastids eat a variety of fruits, small vertebrates such as lizards, rodents and small birds, various insects and spiders, and bird eggs (Worell, 1997).

Toucans grasp the food with the tip of the bill, toss it in the air, catch the food in the open bill and swallow it. Large food items

are compressed with a foot and segmented into smaller pieces with the bill. An adequate maintenance diet for captive mynahs and toucans would consist of fresh fruit (e.g. melons, papaya, berries, tomatoes) supplemented with a low-iron formulated diet (Cornelissen and Ritchie, 1994). Paprika may be added to the diet to maintain the bright coloration of the beak. During the breeding season, the diet should be supplemented with crickets (up to 800 per day when a pair is raising chicks), mealworms (10–20), small mice and hard-boiled eggs complete with shell. Softbills are extremely susceptible to diet-induced iron storage problems, or haemochromatosis; therefore the total diet should contain a low iron level – less than 40 ppm or, based on calculations referring to food intake per kg body weight, a maximum of 4–6 mg iron per kg per bird per day (Dorrestein *et al.*, 1992).

In a field study, rainbow-billed toucans (*Ramphastos sulfuratus*) were observed to eat mainly five fruit items that had concentrations of less than 20–50 ppm iron (Otten *et al.*, 1998). Also, the concentrations of phosphorus, manganese and zinc in these five natural foods were less than concentrations found in commercially available diets. However, the total iron content of the diet of wild toucans may not be derived entirely from fruits. Toucans have been reported to be omnivorous and to supplement their frugivorous diet with animal protein in the form of insects, spiders, an occasional small lizard or snake, eggs, adult small passerines, and nestlings of other birds.

Many dog and cat foods contain high levels of iron (up to 1500 ppm), and these high-iron diets should be avoided when feeding softbills. Grapes and raisins can also be high in iron. However, even the low-iron commercial diets with a stated maximum level of 100 ppm contained 210 ppm iron, and analysis often revealed levels five to six times higher than those stated (Otten *et al.*, 1998).

These birds may normally pass some undigested food. Undigested chitin and feather parts will be regurgitated as small pellets by mynahs. Large quantities of 'brown' mealworms can induce a cloacal impaction (Korbel and Kösters, 1998). Birds that are losing weight and consistently excreting undigested food should be evaluated.

## Breeding and sexing

### Canaries

#### *Breeding*

The breeding season is the cornerstone of the canary fancier's hobby. Success or failure at this stage will determine what will be available for the autumn shows, and will also determine whether the breeder will be in a position to advance a breeding programme in the following year with home-bred birds or will have to purchase replacement stock (Dodwell, 1986). Although most fanciers work with pairs, it is quite a common practice to have breeding trios consisting of one cock bird mating with two hens. During the winter, hens and cocks are housed in separate groups.

Normally, canaries will start breeding when the following conditions are met (Coutteel, 1995):

- maturity and good health
- an accepted partner
- a minimum length of the day
- the presence of a nest and nesting materials
- enough water and food
- a minimum temperature and photoperiodic stimulation.

The ultimate expression of readiness to breed, however, is when the hens crouch low upon the perch with tail raised, inviting the act of coition, whenever they hear the vigorous singing of a cock bird in a neighbouring cage. When these signs are noticed, no time should be lost in introducing the pair to each other. The breeding season will then proceed throughout the spring, and should finish by midsummer. During this period two or three clutches will have been raised, depending on breeding conditions. All young birds should be weaned and independent of their parents by the end of the summer.

After a period of long daylight hours, birds become refractory to photostimulation. Following the moult and period of decreasing daylight hours in the autumn, the breeding season starts again with the increasing daylight hours in the late winter and early spring.

Egg laying in canary breeding is the result of seasonal development of the left ovary, which is less stimulated by the increasing

photoperiod than the testicle in the male. The female may require the presence of a male in breeding condition to trigger appropriate nesting and egg laying responses.

Egg laying may be expected to start within about a week or 10 days of pairing the birds, although variations of some days either way can occur according to season and the condition of the breeding pair. During this period, the pair will have been building the nest.

Signs of the impending event are the hen roosting in (or near) the nest at night, and an increase in the consumption of water for approximately 48 hours. Eggs are laid singly and at 24-hour intervals, usually in the early hours of the morning.

Breeders remove the eggs as they are laid, and substitute them with dummies until the fourth egg has appeared, when they are returned to the nest for the hen to incubate for 13–14 days. The average number of eggs in a clutch is four, and breeders work on this assumption, but five is quite commonplace, and even larger clutches can sometimes occur.

The problems that are likely to present themselves at this period include (Dodwell, 1986):

- hens that occasionally lay their eggs on the floor of the cage (a thick covering of sawdust will prevent breakage)
- hens suffering from egg-binding
- eggs sometimes being broken by an over-inquisitive cock bird.

#### *The role of the length of daylight*

Canaries need 14–16 hours of daylight to start breeding and to feed their nestlings and raise them properly. If the length of the daylight fluctuates, the birds will receive different hormonal incentives (negative feedback), resulting in interruption of breeding and the beginning of an early moult. Artificial day lengths of 17–18 hours give less satisfactory results.

There are several ways to increase the length of the day (examples are given based on the Northern hemisphere):

- 1 Following the natural increase in day length. These birds are called 'cold-temperature' breeders. The disadvantage is that the first chicks will hatch in April/June and that the time will be very short to mature for show season.

- 2 Gradually increasing the length of the day using artificial light, starting in November/December in a heated (15–16°C, 60–80 per cent humidity) environment. It will take a period of 2–3 months to increase from an 8-hour natural day length to a 15-hour day, increasing at 2×15 minutes per week. A minimum luminance of 500–1000 lux is needed, preferable using a dimmer to simulate dawn and twilight.
- 3 Introducing an immediate full day length, extending it from 10 to 15 hours. In this case the birds will reach their breeding condition in 3–4 weeks, but they will often give bad fertilization of the first clutch and the birds are less able to give good results throughout the full breeding season (Coutteel, 1995).

### **Sexing**

Since canaries are monomorphic, it can be a problem sexing them, depending on the time of the year. As the breeding season approaches, the most obvious difference will become apparent; that of song. The cock sings, whereas the hen does not. Song also helps with the sexing of the juveniles; by the time they are 8–10 weeks old, most of the cocks will have started to twitter.

Apart from the song, there are two other methods of sexing; colour and general bearing, and the appearance of the sex organs during breeding.

Cocks are often more intense in colour than their counterparts. The difference will become apparent by comparison with a similar bird of known sex. It will also be observed that cock birds tend to have a bolder manner and more jaunty carriage than hens.

Birds have no distinctly different sex organs, but when in breeding condition, if the vent area is examined it will be seen that the cloaca of the cock bird is quite prominent and somewhat elongated due to swelling of the seminal glomerulus. In the hen, although the cloaca is raised above the general level of the abdomen, it is rounder and flatter.

### **Other finches**

#### **Breeding**

Many varieties of domesticated finches bear little resemblance to their free-ranging

ancestors, and are easy to care for and breed well in captivity. Java finches, zebra finches and Gouldian finches have a somewhat shorter history of domestication than canaries, but are also bred intensively in captivity, and many mutations have occurred. Other passerines are directly imported from the wild, and need indoor, temperature-controlled rooms and sometimes artificial light for reproduction. Some passerines require special materials for nesting or to stimulate display behaviour. Any contact with fine synthetic fibres should be avoided, because these may become entangled around the bird's feet, toes or other body parts, causing damage, loss of limb or death (Plate 15). Hessian cut into small squares, cotton, torn strips of facial tissue, sheep's wool or coconut fibre make suitable, safe nesting materials.

In passerines indigenous to tropical or arid regions, seasonal changes related to daylight hours are less important to the reproductive cycle than the periodic available food and water (Gill, 1994). Most successful breeders of these species mimic natural conditions by lowering the caloric, protein and fat content of diets and maximizing the bird's physical condition by allowing free flight in open aviaries during the non-breeding season. At the beginning of the breeding season the birds are 'flushed', or encouraged to come into breeding condition, by increasing the plane of nutrition. Misting some species with water (to mimic rainfall) and providing green, fresh foods and foliage may stimulate breeding, particularly of those species from desert environments, such as the Australian grass finches. Birds must not become chilled during the misting process. Depending on the species, birds may be transferred in pairs to smaller breeding enclosures, or left in flights to colony breed (Macwhirter, 1994).

### **Sexing**

In some passerines, there are obvious or subtle morphological differences between the genders. Males are generally brightly coloured or elaborately marked, particularly during the breeding season. As in canaries, differences in singing, courtship or nesting behaviour may also provide clues to gender.

In many species, the male's seminal glomerulus will push the cloacal wall into a prominent projection (the cloacal promontory) during the breeding season.

DNA/PCR technology can be used to determine gender in monomorphic passerine birds. The cost of these procedures tends to limit their application to more expensive species.

### **Aggression**

While passerine species may be small, some are quite territorial and others have well-developed pecking orders. Head trauma, feather picking, other injuries or death may occur in individuals that have been attacked by a companion (Plate 16). Self-mutilation, poor body condition and increased susceptibility to disease are indirect results of such aggression in birds that are psychologically stressed because of their low social position (Macwhirter, 1994). Aggression is more likely to occur if the birds are overcrowded in small, open enclosures, where less dominant birds have few opportunities to escape from more dominant ones. Aggression-related injuries can be particularly pronounced if new birds are introduced into collections where a social order has already been established.

Suggestive measures to control combat aggression include:

- 1 Prevent overcrowding; the fewer birds, the better.
- 2 Keep stocking densities low.
- 3 Clip the wings or remove particularly aggressive individuals.
- 4 Provide extra vegetation or visual barriers (burlap sheets) to provide less dominant birds with an escape area.
- 5 Maintain subdued lighting in indoors areas.
- 6 Introduce all birds into a new environment simultaneously.
- 7 'Tranquillizers' (haloperidol 0.02 mg/kg or sodium bromide 1–2 mg/l) may be useful in certain situations.

Parents that become aggressive towards their chicks are preparing to lay a second clutch of eggs, and the chicks should be removed (Macwhirter, 1994).

### **Breeding parasitic species**

Some finch enthusiasts enjoy the challenge of breeding parasitic species (birds that lay their eggs in the nests of other species) such as paradise whydahs (*Steganura* spp.), *Hypochera* spp., small-tail whydahs (*Tetraenura* spp.). Parasitic behaviour is found in only four waxbill genera of the Estrildidae: *Estrilda* spp., *Lagonosticta* spp., *Uraeginthus* spp. and *Pytilia* spp. Whydahs are generally bred in large planted aviaries, where the parasitized finch species has first been firmly established and is breeding freely. The parallels between the appearance and behaviour of the whydah chicks and the finch chicks that they mimic are striking, even though the adults of the two species are very different.

If male and female whydahs do not originate from the same geographic area, they may not enter breeding condition simultaneously, thus preventing successful reproduction. The male whydah develops a long, flowing tail during the breeding season (Plate 17).

## **Mynahs**

### **Breeding**

Mynahs are difficult to breed in captivity. This may be due to their imprinting on humans at a young age, or to their need for a large aviary. In the wild, mynahs are associated with flocks and the birds only separate in pairs during the breeding period. Free-ranging mynahs nest in tree-holes, 10–17 m high, cliff areas, and some nesting boxes. In captivity, nesting boxes (or, better, natural hollowed logs) of 20–30 cm long by 20–30 cm wide and 30–45 cm high should be used. The diameter of the entrance should be at least 8–10 cm, and the box should be suspended as high as possible. Nesting material consists of wood shavings, small twigs, straw, hay, moss and feathers. Flights with abundant foliage are recommended for breeding pairs.

The hen lays between two and five eggs per clutch; they are coloured turquoise with some red brown to black spots, and are usually laid 24–48 hours apart. Breeding starts after the second egg has been laid, and takes 14–15 days. The chicks are fully feathered at 22 days of age, and become independent or weaned at



4–5 weeks. The yellow feet, legs and fleshy wattles are absent in young birds. The youngsters can fly at 6–8 weeks, and sexual maturity is reached at 2–3 years of age.

During the breeding season, the diet should include an abundant amount of insects, baby rodents and lean meats. Young birds being hand fed have been raised on rice, chopped fish and vegetables, and insect larvae such as mealworms. The diet should be supplemented with adequate amounts of calcium, vitamins and minerals. Softbill hand-feeding formulas can be used.

Adult mynahs have been known to crack their own eggs and even throw the young out of the nest (LaBonde, 1996).

### **Sexing**

Most hill mynah species are monomorphic and require surgical or genetic sexing.

## **Ramphastids**

### **Breeding**

Toucans are best bred in large, planted flight enclosures with plenty of privacy. The walls of the enclosure should be covered with a cloth or plastic barrier to protect young chicks from collision injuries while they are learning to fly or, more appropriately, to stop!

Toucans are cavity nesters. The larger species make an entrance hole in decayed portions of large trees. The smaller species take over the nests of woodpeckers, and remodel them for their own use. Most birds will readily accept natural palm logs as nesting cavities, while some toucans can adapt to plywood boxes. The nests of free-ranging species can be found from a few centimetres to a metre below the entrance hole.

Courtship behaviour is characterized by the males feeding the females, with both adults sharing incubation and rearing responsibilities. Sexual maturity generally occurs at 3 years of age.

Toco toucans lay usually three to four eggs per clutch, with an 18-day incubation period. Red-breasted toucans have two to three eggs, with a 16–18-day incubation period. Some of the toucans will use nesting material, while

others will empty the nesting cavity and lay their eggs directly on the bottom of the container (Branch, 1987).

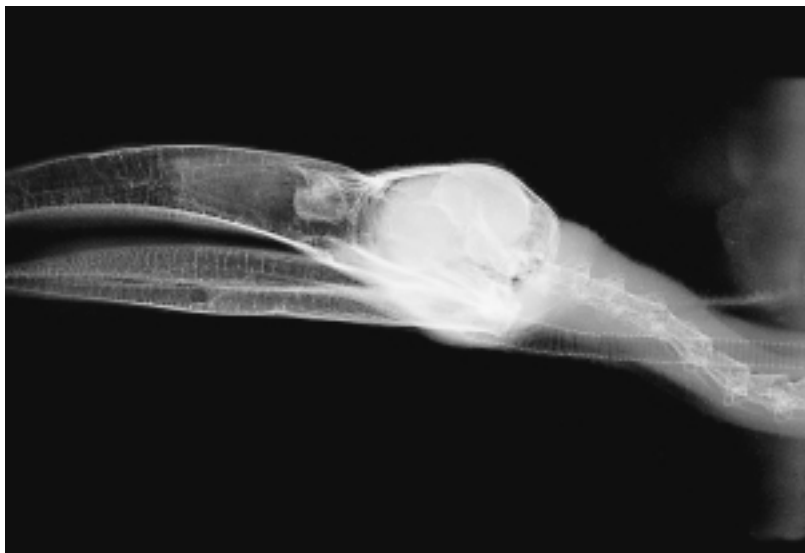Toucan chicks leave the nest within 45 days of hatching, and are weaned between 2 and 4 months of age (Longo, 1989). Cannibalism of young chicks by the parents is common if the diet is not supplemented with animal proteins – e.g. mice, crickets or mealworms.

Toucan chicks have been successfully hand-raised from the egg. The eyes open at 3–4 weeks of age. It is important to remember that these birds have no crop, and should be fed smaller quantities and more frequently than psittacine neonates (Branch, 1987; Worell, 1997). Ramphastid chicks must be observed very closely for dehydration, which is common in hand-fed chicks. Chicks that have a poor daily weight gain or poor feeding response should be examined for potential bacterial or yeast overgrowth. Although the significance of *Enterobacteriaceae* or *Candida* spp. is unknown, their presence in such a chick warrants treatment with appropriate antibiotics and antimycotic drugs. Severe metabolic bone disease is often observed in ramphastid chicks, because chicks may refuse to eat kibble, preferring the apparently tastier fruit.

### **Sexing**

The majority of ramphastids are phenotypically monomorphic, and gender must be determined by endoscopy or genetic determination. Sexual dimorphism occurs in some ramphastids; the male lowland toucanets (*Selenidera* spp.) and two of the aracarids (the green aracarid, *Pteryglossus viridis*, and the lettered aracarid, *P. inscriptus*) have black head feathers, and their female counterparts brown head feathers. Two other species demonstrate very light dimorphism. Males of the black-necked aracarid (*Pteryglossis aracari*) and the many-banded aracarid (*P. plurinctus*) have chestnut-coloured ear covert feathers, whereas the females have black feathers (Worell, 1997).

In general, male ramphastids have a longer, narrower beak than females of the same species. To determine the beak's length, the lower margin of the upper mandible is



**Figure 7.5** Radiograph of plate-billed mountain toucan (*Andigna laminirostris*) showing the large bill that requires a specially modified mask for anaesthetic purposes.

measured from the edge of the facial skin outward toward the tip. In Toco toucans, the beak of the male is generally longer than 16 cm, while in most females it is less than 15.5 cm.

Spot-billed toucans (*Selenidera maculirostris*) have individually distinct beak patterns that can be photographed and used for identification (Cornelissen and Ritchie, 1994).

#### *Surgical sexing*

Specially designed elongated anaesthetic masks are necessary to accommodate those species with lengthy beaks (Figure 7.5). As an alternative, a large Zip-loc® plastic bag may be used to elongate a standard anaesthetic mask and seal against the escape of anaesthetic gases. Pre-anaesthetic fasting for at least 4 hours is suggested, because a distended proventriculus and intestinal loops make the procedure more difficult. The surgical approach to the birds may be at a slightly different to the location used in psittacines (Worell, 1997). For sexing parrots, the surgical site is located cranial to the distal end of the proximal third of the left femur when the left leg is extended caudally. The best site in toucans is more dorsal; this location avoids food-filled intestinal loops.

## Handling and restraint

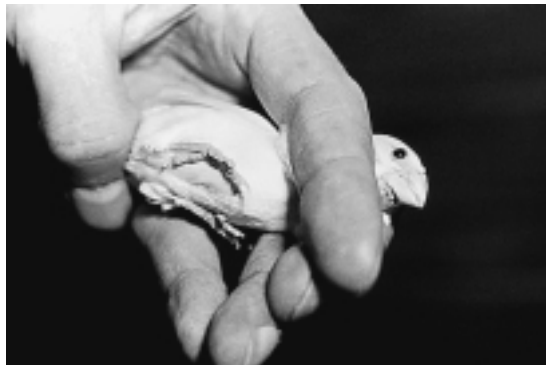### Small passerines

#### *Handling*

A 'lights out/perching out' approach to capture is useful for small active birds. Birds will generally not move in a dark room, and can easily be removed from an enclosure; the bird can be restrained by placing the head between two fingers so that the body rests in the palm of the hand, or it can be restrained by holding the head gently between the thumb and first finger (Figure 7.6). It is essential not to interfere with or restrict the movement of the sternum; this will kill the bird! The handling and restraint period should be as short as possible, and clinicians should be prepared to take samples and perform treatments in one handling session. A modified mask should be used to induce and maintain small passerines on the only general anesthetic agent recommended, isoflurane.

#### *Blood collection*

The right jugular vein is generally the best site for collecting blood or giving intravenous fluids. It is surprisingly large, even in very



**Figure 7.6** Proper handling technique for a small passerine.

small finches. A nail clip is obsolete; the medial tarsal or cutaneous ulnar veins are alternative blood collection sites, but they frequently provide insufficient sample volumes. A skin-prick technique from these sites or from the external thoracic vein (which courses on either side of the ribcage just behind the shoulder) can be used. The blood is collected directly from the skin into a micro-collection tube (Macwhirter, 1994).

### ***Injection sites***

Although the right jugular vein can be used for administration of intravenous fluids, intraosseus catheterization using a 26-gauge needle is a practical means of fluid administration in a finch (Macwhirter, 1994).

For intramuscular or subcutaneous injections, a 27-gauge needle is required; even these can cause significant haemorrhage if not used with caution. To minimize risk, the intramuscular injection site should be located in the caudal third of the breast muscle. Aspiration should be performed prior to injecting any drug to ensure that a blood vessel has not been cannulated. After the needle has been removed, the site should be observed for haemorrhage, and pressure applied digitally if bleeding does occur.

Drug dosing in small patients must be based on an exact body weight (as determined by a digital gram scale), and should be delivered with precise microlitre or insulin syringes to avoid overdose. There is little room for a dosing error in a small bird (Macwhirter, 1994).

## **Mynahs and ramphastids**

### ***Handling***

Mynahs and toucans can be loud, active and aggressive, particularly if untamed. Tame birds that are not given sufficient attention may become also very aggressive towards their keepers. The birds are best restrained by initially removing them from the enclosure with a net or large towel. A toucan can then be controlled by holding the beak in one hand and using a towel loosely wrapped around the body to control the wings and feet. Toucans should never be handled by the head and neck alone (Cornelissen and Ritchie, 1994). A mynah can be controlled by holding the head gently between the thumb and first finger, with or without a towel.

### ***Blood collection and injection sites***

These are the same as described for the smaller passerines and for other birds (see Chapter 5).

## **Diagnostic procedures**

Diagnostic and treatment options in small passerines may be limited by owners' financial constraints and by difficulties in collecting samples from small birds. However, in spite of their size, the medical management of passerine patients weighing less than 25 g is very similar to that of larger avian species. Special instrumentation allows veterinary practitioners to auscultate the heart, respiratory system and gastrointestinal tract of these birds. Low volume, preheparinized syringes can be used to collect enough blood to perform a complete blood cell count and abbreviated plasma chemistry analysis on birds less than 10 g in weight. Surgery can be performed using microsurgery instruments and operating microscopes or other forms of magnification (Massey, 1996).

Veterinary care in these species is frequently directed toward appropriate preventive husbandry measures, and approaching medical problems from a flock perspective. The main clinical diagnostic procedures for these small birds are taking a history, examination of the cage, an external physical examination and

limited clinical procedures. In many cases, especially in flocks, these procedures should be followed by a diagnostic necropsy.

The softbills are larger birds and more expensive. A sound medical work-up will lead to proper diagnosis and treatment.

## Clinical diagnostics

The history should include information on the species, age, symptoms, diet and housing. A thorough history will provide much of the information needed to arrive at a diagnosis.

Examination of the cage or aviary can provide a great deal of useful information. Examination should include the droppings, the feed dishes and the floor. Most breeders of passerines bring their birds to veterinary clinics in transport boxes or cages, and birds should be put in an appropriate cage immediately, even before the history is taken. The birds will acclimatize to their new surroundings, and often a fresh stool will be produced for examination. Transport in their own cage is recommended whenever possible. 'Light out/perches out' catching techniques are almost mandatory, and strong lighting in combination with a magnification device will greatly facilitate any examination of the tiny birds. When handling the birds, keep the windows and doors closed!

The physical examination and clinical procedures are limited in the smaller passerines, but are nevertheless very important. Most digital gram scales can provide an accurate weight if the finch is contained in a paper box or bag, but the container must be weighed or tared. The usual physical examination is performed as for any other bird; the clinician should listen for respiratory sounds, and take care not to interfere with the movements of the sternum, which could kill the patient. Special attention should be paid to the state of moult, the pectoral muscle mass (chronic or acute problem), the abdomen (by blowing the feathers apart and looking for an enlarged liver and dilatation of the gastrointestinal tract) and the skin (searching for pox lesions and parasites).

Routine diagnostic procedures also include the following:

1 Faecal examination. Helminthic infections are very rare in small passerines, but are

more often seen in wild-caught mynahs and toucans. Coccidia, which are common in small passerines, are excreted mainly between 2 pm and darkness. Yeasts and protozoal cysts (eg. *Giardia* spp.) are found using direct wet preparations or flotation techniques. The diagnosis of coccidiosis in society finches or Australian finches can only be made in direct wet mounts of fresh and warm stool without dilution. Because passerines are not considered to have a permanent gut flora, no bacteria or other micro-organisms should be found in large quantities in stained faecal smears. Routine microbiological aerobic cultures should be negative. Microaerophilic strains (e.g. *Campylobacter jejuni*) can be found in stained faecal smears in many Estrildidae. In softbills, bacteria are commonly demonstrated in the stools of healthy birds. These bacteria are considered as 'passage flora'.

- 2 Crop swabs. Crop swabs are essential for the diagnosis of trichomoniasis, infections with other flagellates, and crop candidiasis.
- 3 Blood samples. For additional information in small individual passerine birds, blood can be collected in heparinized capillary tubes after puncturing the medial metatarsal vein. In softbills, blood normally is collected from the right jugular vein. One drop is used for a blood smear, which can be examined for blood parasites. The packed cell volume (PCV) normally ranges from 40–55 per cent; a reading of less than 35 per cent indicates anaemia. Total protein (TP) determinations provide a very significant diagnostic measure. For the serological diagnosis of paramyxovirus infections or toxoplasmosis, 0.5–1.0 ml blood can be collected from the right jugular vein.

Normal haematological and serum biochemical references are presented in Table 7.1. The dosage regimens for passerines are listed in Table 7.2. Tables 7.3 and 7.4 contain the main differential diagnoses and confirmations for canaries and finches.

## The diagnostic necropsy

A necropsy should always be performed on birds that die from unknown causes, both so that flaws in management can be rectified and

**Table 7.1** Some selected normal haematologic and serum biochemical values in passerines and softbills (adapted from Carpenter *et al.*, 1996 and Altman *et al.*, 1997)

Measurement	Canary	Finch	Mynah	Toucan
<i>Haematology:</i>				
PCV (%)	45–60	45–62	44–55	45–60
RBC ( $10^6/\mu\text{l}$ )	2.5–4.5	2.5–4.6	2.4–4.0	2.3–3.5
WBC ( $10^6/\mu\text{l}$ )	4–9	3–8	6–11	4–10
● Heterophils (%)	20–50	20–65	25–65	35–65
● Lymphocytes (%)	40–75	20–65	20–60	25–50
● Monocytes (%)	0–1	0–1	0–3	0–1
● Eosinophils (%)	0–1	0–1	0–3	0–1
● Basophils (%)	0–5	0–5	0–5	0–5
<i>Chemistries:</i>				
AP (IU/l)	146–397	–	–	–
AST = SGOT (IU/l)	45–345	150–350	130–350	130–330
LDH (IU/l)	120–350	–	(600–1000)	200–400
Ca (mmol/l)	1.28–3.35	–	2.25–3.25	2.50–3.75
P (mmol/l)	0.52–1.81	–	–	–
Glucose (mmol/l)	11–22	11–25	10.5–19.4	12.2–19.4
TP (g/l)	20–45	30–50	23–45	30–50
Creatinine (mmol/l)	8.8–88	–	8.8–53	8.8–35.4
Uric acid (mmol/l)	–	–	237–595	–
Potassium = K (mmol/l)	2.7–4.8	–	3.0–5.1	–
Sodium = Na (mmol/l)	125–154	–	136–152	–

**Table 7.2** Dosage regimens for chemotherapeutics and antibiotics for canaries and small passerines

Drug	Conc. in drinking water (mg/l)	Conc. in soft food (mg/kg)
Amoxicillin	1000	300–500
Ampicillin	1000–2000	2000–3000
Chloramphenicol	100–150	200–300
Chlortetracycline <sup>1</sup>	1000–1500	1500
Dimetridazole	100	–
Doxycycline <sup>1</sup>	250–1000	1000
Enrofloxacin <sup>2</sup>	200–400	200
Erythromycin	125	200
Furazolidone	100–200	200
Ivermectin <sup>3</sup>	10 <sup>3</sup>	–
Lincospectin	100–200	200
Ketoconazole	1000	200
Metronidazole	200	100
Neomycin	80–100	100
Nystatin <sup>4</sup>	1 000 000 IU	2 000 000 IU
Polymyxin	500 000 IU	500 000 IU
Ronidazol	400	400
Spectinomycin	200–400	400
Spiramycin	200–400	400
Sulphachlor-pyrazin	150–300	–
Sulphadimidine	150	–
Trim/sulpha <sup>5</sup>	150–400	200
Tylosin	250–400	400

<sup>1</sup>In case of ornithosis, 30 days<sup>2</sup>In case of ornithosis, 21 days<sup>3</sup>Alternative by topical application, one drop of 1% solution<sup>4</sup>For the treatment of *Candida albicans* for 3–6 weeks<sup>5</sup>This dosage is for the trimethoprim part alone.

to protect against a possible epidemic. The necropsy is also the ultimate method of confirming a diagnosis (Dorrestein, 1997b). The following procedures can provide much additional information during the necropsy:

- direct wet preparations of the gut contents and of the coating of the serosae
- scrapings from the mucosa of the crop, proventriculus, duodenum and rectum
- contact or impression smears from a freshly cut surface of liver, spleen, lungs, and any altered tissues.

The smears are stained routinely with Romanowsky stains (e.g. Giemsa) or 'Quick' stains (e.g. DiffQuick) and searched microscopically (cytology) under the oil immersion objective lens. Bacteriological, mycological, virological, serological and histopathological examinations and immunodiagnostic techniques are special techniques to help determine a diagnosis.

Tables 7.5 and 7.6 give the main results on 229 Piciformes necropsied in the Netherlands, divided over the different families. In Table 7.5, the change in diagnoses is illustrated by comparing the data from before 1986 with the findings after 1986. There is a remarkable

Table 7.3 Diagnostic table for canaries and finches

	Go to:
1 Species:	
● Canary	2
● Australian finch	12
● Mixed aviary	7
2 Age:	
● Nestling	3
● Juvenile, under 1 year of age	4
● Any age	5
3 ● Interior of the nests are yellow stained by diarrhoea of the nestlings, the feathers sticky, the youngsters stunted, and there is greatly increased mortality between 1 and 3 days of age	<i>E. Coli</i> DIARRHOEA
● Very pale membranes visible by opening their beaks, and weak in stretching their necks. Females can be found dead sitting on the eggs	BLOOD-SUCKING MITES
● (Black spot on the right side of the abdomen, anorexia and mortality)	Possible CIRCOVIRUS
4 ● The youngsters show huddling and ruffling of the feathers, debilitation, diarrhoea, sometimes neurological signs (20%) and death. Mortality can be as high as 80%	ATOXOPLASMOSIS
5 ● Respiratory distress	6
● Respiratory symptoms not main sign	7
6 ● Dyspnoea, debilitation with scabs and pox-lesions, especially on eyelids, commissure of the beak and in feather follicles. Diphtheric lesions can be found in the mouth and larynx. Birds of all ages can be affected, and the mortality is between 20% and 100%; the infection spreads quickly	AVIAN POX
● Severe respiratory signs, general illness and central nervous symptoms and iridocyclitis, which often results in blind birds after 3 months due to a panophthalmia	TOXOPLASMOSE
● Minor to severe respiratory symptoms with anaemia and sometimes a high mortality. The main complaint from the owner is usually a general depression in the bird	BLOOD-SUCKING MITES
● Loss of voice, decline of physical condition, respiratory distress, wheezing, squeaking, coughing, sneezing, nasal discharge, head shaking and gasping. A low mortality	STERNOSTOMOSIS
● Apathy, respiratory symptoms, regurgitation, blowing bubbles and emaciation, but seldom diarrhoea	TRICHOMONIASIS
● Chronic tracheitis, pneumonia and air sac infections	<i>Enterococcus faecalis</i>
7 ● Diarrhoea	8
● Diarrhoea not specific	9
8 ● A general decline of the physical condition, huddling and ruffling of the feathers, debilitation, diarrhoea and emaciation. The mortality is low	COCCIDIOSIS
● Several birds demonstrate a general malaise, with or without diarrhoea, and some birds show conjunctivitis and rhinitis. Some may die	COLIBACILLOSIS
9 ● Obvious wasting	10
● Sudden death of several birds	11
10 ● Most infections are seen in winter. The clinical signs are apathy, decline in food and water intake, debilitation, emaciation, diarrhoea, respiratory symptoms, ruffling of the feathers and high mortality	PSEUDOTUBERCULOSIS
● Especially in outdoor aviaries, clinically indistinguishable from pseudotuberculosis, more often chronic	SALMONELLOSIS
● Many birds show signs including apathy, anorexia, regurgitation, and parts of or whole seeds in soft, watery, dark green to brown/black faeces	MEGABACTERIOSIS
● Apathy, diarrhoea, debilitation, nasal exudate and conjunctivitis. The mortality is usually less than 10%	CHLAMYDIOSIS
11 ● Not specific. CNS symptoms, often obvious salivation and dyspnoea or diarrhoea in apathic birds	TOXICOSIS
● Often after a weekend when someone other than the owner fed the birds. Sometimes black-stained droppings or diarrhoea. Weakness is often interpreted as a CNS symptom	STARVATION

Table 7.3 Continued

12 Age:		
● Nestlings and fledglings under the age of 3 months		13
● All ages affected		16
13 ● Bengalese or Society finches as foster parents		14
● Natural breed or foster parents		15
14 ● From the age of 10 days until 6 weeks there is debilitation, shrivelling and yellow staining of the fledglings, difficulties with moulting, and parts of or whole seeds in the droppings. The foster parents show only watery droppings	COCHLOSOMOSIS	
15 ● High losses of nestlings, adult Estrildidae can show apathy and yellow diarrhoea or yellow solid droppings due to large amounts of undigested amyllum	CAMPYLOBACTER	
● In nestlings the crop is bloating, and a thickened crop wall is relatively common. In weanlings and adult birds, diarrhoea and moulting problems are more prominent	CANDIDIASIS	
16 ● Respiratory distress		17
● Respiratory distress not the main symptom		18
17 ● Respiratory distress, wheezing, squeaking, coughing, sneezing, nasal discharge, loss of voice, head shaking and gasping. The mortality is low	STERNOSTOMOSIS	
● Apathy, respiratory symptoms, regurgitation, blowing bubbles and emaciation, sometimes diarrhoea	TRICHOMONIASIS	
● Conjunctivitis and respiratory problems in Australian and African finches	CYTOMEGALOVIRUS	
18 ● CNS symptoms		19
● CNS symptoms not a main symptom		7
19 ● Torticollis is the main symptom. As long as these birds can still eat, mortality is low	PARAMYXOVIRUS	
● Sudden death of several birds		11

Table 7.4 Special hints for further diagnostics

Atoplasmosis	A necropsy and demonstration of the parasites in imprints of several organs
Avian pox	Necropsy and virus isolation
Black-spot (circovirus)	Filled gall bladder. Circovirus demonstration in EM
Campylobacter	Demonstration in smears after staining with Diff-Quick. Cultivation only on special media
Candidiasis	A direct wet preparation and/or a stained smear. Culture
Chlamydiosis	Necropsy and demonstration of the agent by staining, IFT, PCR or Elisa.
Coccidiosis	Parasitological examination of droppings collected between 2 and 6 pm
Cochlosomosis	Flagellates in a wet mount of fresh and body-warm faeces from the finches
Colibacillose	Analysis of the situation for other factors in combination with the isolation
Cytomegalovirus	Cytology and histology of conjunctiva. EM and/or virus culture
Enterococcus faecalis	Culture from the trachea
Helminthic infestation	Not important in small passerines. Syngamus very occasionally
Intoxication	Detailed case history. A direct confirmation often impossible, when the toxin is not known
Megabacteria	Faecal wet mount and cytology. At necropsy, smear from proventricular mucosa
Mites	Demonstration of mites in the nest or bird-room crevities
Paramyxovirus	Serological and virological screening. In the histology, a pancreatitis
Pseudotuberculosis	Necrotic foci at necropsy in liver and spleen and agent isolation
Salmonellosis	Necrotic foci at necropsy in liver and spleen and agent isolation
Starvation	Haemorrhagic diathesis (bleeding into the gut) at necropsy
Sweating disease	Demonstration and isolation of bacteria in the faeces
Sternostomosis	Diagnostic necropsy and demonstration of the parasite
Trichomoniasis	Demonstration of flagellates in crop-swab. Necropsy
Toxoplasmosis	Serology and demonstration of the parasite in brain smears, organ smears or histologically

**Table 7.5** Necropsy findings of piciformes between 1961 and 1994. Changes in diseases in the last 10 years (%)

Diagnosis	Before 1986	After 1986
<b>Infectious</b>	<b>67</b>	<b>37</b>
Parasites	37	7
Bacterial	42	26
● <i>Pstbc</i>	32	14
Fungal	2	1
<b>Inflammation</b>	<b>11</b>	<b>15</b>
<b>Management</b>	<b>11</b>	<b>21</b>
<b>Feeding</b>	<b>10</b>	<b>42</b>
● <i>Iron storage</i>	5	26
● <i>Liver problem</i>	5	11
Others	12	19

decrease in the frequency of infectious diseases, especially parasites and pseudotuberculosis. This is mainly due to the use of anthelmintics and vaccination programmes against pseudotuberculosis. There is, however, an increase in iron storage and liver problems, which may be caused by changes in diagnostic techniques and/or changes in the concepts about feeding birds in general.

## Metabolic and nutritional disorders

Nutritional problems, especially those resulting from an unbalanced diet, are often seen in mixed aviaries and individual pet finches. All granivorous birds need a certain amount of supplementation by an egg-food or 'softbill' food, as an unbalanced diet predisposes birds to health problems, especially with *Enterobacteriaceae* (e.g. *E. coli*, *Klebsiella* spp. and *Enterobacter* spp.) and yeast infections (especially *Candida albicans*). The breeding results are poor in birds with an unbalanced diet.

The primary cause of many problems in Australian and other tropical finches is an unbalanced diet; therefore, when treating disease problems in these birds, improvement of the diet has to be the first objective. A good starting point is controlled feeding of three parts of a seed mix supplemented with one part soft food. It may be difficult, however, to make the birds eat the soft food. In some parts of the world pelleted foods for passerines are

**Table 7.6** Necropsy results of piciformes between 1961 and 1994. Main results per superfamily (%)

Diagnosis	Ramphastidae <i>n</i> = 229	Capitonidae <i>n</i> = 74	Picidae <i>n</i> = 46
<b>Infectious</b>	<b>67</b>	<b>49</b>	<b>41</b>
Parasites	32	20	24
Bacterial	43	38	11
● <i>Pstbc</i>	31	30	4
<b>Inflammation</b>	<b>10</b>	<b>11</b>	<b>24</b>
<b>Management</b>	<b>7</b>	<b>7</b>	<b>11</b>
<b>Feeding</b>	<b>20</b>	<b>18</b>	<b>7</b>
● <i>Iron storage</i>	13	7	–
● <i>Liver problem</i>	6	11	4
Others	14	12	11

commercially available, and these are preferable rather than pure seeds.

## Vitamin deficiencies

In small passerines, feeding rancid cod-liver oil or mixing oil through the seed may result in encephalomalacia and fertility problems due to vitamin E deficiency. Vitamin B deficiency can cause CNS disturbances, reduced hatching, stunting, and moulting problems.

Vitamin A deficiency in recessive white canaries is caused by a genetic defect that prevents the absorption of carotenoids from the intestine (Table 7.7). The main symptoms are general malaise, problems with *Enterobacteriaceae* and yeasts, and disappointing breeding results (Dorrestein and Schrijver, 1982). Recessively white canaries are completely dependent on the presence of vitamin A in the food, and it is essential to increase the levels of vitamin A from approximately 15 000 IU/kg egg food for 'normal' canaries to approximately 20 000 IU/kg egg food, which will prevent deficiency problems.

Vitamin C is not normally needed as a dietary source, because most birds can synthesize sufficient amounts from glucose in the liver, kidney or both (Klasing, 1998). Some species of Passeriformes completely lack the enzyme L-gulonolactone oxidase, and require a dietary source of vitamin C to prevent the quick onset of deficiency symptoms. All species that are unable to synthesize ascorbic acid are insectivorous or frugivorous, and receive a



**Table 7.7** Mean values ( $n=5$ ) for vitamin A, total carotenoids, and  $\beta$ -carotene in liver and serum of different coloured canaries (adapted from Dorrestein and Schrijver, 1982)

Colour	Eggfood*		Serum ( $\mu\text{mol/l}$ )		Liver	
	Vitamin A (iu/kg)	Total carotenoids (mg/kg)	Vitamin A	Total carotenoids	Vitamin A (iu/g)	Total carotenoids ( $\mu\text{g/g}$ )
Red**	19 200	27.7	2.75	88.75	2552	72.45
Yellow	18 300	3.1	2.28	42.40	4154	9.83
Rec white	18 300	3.1	2.88	2.25	3751	6.70
Rec white	13 500	4.9	2.20	2.37	524	7.85
Brown	13 500	4.9	2.46	64.86	1428	21.22

\*Eggfood was given in a ratio of 1:4 with a canary seed mixture.

\*\*Extra canthaxanthine for maintaining the red colour.

reliable dietary supply in that way. Some Passeriformes that are able to synthesize ascorbic acid do so at rates two to ten times slower than those in species such as chickens, ducks and Japanese quail, which do not have a dietary requirement.

Even the high endogenous synthetic rate in other species may be inadequate during periods of severe stress, such as heat, physical trauma, infection, and the consumption of some types of purified diets. Ascorbic acid supplementation of seed- or grain-based diets has been reported to improve resistance to a variety of infectious diseases and to improve wound healing. Passerines depending on external sources for vitamin C (e.g. bulbuls, shrikes, etc.) develop symptoms including weight loss, behavioural changes, lethargy, feather loss, and haemorrhages in the liver and leg joints within 15 days of being fed a deficient diet.

The daily requirement is not known, but beneficial responses have been seen at levels of between 50 and 150 mg/kg dry matter. Vitamin C is not widely distributed across avian foods. Fruits, vegetables and many herbs are particularly rich, but domestic grains are very low in vitamin C.

The vitamin C content of avian foods decreases precipitously during storage. It is very susceptible to oxidation, especially in the presence of trace minerals. Food that has been stored for more than 4 months with unprotected vitamin C should be considered to be devoid of that vitamin.

Vitamin D<sub>3</sub> and/or calcium deficiencies or problems with the Ca:P ratio, resulting in rickets and osteomalacia, are seen in small

passerines. Mostly the problems are noticed during the breeding season and egg laying. Tetracycline may also cause problems if administered while the bird is breeding, because tetracycline binds serum calcium.

Severe metabolic bone disease is often observed in ramphastid chicks. Clinically, the affected chicks are presented with soft folds in the beaks or almost folding-type fractures of the beak. The chicks may refuse to eat kibble, preferring the apparently tastier fruit. Commercial hand rearing diets may be accepted spontaneously by the chicks.

After changes in the bird's diet have been made, the majority of affected individuals regain a fairly normal bill with only slight structural modifications (Worell, 1997).

## Haemochromatosis

Haemochromatosis, or iron storage disease, is the most common non-infectious disease in softbills. Clinically, dyspnoea, weight loss, abdominal distension (hydrops ascites), and weakness are seen with hepatic haemochromatosis. Clinical pathology results usually show a hypoproteinaemia and an elevated activity of liver enzymes. At necropsy, iron storage disease is detected basically in the liver. In terminal cases, a liver fibrosis, concentric heart decompensation, lung oedema and hydrops ascites are noted. Sometimes iron will be found in other organs as well, especially in combination with an infectious disease. When iron is found in combination with an infectious disease, the iron is predominantly stored in macrophages, which

can eventually form extensive focal granulomas.

Toucans and mynahs suffer from a primary haemochromatosis, which is a species-specific inherited metabolic disorder that causes a relative excess of iron to be absorbed from 'iron-balanced' diets (Dorrestein *et al.*, 1992). In general, fructivorous, insectivorous and omnivorous birds accumulate more iron in their livers (Figures 7.7 and 7.8) than carnivorous, piscivorous and granivorous birds, even within the same order (Dierenfield and Sheppard, 1989; Dorrestein, 1997a). Figure 7.8

shows the distribution in hepatocytes and Kupffer cells in the livers of commonly affected avian orders. In Passeriformes, iron storage in hepatocytes is only noted in mynahs. In canaries and finches, the only iron found in the liver is related to an inflammatory reaction in Kupffer cells. These species/nutritional correlations are indicative of a species-specific genetic predisposition consistent with primary haemochromatosis.

In birds that are susceptible to iron storage in the liver, diets with 50–60 ppm can induce an iron liver storage (Cornelissen *et al.*, 1995).

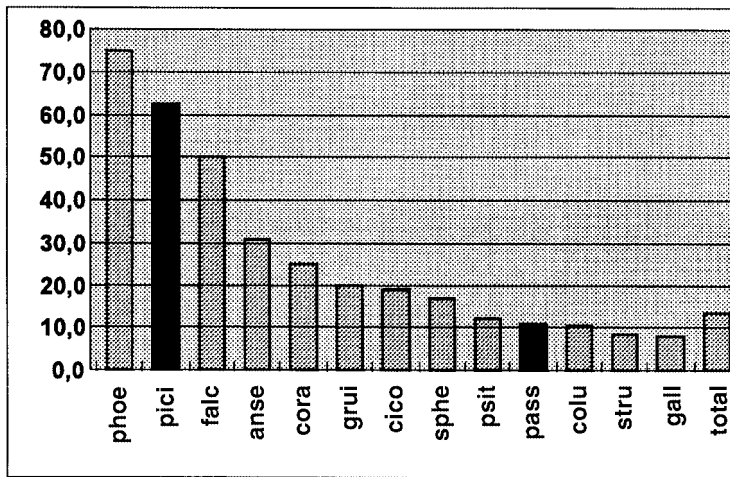


Figure 7.7 Percentage of livers positive for iron different avian orders (total birds is 945).

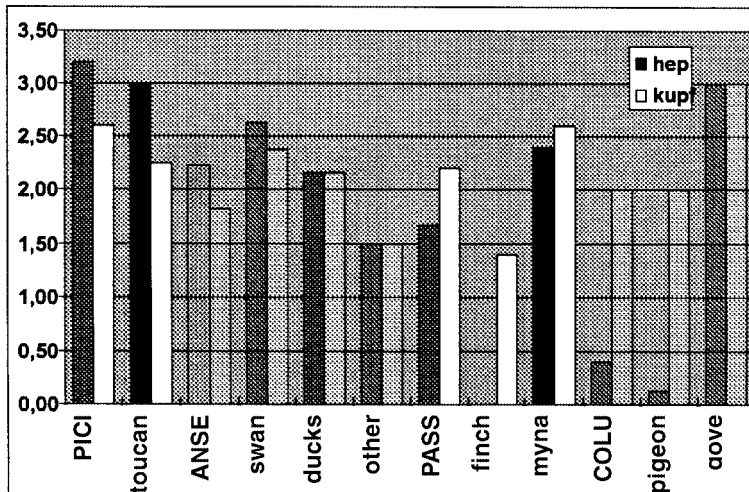


Figure 7.8 Average iron score (0 to 5) in hepatocytes and kupffer cells with emphasis on Piciformes and Passeriformes. In the Passeriformes iron in hepatocytes is only found in mynahs, not in canaries or finches.

Therefore, diets with a total iron of less than 50 ppm should be fed to mynahs and toucans, or the daily intake of iron should be 4–6 mg/kg bird per day.

Diets with 100 ppm iron or less have been recommended in order to reduce dietary sources. However, diets with less than 100 ppm iron are normally difficult to formulate. This observation may prove to be more in line with what is available to feed birds than what is needed to prevent excessive iron storage. Even diets with 100 ppm iron are in excess of the requirements for growth of poultry, which generally require 60–80 ppm.

In cases of confirmed iron storage problems it is advisable to collect some food, especially when it is a 'low-iron' diet, and freeze it for future analysis.

Dietary ascorbic acid promotes the bio-availability of dietary iron in animals, and consequently decreases the iron requirements. Ferrous iron forms chelate with ascorbic acid that is soluble in the alkaline environment of the small intestine, and is relatively efficiently absorbed (Klasing, 1998). In a comparative study in mynahs, pigeons and rats, the author was not able to confirm this hypothesis (Dorrestein *et al.*, 1992). Moreover, haemochromatosis is a symptom of a vitamin C deficiency in mammals (Klasing, 1998).

The presumptive diagnosis is made based on the diet, and on radiographs, which reveal an enlarged heart, liver and ascites; a liver biopsy confirms haemochromatosis.

Weekly phlebotomies to remove a blood volume equivalent to 1 per cent of the body weight are an effective treatment, and these are usually performed in conjunction with low-iron diets. A less invasive treatment has been documented, using deferoxamine (100 mg/kg q24h.s.c.) combined with a low-iron diet (65 ppm) for up to 4 months, until the iron content in the liver of the toucan has normalized (Cornellissen *et al.*, 1995).

## Diabetes mellitus

Diabetes mellitus is seen in toucans, which demonstrate the classical signs including weight loss, polydipsia, polyuria, anorexia and hyperglycaemia (> 55.1 mmol/l;

N = 11.0–19.3 mmol/l). Although the hyperglycaemia may be specifically related to a defective glucagon metabolism rather than to a lack of insulin production, affected individuals may respond to daily or intermittent insulin (0.1–0.5 units) injections (Worell, 1997).

## Amyloidosis

Amyloidosis is common in Gouldian finches, and is occasionally seen in other Passeriformes. Affected birds may be found dead, have a chronic non-specific history of illness or suffer from concurrent infections (polyomavirus, cryptosporidiosis). Social stress may play a role in the development of the disease. At necropsy the liver and kidney may appear grossly normal in some affected patients, but histologically the evidence of disease is severe. A hereditary predisposition is suspected in cases of amyloidosis in small passerines.

## Fatty livers

Fatty livers (hepatic lipidosis) are occasionally seen in Estrildid finches (zebra finch, parrot finch and star finch), and may be associated with inadequate exercise and high-energy diets such as soft foods and mealworms. The liver is swollen, yellow or tan in colour, and may float in formalin. The use of some formulated diets may help to resolve or prevent hepatic lipidosis (Macwhirter, 1994).

In canaries, lipogranulomata are commonly found in the liver. These lesions consist of foci formed by a variable number of vacuolated cells (probably macrophages), often mixed with lymphoid cells. In some cases heterophils have infiltrated as well. Lipogranulomata cannot generally be related to clinical problems, and the author has seen them in almost all canaries of all ages at necropsy. In other passerines or avian orders these lesions are only very rarely seen. Based on the fact that canaries are commonly fed with a large amount of rapeseed in their seed mixtures (up to 60 per cent), the hypothesis is that some glycosides interfere with the fat metabolism, resulting in these lipogranulomata.

## Haemorrhagic enteritis

'Haemorrhagic enteritis' is often diagnosed at necropsy, but this is not a 'true' enteritis and should be considered as a haemorrhagic diathesis (bleeding into the gut). This disease process is seen in small birds that are anorexic for over 24 hours. Causes of anorexia in affected patients include being too ill to eat (e.g. because of an infection or intoxication), getting the wrong food or no food at all (e.g. if someone other than the owner is feeding the birds). A typical sign of haemorrhagic enteritis at necropsy is an empty stomach.

A similar interpretation should be given to swollen white kidneys, which are the result of uric acid precipitation in the collection tubules. This occurs when birds do not drink and is often falsely called renal gout, although it should not be interpreted as either nephritis or gout. It should be differentiated from visceral gout caused by impaired renal function or a high-protein diet. Articular gout is a poorly understood chronic condition with no relation to renal function.

## Toxicosis

- 1 Carbon monoxide exposure can be rapidly fatal. Canaries and finches are particularly susceptible to inhalant toxins because they breathe more air per gram of body weight than larger birds, and they have a highly efficient gas exchange system (Macwhirter, 1994). There may be minimal changes at necropsy, or the lungs and blood may appear bright red.
- 2 Carbon dioxide poisoning may occur in crowded, poorly ventilated shipping boxes.
- 3 Polytetrafluoroethylene (Teflon®) released after overheating Teflon®-coated cooking utensils may be fatal to Passeriformes, as it is for psittacines. At necropsy, the extremely haemorrhagic, oedematous lungs are characteristic.
- 4 Avocado, or at least certain varieties, may be toxic to some passeriformes. Post-mortem findings in intoxicated birds include hydropericardium and subcutaneous oedema in the pectoral area (Hargis, 1989).
- 5 Green almonds have been considered as a cause of mortality in American goldfinches, presumably from cyanide released

by hydrolysis of amygdalin, a cyanogenic glycoside.

- 6 Ethanol toxicity has been reported in free-ranging passerines (especially cedar waxwings) following the ingestion of hawthorn pomes or other fruits that have frozen and then thawed, allowing yeast fermentation of sugars to produce ethanol. Birds are lethargic, ataxic, or may be in a stupor ('drunk'). Many intoxicated birds die from accidents that occur while they are 'flying under the influence'. The diagnosis is based on analysing crop contents and liver for ethanol concentrations (Fitzgerald *et al.*, 1990).
- 7 Heavy metal toxicosis caused by the direct consumption of the metal is uncommon in passerines, because they have limited capacity to damage metal objects. Lead or zinc toxicosis has occasionally occurred when galvanized wire has been used in the construction or repair of enclosures. Another source of zinc for passerine species is galvanized containers for supplying bath or drinking water. Removing the source of heavy metals and the administration of chelation therapy (Ca-EDTA 20–40 mg/kg i.v./i.m., followed by 40–80 mg/kg p.o. b.i.d. until the lead has disappeared) are recommended.

## Some non-infectious problems

### Management and hygiene-related problems

Many problems in aviaries are management and hygiene-related problems. These include location of the food and water containers where large quantities of droppings may collect; overcrowding, which leads to aggression; and insufficient nesting sites, resulting in poor breeding results. The control of ecto- and endoparasites is a matter requiring constant attention.

### Feather cysts

Feather cysts are common in canaries and are thought to be more prevalent in certain breeds – e.g. Norwich and 'intensive' type canaries (Plate 18). Cysts may occur individually or in

clusters involving an entire feather tract. Contents of the cysts may be gelatinous in the early days, ranging to dry, keratinous material in mature cysts. Treatment requires surgical removal of the affected follicles.

## Trauma

Picking is a common problem in aviaries, ranging from a few feathers lost on the back of the head to cannibalism. Zebra finches are particularly prone to cage mate trauma. Picking can also be the result of inappropriate sexual behaviour of one or more dominant male birds. Hierarchical aggression occurs when aviaries are overcrowded and nesting site territories are being established. Sick birds may attract aggressive behaviour; the attacked bird should therefore be separated and the underlying problem addressed.

Trauma often results in fractures of the lower legs. Splinting in a flexed position using layered masking tape is sufficient to allow healing. Splints are well tolerated, and can usually be removed in 3 weeks.

## Infectious diseases

Many infectious diseases are species-specific, although salmonellosis and pseudotuberculosis are exceptions. Coccidiosis is often diagnosed in finches, but most species appear to have their own coccidian species. These coccidia are often said to belong to the *Isospora lacazei* group.

## Viral diseases

### *Avian pox*

In captive passerines, avian pox as a septicaemic problem is almost exclusively seen in canaries and other *Serinus* spp. This disease predominates in the autumn and winter, with affected birds showing the cutaneous, diphtheric and septicaemic forms of the disease. The septicaemic or respiratory form causes a high mortality due to a severe tracheitis and, occasionally, pneumonic lesions around the bronchi.

Birds of all ages can be affected, and the mortality ranges from 20–100 per cent. The most alarming clinical signs are dyspnoea, debilitation and death. The infection is transmitted by insects and directly via blood from the lesions, and (less commonly) directly via the food and drinking water. A presumptive diagnosis can be made on the clinical signs, the lesions and cytology. A positive diagnosis is made after isolation of the virus or histological demonstration of the eosinophilic intracytoplasmic inclusion bodies in the epithelial cells, followed by an electron microscopic examination.

As a differential diagnosis, *Staphylococcus* spp., *Candida* spp. infection and trichomonads must be considered.

Preventive vaccination is possible by the cutaneous wing-web method, preferable in early summer. The vaccination must be repeated once every year. In case of an epidemic, all birds must be caged individually or, if this is impossible, in small groups. All clinically healthy birds should be vaccinated, and supportive treatment exists of the administration of antibiotics and multivitamin preparations. When there has been no mortality for 2 weeks, the birds can be housed in their flights again.

In masked bullfinches (*Pyrrhula erythaca*) a pox virus has been demonstrated, causing tumour-like lesions in the head region and inside the beak (Dorrestein *et al.*, 1993).

In young mynahs, keratitis, conjunctivitis and other eye problems have been identified in birds infected with avian pox virus. In other avian cases, pox lesions were located in the beak and commissure (Korbel and Kösters, 1998).

### *Polyoma-like and papilloma virus infections*

These infections occur in finch aviaries across Australia, Europe and the United States, and are probably more common than the number of cases actually diagnosed. These infections are mainly reported in Estrildidae and Fringillidae (e.g. Gouldian finches, painted finches, canaries, goldfinches and green finches) and in Shama (*Copsychus malabaricus*) (Crosta *et al.*, 1997; Vereecken *et al.*, 1998). The disease causes young nestling mortality, a more chronic disease in which poor development and beak abnormalities predominate, and

peracute death. Secondary infections appear to complicate the disease. Gross necropsy may reveal spleno/hepatomegaly and/or lung adenomatose, while the predominant histological lesions are hepatocellular necrosis, myocarditis, or lung adenomatose showing karyomegaly with foamy, intranuclear inclusions. Myocarditis may be seen. The diagnosis is made by a specific fluorescent antibody test on liver and spleen impression smears. In an electron microscopic examination of the intranuclear inclusions, discrete round to icohedral (20-sided) electron-dense particles, 45–50 nm in diameter, can be found.

Papilloma virus is found in European finches, and causes slow-growing, dry, wart-like epithelial proliferations of the skin of the feet and legs, 'tassel-foot' (Plate 19).

### ***Paramyxovirus infection***

Paramyxovirus (PMV) infection is commonly seen in many finches (e.g. African silverbills (*Lonchura malabarica cantans*), zebra finches and Gouldian finches), and serotype 3 causes torticollis in these birds. Depression and variable degrees of weight loss are other clinical signs often associated with this viral infection. The birds can be carriers for months before the clinical symptoms become manifest. The diagnosis is based on the symptoms, and can be confirmed by serology and virus isolation; necropsy is non-specific. A severe pancreatitis may be found on histological examination in some cases.

Antibiotic therapy produces no significant difference in survival rate or outcome. The disease must be differentiated from a vitamin E deficiency caused by feeding rancid cod-liver oil or mixing oil through the seed.

A number of paramyxoviruses have been reported in mynahs and toucans, including PMV-1 (ND), PMV-2 and PMV-3 (Worell, 1997). PMV-1 has been identified in recently imported mynahs (Korbel and Kösters, 1998), and the clinical symptoms associated with these birds included central nervous symptoms, opisthotonus and greenish slimy diarrhoea which started 4 weeks after their introduction into a collection. The diagnosis of PMV is based on clinical symptoms, isolation and characterization of the virus. A preventive inactivated vaccine is available.

### ***Herpesvirus and cytomegalovirus***

These viruses cause conjunctivitis and respiratory problems in Australian and African finches (Macwhirter, 1994). Lady Gouldians are very sensitive, and can be infected by recently imported wild-caught finches from Africa. The diagnosis is confirmed by demonstration in cytology and histology of (basophilic) intranuclear inclusion bodies in the mucosal epithelial cells of the trachea and conjunctiva.

A herpesvirus has been isolated from a toucan that died following a brief episode of depression and inappetence. A severe hepatitis with intranuclear inclusion bodies in liver and spleen were the principal histological lesions (Charlton *et al.*, 1990).

### ***Other virus infections***

Infections with influenza virus have been reported in finches and in imported mynahs. In a breeding flock of canaries, significant mortality of juvenile birds with neurological signs and nestling mortality has been associated with an adenovirus-like infection (Dorrestein *et al.*, 1996). Recently, a coronavirus has been demonstrated in the trachea of canaries with mild respiratory problems (Dorrestein *et al.*, 1998). In canary nestlings showing the so-called 'black spot', which is a gallbladder congestion, a circovirus has been demonstrated at electron microscopy, but a cultivation and infection trial were negative (Goldsmith, 1995).

Suspected leukosis cases are sporadically found at necropsy in passeriformes, especially in canaries. These birds historically show hepatomegaly and splenomegaly on gross necropsy. The histopathology is suggestive of leukosis. A virus aetiology is suspected, but this has never been confirmed.

### ***Bacterial infections***

#### ***E. coli*** (and other Enterobacteriaceae)

In normal healthy passerines, *E. coli* (and other Enterobacteriaceae) are absent in the intestines. However, these bacteria are very often demonstrated (by cytology) and isolated from the faeces or intestinal contents of diseased passerine birds both with and without diarrhoea. In toucans, *E. coli* (and *Staphylococcus*

spp. and *Streptococcus* serotype D) were found in the cloacae of 90 per cent of clinically normal toucans (Cornelissen and Ritchie, 1994).

*E. coli* septicaemia is suspected to be a major cause of epizootic mortality in newly arrived shipments of finches. *Citrobacter* spp. infection has also been reported as a cause of mortality in finches, and gross necropsy can, as with *E. coli*, be unrewarding. The Enterobacteriaceae present a secondary problem in finches more frequently than in canaries. The clinical signs and gross necropsy are not specific. In general, clinical signs include depression, conjunctivitis and rhinitis, and a few birds may die. These are secondary pathogens, however, and should be considered as a sign of poor health or management conditions. Possible causes are an unbalanced diet, housing problems or husbandry problems. Other primary diseases may be present (e.g. atoxoplasmosis or coccidiosis). Cultures are necessary for diagnosis, and a sensitivity test is essential for treatment. Treatment temporarily improves this condition, but only by suppressing clinical signs. Clinicians must search for the primary underlying cause to prevent recurrence.

In clinically healthy toucans, *E. coli* should be considered both as a normal passant of the intestines and as a potential pathogen (Worell, 1997).

Enterobacteriaceae are regularly cultured from passerine nestlings with diarrhoea ('sweating disease'). The antibiotics of choice are neomycin or spectinomycin, because they are effective and not resorbed from the gut. The selected drug is administered via the soft food. In fledglings, extra water, chopped greens and vegetables will prevent dehydration. As always, the clinician should remember that a specific culture and sensitivity is recommended to select the most effective antibiotic.

### ***Yersiniosis (pseudotuberculosis)***

Infection with *Yersinia pseudotuberculosis* is regularly seen in canaries and wild finches in the wintertime in Europe. The clinical signs are non-specific; ruffling of the feathers, debilitation and high mortality. At necropsy, a dark, swollen, congested liver and spleen with small, yellow, focal bacterial granulomata are often found, with an associated acute catarrhal pneumonia and typhlitis. Many rod-

shaped bacteria are seen in impression smears from all the organs, and diagnosis is confirmed after culturing the micro-organisms. The treatment of choice is amoxicillin via drinking water and soft food. Once sensitivity test results have been obtained, the antibiotic might need to be changed. Cleaning and disinfection are essential to prevent a relapse after therapy has been completed.

Mynahs and, especially, toucans are very susceptible to yersiniosis, and mortality can be high due to a peracute pneumonia. Post-mortem examination of affected birds demonstrates hepatomegaly, sometimes with small white foci, splenomegaly and an acute to peracute pneumonia. In Europe a form-line vaccine is available that appears to be clinically effective in reducing the prevalence of infections.

### ***Salmonellosis (paratyphoid)***

Infection with *Salmonella typhimurium* in small passerines appears identical with pseudotuberculosis, both clinically and at necropsy, although salmonellosis more often has a chronic course. Carriers are unknown in canaries. The diagnosis is confirmed after culturing the micro-organism. Fatal septicaemias are also reported in mynahs and toucans.

The antibiotics that are most effective are trimethoprim (with or without sulfa), amoxicillin or enrofloxacin, and the therapy needs to be combined with hygiene measures. A bacteriological examination of a pooled faecal sample in an enrichment medium should be performed 3–6 weeks after therapy to evaluate its success. The therapy and hygiene measures can be repeated until the bacteriological control remains negative.

### ***Campylobacter fetus***

*Campylobacter fetus* subsp. *jejuni* is often found in tropical finches, especially in Estrildidae. Society finches are commonly identified as carriers without conspicuous clinical symptoms. Clinical signs include apathy, retarded moulting, yellow droppings and a high mortality, especially among fledglings. The yellow droppings are caused by large amounts of undigested suspension (amylum). Sometimes parts of or whole seeds are found in the droppings. At necropsy the intestine is filled

with a yellow amyllum or whole seeds, resembling the beads of a rosary. Other necropsy findings are cachexia and a congested gastrointestinal tract. The diagnosis is confirmed by demonstrating the curved rods in stained smears from the droppings or gut contents, and cultivating the bacteria on special micro-aerophilic media. *Campylobacter* spp. have also been isolated from recently imported mynahs.

Treatment can be attempted with several antibiotics, but hygienic measurements are most important. Although campylobacteriosis is considered a potential zoonosis, there are no published reports of *Campylobacter* transmission from passerines to men.

### **Cocci infections**

*Streptococcus* spp. and *Staphylococcus* spp. are often demonstrated in passerines and rhamphastids. The clinical signs include abscesses, dermatitis, 'bumble foot', conjunctivitis, sinusitis, arthritis, pneumonia and death. In patients suffering from these infections, cocci will be seen in the impression smears. Local and systemic treatment with ampicillin or amoxicillin is the therapy of choice.

### **Enterococcus faecalis**

*Enterococcus faecalis* has been associated with chronic tracheitis, pneumonia and air sac infections in canaries. Clinically affected birds have harsh respiratory sounds, voice changes and dyspnoea.

### **Pseudomonas spp. and Aeromonas spp. infections**

Improperly prepared sprouted or germinated seeds, dirty drinking vessels or baths, and water sources can be the source of *Pseudomonas* spp. or *Aeromonas* spp. bacteria. A polluted flower-spraying mister, used for spraying the birds, can cause a severe necropurulent pneumonia and aerosacculitis. *Pseudomonas* spp. are often found as the result of an improper antibiotic treatment. Proper treatment includes locating the source of the trouble and administration of an antibiotic (after performing a sensitivity test). Until the results are available, the first choice antibiotic in these infections is enrofloxacin. Painstaking hygiene is essential, because many strains are resistant to antibiotic treatment.

### **Avian tuberculosis**

The classic tuberculosis with tubercles in the organs is seldom seen in small passerines. Tuberculosis (so-called atypical *Mycobacterium avium* or *Mycobacterium-avium-intracellulare*-complex) is most commonly found accidentally at necropsy in canaries and finches (Estrildidae). A new species, *M. genavense*, is also involved in avian tuberculosis, and is mainly isolated from patients with AIDS (Hoop *et al.*, 1995; 1996).

Incidental infections with acid-fast bacilli are seen relatively often. On histological examination, macrophages loaded with acid-fast bacilli can be found in many organs, especially in the liver or intestines. No signs are apparent at necropsy, except perhaps a dark, slightly swollen liver. In a flock of zebra finches with signs of a CNS disease, acid-fast bacteria were demonstrated in impression smears of brain, liver and intestines, and the bacterium was identified as *M. genavense* by using PCR (Sandmeier *et al.*, 1997).

Infections with *Mycobacterium* spp. have also been reported in mynahs and toucans as an enteritis catarrhalis, as well as classical tuberculosis (Korbel and Kösters, 1998).

The diagnosis is confirmed by demonstrating the acid-fast bacteria in tissue smears, while differentiation is possible using PCR techniques.

Treatment is not often practised. There is a zoonosis aspect, mostly for people with an immunocompromised physiological status. The enclosures need to be cleaned and disinfected. In the infected soil, the bacteria can survive for 2 years.

### **Ornithosis (chlamydiosis)**

This a relatively uncommon problem in passerines and softbills. The annual incidence of ornithosis in canaries at necropsy in the Netherlands is between 0 and 1.4 per cent. *Chlamydia* spp. has been isolated from the droppings of clinically normal finches in households in which clinical cases of chlamydiosis (psittacosis) occurred in psittacines (Macwhirter, 1994). In a study in Israel, 26 per cent of the Passeriformes tested by IFT were positive, ranging from 10 per cent in zoo collections up to 41 per cent in pet birds (Dublin *et al.*, 1995). Of these, 12 per cent



were found in the winter (December to February) and 41 per cent in the summer (June to August). In a study of wild birds in Austria using an ELISA test, five of 29 passerines were positive for the antigen and 15 of 17 showed antibodies (Pohl, 1995). Based on reviews, geographical areas and different test systems give large differences.

The symptoms are non-specific, and can include apathy, diarrhoea, debilitation, nasal exudate and conjunctivitis. The mortality is generally less than 10 per cent. Chlamydiosis should be expected in passerines with recurrent respiratory disease, especially if they are exposed to psittacines.

The diagnosis is made at necropsy by the presence of the chlamydial organism in impression smears from the altered air sacs and organs, using special staining techniques, or an enzyme-linked immunosorbent assay (ELISA) from swabs.

In mynahs, shedding has been demonstrated in clinically healthy birds (Korbel and Kösters, 1998).

Treatment with chlortetracycline (30 days) or doxycycline (30 days) via drinking water and soft food is clinically effective, but only when the birds continue to eat and drink the normal amount of food and water.

### ***Mycoplasma spp.***

*Mycoplasma* spp. have been isolated from canaries, and many cases of conjunctivitis and upper respiratory disease in canaries respond to tylosin; however, there has been no conclusive work proving that *Mycoplasma* spp. are associated with this syndrome. An epizootic of conjunctivitis in house finches (*Carpodacus mexicanus*) associated with *Mycoplasma gallisepticum* (MG) infection was reported in 1994 and 1995 from the United States (Fischer and Converse, 1995). The clinical signs ranged from mildly swollen eyelids with clear ocular discharge to severe conjunctivitis and apparent blindness.

Tetracyclines and enrofloxacin are believed to be effective against many *Mycoplasma* spp. Clinical signs of conjunctivitis associated with MG infection in house finches resolved following oral tylosin (1 mg/ml drinking water for at least 21 days) as the sole source of drinking water, in conjunction with topical ciprofloxacin

HCl ophthalmic solution for 5–7 days (Mashima *et al.*, 1997).

### ***Other bacterial infections***

Gram-negative oviduct infections, which if untreated can cause high mortality amongst canary hens sitting on their second round of eggs, are seen in epidemic proportions in canary breeding establishments in some years (Macwhirter, 1994).

*Erysipelothrix rhusiopathia*, *Listeria monocytogenes* and *Pasteurella multocida* (cat-bite?!) are occasionally isolated from dead passerine and softbill birds.

Megabacteria were recently classified as yeast-like organisms. Megabacteria spp. are large (20–50 µm), Gram-positive, periodic acid-Schiff (PAS) positive, rod-shaped organisms that have some fungal characteristics and have been found in the proventriculus or droppings of several avian species. In canaries, an infection caused by these organisms in the proventriculus is common, and is predominantly found on the mucosal surface and in the ducts of the glands. In a recent study, 22.9 per cent of Psittaciformes (35.8 per cent in budgerigars) and 19 per cent of Passeriformes (only 16.7 per cent in canaries) demonstrated a positive proventriculus at necropsy for these organisms (Ravelhofer *et al.*, 1998). Megabacterial colonization of the proventriculus in companion birds is not always associated with clinical signs or pathological lesions (De Herdt *et al.*, 1997).

Clinical signs of birds suffering from megabacteriosis can include apathy, anorexia, regurgitation, and the passing of part or whole seeds in soft, watery, dark green to brown/black faeces. These birds show a proventriculitis, and the pH in the lumen (originally 0.7–2.4) is increased to 7.0–7.4. These micro-organisms can be seen in a smear taken from the thick, whitish mucus covering the mucosa, and sometimes in faecal smears. The birds are often debilitated; the morbidity is high, but the mortality is low.

The diagnosis is based on demonstrating the organism in wet-mount or stained microscopic smears. organism seems to be a facultative anaerobe, and exhibits its best growth on blood agar when incubated in air with 10 per cent carbon dioxide at 37°C (Scanlan and Graham, 1990).

At necropsy, the organism can be demonstrated in the mucus of the proventriculus. The proventriculus is mostly distended, and the mucosa is covered with a cloudy, thick, mucus layer, predominantly in the lower part of the organ. The wall of the proventriculus is thickened and often shows small haemorrhages. The koilin layer may appear soft and devitalized.

Therapy needs to aim at improvement of the management conditions, including provision of easy digestible food (egg food), and lowering the pH in the proventriculus (6 ml 0.1N HCl/l or citric acid 1 g/l) to activate pepsin. *In vitro* studies have shown that the organism isolated from budgerigars is sensitive to a number of antibiotics (Scanlan and Graham, 1990); oral amphotericin B has proved effective in budgerigars, and oral nystatin in European finches (Filippich and Parker, 1994).

After 6 weeks the birds can be returned to a normal diet, which should include egg food as a regular supplement.

## Mycotic infections

Mycotic infections are not a significant problem in canaries, but are much more common in tropical finches, mynahs and toucans.

### *Candidiasis*

Care should be taken in evaluating faecal smears from passerines for candida. Many Passeriformes are fed yeast products, and yeast blastophores may pass through the gastrointestinal tract unchanged and appear in large numbers in the faeces. These organisms do not reflect disease, and do not grow on yeast culture media.

Cases of candidiasis are commonly seen in finches and toucans, and can be related to an unbalanced diet, poor hygiene, crowded conditions, excessive moisture, spoilage of food, stress, and the uncontrolled use of antibiotics. In nestlings and fledgling, crop candidiasis (with gas formation caused by fermentation and a thickened, opaque crop wall whose mucosa is covered with a white coating) is relatively common. In weanlings and adult birds, diarrhoea and moulting problems are more prominent. The typical signs in African

finches with endoventricular mycoses were lethargy, weight loss, a 'fluffed' appearance, passage of whole seeds in the stool, and in many cases the bird 'tilted' forward, elevating the abdomen and tail (Suedmeyer, 1997).

It is not uncommon to identify the yeast *Candida albicans* in cultures of the gastrointestinal tract of toucans and other softbills. Chicks that have poor daily weight gain or a poor feeding response should be examined for potential bacterial or yeast overgrowth. Cytology stain or cultures of the crop or cloaca should be performed to confirm the diagnosis.

In toucans, some cases of corneal ulcerations or mycotic dermatitis caused or complicated by *Candida* spp. can be found (Cornelissen and Ritchie, 1994).

The diagnosis is confirmed by finding the budding yeasts in crop swabs, faecal smears or skin scrapings. Intestinal candidiasis is treated with nystatin for 3–6 weeks, at a dose of 100 000 IU/l drinking water and 200 000 IU/kg soft food. The eye lesions and dermatitis can be treated with intravenous and topical amphotericin B. The predisposing factors should be addressed as well.

### *Fungi*

*Aspergillus* spp. is an uncommon finding in small passerines and Piciformes. In captive mynahs, however, *Aspergillus* spp. infections are much more common. In Munich, aspergillosis was diagnosed in 23.8 per cent of 147 mynah necropsies (Korbel and Kösters, 1998). In 92 necropsies of mynahs performed in Utrecht, seven cases showed a mycotic air sacculitis and pneumonia (Dorrestein and van der Hage, 1988). Acute deaths caused by *Penicillium griseofulum* were reported in a group of toucanets. Fungal infections are to be considered as opportunistic infections, and are generally the result of an impaired immunosystem (e.g. due to haemochromatosis, hypovitaminosis A, misuse of antibiotics such as tetracyclines).

Clinically chronic respiratory problems are suspect of a mycotic problem.

Clinical diagnosis involves culturing from tracheal swabs, X-rays and endoscopy. In some cases (e.g. syrinx aspergillomata or localized air sac involvement), surgery may be effective in treating the disease. In chronic cases, drug therapy has a poor prognosis.

Preventive measures include adequate vitamin A supplementation and improvement of management techniques.

Dermatomycosis are occasionally reported in passerines, and generally cause alopecia of the head and neck, or hyperkeratosis. *Microsporium* spp. and *Trichophyton* spp. are the most common aetiological agents identified, but saprophytic fungi may also be involved. Zoonotic aspects need to be considered.

Treatment with ketoconazole and griseofulvine provide some improvement, but does not always eliminate the infection.

Other mycotic infections reported in passerines include *Cryptococcus neoformans*, but this is very rarely seen as a disease problem in these birds.

Zygomycosis (mucormycosis) has been reported as appearing as multiple granulomata in the lung, liver or brain of canaries and finches. The incidents are related to feeding damp, germinated seeds (Macwhirter, 1994).

## Parasitic infections

### Protozoal infections

The most important protozoal infections in canaries are atoxoplasmosis, coccidiosis, toxoplasmosis and trichomoniasis. Atoxoplasma-like infections and cryptosporidiosis are found only occasionally in finches, starlings and mynahs, and are mostly restricted to individual birds; in those species of birds the infection is never seen as a flock problem. Coccidiosis, cochlosomosis and trichomoniasis are very common in finches. In softbills, *Giardia* spp. and coccidiosis are occasionally noted in faecal examination or post-mortem examination.

#### Atoxoplasmosis

Atoxoplasmosis (formerly Lankesterella) in canaries is caused by *Isoospora serini*, a coccidium with an asexual life cycle in the organs and a sexual cycle in the intestinal mucosa. Atoxoplasmosis is a disease of young canaries ranging in age from 2–9 months. The clinical symptoms are huddling and ruffling of the feathers, debilitation, diarrhoea, neurological signs (20 per cent) and death. Mortality can be as high as 80 per cent. An enlarged liver can be seen as a blue spot on the right side of the

abdomen caudal to the sternum, referred to by fanciers as 'thick liver disease'. At necropsy, an enlarged and sometimes spotted liver (with necrosis in the acute phase) may be seen, along with a huge, dark-red coloured spleen and, often, an oedematous duodenum with vascularization. In the imprints of the liver, spleen and lungs, parasites are found in the cytoplasm of the monocytes. The nucleus of the host cell is crescent-shaped. Coccidia spp. are seldom found in the faeces or intestinal contents because, after the acute phase is passed, only a few coccidia spp. (100–200/24 hours) are excreted. The therapeutic agent of choice is sulfachlorpyrazin (150 mg/l drinking water) until after moulting for 5 days a week. This treatment affects the production of oocysts, but does not influence the intracellular stages.

Other measurements to improve health of young birds include feeding one part egg food and one part seed mixture until after moulting, prevention of crowding, and better hygiene – especially cleaning and changing the floor coating. These measurements alone can prevent clinical outbreaks in infected canaries. This infection is also a common problem in other European finches kept in captivity (e.g. goldfinches, siskins, greenfinches and bullfinches).

#### Atoxoplasma-like infections

Atoxoplasma-like infections are seen in tropical finches, mynahs and other Sturnidae. Atoxoplasmosis and haemochromatosis are the primary medical problems in captive Bali mynahs. Atoxoplasma oocysts have been found in the faeces of wild Bali mynahs; however, it is unknown whether this disease is contributing to the birds' decline (Norton *et al.*, 1995).

#### Coccidiosis

*Isoospora* spp. have been described in more than 50 species of passerines throughout the whole world. Although this species was named *Isoospora lacazei*, the author is convinced that there are many different species. Coccidia spp. are frequently encountered in toucans.

In canaries, *I. canaria* is identified as a specific intestinal coccidiosis, and can be a problem in canaries over 2 months of age. The clinical symptoms are diarrhoea and

emaciation. At necropsy the duodenum is oedematous, often with extensive haemorrhages in the gut wall. Trophozoites of the parasite can be found in scrapings of the duodenal mucosa, and large amounts of oocysts are seen in wet preparations from the droppings. Therapy consists of strict hygiene measures and treatment with coccidiostatic drugs. Amprolium solution has been recommended for the treatment of coccidiosis at a dosage of 50–100 mg/l for 5 days, or sulphachlorpyrazin 300 mg/l drinking water, 5 days a week for 2–3 weeks.

*Eimeria* spp. are not common in Passerines and ramphastids, but single cases are being reported, based on the morphology of sporulated oocysts (*Eimeria* spp., four sporocysts with two sporozoites, 4:2; *Isospora* spp. 2:4). In Hill mynahs, *Eimeria* spp. is associated with a haemorrhagic enteritis (Korbel and Kösters, 1998).

Other coccidia, e.g. *Dorisiella* spp. (2:8) and *Wendyonella* spp. (4:4) have also been identified in passerines and Piciformes.

Sarcocystis has been identified in skeletal muscle of many Passeriformes, especially in North America. Cowbirds, grackles and other Passeriformes have been shown to be intermediate hosts for *Sarcocystis falculata*, for which opossums are the definitive hosts. Sarcocystis is usually found incidentally in necropsy examinations.

#### *Toxoplasmosis*

In the acute phase of toxoplasmosis, the birds (canaries and mynahs) may show severe respiratory signs. In canaries this phase is often not diagnosed, and the owner is only alarmed when several birds become blind many weeks after becoming infected. The route of infection is not known, but it is likely that oocysts excreted in cat faeces get into the aviary. In the acute phase, hepatomegaly and splenomegaly, and mostly a severe catarrhal pneumonia and a myositis of the pectoral muscle, are found in canaries and mynahs at necropsy. The trophozoites are easily identified in impression smears. The blind canaries have iridocyclitis or panophthalmitis, and trophozoites are only found in smears from the brains after a long search. In histological slides from the brains, (pseudo)cysts are relatively easy to find. Serology, immunofluorescence on brain tissue slides, or infection of

mice confirms the diagnosis. The Sabin-Feldman dye test will not detect *Toxoplasma gondii* antibodies in the serum of birds (Patton, 1996). No effective treatment is known.

#### *Cryptosporidiosis*

Cryptosporidiosis has been associated with acute onset, severe diarrhoea and death in a diamond firetail finch, but is not common in passerines or ramphastids. The case in the firetail finch showed focal cuboidal metaplasia of the glandular epithelium of the proventriculus and amyloid deposits in the proventriculus and kidneys. In another case, canaries were infected with cryptosporidia in the proventriculus and *Salmonella* spp. was concurrently isolated (Macwhirter, 1994).

#### *Trichomoniasis*

Trichomoniasis is commonly seen in many avian species. The protozoa is not very host-specific. In canaries, infections with *Trichomonas* spp. are seen sporadically, and birds of all ages can be affected. The clinical symptoms include respiratory symptoms, regurgitation, nasal discharge and emaciation. The diagnosis can be made in a live bird, using a crop swab. At necropsy, trichomoniasis infections present as a thickened, opaque crop wall. The flagellates can be identified, even when the bird is not very fresh, in crop smears stained with Hemacolor® or another 'quick stain'. The treatment is the same as for coelomose.

In mynahs, the lesions look like trichomoniasis in pigeons with typical lesions in the oral cavity.

Another flagellate is seen in the crop of canaries, causing the same clinical symptoms in full-grown birds and mortality in nestlings. The diagnosis can be made with a wet mount, but the flagellates are difficult to recognize. The parasite does not move about in the preparation, but 'waves' with its flagella (van der Hage and Dorrestein, 1991).

#### *Cochlosomosis*

The flagellate *Cochlosoma* spp., living in the intestinal tract of society finches, can cause many deaths among Australian finches fostered by these carriers (Poelma *et al.*, 1978). It is a problem in young birds from 10 days until 6 weeks of age. Typical symptoms are debilitation, shivering due to dehydration, and difficulties with moulting.

The diagnosis of cochlorsomosis is based on demonstrating the flagellates in fresh faeces. Treatment consists of ronidazole at 400 mg/kg egg food and 400 mg/l drinking water for 5 days. After a pause of 2 days, the regimen is repeated. This drug is relatively safe and no toxic signs have been seen. If dimetridazol is used, the concentration should not exceed 100 mg active drug per litre for 5 days. A sign of intoxication with dimetridazol is torticollis, and this will disappear after the medication is stopped. Metronidazole has also been reported to cause toxicity in finches.

Management should include disinfecting water containers, and the aviary should be kept clean and dry.

#### *Giardia* spp.

*Giardia* spp. has been reported to be associated with gastrointestinal tract infections in finches. In toucans giardiasis is frequently identified in faecal samples, but no clinical disease has been associated with these infections (Cornelissen and Ritchie, 1994). Treatment for *Giardia* spp. is the same as for trichomonads.

#### Blood parasites

Blood parasites may be detected on routine screening of apparently healthy passerines and ramphastids, but they are rarely implicated as the primary cause of disease or death. The most commonly encountered blood parasites include *Haemoproteus* spp., *Leucocytozoon* spp., *Trypanosoma* spp., *Plasmodium* spp. (malaria) and microfilaria.

*Plasmodium* spp., the cause of avian malaria, are mosquito-borne protozoa that occur world-wide. Sporogony occurs in the invertebrate host, schizogony occurs in the erythrocytes, and golden or black refractile pigment granules are formed from the host cell haemoglobin. *Plasmodium* spp. has been described in free-ranging passerines, including tits, finches, thrushes, starlings and sparrows. It is occasionally found in captive-bred birds such as canaries and other finches. Three species of *Plasmodium* have been documented in toucans. The diagnosis is based on the demonstration of the parasite in erythrocytes, and is differentiated from *Haemoproteus* spp. by the demonstration of the schizont in malaria. Clinical and post-mortem signs include anaemia and splenomegaly.

Treatment with chloriquine (250 mg/120 ml drinking water for 1–2 weeks) or pyrimethamine is successful in some cases, but a lasting immunity does not occur. Controlling of mosquito vectors is necessary to prevent infection.

*Haemoproteus* spp. are also found world-wide, but cause only mild or non-apparent clinical symptoms. For most species of *Haemoproteus* the intermediate hosts are hippoboscids flies, biting midges or tabanids. Diagnosis is based on identification of typical pigment-containing gametocytes in erythrocytes; but schizonts are not found in blood cells. Treatment is seldom indicated, and will be identical to the treatment for avian malaria.

*Leucocytozoon* spp. occur world-wide, and can infect either erythrocytes or leucocytes. Parasitized cells are so distorted by the parasite that it may be difficult to determine their origin. Pigment is not produced by *Leucocytozoon*, and schizonts cannot be found in peripheral blood. Megalochizonts can be found in brain, liver, lung, kidney, intestinal, heart, muscle and lymphoid tissue. Most infections are sub-clinical, although vague signs and death are reported.

*Trypanosoma* spp. are also found world-wide, but their incidence is low and they are only found during summer months in temperate climates. Vectors are thought to include hippoboscids flies, red mites, simuliids and mosquitos, and treatment is not warranted.

#### Helminthic parasitism

Helminthic parasites are usually of no significance in small passerines. Acanthocephalans, cestodes and nematodes have mostly been reported in free-ranging and captive large passerines (e.g. thrushes, grackles and starlings). Insect-eating species in particular show more parasitic infections.

The incidence of internal parasites in captive ramphastids is quite low. Ascarids, *Capillaria* spp. and gizzard worms (*Tetrameres* spp.) are occasionally noted in toucans and mynahs.

#### Nematodes

Two main types of roundworms affect passerines; *Ascaridia* spp., which have a direct life cycle and *Porrocaecum* spp., which have an indirect life cycle, with invertebrates such as earthworms as the intermediate host. Both

types of roundworms may be associated with weight loss, diarrhoea, general debility and, sometimes, neurological signs. *Ascaridia* spp. are uncommon in small passerines. *Porrocaecum* spp. have been found in a variety of free-ranging passerines (e.g. pipits, thrush, blackbirds and corvids). Ascarids are also frequently encountered in toucans. Fenbendazole, piperazine, levamisole and ivermectin, all orally applied, are useful in treating ascarid infections.

*Capillaria* spp., are cosmopolitan in their distribution and affect a range of passerines, including mynahs, and ramphastids. The life cycle is direct, or may involve earthworms as paratenic hosts. Susceptibility does not depend on dietary preferences, and the parasite has been found to cause disease in a variety of seed-eaters, insect-eaters, omnivorous species and honey-eaters.

High parasite loads may lead to weight loss, diarrhoea, general ill health and death. These worms may localize to a variety of sites in the gastrointestinal tract. They may be associated with white or creamy-coloured plaques in the buccal cavity or pharynx, and swelling of the crop, proventriculus, intestines or bowel. The typical *Capillaria* spp. egg has bipolar plugs and may be found by direct swabbing of lesions or faeces, or by faecal flotation.

Treatment may be more difficult than for ascarids. Aviary hygiene and removal of earthworms are important control measures. Anthelmintics may be effective in some cases. In a cleaned, dry environment, the eggs will lose their infectious capacity within 3 weeks without further disinfection (Korbel and Kösters, 1998).

*Syngamus trachea* (gapeworm) are found in outdoor aviaries and are a serious problem in mynahs, corvids and starlings. Earthworms may act as a transport host. The symptoms include gasping for breath, and the small passerines often die from occlusion of the trachea by the worms and the mucus produced. The diagnosis is confirmed by demonstrating the worms in the trachea by using backlighting, or by finding the typical eggs in the droppings. The worms are easily identified in the trachea at necropsy. Ivermectin (injection 200 µg/kg) and levamisole or fenbendazole are effective in treating this parasite, but caution should be exercised when treating birds with heavy infections, because

the worm dead can obstruct the trachea. In such a case with a heavy worm burden, treatment with a low dose of an anthelmintic (especially fenbendazole) over several days provides effective treatment.

#### *Spiruroids*

*Geopetitia aspiculata* is a parasite that lives in the proventriculus and has been reported in tropical birds housed at zoological gardens in Europe and North America (Kübber-Heiss and Juncker, 1997; Tscherner *et al.*, 1997). Insects (e.g. cockroaches, crickets) serve as intermediate hosts. *Geopetitia aspiculata* are pathogenic, leading to perforation of the wall of the proventriculus, often resulting in death. The parasite is not host-specific and is demonstrated in six avian orders, including Passeriformes (e.g. Emberizidae, Estrildidae, Fringillidae, Icteridae, Sturnidae – including a hill mynah) and insect-eating Piciformes (e.g. barbets and woodpeckers). The diagnosis is confirmed by finding the embryonated spiruroid eggs in the faeces (although this might not always be effective), followed by endoscopic demonstration of the proventricular lesions. At necropsy an enlarged abdomen is found, due to a mass of tightly coiled parasites attached to the serosa of the proventriculus, and worms are sometimes found in the liver. Infected birds can be successfully treated with ivermectin (300–400 µg/kg body weight s.c.) or fenbendazole (25 mg/kg body weight p.o. for 3 days). To interrupt the development cycle of the parasite, emphasis should be laid on eradication of the intermediate host.

*Acuaria skrjabini* infections of the gizzard, with mucosal necrosis, have been reported in adult finches in Australia. The mortality rate was 4–5 per cent, and oral treatment with 80 mg levamisole or 50 mg fenbendazole/l drinking water for 3 days was effective.

Feeding live food (such as maggots, mealworms or termites) or providing a compost heap in the aviary to attract insects for the birds to eat are both common management practices in Australia. These practices increase the likelihood of infection, as insects are the intermediate hosts for gizzardworms and tapeworms.

Tapeworm (*Cestoda*) infestations in softbills and insectivorous finches are common. They are not normally seen in canaries or

exclusively seed-eating birds, except in situations where parents feed insects to their offspring or insects are accidentally consumed with the seeds (Macwhirter, 1994). Some necropsies show small intestines literally packed with the tiny tapeworms. The typical hexacanth embryos are usually identified on faecal flotation.

Effective treatment for passerines include praziquantel and oxfenbendazole.

*Trematodes* have complicated life cycles that typically involve snails as initial intermediate hosts and other invertebrates as secondary intermediate hosts. Trematodes are seen occasionally in wild-caught passerines. *Schisto-zoma* spp. are trematodes that live in blood vessels and have been reported in North American goldfinches and cardinals. *Prosthogonimus* spp. are trematodes affecting the intestinal tract, cloaca, bursa of Fabricius or oviduct. These parasites been found worldwide in passerines, and are not particularly pathogenic. *Prosthogonimus* spp. have also been documented in a toucan (Giddings, 1988). Dragonflies and snails are intermediate hosts. Praziquantel (10 mg/kg) may be useful in treating trematodes.

### Arthropods

Ectoparasites, including blood-sucking mites (*Dermanyssus gallinae* and *Ornithonyssus sylviarum*), skin mites (e.g. *Backericheyla* spp. and *Neochelyletia media*) and feather mites (e.g. Epidermotidae, *Dermation* spp.) are found in the calamus of the feathers. Meal-mites (*Tyroglyphus farinae*) are not parasites, but their large number on a bird can cause unrest and irritation.

The red mite (*Dermanyssus gallinae*) is a blood-sucking mite that can cause serious mortality among fledglings as well as adult birds. The common clinical sign in affected patients is anaemia. A bird with respiratory symptoms and a PCV of less than 30 per cent should be suspected of having serious problems with blood-sucking mites. The main complaint from the owner is a general depression; the mites are often not detected or their presence is even denied. The red mite spends the day in the nest or birdroom crevices, and ventures out at night to attack the birds. Treatment should be prompt, and consists of dusting or spraying the victims with an insecticide and vacating the cage or

room during the day and thoroughly cleaning it.

The white or Northern mite (*Ornithonyssus sylviarum*) is increasingly found to cause problems in aviaries. This blood-sucking mite spends its entire life on the host. Dusting with insecticides can be hazardous, especially to nestlings. A relatively safe method of treatment is to put one drop of 0.1 per cent ivermectin in propylene glycol on the bare skin; however, the mites are killed only after sucking blood.

Other ectoparasites may cause some irritation or feather damage. They are considered a sign of inadequate hygiene and management.

Quill mites have been described in passerines, and infested birds show clinical signs of irritation, pruritis, feather-picking and feather-loss. These signs are rarely severe. The mites seem to feed on the quill tissue, and not on blood or sebaceous fluid. Many different species of quill mites are described, including *Syringophylus* spp., *Harpyrhynchus* spp., *Dermatoglyphus* spp. and *Picobia* spp. The diagnosis is made by inspection (usually with magnification) of quill material. Treatment with ivermectin (spot-on 0.1 per cent ivermectin in propylene glycol) is very effective (Dorrestein *et al.*, 1997).

*Cnemidocoptes pilae* infections, or scaly mites, are occasionally seen on the beak base of finches. In general, they tend to cause hyperkeratotic lesions on the feet in Passeriformes. These mites are easily found and recognized in scrapings from the altered areas. Treatment with any oil or 0.1 per cent ivermectin applied locally will cure the birds. This infestation should not be confused with the so-called 'tassel foot' found in the European goldfinch (*Carduelis carduelis*), which is caused by a papillomavirus.

Lice are fairly common in Passeriformes. Some biting lice are not specialized for life on particular feathers, and are able to move quickly. Chewing lice are often more adapted to a particular part of the body, and are more sluggish. Signs of the presence of lice include restlessness and biting, excessive preening, and damage to the plumage. Some cases of baldness in canaries are caused by lice. Lice undergo a complete life cycle on the bird, and a weekly dusting with pyrethrins is an effective method of control (Macwhirter, 1994). Some

species of Estrildidae are hypersensitive to pyrethrin, and care must be taken in its use.

#### Endoparasites

Air sac mites (*Sternostoma tracheacolum*) are occasionally found in canaries, but they are seen mostly commonly in Australian finches. They are not reported in softbills. This problem is also seen in wild Gouldian finches in Australia, and may have been introduced with domestic canaries. The mites' life cycle is unknown, but it is theorized that nestlings become infected by parents regurgitating nutrients with mites. Adults may be exposed via contamination of water and food, and by coughing or sneezing.

Clinical signs include a decline in physical condition, respiratory distress, wheezing, squeaking, coughing, sneezing, nasal discharge, loss of voice, head shaking and gasping. The mortality is low. Diagnosis of air sac mites can sometimes be made by transillumination of the trachea in live birds, with the mites visible as tiny black points in the

trachea. The throat of the bird must be wetted (e.g. with alcohol) and the feathers parted. Post-mortem examination, however, is more reliable, and the condition is diagnosed by finding in the mites in the air sacs, the lungs and/or the trachea. Airsacculitis, tracheitis and focal pneumonia may be evident.

Several therapeutic regimens have been described for air sac mite infestations. Pest strips make a reasonable good air sac mite preventative, provided the bird does not come into direct contact, and only if the bird is not held within a small enclosure. Ivermectin can be used for individual treatment by a spot-on method of 0.1 per cent ivermectin in propylene glycol, one drop on the bare skin dorso-lateral to the thorax inlet or on the chest. A small amount of alcohol is necessary to view the site of application.

*Cytodites nudus* is another mite that has occasionally been associated with respiratory disease in free-ranging passerines. It may be found in the abdominal cavity as well as the respiratory system.

**Table 7.8** Zoonotic diseases of passerines

Allergy	Although known associated with finches it is very rare, more commonly associated with pigeons
Viruses	Very unlikely; Newcastle disease is always mentioned and might play a role with chickens
<b>Bacteria</b>	
<i>Ornithosis</i> or <i>Chlamydia psittaci</i>	Infection: uncommon infection in passerines or ramphastids. However, if influenza-type symptoms occur in man, with high fevers, atypical pneumonia, muscle pain and serious headache, a physician should be consulted. Transmission is aerogenic. Treatment in man is generally with doxycycline
<i>Tuberculosis</i>	In Passeriformes and Ramphastidae, only <i>Mycobacterium-avium-intracellulare</i> complex, which is of minor importance as a direct zoonosis. <i>M. genavense</i> is a new species that is mainly isolated from patients with AIDS and has also been identified in 20 per cent of the culturally confirmed avian tuberculosis cases (Hoop <i>et al.</i> , 1995, 1996). Only a danger in those who are immunocompromised
<i>Salmonella typhimurium</i> , <i>S. enteritidis</i>	Sometimes isolated from passerines and possibly also from Ramphastidae. Confirmed transmissions to man have only been incidental findings. In man these cause gastroenteritis, headache, shivering, stomach ache and retching, followed by vomiting and diarrhoea
Other bacteria	These include <i>Campylobacter</i> spp., <i>Yersinia pseudotuberculosis</i> , <i>Listeria monocytogenes</i> , and possible many others such as <i>E. coli</i> , <i>Klebsiella pneumoniae</i> , etc. However, human involvement is very uncommon and incidental and occurs only in the most extreme situations
Fungi	<i>Trichophyton</i> spp., <i>Candida albicans</i> and <i>Aspergillus</i> spp. are all mycotic species that have been isolated from immunocompromised people, but under normal hygienic circumstances problems with these fungi are rare
Parasites	<i>Dermanyssus</i> mites can bite people when they are cleaning cages, causing itching erythromatosis, urticaria or papillomatous exanthema



## Zoonoses

Zoonotic diseases of passerines are listed in Table 7.8.

## References

- ALTMAN, R. B., CLUBB, S. L., DORRESTEIN, G. M. and QUESENBERRY, K. E. (eds) (1997). *Avian Medicine and Surgery*, p. 1021. W. B. Saunders.
- BRANCH, S. (1987). Breeding and handrearing toucans. *AAV Today*, **1**, 170–71.
- CARPENTER, J. W., MASHIMA, T. Y. and RUIPIPER, D. J. (1996). *Exotic Animal Formulary*, p. 156. Greystone Publications.
- CHARLTON, B. R., BARR, B. C., CASTRO, A. E. *et al.* (1990). Herpes viral hepatitis in a toucan. *Avian Dis.*, **34**, 787–90.
- CORNELISSEN, H. and RITCHIE, B. W. (1994). Ramphastidae. In: *Avian Medicine: Principles and Application* (B. W. Ritchie, G. J. Harrison and L. R. Harrison, eds), pp.1276–83. Wingers.
- CORNELISSEN, H., DUCATELLE, R. and ROELS, S. (1995). Successful treatment of a channel-billed toucan (*Ramphastos vitellinus*) with iron storage disease by chelation therapy: sequential monitoring of the iron content of the liver during the treatment period by quantitative chemical and image analyses. *J. Avian Med. Surg.*, **9**, 131–7.
- COUTTEEL, P. (1995). The importance of manipulating the daily photoperiod in canary breeding. In: *Proc. 3rd Conf. Eur. AAV*, Jerusalem, pp. 166–70. European Association of Avian Veterinarians.
- CROSTA, L., SIRONI, G. and RAMPIN, T. (1997). Polyomavirus infection in Fringilidae. *Proc. 4th Conf. Eur. AAV*, London, pp. 128–31.
- DE HERDT, P., DUCATELLE, R., DEVRIESE, L. A. *et al.* (1997). Megabacterium infections of the proventriculus in passerine and psittacine birds: practice experiences in Belgium. In: *Proc. 4th Conf. Eur. AAV*, London, pp. 123–7. European Association of Avian Veterinarians.
- DIERENFIELD, E. and SHEPPARD, C. D. (1989). Investigations of hepatic iron levels in zoo birds. In: *Proc. 8th Dr. Scholl Conf. Nutr. Captive Wild Animals*, pp. 101–14. Lincoln Park Zoological Society, Chicago.
- DODWELL, G. T. (1986). *The Complete Book of Canaries*. Howell Book House Inc.
- DORRESTEIN, G. M. (1997a). Passerines. In: *Avian Medicine and Surgery* (R. B. Altman, S. L. Clubb, G. M. Dorrestein and K. E. Quesenberry, eds), pp. 867–85. W. B. Saunders.
- DORRESTEIN, G. M. (1997b). Diagnostic necropsy and pathology; avian cytology. In: *Avian Medicine and Surgery* (R. B. Altman, S. L. Clubb, G. M. Dorrestein and K. E. Quesenberry, eds), pp. 158–69; 211–22. W. B. Saunders.
- DORRESTEIN, G. M. and SCHRIVER, J. (1982). A genetic defect in the vitamin A metabolism in recessive white canaries. *Tijdschr. v. Diergeneesk.*, **107**, 795–9.
- DORRESTEIN, G. M. and VAN DER HAGE, M. H. (1988). Veterinary problems in mynah birds. In: *Proc. AAV*, Houston, pp. 263–74. Association of Avian Veterinarians.
- DORRESTEIN, G. M., GRINWIS, G. M., DOMINGUEZ, L. *et al.* (1992). An induced iron storage disease syndrome in doves and pigeons: A model for haemochromatosis in mynah birds? (a preliminary report). *Proc. Ann. Conf. AAV*, New Orleans, pp. 108–12. Association of Avian Veterinarians.
- DORRESTEIN, G. M., VAN DER HAGE, M. H. and GRINWIS, G. (1993). A tumour-like pox lesion in masked bull finches (*Pyrrhula erythaca*). In: *Proc. 2nd Eur. AAV*, Utrecht, pp. 232–40. European Association of Avian Veterinarians.
- DORRESTEIN, G. M., VAN DER HAGE, M. H. and VAN GARDEREN, E. (1996). Virus infections in passerines with special reference to a Coronavirus-like infection in canaries (*Serinus canaria*). In: *Proc. Main Conf. AAV*, pp. 171–6. Association of Avian Veterinarians.
- DORRESTEIN, G. M., CREMERS, S. H. J., VAN DER HORST, H. J. *et al.* (1997). Quill mite (*Dermoglyphus passerinus*) infestation of canaries (*Serinus canaria*): diagnosis and treatment. *Avian Pathol.*, **26**, 195–9. European Association of Avian Veterinarians.
- DORRESTEIN, G. M., VAN DER HAGE, M. H., FUCHS, A. *et al.* (1998). A Coronavirus-like infection in canaries (*Serinus canaria*): pathology and diagnosis. In: *Proc XI Tagung über Vogelkrankheiten*, München, pp. 110–19.
- DUBLIN, A., MECHANI, S., MALKINSON, M. *et al.* (1995). A 4-year survey of the distribution of *Chlamydia psittaci* in 19 orders of birds in Israel with emphasis on seasonal variability. In: *Proc. 3rd Conf. Eur. AAV*, Jerusalem, p. 1. Association of Avian Veterinarians.
- FILIPPICH, L. J. and PARKER, M. G. (1994). Megabacteria and proventricular/ventricular disease in psittacines and passerines. In: *Proc. AAV*, Reno, pp. 287–93. Association of Avian Veterinarians.
- FISCHER, J. R. and CONVERSE, K. A. (1995). Overview of conjunctivitis in house finches in the eastern United States, 1994–1995. In: *Proc. Joint Conf. AAZV, WDA, AAUV*, pp. 508–9. American Association of Zoo Veterinarians.
- FITZGERALD, S. D., SULLIVAN, J. M. and EVERSON, R. J. (1990). Suspected ethanol toxicosis in two wild cedar waxwings. *Avian Dis.*, **34**, 488–90.
- GIDDINGS, R. F. (1988) Treatment of flukes in a toucan. *J. Am. Vet. Med. Assoc.*, **193**, 1555–6.
- GILL, F. B. (1994). *Ornithology*. Freeman and Company.
- GOLDSMITH, T. (1995) Documentation of passerine circoviral infection. In: *Proc. Main Conf. AAV*, pp. 349–50. Association of Avian Veterinarians.
- HARGIS, A. M. (1989). Avocado (*Persea americana*) intoxication in caged birds. *J. Am. Vet. Med. Assoc.*, **194**, 64–6.
- HOOP, R. K., OSSEN, P. and PFYFFER, G. (1995). *Mycobacterium genavense*: a new cause of mycobacteriosis in pet birds? In: *Proc. Eur. Conf. AAV*, Jerusalem, pp. 1–3. European Association of Avian Veterinarians.

- HOOP, R. K., BÖTTGER, E. C. and PFYFFER, G. (1996). Etiological agents of Mycobacteriose in pet birds between 1986 and 1995. *J. Clin. Microbiol.*, **34**, 991–2.
- KLASING, K. C. (1998). Vitamins. In: *Comparative Avian Nutrition* (K. C. Klasing, ed.) pp. 277–329. Cab International.
- KORBEL, R. and KÖSTERS, J. (1998). Beos. In: *Krankheiten der Heimtiere*, 4th edn (K. Gabrisch and P. Zwart, eds), pp. 397–428. Schlütersche Hannover.
- KÜBBER-HEISS, A. and JUNCKER, M. (1997). Spiruridosis in birds at an Austrian Zoo. In: *Proc. 4th Conf. Eur. AAV*, London, pp. 102–6.
- LABONDE, J. (1996). Medicine and surgery of mynahs. In: *Diseases of Cage and Aviary Birds*, 3rd edn (R. W. Rosskopf Jr and R. W. Woerpel, eds), pp. 928–32. Williams & Wilkins.
- LONGO, J. (1989). Breeding the Toco topucan. In: *Proc AAV*, pp. 248–9. Association of Avian Veterinarians.
- MACWHIRTER, P. (1994). Passeriformes. In: *Avian Medicine: Principles and Application* (B. W. Ritchie, G. J. Harrison and L. R. Harrison, eds), pp. 1172–99. Wingers.
- MARTINEZ DEL RIO, C., BOZINOVIC, F., DSABAT, P. and NOVOA, F. (1996). Digestive ability and dietary flexibility in Passerine birds: a collection of 'not so stories'. In: *Symp. Comparative Nutrition Society 1*, pp. 87–91.
- MASHIMA, T. Y., LEY, D. H., STOSKOPF, M. K. *et al.* (1997). Evaluation of treatment of *Mycoplasma gallisepticum*-associated conjunctivitis in house finches (*Carpodacus mexicanus*). *J. Avian Med. Surg.*, **11**, 20–24.
- MASSEY, J. G. (1996). Clinical medicine in small Passerines. In: *Proc. Main Conf. AAV*, pp. 49–53. Association of Avian Veterinarians.
- NORTON, T. M., SEIBELS, R. E., GREINER, E. C. and LATIMER, K. S. (1995). Bali mynah captive medical management and reintroduction program. In: *Proc Main Conf AAV*, pp. 125–36. Association of Avian Veterinarians.
- OTTEN, B. A., OROSZ, S. E., FRAZIER, D. L. and AUGÉ, S. (1997). Toucans in Belize: Implications of diet on hemochronatosis. In: *Pro. Main Conf. AAV*, pp. 105–7.
- PATTON, S. (1996). Diagnosis of *Toxoplasma gondii* in birds. In: *Proc. Main Conf. AAV*, pp. 75–8. Association of Avian Veterinarians.
- POELMA, F. G., ZWART, P., DORRESTEIN, G. M. and IORDENS, C. M. (1978). Cochlosomose, a problem in raising Estrildidae in aviaries. *Tijdsch. Diergeneesk.*, **103**, 589–93.
- POHL, U. (1995). Chlamydia psittaci in Austrian wild birds. In: *Proc. 3rd Conf. Eur. AAV*, Jerusalem, pp. 15–17. European Association of Avian Veterinarians.
- RAVELHOFFER, K., ROTHENDER, R., GAREIS, M. *et al.* (1998). Megabacteria infections of various avian species. In: *Proc. XI Tagung über Vogelkrankheiten*, München, pp. 95–104. DVG.
- SANDMEIER, P., HOOP, R. K. and BOSSHART, G. (1997). Cerebral mycobacteriosis in zebra finches (*Taeniopygia guttata*) caused by *Mycobacterium genavense*. In: *Proc. 4th Conf. Eur. AAV*, London, pp. 119–22. European Association of Avian Veterinarians.
- SCANLAN, C. M. and GRAHAM, D. L. (1990). Characterization of a gram-positive bacterium from the proventriculus of budgerigars (*Melopsittacus undulatus*). *Avian Dis.*, **34**, 779–86.
- SUEDMEYER, W. K. (1997). Clinical management of endoventricular mycosis in a group of African finches. In: *Proc. Main Conf. AAV*, Reno, pp. 225–7.
- TAYLOR, E. J. (1996). An evaluation of the importance of insoluble versus soluble grit in the diet of canaries. *J. Avian Med. Surg.*, **10**, 248–51.
- TSCHERNER, W., WITTSTATT, U. and GÖLTENBOTH, R. (1997). *Geopetitia aspiculata* Webster, 1971 – a pathogenic nematode in tropical birds in zoological gardens. *Zool. Garten N.F.*, **67**, 108–20.
- VAN DER HAGE, M. H. and DORRESTEIN, G. M. (1991). Flagellates in the crop of canary bird. In: *Proc. 1st Eur. AAV*, Vienna, pp. 303–7. European Association of Avian Veterinarians.
- VERECKEN, M., DE HERDT, P., CHARLIER, G. *et al.* (1998). An outbreak of polyomavirus infection in Shamas (*Copsychus malabaricus*). In: *Proc XI Tagung über Vogelkrankheiten*, München, pp. 176–83.
- WALSBERG, G. E. (1983). Avian ecological energetics. *Avian Biol.*, **7**, 161–220.
- WHITE, J. (1997). Neotropical songbirds and veterinary medicine: are we giving them the attention they deserve? In: *Proc. Main. Conf. AAV*, Reno, pp 77–81. Association of Avian Veterinarians.
- WOLF, P., KAMPHUES, J., BARTELS, T. and DEHNING, S. (1997). Enzyme activities along the intestinal tract of pet birds. *Abstr. 1st Int. Symp. Pet Bird Nutr.*, Hannover, pp. 27–8.
- WORELL, A. B. (1997). Toucans and mynahs. In: *Avian Medicine and Surgery*. (R. B. Altman, S. L. Clubb, G. M. Dorrestein and K. E. Quesenberry, eds), pp. 910–17. W. B. Saunders.

---

# Raptors

*Patrick T. Redig and Janette Ackermann*

## Part I: Overview

### Introduction

In Latin, the term 'raptor' means 'to seize'. The term is also descriptive of the powerful, grasping, talon-tipped feet found in all birds of prey, and is used as a name for the group of birds whose members have this common feature. Raptors include all species in the orders Strigiformes and Falconiformes (Cooper, 1996). There were five families within the order Falconiformes; the Accipitridae (hawks), the Cathartidae (vultures), the Falconidae (falcons), the Pandionidae (ospreys) and the Sagittariidae (secretary birds). However, recently the family Cathartidae has been moved to the order Ciconiiformes. Within Accipitridae are three distinct groups; accipiters, buteas and eagles. The order Strigiformes has two families; the Tytonidae (barn owl) and the Strigidae (all other owls). Taxonomically unrelated relatives, but usually included with raptors because of behavioural similarities, are ravens, a member of the Corvidae (crow and jay) family within the order Passeriformes.

Raptors have a longstanding association with human beings. They have been incorporated into ancient religions and mythologies as well as modern-day culture, and have been and still are used in the sport of falconry. Falconry, hunting with trained raptors, peaked in popularity in Western civilization during the medieval age in Europe, but has seen a marked resurgence in recent times.

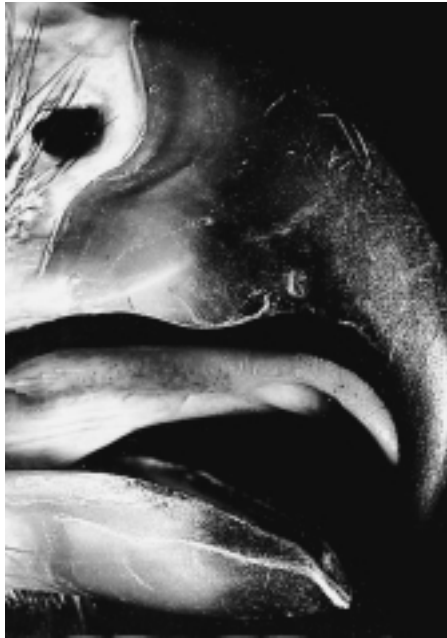In the last two decades there has been an increase in environmental awareness and conservation efforts involving raptors. These efforts include captive propagation, rehabilitation and reintroduction. Keeping birds of prey in zoos and education facilities is part of

this conservation effort. As a result, more raptors are being brought to veterinarians and wildlife rehabilitation facilities for treatment. This chapter will be a basic introduction to raptor biology, husbandry and medical care. The reader is referred to cited literature for more in-depth information on these topics.

There are many legal requirements that must be met by persons who choose to handle and keep birds of prey. All species of raptors in the US are federally protected, and most also have state protection. Special permits, acquired from the United States Fish and Wildlife Service at their regional offices and respective state agencies, are needed for both falconers and rehabilitators. Varying legislation exists in Europe and other countries.

### Biology and anatomy

All raptors are carnivores, and they have specialized anatomical and physiological characteristics that give them great hunting capabilities. These characteristics vary, depending on the life style of the birds. Diurnal raptors rely heavily on sight to locate food, and have evolved very large and sensitive eyes. As with all other avian species, they have striated muscles in their ciliary bodies, which allows them to focus quickly on their prey. Nocturnal raptors, such as the owls, have even larger eyes; however, they also rely heavily on hearing to locate their prey. The ear openings are very large and they are bilaterally asymmetrical, resulting in differential sound detection, which is an aid to auditory prey loca-



(a)



(b)

**Figure 8.1** All raptors possess strongly curved bills. (a) Bills of eagles (golden eagle) and buteos have smooth contours to the rhinotheca. (b) Bills of falcons (peregrine falcon) have a tomial tooth. The baffle or operculum is visible in the nares. (Photo by G. Buhl.)

tion in total darkness. The ear tufts on many of the owl species do not aid in hearing, as is often thought; rather, they are part of an owl's camouflage repertoire.

Another feature unique to raptors that complements their hunting capabilities is their stout, sharply hooked bill (Figure 8.1a). The bill is made of keratin and grows from the cere. It is a highly specialized tool that has functional morphologic variations related to specific dietary habits. For example, the snail kite has a very long, sharply hooked maxilla to allow it to extract the soft flesh of apple snails from their shells. Falcons have a notch on their maxilla (Figure 8.1b) which forms an almost tooth-like structure, called a tomial tooth, that is believed to enable them easily to sever the neck of vertebrate prey. It is important to preserve this structure when performing any repairs or trimming the bill. The nares of falcons, buteos and eagles have a bony baffle, or operculum (Figure 8.1a), which is thought to reduce the air pressure in the nostrils during high speed flight (Heidenreich, 1997).

### ***Feathers and plumage***

The wings and feathers of raptors are modified in accordance with their specialization. The falcons possess long, tapered, pointed wings that enable them to achieve great speed in their flight. They are perfectly adapted to hunting other avian species on the wing in vast open spaces. The accipiters have shorter, rounded wings and very long tails, which give them great manoeuvrability with short, sudden bursts of speed. They hunt prey, both small rodents and avian species, in heavily wooded habitats. Finally, the buteos (or soaring hawks) have broad, rounded wings and tails, which facilitate soaring on the rising currents of warm air called thermals.

Owls have a unique feathering feature where all the flight feathers have a serrated leading edge. This condition permits almost soundless flight, which helps them catch nocturnal prey species that are also dependent on hearing for survival in the low light conditions.

Most raptors moult their feathers once per year in the early summer. The timing and pattern vary with the species, age and sex of the individual bird. Young raptors grow all their feathers in at the same time. However, in subsequent annual moults the wing feathers come down in pairs, one from the right and one from the left. This mechanism means there is only a slight flying handicap during the 6 months required for moulting, unlike in waterfowl, which lose all their primary feathers at one time and are flightless for 4–6 weeks. Some owls, such as barred owls (*Strix varia*), moult all their tail feathers at once. Juvenile or first year plumages are typically distinctly different from the adult plumages attained once the birds are over 1 year of age. Small owls, such as the saw-whet owl (*Aego-*

*lius funereus*), moult into adult plumage in the late summer of their first year.

With the exception of the Northern harrier (*Circus cyaneus*), American kestrel (*Falco sparverius*), merlin (*Falco columbarus*) and osprey (*Pandion haliaetus*), the plumages of North American raptors are not sexually dimorphic – that is, no distinct differences exist between males and females. In many situations it is not possible to determine sex of raptors based on plumage characteristics.

Feathers broken during medical treatment and/or the rehabilitation process should be repaired before the raptor is released back into the wild, in order to give it the best chance of survival. This repair process is called ‘imping’ (Arent and Martell, 1996; Heidenreich, 1997; Figure 8.2).



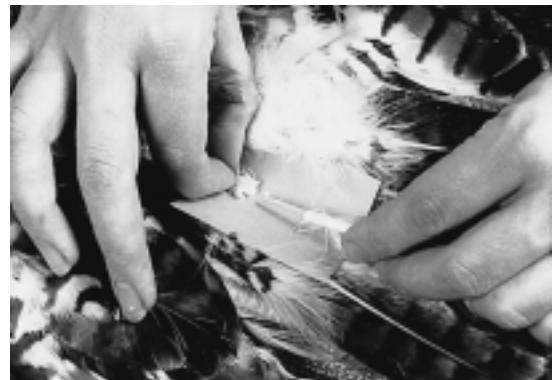(a)



(b)



(c)



(d)

**Figure 8.2** Broken feathers (a) are easily repaired by ‘imping’. The replacement feather is trimmed to the correct length (b), then a piece of bamboo is carved to make a triangular-shaped and tapered imping needle (c). Five-minute epoxy is applied to the imping needle, and its ends are inserted into the replacement feather and the original cut shaft (d). (Photos by R. Winch.)



**Figure 8.3** Tail feathers of caged raptors should always be protected with a tail sheath. This is fashioned from manila paper or discarded X-ray film and affixed to the covert feathers with adhesive tape. (Photo by P. T. Redig.)

Since the feathers of juvenile raptors are typically longer than those of adults, exact matching of feathers for age and sex is desired where possible. Tail feathers of hospitalized raptor patients should be protected from breakage and soiling by covering them with a tail sheath made from an envelope of heavy paper or discarded radiograph film that fits over the tail and is affixed to the covert feathers with adhesive tape (Arent and Martell, 1996; Figure 8.3).

### **Feet**

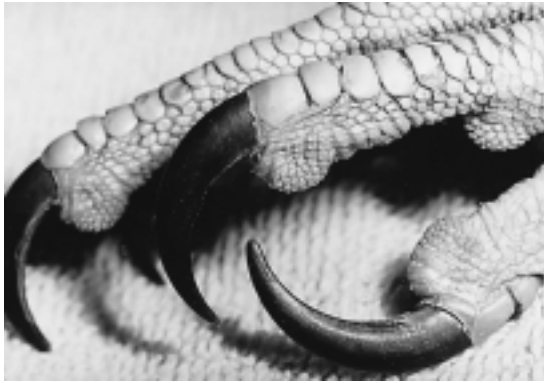Another important area of morphological specialization of raptors is their feet. These specializations include thick scales to protect them from injury, and strong toes that terminate in curved talons (Figure 8.4).

Again, distinct differences occur among the various groups of raptors. The falcons (e.g. peregrine falcon) and accipiters (e.g. sharp-shinned hawk, Cooper's hawk), whose diets consist largely of light, agile prey, have long slender toes and a longer tarsus (Figure 8.4a,b) than the buteos (e.g. red-tailed hawks, broad-winged hawks), which have thick strong toes enabling them to handle difficult quarry (Figure 8.4c). Ospreys have specialized pads with little spines called spicules on the ventral surface of the foot,

which enable them to grab and hold onto slippery fish (Figure 8.4d). Ospreys also have the ability to swivel their fourth digit to the rear, making them semi-zygodactylous, which gives them more dexterity in handling heavy or awkward prey items. Owls are also semi-zygodactylous, while all of the other Falconiformes are syndactylous, and most have feathers extending to the ends of their digits (Figure 8.4e). Ospreys have round talons (Figure 8.4d), but the talons of all other raptors are either flat or slightly concave along the ventral surface. The medial side of the talon of the third digit has a specialized sharp edge that is used for feather grooming (Figure 8.5). This structure should be preserved during any talon trimming and reshaping procedure.

Clinically, there are four aspects of talons that require attention:

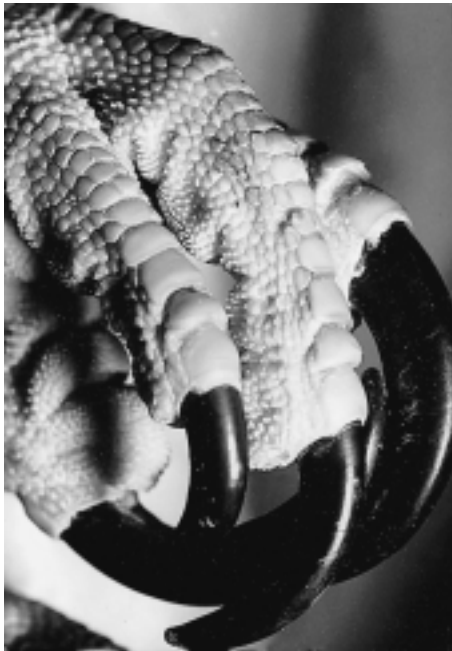- 1 Captively-held birds should have the ends of the talons blunted to prevent self-inflicted injury. Conversely, birds about to be released to the wild should have their talons sharpened.
- 2 Talons need to be kept trimmed to a proper length. There is no exact landmark that can be used to determine length, but a sense of this is gained by experience. Trimming them too short will cause profuse bleeding,



(a)



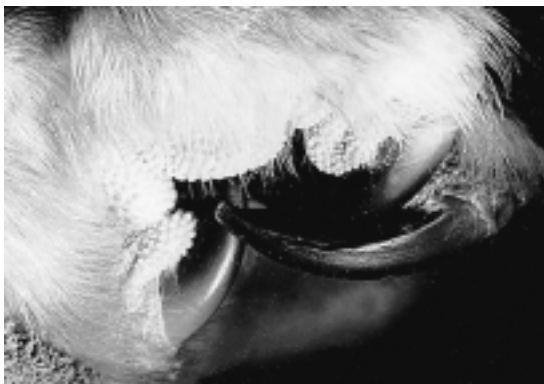(b)



(c)

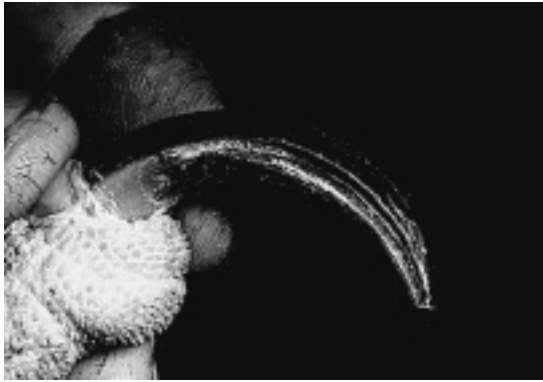


(d)



(e)

**Figure 8.4** The strongly curved grasping talons of a raptor explain their group name – ‘*rapere*’ is Latin for ‘to grasp’. Bird-eating raptors (falcons, accipiters) have long, slender toes and delicate talons (a, b), while buteos (red-tailed hawk) have stout talons and heavy scales (c). Ospreys have round talons and pronounced spicules on the plantar epithelium (d), and owls have feathering to the ends of the digits (e). (Photos by G. Buhl.)



**Figure 8.5** The protruding sharp edge on the medial side of the talon of the third digit is apparently a tool for grooming feathers of the head and neck, and should be left intact during any trimming operations. (Photo by G. Buhl.)

and excessive length predisposes to self-inflicted foot injuries.

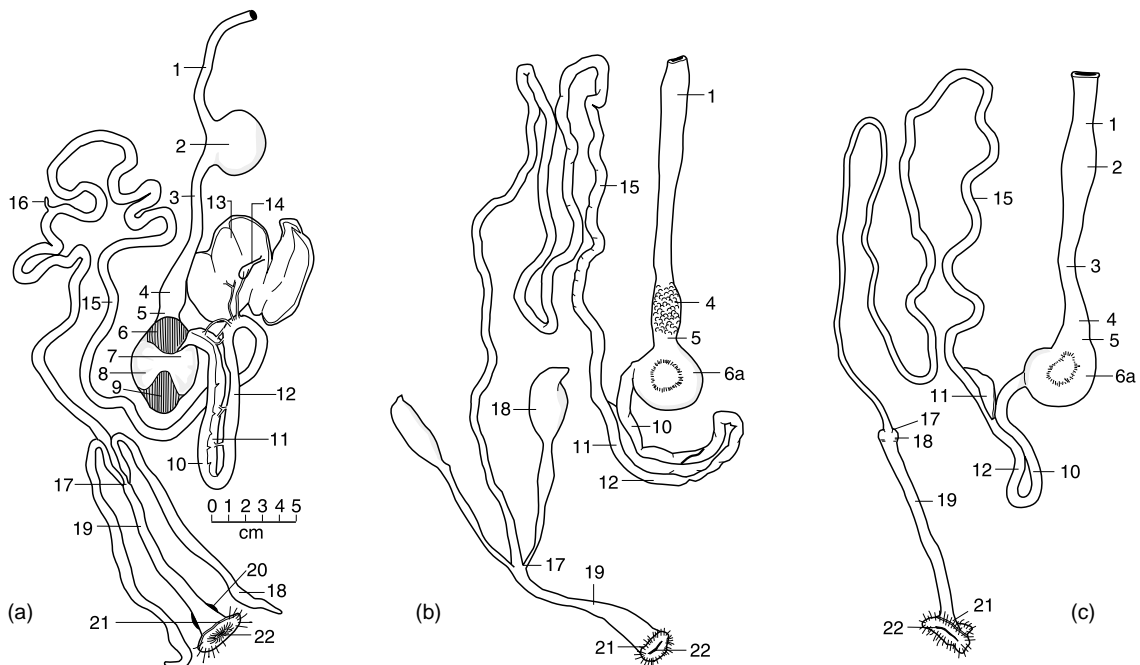
- 3 The groove on the ventral (or back) side of the talons needs to be kept free of debris,

especially at the junction with the end of the toe. Failure to do this leads to pressure necrosis and infection of the distal toe.

- 4 Talons are sometimes accidentally pulled off, exposing the white, curved bone of the distal phalanx. Treatment of this is accomplished acutely by controlling bleeding and wrapping the foot in a ball bandage for protection for about 10 days. Regrowth of a talon will take up to 6 months.

**Gastrointestinal tract**

There are also differences in the gastrointestinal (GI) tract anatomy of raptors (Duke, 1986). Owls do not have crops, whereas most raptors do (Figure 8.6). The crop is used for the storage of food. The stomach of all raptors is essentially a simple glandular stomach. The pH of the stomach during digestion is approximately 1 in diurnal raptors, while owls have a pH of about 3. The former are capable of completely digesting bones, while the latter do not. The undigested bone is incorporated



**Figure 8.6** GI tracts of (a) domestic turkey; (b) great-horned owl; (c) red-tailed hawk. Included are: (1) pre-crop oesophagus; (2) crop; (3) post-crop oesophagus; (4) glandular stomach; (5) isthmus; (6) thin craniodorsal muscle; (6a) muscular stomach of raptors; (7) thick cranioventral muscle; (6 to 9) muscular stomach; (10) proximal duodenum; (11) pancreas; (12) distal duodenum; (13) liver; (14) gallbladder; (15) ileum; (16) Meckel's diverticulum; (17) ileocaecocolic junction; (18) caecum; (19) colon; (20) bursa of Fabricius; (21) cloaca; (22) vent; (Gc) greater curvature.



into the 'pellet', the mass of indigestible material that is cast from the body in the late phases of the digestive cycle prior to ingestion of another meal (Duke, 1986). In falcons and hawks the caecae are vestigial, while in the owls they are large and functional. The caecae may serve to facilitate microbial fermentation and water reabsorption (Duke, 1986).

### ***Musculoskeletal anatomy***

While anatomists will delineate significant differences in skeletal anatomy among raptors, the clinician will find variations among the elements of the appendicular skeleton to be minor. The surgical anatomy, as it relates to orthopaedic surgery, is not fundamentally different whether a kestrel or an eagle is being evaluated. Avian surgical anatomy is well described in *Avian Surgical Anatomy* (Orosz *et al.*, 1992) and *Avian Medicine and Surgery* (Altman *et al.*, 1997).

### ***Reproduction***

Owing to the demands for conservation, and to provide access to species such as peregrine falcons, gyrfalcons and goshawks (which are hard to obtain from the wild) for use in falconry, many species of raptors have been bred successfully in captivity since the early 1970s (Heidenreich, 1997). Artificial insemination techniques have permitted the development of hybrids that not only generate very interesting specimens for hunting, but also test prevailing theories of species. Hybrids among most falcon species are relatively common, including peregrine  $\times$  gyr, gyr  $\times$  merlin, and prairie or Saker  $\times$  gyr. Goshawks, red-tailed hawks and Harris' hawks (genera *accipiter*, *buteo* and *parabuteo*) have also been successfully hybridized. At a falconry meet in 1996 in the USA, a Cooper's  $\times$  Harris' was present.

Propagation of raptors can be accomplished by either natural mating of a compatible pair or artificial insemination, in which birds imprinted on humans are used. For natural mating, the most consistent results have been obtained from pairs that were raised in captivity in the chamber in they eventually breed. Breeding of birds taken from the wild after fledging is less likely to happen, although not impossible, and it will take years before individual birds

actually adapt sufficiently to the captive environment in order to reproduce. Notable exceptions to this pattern are seen among the large raptors. Bald eagles, golden eagles, Philippine eagles, harpy eagles, Californian condors and Andean condors have all bred successfully in captivity as wild-taken adults.

The greatest production of young and the most versatility and control from the point of obtaining desired matings is attained by using artificial insemination. The greatest success is typically achieved with human imprinted birds. Hand-reared from early after hatching to adulthood, such birds will voluntarily – and with great avidity – attempt to mate with a human handler. Males will copulate readily on top of a human head, which, if equipped with a special hat that has a rubber rim around the perimeter, allows collection of several microlitres of semen in a capillary tube or pipette. Females will solicit copulation and allow placement of the pipette in their cloaca. In their 'mating trance', such females will also tolerate restraint and eversion of their oviduct, which permits more accurate and effective placement of the semen (Heidenreich, 1997). Raptors do not store semen to any great extent; hence one insemination typically yields one or two fertile eggs. Most raptors lay eggs at 36–72-hour intervals, and insemination must occur within hours of the laying of an egg in order to fertilize the next one. There has been limited success with use of semen extenders and frozen semen (Parks and Hardaswick, 1987).

Raptors typically do not commence incubation until the clutch is complete, or nearly so. The numbers of eggs produced can be extended by two methods:

- 1 Waiting until a clutch is complete (two to four eggs, depending on the species) and then removing it, in which case the birds will recycle and lay another clutch in about 2 weeks, a practice known as double clutching. Two to three clutches per season may be acquired in this manner.
- 2 Removing eggs as they are laid, in which case many females will continue to lay for an extended period of time. Twelve to fifteen eggs may be obtained in this fashion.

The greatest hatchability of eggs is obtained if they are given 7–10 days of normal incubation, after which they can be placed in a

suitable incubator for the remaining 20–25 days of incubation. The range of incubation times among raptors is given in Table 8.1 (Heidenreich, 1997). Pipping of the egg usually occurs 1–2 days before hatching. Eggs must be moved from the incubator to a lower temperature, higher humidity hatcher at this time. Further detailed accounting of the procedural nuances for successful incubation and hatching are given by Weaver and Cade (1983) and Heidenreich (1997).

Once hatched, youth falcons can be hand-reared up to about 7 days of age without becoming imprinted. At this point they should be given back to parent birds to be raised to fledging age. If eggs have been hatched by natural incubation, caretakers must carefully observe parental behaviour at the time of hatching. First-time parents are

**Table 8.1** Incubation periods for various birds of prey (Heidenreich, 1997)

<i>Species</i>	<i>Incubation period (days)</i>
Bearded vulture ( <i>Gypaetus barbatus</i> )	53–58
European black vulture ( <i>Aegypius monachus</i> )	50–55
Griffon vulture ( <i>Gyps fulvus</i> )	48–54
Egyptian vulture ( <i>Neophron percnopterus</i> )	42
White-tailed sea eagle ( <i>Haliaeetus albicilla</i> )	38–40
Pallas' sea eagle ( <i>Haliaeetus leucoryplis</i> )	38
Osprey ( <i>Pandion haliaeetus</i> )	35–38
Peregrine falcon ( <i>Falco peregrinus</i> )	31–33
Gyrfalcon ( <i>Falco rusticolus</i> )	30–34
Saker falcon ( <i>Falco cherrug</i> )	31–33
Lanner falcon ( <i>Falco biarmicus</i> )	32
European hobby ( <i>Falco subbuteo</i> )	(28) 31–33
Common kestrel ( <i>Falco tinnunculus</i> )	28–30
Merlin ( <i>Falco columbarius</i> )	28–30
Eleonora's falcon ( <i>Falco eleonora</i> )	28–30
Northern goshawk ( <i>Accipiter gentilis</i> )	32–34 (39)
European sparrowhawk ( <i>Accipiter nisus</i> )	32–34
Common buzzard ( <i>Buteo buteo</i> )	31–33
Rough-legged buzzard ( <i>Buteo lagopus</i> )	31–34
Long-legged buzzard ( <i>Buteo rufinus</i> )	33–35
Golden eagle ( <i>Aquila chrysaetus</i> )	43–45
Imperial eagle ( <i>Aquila heliaca</i> )	43
Tawny or steppe eagle ( <i>Aquila rapax</i> )	35
Lesser spotted eagle ( <i>Aquila pomarina</i> )	38–41
Greater spotted eagle ( <i>Aquila clanga</i> )	42–44
Bonelli's eagle ( <i>Hieraetus fasciatus</i> )	37–39
Booted eagle ( <i>Hieraetus penatus</i> )	35–38
Red and black kites ( <i>Milvus milvus</i> and <i>Milvus migrans</i> )	30–32
Marsh harrier ( <i>Circus aeruginosus</i> )	33–35
Montagu's harrier ( <i>Circus pygargus</i> )	28–30

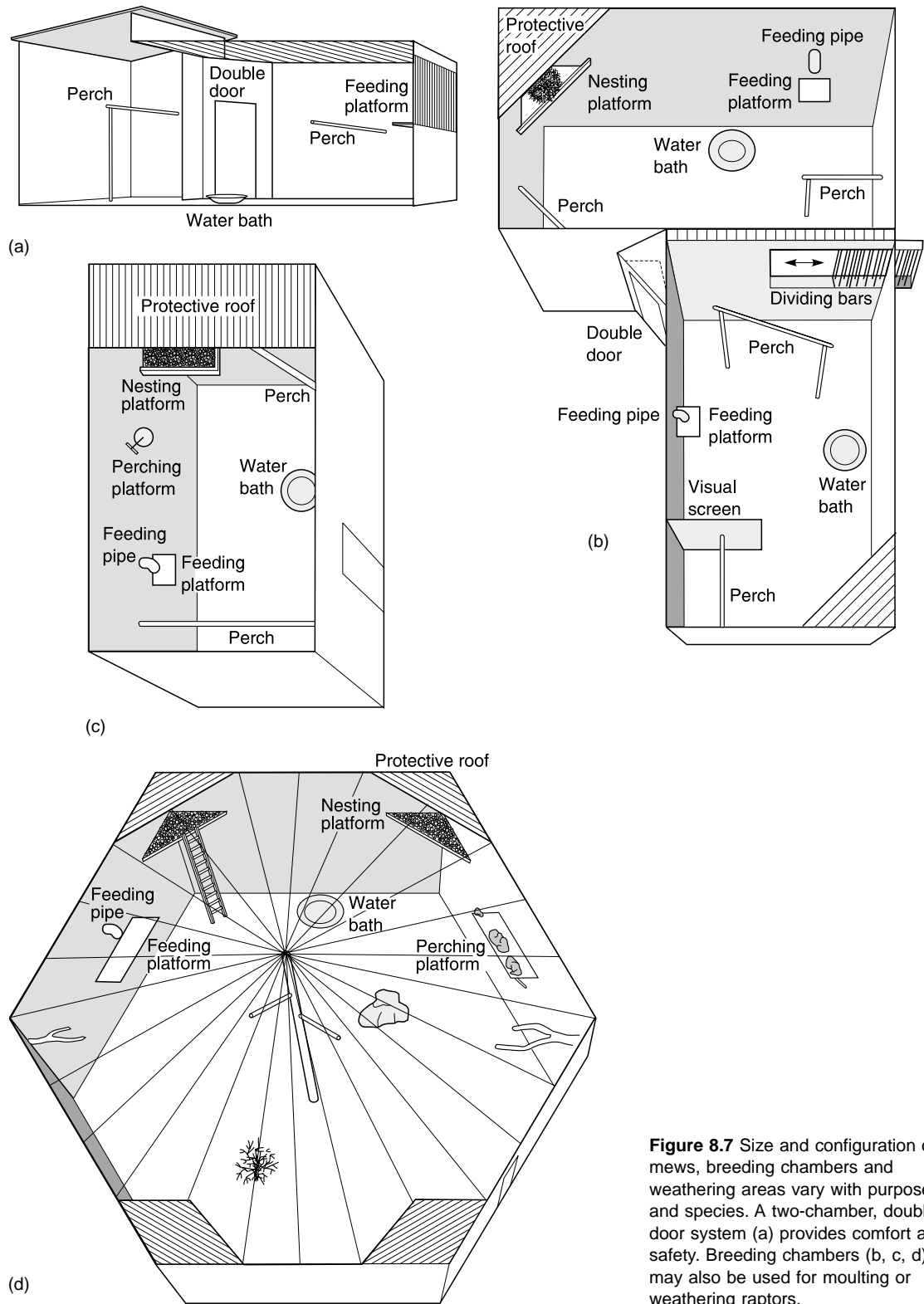
notorious, both in captivity and in the wild, for not caring for their young properly. At the time of hatching, the umbilical cord should be swabbed with iodine and the young raptor placed in a small confining container where it can be provided with supplemental heat. Feeding does not typically occur until 12 hours after hatching, during which time the remaining yolk sac is utilized. Newly hatched raptors are fed the normal food items (e.g. quail, mice, rats) ground to a coarse paste and moistened with a small amount of saline solution. This mixture is squeezed out of a hole in the bottom of a plastic bag and into the mouth of the young bird. Some breeders (Heidenreich, 1997) believe that only coarse-cut pieces of freshly killed prey should be fed; however, this theory is countered by the experience of others (Weaver and Cade, 1983). Vocalizations by the human handler, mimicking the feeding calls of the adults, will stimulate food begging by the young bird. As with other aspects of reproduction, species-specific information is available about feeding and should be consulted for further details (Heidenreich, 1997).

## Management

### Housing

Housing and feeding practices for raptors vary widely depending on the species and the purposes for which they are kept. In general, both indoor and outdoor facilities should be provided. Protection from direct sunlight is mandatory, but birds may be allowed to choose their own level of exposure to inclement weather. Many birds prefer limited exposure to rain and snow; however, protection from wind, especially in very cold weather, is essential.

Indoor facilities for raptors are referred to as a mews. This is the term for the facility used by falconers to house their birds during the moulting season, the mews is also used simply as a place to protect birds from inclement weather. Some keepers move birds into the mews each night and out to the weathering yard in the day. The minimum height usually depends upon the caretaker's size and ability to walk in and handle the bird. Other dimensions and the shape vary



**Figure 8.7** Size and configuration of mews, breeding chambers and weathering areas vary with purpose and species. A two-chamber, double-door system (a) provides comfort and safety. Breeding chambers (b, c, d) may also be used for moulting or weathering raptors.

tremendously depending on the species, and readers should confer with current keepers or consult other references (Beebe and Webster, 1994; Arent and Martell, 1996; Heidenreich, 1997). Examples of building configurations meeting the requirements for suitable housing of raptors are given in Figure 8.7 and Table 8.2. Many states in the USA have regulations affecting house design. The mews should have at least one window obstructed by vertical dowels made of wood or metal (e.g. electrical conduit), and wall surfaces and flooring that are easily cleaned.

Materials used for the construction of facilities vary according to availability and preference. Pressure-treated wood is to be avoided, as the preservatives are known to be toxic. Wooden or metal dowels (e.g. electrical conduit), manufactured wood panels, cement and cinder block are typical materials used for construction of raptor facilities. Inside, walls should be smooth to facilitate cleaning and reduce wear. The flooring should be easily cleaned, and non-organic materials (such as pea gravel) bedded to a level of 6–8 cm provides the optimal substrate.

Perches in the mews must be carefully considered with regard to size, shape, covering materials and placement, both for comfort and to maintain foot health. Falcons require broad, flat perches, usually covered with artificial

turf, whereas buteos and goshawks are maintained on perches that are elliptical in cross-section, sized proportionately to their feet and wrapped with sisal rope (Arent and Martell, 1996). Care must be taken to ensure that there are no sharp edges present where the bird may puncture its foot. Perches should be positioned well off the floor so the handler can approach the bird at chest level. Proximity to the barred window is desirable in most cases. Multiple perches within the mews are not required, and can in fact be detrimental to foot health – when moving about in small areas birds hop rather than fly, thus subjecting their feet to bruising from harder landing loads.

Outdoor pens, usually referred to as weathering areas, are also required. Minimum dimensions of a pen for a typical raptor of approximately 1 kg housed singly are 2 m × 3 m × 2.5 m high (Heidenreich, 1997). Configuration and size vary greatly, and advice should be taken from experienced individuals and appropriate references for specifics concerning the species that are being kept (Arnet and Martell, 1996; Heidenreich, 1997). Falconry birds and those trained for handling and demonstration flights should be tethered in most instances. Where housing for multiple birds is provided, it is desirable for such birds to be separated by partitions within the facility. If separation is not practised,

**Table 8.2(a)** Categories of minimum size requirements for raptor enclosures (given per animal; young birds are not included until they gain independence) (Heidenreich, 1997)

A. Aviary: outdoor area 2 m <sup>2</sup> , width 1 m, height 2 m. Each additional animal: 1 m <sup>2</sup> added to outdoor area, and 1 m <sup>2</sup> shelter area. If kept exclusively in heated indoor chamber: area 2 m <sup>2</sup> , height 1 m, each additional animal 1 m <sup>2</sup> more.	F. Aviary: outdoor area 24 m <sup>2</sup> , width 3 m, height 3 m. Each additional animal: 10 m <sup>2</sup> added to outdoor area, and shelter, if necessary: 4 m <sup>2</sup> , height 2 m, width 2 m.
B. Aviary: outdoor area 5 m <sup>2</sup> , width 2 m, height 2 m. Each additional animal 1 m <sup>2</sup> added to outdoor area, and shelter, if necessary: 1.5 m <sup>2</sup> , height 2 m, width 1 m.	G. Outdoor aviary for a pair of birds at least 100 m <sup>2</sup> .
C. Aviary: outdoor area 7.5 m <sup>2</sup> , width 2 m, height 2.5 m. Each additional animal: 3 m <sup>2</sup> added to outdoor area, and shelter, if necessary: 2 m <sup>2</sup> , height 2 m, width 1 m.	<b>Categories of temperature requirements</b>
D. Aviary: outdoor area 12 m <sup>2</sup> , width 2 m, height 2.5 m. Each additional animal: 6 m <sup>2</sup> added to outdoor area, and shelter, if necessary: 4 m <sup>2</sup> , height 2 m, width 2 m.	I. Hardy in winter, requires only protection from rain and wind.
E. Aviary: outdoor area 18 m <sup>2</sup> , width 3 m, height 2.5 m. Each additional animal: 6 m <sup>2</sup> added to outdoor area, and shelter, if necessary: 4 m <sup>2</sup> , height 2 m, width 2 m.	II. Sensitive to very cold temperatures, requires an unheated enclosure or chamber.
	III. Sensitive to moderately cold temperatures, requires indoor room protected from frost and draughts.
	IV. Not tolerant of cold temperatures, requires heated indoor chamber kept at temperatures above +15°C.

**Table 8.2(b)** Categories of minimum size requirements for many species of raptors along with temperature tolerances (Heidenreich, 1997)

Family	Species	Category of aviary size requirement	Category of temperature requirement
New World Vultures <i>Cathartidae</i>	Black vulture <i>Cathartes atratus</i>	D	III
	Turkey vulture <i>Cathartes aura</i>	D	IV
	King vulture <i>Sarcoramphus papa</i>	D	IV (very sensitive to frost)
	Andean condor <i>Vultur gryphus</i>	F	I
Osprey <i>Pandionidae</i>	Osprey <i>Pandion haliaetus</i>	D	II
Secretary Birds <i>Sagittariidae</i>	Secretary bird <i>Sagittarius serpentarius</i>	G because they are ground birds, can also be maintained with unilaterally trimmed flight feathers	
Hawks <i>Accipitridae</i> <i>G. Elanus</i>	Black-shouldered kite <i>Elanus caeruleus</i>	C	IV
<i>G. Milvus</i>	Black kite <i>Milvus migrans</i>	D	I-II Consider origin*
	Red kite <i>Milvus milvus</i>	D	I
	Brahminy kite <i>Haliaeetus indus</i>	D	IV
<i>G. Ichthyophaga</i>	Gray-headed fishing eagle <i>Ichthyophaga ichtyaetus</i>	D	IV
<i>G. Haliaeetus</i>	White-tailed sea eagle <i>Haliaeetus albicilla</i>	F	I
	Bald eagle <i>Haliaeetus leucocephalus</i>	F	I
	White-bellied sea eagle <i>Haliaeetus leucogaster</i>	D	I
	Pallas' sea eagle <i>Haliaeetus leucoryphus</i>	D	I
	Steller's sea eagle <i>Haliaeetus pelagicus</i>	F	I
	African fish eagle <i>Haliaeetus vocifer</i>	D	IV
<i>G. Gypaetus</i>	Bearded vulture <i>Gypaetus barbatus</i>	F	I
<i>G. Aegyptius</i>	European black vulture <i>Aegyptius monachus</i>	F	I
<i>G. Gypohierax</i>	Palm nut vulture <i>Gypohierax angolensis</i>	D	IV
<i>G. Neophron</i>	Egyptian vulture <i>Neophron percnopterus</i>	D	II-III Consider origin*
<i>G. Necrosyrtes</i>	Hooded vulture <i>Necrosyrtes monachus</i>	D	IV
<i>G. Sarcogyps</i>	Indian black (King) vulture <i>Sarcogyps calvus</i>	F	IV
<i>G. Torgos</i>	Lappet-faced vulture <i>Torgos tracheliotus</i>	F	IV
<i>G. Trionocephs</i>	White-headed vulture <i>Trionocephs occipitalis</i>	F	III
<i>G. Gyps</i>	Griffon vulture <i>Gyps fulvus</i>	F	I
	Himalayan griffon <i>Gyps himalayensis</i>	F	I
	Rüppell's griffon <i>Gyps rueppellii</i>	F	III
<i>G. Pseudogyps</i>	Indian white-backed vulture <i>Pseudogyps bengalensis</i>	D	
	African white-backed vulture <i>Pseudogyps africanus</i>	D	III
<i>G. Circaetus</i>	Brown harrier (snake) eagle <i>Circaetus cinereus</i>	D	IV
	Short-toed (serpent) eagle <i>Circaetus gallicus</i>	D	IV
<i>G. Teraathopius</i>	Bateleur eagle <i>Therathopius ecaudatus</i>	D	IV
<i>G. Spilornis</i>	Crested serpent eagle <i>Spilornis cheela</i>	D	IV
<i>G. Circus</i>	Marsh harrier <i>Circus aeruginosus</i>	D	II
	Hen harrier <i>Circus cyaneus</i>	D	I
<i>G. Melierax</i>	Pale chanting goshawk <i>Melierax canorus</i>	D	IV
<i>G. Polyboroides</i>	African harrier hawk <i>Polyboroides typus</i>	D	IV
<i>G. Accipiter</i>	Northern goshawk <i>Accipiter gentilis</i>	D	I
	European sparrowhawk <i>Accipiter nisus</i>	C	I
<i>G. Kaupifalco</i>	Lizard buzzard <i>Kaupifalco monogrammicus</i>	C	IV

Table 8.2(b) Continued

Family	Species	Category of aviary size requirement	Category of temperature requirement
Hawk (cont.)			
<i>G. Geranoaetus</i>	Grey eagle-buzzard <i>Geranoaetus melanoleucus</i>	D	II
<i>G. Buteo</i>	Common buzzard <i>Buteo buteo</i>	C**	I
	Red-tailed hawk <i>Buteo jamaicensis</i>	C**	I–II Consider origin*
	Rough-legged buzzard <i>Buteo lagopus</i>	D	I
	Red-backed buzzard <i>Buteo polyosoma</i>	D	II
	Ferruginous hawk <i>Buteo regalis</i>	D	I
	Jackal (Augur) buzzard <i>Buteo rufofunus</i>	D	III
	Long-legged buzzard <i>Buteo rufofuscus</i>	D	I
<i>G. Pernis</i>	Honey buzzard <i>Pernis apivorus</i>	C**	III
<i>G. Harpis</i>	Harpy eagle <i>Harpia haryija</i>	F	III
<i>G. Morphnus</i>	Guiana crested eagle <i>Morphnus guianensis</i>	F	III
<i>G. Pithecopaga</i>	Philippine monkey-eating eagle <i>Pithecopaga jefferyi</i>	F	IV
<i>G. Polemaetus</i>	Martial eagle <i>Poledmaetus bellicosus</i>	F	III
<i>G. Stephanoaetus</i>	Crowned eagle <i>Stephanoaetus coronatus</i>	F	IV
<i>G. Lophaetus</i>	Long-crested eagle <i>Lophaetus occipitalis</i>	D	IV
<i>G. Hieraetus</i>	Bonelli's eagle <i>Hieraetus fasciatus</i>	D	I–II Consider origin*
<i>G. Spizaetus</i>	Ornate hawk eagle <i>Spizaetus ornatus</i>	D	IV
<i>G. Aquila</i>	Wedge-tailed eagle <i>Aquila audax</i>	F	I
	Greater spotted eagle <i>Aquila clanga</i>	D	II
	Golden eagle <i>Aquila chrysaetos</i>	F	I
	Imperial eagle <i>Aquila heliacea</i>	F	I
	Lesser spotted eagle <i>Aquila pomarina</i>	D	II
	Tawny (Steppe) eagle <i>Aquila rapax</i>	E	I–II Consider origin*
	Verreaux's (Black) eagle <i>Aquila verreauxii</i>	F	III
Falcons			
<i>Falconidae</i>	Chimango <i>Milvago chiachima</i>	C	III
<i>G. Milvago</i>	Yellow-headed caracara <i>Milvago chiachima</i>	C	III
<i>G. Phalcoboenus</i>	Forster's caracara <i>Phalcoboenus australis</i>	D	I
	Mountain caracara <i>Phalcoboenus megalopterus</i>	D	II
<i>G. Polyborus</i>	Common caracara <i>Polyborus plancus</i>	D	II
<i>G. Polhierax</i>	African pygmy falcon <i>Polyhierax semitorquatus</i>	B	IV
<i>G. Microhierax</i>	Red-legged falconet <i>Microhierax caerulescens</i>	A	IV
<i>G. Falco</i>	Lanner falcon <i>Falco biarmicus</i>	D	I–II Consider origin*
	Saker falcon <i>Falco cherrug</i>	D	I–III Consider origin*
	Merlin <i>Falco columbarius</i>	C	I
	Eleonora's falcon <i>Falco eleonorae</i>	D	III
	Laggar falcon <i>Falco jugger</i>	D	II
	Prairie falcon <i>Falco mexicanus</i>	D	I
	Peregrine falcon <i>Falco peregrinus</i>	D	I
	Gyr falcon <i>Falco rusticolus</i>	D	I
	American kestrel <i>Falco sparverius</i>	B	II–III Consider origin*
	European hobby <i>Falco subbuteo</i>	C**	III
	Common kestrel <i>Falco tinnunculus</i>	B	I
	Red-footed falcon <i>Falco vespertinus</i>	B	III

\*Consider origin: Temperature requirements will vary with regional geographic origin. Other categories may be more appropriate.

\*\*Individually-housed birds require the same space as pairs do, 10.5 m<sup>2</sup>.

**Table 8.3** Raptor species that can be safely housed together (Heidenreich, 1997)

Species	American kestrel	Bald eagle	Barn owl	Barred owl	Broad-winged hawk	Burrowing owl	Cooper's hawk	Golden eagle	Great horned owl	Northern goshawk	Peregrine falcon	Prairie falcon	Long-eared owl	Red-tailed hawk	Rough-legged hawk	Saw-whet owl	Screech owl	Sharp-shinned hawk	Short-eared owl	Swainson's hawk	Turkey vulture	
American kestrel	S					X																
Bald eagle		X						X														X
Barn owl			X																			
Barred owl				X																		
Broad-winged hawk					X									X						X		
Burrowing owl	X					X																
Cooper's hawk							S															
Golden eagle		X						X														X
Great horned owl									X						X	X						X
Northern goshawk										S												
Peregrine falcon											X	X										
Prairie falcon											X	X										
Long-eared owl					X								X									
Red-tailed hawk									X					X	X						X	X
Rough-legged hawk									X					X	X						X	X
Saw-whet owl																X						
Screech owl																	X					
Sharp-shinned hawk																		S				
Short-eared owl					X								X							X		
Swainson's hawk														X	X						X	X
Turkey vulture		X						X	X					X	X						X	X

S = Same sex only.

extreme diligence is required to maintain equipment in top condition so that a bird cannot break loose and attack one of the others. Convalescing birds undergoing rehabilitation are not tethered, and may be housed in groups of compatible individuals so long as sufficient food is available to keep all of them satiated (Table 8.3) (Arent and Martell, 1996). Certain species, e.g. accipiters, cannot be housed with other species, and the sexes should also be kept apart. Similarly, with kestrels and merlins the sexes should not be housed together. Great horned owls (*Bubo virginianus*) may be housed with similar-sized buteos such as red-tailed hawks (*Buteo jamaicensis*), Swainson's hawks (*Buteo swainsoni*) and ferruginous hawks (*Buteo regalis*), but not with other species.

Shade is important for all birds, especially gyrfalcons, snowy owls and other birds sensitive to the heat. Conversely, some species, such as the Harris' hawks (*Parabuteo unicinctus*), Northern harriers, small buteos and ospreys, cannot tolerate the cold and must

have supplemental heat when the ambient temperature drops below 0°C (Figure 8.7). Harris' hawks, which are desert natives, require modest exposure to strong sunlight. Temperature tolerance guidelines are given in Table 8.2 (Heidenreich, 1997).

Water must be available at all times for drinking and bathing, but care must be taken that a tethered bird cannot get tangled and drown in a deep water pan. The water must be changed daily in the summer to prevent algae growth, and protected from freezing in the winter.

### Feeding

Raptors are carnivores, and an appropriate diet is critical to their health and wellbeing. In nestling-stage raptors, all-meat diets with no bones cause nutritional secondary hyperparathyroidism (metabolic bone disease; Fowler, 1986). This presents as poor growth and progressive rapid demineralization of the bones, with multiple fractures and/or

pathological folding of the long bones. From immediately after hatching, raptors need a diet consisting of the whole bodies of typical prey species. Domestic quail, mice, and other small birds and rodents are appropriate. A commercial diet is available (Bird of Prey Diet®, Spectrum Inc., PO Box 721, North Platte, NE 69103-0721), and this is a good short-term source of nutrition; however, it should not be the only source of food, and a natural diet is always preferred. Falcons prefer quail and chicken, ospreys require fish, bald eagles receive a mixture of fish, rodents, rabbits and poultry, and most buteos and owls prefer rodents. If frozen fish is to be used for food for bald eagles and ospreys, thiamine needs to be supplemented at 1–3 mg/kg per week. For more specific information, the reader is referred to Beebe and Webster (1994) and Arent and Martell (1996). As a general rule of thumb, the smaller raptors eat approximately 20 per cent, the medium-sized birds approximately 10–15 per cent and the larger birds 6–8 per cent of their body weight daily. Regular weighing of birds is an effective means of ensuring adequate dietary intake (Arent and Martell, 1996).

Adequate water intake is essential to good health and for wild birds maintained in captivity. Raptor patients are not guaranteed to drink water provided *ad lib* and they do not obtain adequate amounts of water from the food they ingest, particularly if it is frozen and thawed; the so-called ‘metabolic water’ does not make up the difference. Therefore, to avoid dehydration, food items should be soaked in water for a few minutes prior to feeding. Certain parts of the diet are indigestible, such as fur, feathers and scales, and all raptors have an efficient means of eliminating this material. This unique process of elimination is called ‘casting’, and the products are ‘pellets’ (Duke, 1986). These indigestible materials are compacted into a tight bundle by the ventriculus and egested, usually daily, or more often in smaller raptors.

### **Clinical aspects of raptors – infectious and non-infectious diseases**

There are many diseases, especially those of bacterial origin, which raptors share in com-

mon with other avian species. These are covered in other sections of this book. This chapter will focus on diseases that are unique to or commonly found in raptors.

### **Endoparasitic diseases of raptors**

There are numerous endoparasites in birds of prey (Table 8.4; Greiner, 1997). The most commonly encountered endoparasitic diseases among raptors are protozoan infections caused either by coccidia or trichomonads, fluke and roundworm infestation of the GI tract, and two types of nematodes found in the respiratory tract. Most are capable of causing or contributing to a debilitated state; hence detection and treatment is recommended.

*Syngamus trachea* and *Cyathostoma* spp. are common upper respiratory parasites, although the latter can also be found in air sacs. Their life cycle is either direct, or via paratenic hosts such as earthworms, snails and other invertebrates. Raptors that eat these paratenic hosts, such as the snail kite, kestrels and small owls, are more likely to be infected than other species of raptors (Hunter *et al.*, 1993). After ingestion, the larvae pass from the GI tract to the respiratory system via the blood stream. The eggs move into the trachea and oropharynx, where they are swallowed, and pass through the GI tract to be shed with the faeces.

*Serratospiculum* spp. (e.g. *S. amaculata*) are filarid worms found in the air sacs of some falcon species. *S. amaculata* may be endemic in North American prairie falcons (*Falco mexicanus*) and Asian saker falcons (*Falco cherrug*). The host range for this species is described by Smith (1993) and Cooper (1985), and other species affected include peregrine falcons (*Falco peregrinus*), Cooper’s hawks (*Accipiter cooperi*) and goshawks (*Accipiter gentilis*). Diagnosis is typically made following an incidental finding of eggs on routine faecal flotation (Smith, 1993), providing a photographic appearance of the characteristic lemon-shaped embryonated eggs passed by these worms, rather than a result of a search for aetiology of medical problems with vague signs. Poor performance or unthriftiness in a falcon could indicate a worm as part of a differential diagnosis. The mode of transmission, the intermediate hosts and other aspects of the biology of this parasite are unknown. It



**Table 8.4** Endoparasitic diseases (after Cooper, 1985)

<i>Parasite</i>	<i>Location</i>	<i>Detection</i>	<i>Treatment</i> (after Carpenter <i>et al.</i> , 1996)
<b>Nematodes</b>			
Capillaria	Oral, GI, caecae	Faecal exam, oral scraping	Ivermectin (0.2 mg/kg one dose)
Ascarids	Intestines	Faecal exam	Ivermectin (see above)
Spirurids	Intestines	Faecal exam	Ivermectin (see above)
Porrocaecum	Stomach	Faecal exam	Ivermectin (see above)
Contracecaecum	Stomach	Faecal exam	Ivermectin (see above)
<i>Syngamus</i> spp.	Trachea, bronchi	Faecal exam, tracheal wash	Ivermectin (see above)
<i>Cyathostoma</i> spp.	Air sacs	Faecal exam	Ivermectin (see above)
<i>Serratospiculum</i> spp.	Air sacs	Faecal exam	Ivermectin (see above)
Cestodes	Intestines	Motile segments in faeces	Praziquantel (30 mg/kg) repeat in 10 days
Trematodes	Intestines, bile ducts, pancreatic ducts	Faecal exam	Praziquantel (see above)
<b>Protozoans</b>			
Trichomonads	Oral, intestines	Oral scrapings	Metronidazole 50 mg/kg b.i.d. for 5–7 days Carnidazole 20 mg/kg – one dose
Coccidia	Intestines	Faecal exam	Albon (55 mg/kg day 1, then 25 mg s.i.d. for 10 days) Clazuril 10 mg/kg s.i.d. for 3 days, repeat 1–2x with 2 days off (Tully, 1997) Toltrazuril 0.25 cm <sup>3</sup> /kg p.o., two doses 24 hours apart
Sarcocystis	Skeletal muscle		None
Frankelia	Intestines		None
Toxoplasma			None
<b>Hematozoa</b>			
Leucocytozoon	Peripheral blood	Blood smear	None
Haemoproteus	Erythrocytes	Blood smear	Chloroquine (10 mg/kg) plus primaquine (0.75 mg/kg). Questionable efficacy
Plasmodium	Erythrocytes	Blood smear	Chloroquine/primaquine (see above for dosage), dose at t <sub>0,12,24,48</sub> hours, primaquine first dose only. Combination also used as a once weekly prophylactic during mosquito season for gyrfalcons and their hybrids Mefloquine (alternative treatment/prophylactic – better acceptance than C/P, but utilized sufficiently to know efficacy)

is easily eliminated with ivermectin (Ivomec® ivermectin, MSD AGVET Division of Merck and Co., Inc. Rahway, New Jersey) or fenbendazole (Panacur® fenbendazole, Hoechst-Roussel Pharmaceuticals, Inc. Somerville, New Jersey); however, advisability of treatment is controversial. Some experts fear that a mass of dead worms in the air sacs may lead to a necrotizing nidus of infection there (Cooper, 1985); however, based on the numbers of worms typically found, this concern may be unfounded (Redig, unpublished). The

most common parasites of clinical significance are *Trichomonas gallinae* or *T. columbarum*, the causative organisms of 'frounce'; (Pokras *et al.*, 1993). The organism is found in nearly all wild pigeons but seldom causes disease in them, and the disease is frequently seen in captive falcons that have fed upon a warm, freshly killed pigeon. It is also seen in wild birds that feed on pigeons, most frequently in goshawks, barred owls, and great horned owls, especially in late spring when the low availability of normal prey has them resorting to

alternative sources such as pigeons. Interestingly, wild peregrine falcons appear to develop a resistance, as the disease seldom occurs in them despite regular taking of feral pigeons.

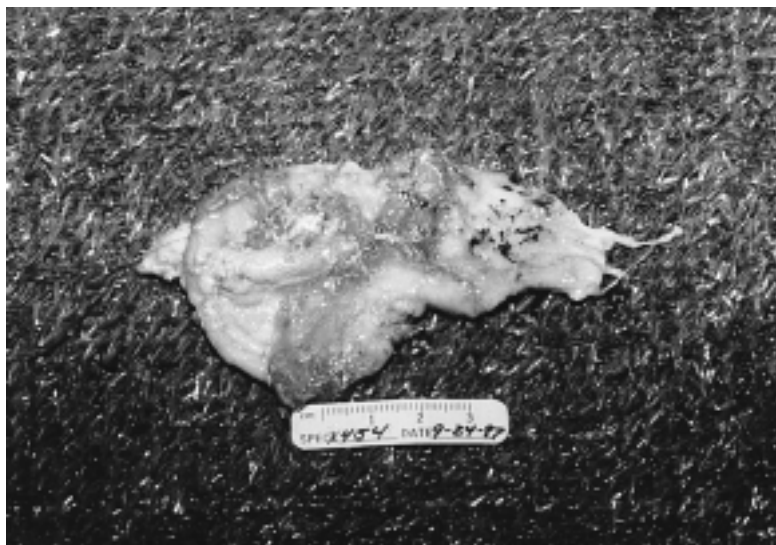Clinical signs of frounce are yellow caseous plaques on the tongue and pharyngeal surfaces. Affected birds have difficulty swallowing, often flicking away bites of meat. Ultimately they are unable to swallow, and starvation ensues. Diagnosis is confirmed by recovering the protozoan organisms with a swab or scraping. The organism is very sensitive to treatment with metronidazole (Sparatrix® carnidazole, Wildlife Pharmaceuticals Inc., Connecticut); a single dose of 30–50 mg/kg for 1–5 days (depending on severity) is usually effective. Carnidazole at 30 mg/kg given once daily for 1–3 days is an effective alternative (Forbes, 1996). Where invasion of the palate and development of large caseous lesions has occurred, treatment is ineffective.

Among nematodes, *Capillaria* spp. (e.g. *C. contorta*) are the most frequently encountered and are likely to be a source of pathology. They can occur anywhere in the GI tract, and morbidity and mortality have been associated with capillaria in the oral cavity, where they cause a lesion resembling that of trichomoniasis (Boydell and Forbes, 1996). Their bipolar

ova are readily recognized in a faecal flotation (Smith, 1993). Stomach worms of the genera *Porroecum* and *Contracecum* are frequently encountered by faecal examination. Pathology and clinical signs are rare; however, verminous granulomatous inflammation of the ventriculus of undetermined aetiology, possibly due to such nematodes, has been encountered (Redig, unpublished; Figure 8.8). The affected owls (two cases in great owls) exhibited anorexia, vomiting and severe weight loss.

Other roundworms (e.g. *Acanthocephalans*) and tapeworms rarely cause clinical problems. Finding their eggs or motile segments in faeces will prompt treatment. The former are easily eliminated by periodic treatments with either fenbendazole, mebendazole or ivermectin, while praziquantel (Droncit® praziquantel, Bayer Corporation, Animal Health, Shawnee Mission, Kansas) effectively eliminates the latter (Cooper, 1985; Smith, 1993).

Trematodes are the second most prevalent parasite detected by faecal examinations. There are many species, indistinguishable by their large, operculated eggs, but known to inhabit the intestine, bile, and pancreatic ducts (Cooper, 1985). While pathology is not a constant feature of their presence, fatal syndromes and poor condition have been reported in several raptor species. One case of intestinal intussusception and prolapse was



**Figure 8.8** The granulomatous lesions on the mucosal surface of the ventriculus were associated with an unidentified nematode. (Photo by P. T. Redig.)

encountered in an American kestrel (*Falco sparverius*) with a heavy fluke (dicrocoelid type) infestation. Trematodes are eliminated by dosing with praziquantel.

*Coccidia* spp. are a frequent cause of lethargy accompanied by weight loss, anorexia and passage of abnormal stools, varying from green, stringy masses to bloody pools of faeces (Heidenreich, 1997). Eimeriad types and *Caryospora* spp. (e.g. *C. neofalconis*; Forbes and Simpson, 1997) are most common. The latter are frequently found in captive-produced falcons. Other coccidian genera found in raptors include *Sarcocystis* spp. and *Frankelesia* spp. (Cawthorne, 1993). An aberrant occurrence of the former was reported to be associated with a neurological syndrome in a goshawk (Aguilar *et al.*, 1991), and Dubey *et al.* (1991) reported on a similar case in a golden eagle (*Aquila chrysaetos*). While the latter types of coccidial infections are clearly untreatable, most others occurring in the GI tract are amenable to treatment with sulfa drugs or, preferably, clazuril (Appertex® clazuril, Janssen Pharmaceutical, Titusville, New Jersey) or toltrazuril (Baycox® toltrazuril, Bayer Austria, Wien) (Forbes, 1996).

### **Ectoparasitic diseases**

A wide variety of ectoparasites, such as lice, black flies, mosquitos, ticks, and Hippoboscid and Acarin flies, are found on raptors (Heidenreich, 1997). They can be seen on physical examination of the bird. Most are commensal on raptors. With debilitation and concomitant decreased grooming by the host, their numbers can increase to cause clinical disease. Ectoparasites cause anaemia, both directly from their blood sucking and indirectly by the transmission of the blood parasites. Pyrethrin sprays (Sectrol® Plus Pyrethrin Spray, 3M Animal Care Products, St Paul, Minnesota) effectively kill these ectoparasites.

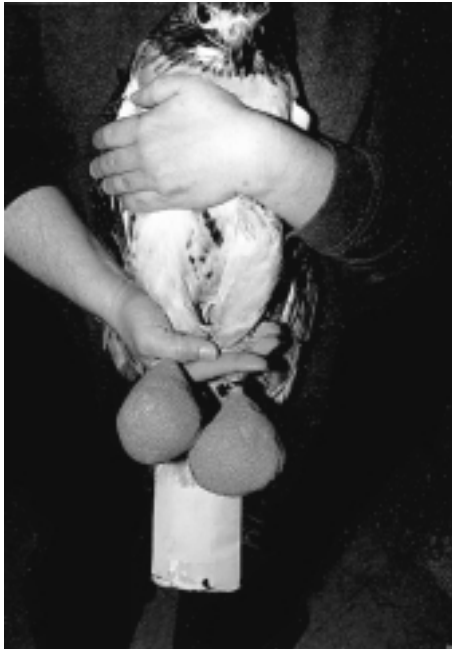Blow-fly larvae of the genus *Protocalliphora* are found with regularity in the external auditory canals of nestling raptors (Smith, 1993), especially the buteoinae hawks (e.g. red-tails, broad-wings, red-shoulders). Though the ear canal becomes soiled with dried blood and excreta from the worms, permanent damage is not done to the host. Ordinarily, these larvae leave the ear canal to pupate in the nest. When encountered among orphaned

birds submitted for rehabilitation, they can and should be mechanically removed. This is easily accomplished by placing a drop of mineral oil or saline in the ear, thereby forcing the worms to stretch to get their spiracles in open air for breathing. They can then be removed with a pair of forceps.

### **Bumblefoot**

Bumblefoot is a pododermatitis found primarily in raptors and occasionally in other birds, most notably waterfowl (Redig, 1996a). Though common in captive raptors, it is a by-product of captive management and is not an infectious disease. This condition is rare among wild birds and is typically associated with pre-existing injury to one or both feet (Ellis, 1986; Gentz, 1996). It is initiated by abnormal pressures placed on the feet by improperly shaped perches and inappropriate perching substrate, and by housing arrangements in which raptors traumatize the metatarsal pad by jumping from perch to perch. In rare instances, the condition may result from self-inflicted puncture wounds (Cooper, 1985) or bite wounds from prey or other trauma. In all cases, trauma to the bottom of the foot or toe is the inciting factor. Infection, usually with *E. coli* or *Staphylococcus* spp., is secondary. Harcourt-Brown (1996) likens the pathogenesis to that of a bedsore. This disorder is graded in five categories (Oaks, 1996), depending on the severity and prognosis; type I is a non-disrupting hyperaemic or hyperkeratotic devitalization of the plantar epithelium and carries a good prognosis, while type V is characterized by deep infection of the soft tissue and osteomyelitis and is most often treated by euthanasia.

The treatment of bumblefoot involves removal of the underlying cause(s) and management of the wound. In early type I cases, where the papillae of the plantar epithelium are flattened and there is slight reddening of the skin, application of skin tougheners (NewSkin® Liquid Bandage, Medtech Laboratories Inc., Jackson, Wyoming) along with alteration of perch size and/or covering material will suffice. In types II and III, where there is ulceration, swelling and inflammation, management consists of surgical debridement, establishing and maintaining drainage, and protective bandaging. Culture of exudate and



(a)



(b)

**Figure 8.9** Ball bandages may be applied unilaterally (a) or bilaterally (b) to provide whatever protection injured feet need. (Photos by P. T. Redig.)

determination of antibiotic sensitivity for systemic antibiotics is essential. The course of treatment typically involves surgically removing the scab, gently removing loose tags of exudate and inflammatory tissue, and irrigating the wound with sterile saline or 0.5 per cent chlorhexidine (not iodine-containing solutions). A sterile strip of gauze or umbilical tape is inserted into the wound as a seton and the foot is bandaged into a 'ball bandage' (Figure 8.9), using sterile gauze in contact with the bottom of the foot, thereby forming a wet-to-dry bandage. This bandage is changed daily, with continued irrigation, replacement of the seton and application of a ball bandage for a period of 10–20 days, depending on the initial severity. Appropriate systemic antibiotic therapy should be given for 5–7 days (cephalosporins and fluoroquinolones typically yield the best results). Signs of progress include absence of drainage and the appearance of granulation tissue in the wound. From this point, the wound should be packed with a hydroactive paste (Duoderm Hydroactive Paste®, ConvaTec, Bristol-Meyers Squibb Co., Princeton, New Jersey) and covered with a non-adherent absorbent dressing (Release® non-adhering

dressing, Johnson and Johnson Medical Inc., Arlington, Texas) held in place with adhesive tape or semipermeable membrane wound dressing material (Tegaderm®, 3M Medical-Surgical Division, St Paul, Minnesota). All of this is overwrapped with conforming bandaging material (Vetrap® bandaging tape, 3M Animal Care Products, St Paul, Minnesota) to form a ball. The ball bandage is maintained until the wound has closed by secondary intention healing, and the foot is then protected with a padded inderdigitating bandage for several weeks until the integrity of the tissue allows normal use.

#### *Prevention of bumblefoot*

Since the causes of bumblefoot are management-related and the course of treatment is complicated and protracted, prevention is extremely important. Five important elements include:

- 1 Provision of a nutritious, balanced diet suitable for the species of raptor in question.
- 2 Provision of perches that are sized, shaped and covered appropriately for the species and sex.

- 3 Provision of adequate manoeuvring space for free-lofted birds so they can land normally.
- 4 Avoidance of overweight conditions.
- 5 Provision of adequate exercise and observing the condition of the feet on a regular basis.

Problems related to improper perching surfaces can be assessed in part by wear patterns on the feet. Lesions occurring in the centre of the metatarsal pad arise from perches that are too small for that particular bird, resulting in excess amounts of pressure being applied to that portion of the foot. Conversely, lesions appearing on the toe pads are indicative of perches that are too large.

The shape of the perch varies with major raptor groups. Falcons are best kept on flat perches, such as the traditional block perch or a shelf perch. Eagles, accipiters, buteos and owls should be provided with perches that are round or elliptical in cross-section. The most suitable covering material for falcon perches is Astroturf® (Monsanto Solutia Inc., St Louis, Montana), while perches for the latter groups can be covered with Astroturf, hemp or sisal rope (Arent and Martell, 1996).

A special form of bumblefoot, seen in large, highly athletic hunting falcons, is described by Heidenreich (1997). Because it occurs when hunting hawks are idled at the end of the hunting season, it is likened to similar conditions seen in horses and human athletes. The high level of cardiovascular condition and blood volume present in such animals is not compatible with abrupt onset of inactivity, and this leads to oedema and swelling of dependent limbs. In falcons, these events can lead to bumblefoot. Prevention can be accomplished by placing the birds on a schedule of progressively decreasing exercise as the field season draws to a close.

### **Feather abnormalities**

Issues relating to the protection of feathers, repairing broken feathers by imping, and moulting have been discussed above. Pathological conditions involving feathers of raptors include the occurrence of 'stress marks', and a peculiar 'pinching-off' syndrome.

Stress marks appear as lines across one or more feathers, which occur due to an inter-

ruption in the normal flow of nutrients to that feather during its growth or to exposure to stress. In young raptors taken into captivity as mid-growth nestlings, a continuous line of stress marks across the tail feathers will often be seen; these reflect the stress of adjustment to a new environment and possibly a day or two of below-normal food intake. Injury, administration of corticosteroids, or illness during feather growth are other purported causes (Malley and Whitbread, 1996).

Pinching off of individual feathers is an occasional cause for presentation of captive raptors. Whether it occurs among wild birds is unknown. The pattern is for normal growth of a retrix or remige for one-half to two-thirds of its normal growth, after which the blood supply withdraws and the feather pinches off in a characteristic hourglass presentation. A new feather usually grows after removal of the remaining stump (by the bird or by human intervention), and this may or may not pinch off. In time the problem self-corrects, but it may require more than a couple of moult sequences to do so. Heidenreich (1997) attributes the cause to quill mites (*Harpyrhyntus* spp.), and suggests treatment with ivermectin during feather growth stages as a possible means of management.

A brisk moult can be stimulated in raptors by feeding them unadulterated thyroid gland of bovine, porcine or ovine origin. A dose of 15 g/kg per day for 3–5 days will usually initiate the moult. There is no commercially available product; rather, the raw thyroid gland is obtained from a butcher's shop. Overdosing will result in the loss of nearly all the feathers simultaneously.

### **Infectious agents**

#### *Viruses*

While herpesviruses are known to occur in a wide number of vertebrate species, and three distinct serotypes have been encountered in carious raptors, the fatal hepatosplenitis or inclusion body disease seen in falcons is the most commonly encountered. There are three sub-families of the herpesvirus, alpha, beta and gamma, which determine the biologic properties, host range, cytopathology and other characteristics of that sub-family (Wheler, 1993). Other diseases known to be

caused by herpesviruses in other birds are Marek's disease, duck viral enteritis, and Pacheco's disease in psittacines (Ritchie *et al.*, 1994). The viruses cause a fatal disease process that is characterized by a multifocal necrosis of the liver, spleen and other organs, with the formation of intranuclear inclusion bodies. The clinical course lasts from several hours to several days, with weakness, depression, anorexia, regurgitation and diarrhoea following a pre-patent period of 7–10 days. A profound leucopenia is exhibited in the 24–48 hours preceding death. Presumptive diagnosis is based on gross lesions (Heidenreich, 1997) and demonstration of intranuclear inclusion bodies. The diagnosis is confirmed by virus isolation. Natural transmission of this disease occurs via ingestion of the viral particle, usually from the consumption of infected prey – most commonly pigeons.

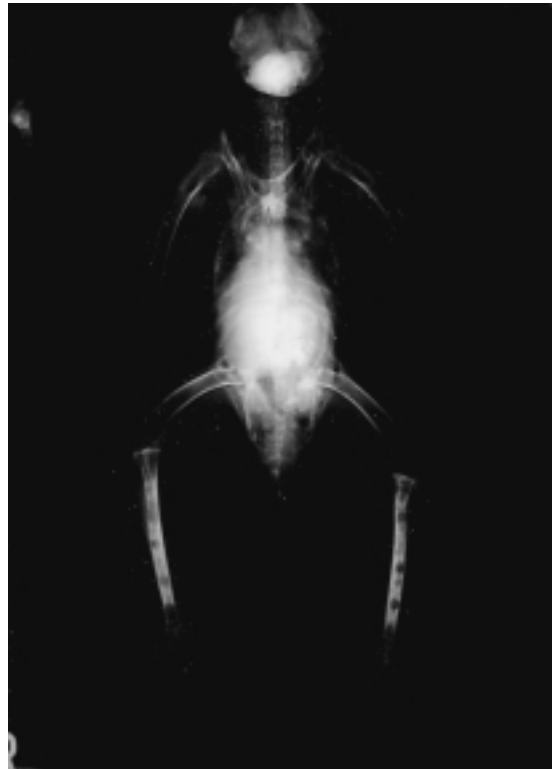Another virus that causes a disease in raptors and is characterized by sudden onset with a fatal outcome is an adenovirus (Forbes, 1997). The disease has been encountered primarily in non-native (usually tropical) falcons reared in temperate zones or fed domestic poultry. The virus may be related to the turkey haemorrhagic enteritis virus or the quail bronchitis virus. In affected falcons, clinical signs may hint at enteritis by virtue of passage of undigested meat in faeces, but most often sudden death is the only sign. Since little is known about the disease, management recommendations are difficult to prescribe. Great care must be taken in feeding domestic poultry to non-native species of falcons.

Pox is another viral disease seen in raptors (Ritchie *et al.*, 1994; Heidenreich, 1997). Usually only the dry form is seen in birds of prey, and is spread by mosquitoes. Avipox is species specific, although it may cross the species barrier to cause a less severe form of the disease in the new host (Heidenreich, 1997). Clinical signs include nodular encrustations on the cere, eyelids and feet, which progress through the papule state to vesicles, pustules and then scabs. These are prone to secondary bacterial infections. Diagnosis is made typically by histological examination of biopsies of affected epithelial tissue, which show intracytoplasmic inclusions (Bolinger bodies). Affected birds typically do not exhibit outward signs of illness unless the lesion is obstructing part of the mouth or an eye, which

may debilitate the patient. Treatment consists of surgical removal of larger lesions (cautery) and administration of antibiotics and wound treatment for control of secondary bacterial infection. The disease is self-limiting.

#### *Bacteria*

Avian tuberculosis is uncommon in raptors in North America; however, in other parts of the world it is endemic (Cooper, 1985). It is usually fatal for the affected bird, and is a potentially zoonotic disease. *Mycobacterium avium* is the causative organism, and it causes a chronic wasting disease syndrome accompanied by weakness, anorexia and diarrhoea (Boydell and Forbes, 1996). Tuberculosis occurs in the liver, intestine and bone marrow, and it is diagnosed by acid-fast staining of the faeces and bone marrow aspirate (if the bones display the pathognomonic punched out lesions; Figure 8.10). Heidenreich (1997) describes utility in administering a tuberculin skin test. In general, due to the disease's



**Figure 8.10** In this radiograph, the 'punched out' lesions characteristic of tuberculosis are seen in the long bones. (Photo by P. T. Redig.)

zoonotic potential and poor treatment success, most authors recommend euthanasia for all tuberculosis patients.

### *Fungal and yeast infections*

A common yeast infection of raptors and other species of birds is *Candida albicans*. It generally affects the anterior gastrointestinal tract, with particular affinity for the crop. Clinical signs range from inappetance to flinging food, and regurgitation to complete anorexia. When the lower GI tract is involved, diarrhoea can occur. Usually no lesions are seen, but the mucous membranes have a somewhat milky and occasionally doughy appearance. There is often a layer of mucus, which adheres to the membranes and causes an audible clicking sound when the bird opens its mouth. Diagnosis of *Candida albicans* is made by cytology and culture; the former is performed using Diff-Quik or a Gram's stain on a glass slide preparation, the latter on Sabouraud's agar, where culture takes 2–3 days at 37°C. Treatment is a course of nystatin (20 000 IU/kg b.i.d. for 10 days). Alternatively, fluconazole (Diflucan®, Janssen Pharmaceutical, Titusville, New Jersey) is an effective treatment.

One of the most devastating diseases of raptors is the fungal infection of the respiratory system caused by *Aspergillus fumigatus* (Aguilar and Redig, 1995). Infection occurs by inhalation of the spores, which are ubiquitously distributed in the environment. The incubation period is extremely variable, depending on the immunocompetency and exposure dose of the host. Acute aspergillosis is the product of inhalation of overwhelming numbers of spores from the environment.

Clinical diagnosis is made by evaluation of a combination of clinical signs, complete blood count (elevated TWC and heterophilia), radiography, and tracheal washes for cytology and/or culture. A specific ELISA is available that detects antibodies to *A. fumigatus* (The Raptor Center, University of Minnesota). Antigen detection tests and serum electrophoresis (University of Miami, School of Medicine) are showing promise as useful tools in diagnosing this disease, and bronchoscopy and laparoscopy are invaluable in confirming the diagnosis. The currently recommended treatment consists of oral itraconazole (Sporonox®, Janssen Pharmaceutica, Titusville, New Jersey),

nebulization with clotrimazole (Clotrimazole® Lotrimin Solution, Schering-Plough Health-Care Products Inc., Memphis, Tennessee), and intratracheal amphotericin B (Amphotericin B, Bristol-Meyers Squibb Co., Princeton, New Jersey) if bronchial and tracheal lesions are seen. Itraconazole (5–10 mg/kg b.i.d. for 5 days, then s.i.d. for up to 4 months) is effective in controlling clinically unapparent cases detected by ELISA or an elevated white cell count. Nebulization with clotrimazole (1 or more hours/day for 4 weeks) is indicated where clinical signs of inappetance, reduced endurance or mild respiratory signs are seen. Attempts to treat birds with severe respiratory signs have not been effective. Surgical removal of lesions that are blocking the trachea or syrinx is an effective therapeutic adjunct. Prophylaxis is recommended for captive-held raptors undergoing a change in management, and for certain species with a known high risk (Redig, 1996b).

### **Toxins**

Organochlorine pesticides remain a source of potential toxicity for raptors in parts of the world where these compounds are still used. The likelihood of encountering a raptor intoxicated from these compounds is small, and treatments are not known.

Presently, the most commonly occurring toxicities are due either to cholinesterase-inhibiting compounds (Porter, 1993) or lead (Kramer and Redig, 1997). Laboratory tests for toxins are run on suspicion of which toxin is involved from the clinical signs and history, if any is available. When a toxin is suspected, but the exact one is undetermined, it is advisable to treat with supportive care. This includes activated charcoal orally to stop any further gastrointestinal absorption of the toxin, intravenous and subcutaneous fluids, and diazepam if seizures are occurring. Lead poisoning remains one of the most significant causes of nervous and multisystemic diseases in waterfowl and in the raptors that eat them. Bald eagles are the most frequent victims. Clinical toxicosis occurs when the ingested lead is dissolved in the acid environment of the stomach and absorbed in sufficient quantity to cause disruption of various organ systems. Symptoms include anaemia, lethargy, anorexia, paralysis

of the anterior gastrointestinal tract, vomiting, ataxia, diarrhoea, and paralysis of the neck, wings or legs. Seizures and blindness may occur in some severe cases. The diagnosis is made from the clinical signs and from assays of the blood lead levels using atomic absorption spectrophotometry. Toxicity is typically apparent at blood lead levels greater than 0.4 ppm. Treatment with calcium-EDTA (CaEDTA, Sigma Chemical Co., St Louis, Montana), 35–50 mg/kg b.i.d., is initiated on the basis of clinical signs, clinical suspicion and blood lead levels. If lead particles are seen in the ventriculus on radiographs, they may be removed by gastric lavage or allowed to pass through the GI tract if the patient is not severely affected. Treatment should continue until blood lead levels are below 0.2 ppm. Treatment is not effective if blood lead levels are greater than 1.2 ppm (Kramer and Redig, 1997).

Toxicity due to cholinesterase-inhibiting compounds (i.e. organophosphates and carbamates) is another common form of poisoning in raptors (Porter, 1993). The onset of clinical signs is peracute, although there may be a delayed onset of 1–3 weeks, depending on the dosage received. These signs include ataxia and weakness, salivation and mild head tremors. Paralysis may be seen. The mechanism of action is similar to that in mammals, where acetylcholinesterase is inhibited at the neuromuscular junctions. The treatment consists of atropine (Atropine sulfate 1/120 g, Vedco Inc., St Joseph, Montana) or 2-Pam (2-Pam® pralidoxime hydrochloride, Survival Technology, Wyeth-Ayerst), supportive care, and diazepam (Valium® diazepam, Steris Laboratories Inc., Phoenix, Arizona) to control seizures.

### Zoonoses

There are diseases among raptors with zoonotic potential, although actual documentation of zoonoses is extremely rare. Chlamydiosis, itself very rare among raptors (Schlosberg, 1976), is clearly a concern should the disease ever be encountered in raptors. There is no indication that they are sub-clinical carriers of this disease. Tuberculosis produces a miliary disease in humans with varying clinical signs, depending on which organ systems are involved. This disease,

caused by *M. avium* in birds, is encountered with low frequency in raptors, but its zoonotic potential has not been realized. *M. avium* is regarded as having low pathogenicity for humans.

While salmonellosis has zoonotic potential, it is rarely encountered in either captive or wild raptors (Smith, 1993), and human handlers are more likely to encounter *Salmonella* spp. in the food items prepared for the birds. Proper sanitation and hygiene precautions are generally sufficient to prevent these and other infections with zoonotic potential.

## Part II: Clinical approach to management of medical problems in raptors

### Introduction

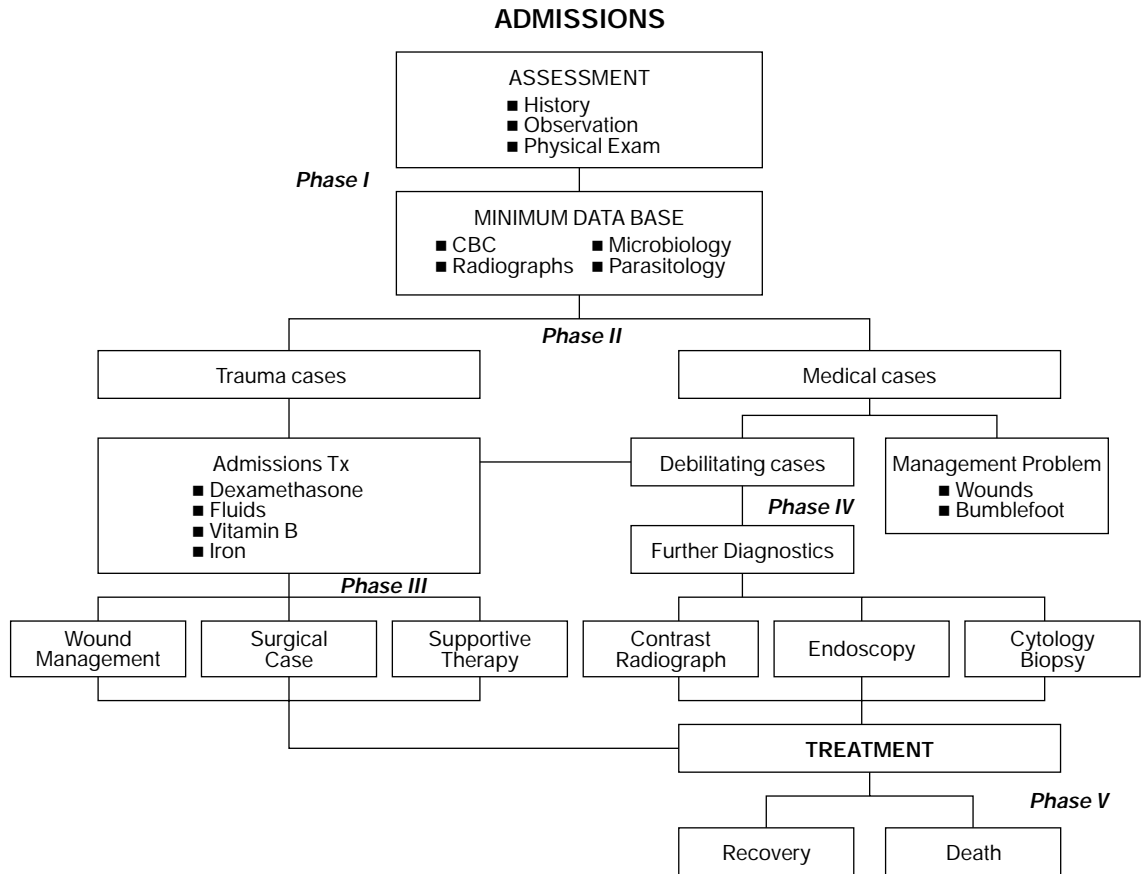
Part I of this chapter gave an overview of what raptors are and the significant medical problems they have, along with general treatment modalities that may be applied. In this section, approaches to patient assessment, establishment of a minimum database, and generalized and specific treatment modes for the most frequently encountered disease complexes will be presented.

While there is increased likelihood that captive-held raptors (such as are used in falconry or bird shows) may present with a defined problem or complaint, they (like the many wild casualty birds) often have multiple problems or complexes for which the presenting sign is only the most obvious indicator. In order to expedite diagnosis and application of appropriate treatment, a basic core of assessment and diagnostic procedures should be applied to all birds at admission, thereby avoiding the need for return visits for further diagnostics and a potential delay in the administration of what may be life-saving treatment.

### Assessment

The approach recommended for thorough assessment is presented in Figure 8.11. Phase 1 includes the usually followed anamnesis





**Figure 8.11** The treatment program for injured and ill raptors follows a five-phase process. Phase I is admission, examination and history taking. Phase II is stabilization treatments. Phase III is specific treatment for trauma cases, while phase IV entails the application of specific diagnostic tests to further elucidate problems in medical cases. Phase V is the outcome phase.

accompanied by a four-element minimum database, consisting of complete blood count (CBC), microbiological evaluation (bacteria and pathogenic fungi), radiological examination and, optionally, a parasite examination. Raptors, due to their strength, inherent ability to inflict damage on handlers and stressful response to restraint, are best handled under isoflurane (Isoflo® isoflurane, USP Abbot Laboratories, North Chicago, Illinois) anaesthesia (Redig, 1998) for all of these procedures except, of course, for history taking and observation. This recommendation extends to debilitated and dyspnoeic birds, especially the latter.

Phase 2 events flow directly from phase 1, both temporally and spatially, so that the initial stabilization and treatment modalities

are instituted essentially at the time of admission. It will be of greatest benefit to the patient if radiology facilities are available in the admission arena, and the haematology and microbiological procedures are conducted on an in-house basis to facilitate rapid return of results. Facilities and operational procedures should be designed with this arrangement in mind.

Phases 3 and 4 are separated in time and space from the first two phases, depending on the patient's needs and response to admission treatment. Surgical management of fractures may be delayed to allow for soft tissue management and overall patient recovery; however, earlier intervention will enhance the restoration of blood supply to damaged bone fragments.

### AVIAN HISTORY FORM

Owner's name and address: .....

.....

Telephone number: .....

Species: ..... Age: ..... Sex: .....

Name: .....

Has the bird been examined by another vet? Yes/No Name: .....

Telephone Number: .....

Duration of ownership? .....

Source (if acquired in last year)? .....

Do you or have you kept other birds (list species)? Yes/No .....

Any previous disease history with this or other birds? .....

Reason for presentation and clinical signs? .....

Duration of problem? .....

Any other birds/pets (own or friends) affected/ill? .....

Have you had any new birds in the last six months? .....

Does the bird have contact with feral birds? .....

Any change of food (type or source)? ..... Duration of food storage? .....

Has the bird received any medication? .....

Is the bird confined to perch/aviary/pond? ..... Size? ..... Inside/Outside? .....

Has anything changed in the bird's environment in the previous three months? .....

How long ago? .....

Change of appetite? .....

What diet is fed? ..... Are any other birds fed on the same diet? .....

Any change in the bird's behaviour? .....

List any supplements, additives or tonics administered: .....

Any change in water consumption? .....

What is the bird's reproductive status? .....

Has the bird's plumage changed at all in previous six months, ie. moulted or changed in appearance? .....

Has the appearance of the bird's excreta changed? .....

If yes, is it the coloured part (faeces) or the white part (urates) which has altered? .....

If flown, is there any exercise intolerance? .....

Have any nasal or ocular discharges been apparent? .....

Has there been any change in vocalisation? .....

What is the bird's body condition or weight? ..... What is the bird's normal weight? .....

Has the bird required more/same/less food to maintain its weight? .....

Is the bird perching normally on one leg or two, or lying down? .....

Is there excessive heat in either foot or any leg joint? .....

If a raptor, has it been casting normally? .....

**Figure 8.12** This shows the pertinent historical information that should be obtained for any raptor patient that is being held in captivity at the time of presentation.

Phase 5 addresses the outcomes and preparation for return to normal function. For birds being returned to the wild, recovery means not only restoration to function from disease or injury, but also returning the animal to the full athletic capability required for survival in the wild. It will severely diminish the likelihood of post-release survival if adequate exercise and evaluation regimens are not included in the management scheme prior to release.

### **History and background information**

For raptor patients coming from a captive environment, the information needed is summarized in the avian history form (Figure 8.12;

Forbes, 1996). For wild casualty birds, most of the information requested in the history form is unavailable. However, the following details should be obtained if possible:

- 1 Name and address of person recovering the bird if different from presenter
- 2 Date of recovery
- 3 Location of recovery
- 4 Circumstances of recovery
- 5 Proximity to fences or power lines
- 6 Proximity to roads and vehicular traffic
- 7 Proximity to water
- 8 Proximity to windows or glass buildings
- 9 Proximity to areas of recent pesticide application

**Table 8.5** Key observations to be made in assessing a raptor patient

<i>Parameter</i>	<i>Normal appearance</i>	<i>Common abnormalities</i>
Posture	Erect, near vertical	Hunched over, wings drooped, leaning to one side, hocks straight
Respiratory rate and character	10–15/minute, little to no evidence of movement of body parts, especially in areas over the shoulders, tailhead or in the abdominal area	Tail bobbing with each breath Exaggerated movements of abdominal panel between legs Movement of wings in shoulder area with each breath
Eyes	Round, bright, adnexia clean and dry	Dull appearance to cornea Squinted or almond shaped Lids closed Moisture on feathers below eye
Feathers	Clean, straight, rounded edges	Soiling with mutes or dirt on tips of tail and wing feathers Broken, frayed Damage to top of head Fluid or blood on body feathers
Mutes (stool)	Dark black centres with chalk white urates, occasionally tan centres if fed day-old chicks Urates occasionally have a reddish pigment in them (unknown) Bright green centres in a fasted bird	Lime-green staining to faecal or urine component Yellow urates Dark blood flecks
Condition of scales on legs and feet	Bright yellow, clean, undamaged	Brown lumps Missing or worn scales Swellings
Talon condition	Even curvature, sharp points	Thick, dull Twisted Missing Too long and curved
Beak and cere	Beak black, cere a bright shiny yellow Beak of normal length, coming to a sharp point	Cere traumatically damaged Beak cracked and delaminating, especially around tooth in falcons Mandible or maxilla overgrown

- 10 Any other affected birds or mammals in the vicinity
- 11 Any treatments administered prior to presentation
- 12 Any identifying markers, rings or bands carried by the bird.

Captive-held birds used for falconry or bird shows will most often be presented perched on the fist, with or without a hood, or inside a carrying box with which they are very comfortable and familiar. Before the bird is restrained for any further work, a few minutes should be spent observing the bird as it is perched. The key observations are listed in Table 8.5.

Wild birds are more difficult to observe. However, the task can be accomplished by releasing the bird into an unoccupied room or large cage and observing it clandestinely for the above parameters. Often such observations are made following admission and physical examination in wild birds.

### ***Faecal and urine examination***

In raptors, intestinal and urinary tract outputs are collectively referred to as a 'mute'. Birds in boxes for any amount of time will have muted in the box, and this material should be examined. Hooded falcons will usually mute when the hood is removed. As indicated in Table 8.5, the normal mute of a raptor consists of a dark black centre surrounded by a pure chalky white urate mass, sometimes accompanied by a larger ring of clear urine. Any presentation other than this should raise a question. A fatty diet (such as day-old cockerels) will cause the faecal portion to turn tan, and the small feathers of such cockerels may be passed through the GI tract and appear in the mute. A fasted bird (one normally fed at the same time every day and approaching feeding time when examined) will pass unutilized bile in the faecal portion, which has a bright green appearance. Any other shades of green or other colours in either the stool or the urine are indicative of serious liver, kidney or urinary tract problems. A very thorough review of the various mute presentations, enhanced by vivid colour pictures is available in Heidenriech (1997).

### ***Physical examination***

It is difficult – if not impossible – to conduct an adequate physical examination on a strong, frightened and struggling raptor. Not only is it difficult, it is also dangerous to both restrainer and examiner. The safety and efficacy of isoflurane anaesthesia alleviates all of these concerns, and its use is highly recommended. Anaesthesia can be administered safely by mask immediately upon restraining the bird. Birds wearing hoods can be anaesthetized while perching on their owner's fist, by placing a cone with a large opening over the bird's head and shoulders. Mild restraint may be necessary with the onset of ataxia.

A checklist of parameters is presented in Table 8.6.

### ***Laboratory assessment***

The haematological assessment can be quickly accomplished by drawing 0.1–0.2 cm<sup>3</sup> blood from the basilic, metatarsal, cutaneous ulnar or jugular veins, and preparing two or three good films and two haematocrit tubes. The tubes are spun immediately for determination of packed cell volume and total plasma solids (refractometer), while the slides can be stained with a rapid staining method (e.g. Diff-Quik®, American Scientific Products, Harleco, Gibbstown, New Jersey), dried with a blowdrier and examined by microscope within a few minutes of drawing. An estimated white cell count and differential will yield the necessary data for interpretation. Presently, the parameters assessed are total white cell count, differential white cell count (percentages), and examination for blood parasites. The use of absolute counts for different white cells has not typically been pursued, hence no reference values for this parameter or indications of its clinical use are available. Table 8.7 contains reference values for haematological parameters in raptors (Redig, 1996b).

Microbiological examination should consist of cultures taken from the oral pharynx and trachea, and from freshly voided faeces. The use of an in-house microbiological system (Vet Dx Micro-System®, Vet Dx Co., 978 W County Road E, Shoreview, Minnesota) allows quicker results. The trachea should be cultured as a routine matter, using a nasopharyngeal swab thrust deeply into the trachea and cultured on

**Table 8.6** Checklist of parameters for physical examination in a raptor

<i>Important items to note</i>	
<i>Head region</i>	
Beak (maxilla)	Length Normal notch or tomial tooth in falcons Absence of cracking or delaminating Proper approximation to mandible when closed
Beak (mandible)	Length normal – not forcing maxilla outward Mandibular rami intact
Cere	Note colour, evidence of trauma, nodular lesions
Nostril and operculum	Rhinoliths
Mouth	Membranes pink in most species, blue in accipiters and merlins Membranes doughy consistency, clinging mucus (associated with <i>Candida</i> spp. infections) Proliferative lesions, diphtheritic membranes (associated with pox)
Tongue	Ingested tendon or other fibrous material entangled around base Caseous lesions sublingually
Palate	Caseous lesions Penetrating wounds
Choanal slit	Mucus Palatine fringes with caseous lesions
<i>Eyes</i>	
Adnexia	Normally feathered, not damp, not reddened, no crepitus when palpated
Conjunctiva	White, not inflamed or infiltrated with blood vessels
Lacrimal duct	Normal, bilaterally symmetrical distension, not oedematous, fluorescein dye test – no retention
Cornea	Normal, bilaterally symmetrical distension, not oedematous, fluorescein dye test – no retention
Iris	Normally pigmented, round, responsive to light
Anterior chamber	Filled with clear fluid, no blood or fibrin strands, no turbidity, no synechia
Lens	In normal position, translucent, not containing a cataract
Posterior chamber	
Posterior segment and retina	Uninterrupted retinal pattern, pecten in normal position, absence of focal areas of depigmentation
Ears	Free of blowfly larvae and blood
Pharynx	Colour of mucous membranes (pigmented blue in accipiters), devoid of lesions, foreign bodies
Neck region	Free of obstructing foreign bodies, fistulas, no crepitus
Crop	Empty or solid distension from food, not soft and fluctuant as with fluid content, not fistulated
Thoracic inlet	Free of obstructing foreign bodies
Shoulder girdle	Symmetrical range of motion of humeral head, no crepitus or joint laxity
Joint palpation	Elbows, metacarpi, stifles, hocks – not swollen, full range of motion
Forelimb	Functional mechanical extension, integrity of patagium
Alula	Not turned over leading edge of wing
Secondary feathers	Not broken, frayed, or abnormally sheathed
Primary feathers	Not broken, frayed, or abnormally sheathed while still growing, look for evidence of fault bars
<i>Pelvic limb</i>	
Femur and hip	Absence of fractures, crepitus, weight-bearing symmetry
Tibiotarsus	Asymmetrical muscle mass between legs Lack of tension when stretched, weight-bearing
Tarsometatarsus	Nodular lesions, cuts, bite wounds, trap injuries, weight-bearing
Halux	Held in flexed position from extensor tendon rupture, erosive lesions on joint pads
Forward digits	Erosive lesions on digital pads Accumulation of debris under talons at end of P1 Held in flexed position from flexor tendon rupture
Metatarsal pad	Erosive lesions Puncture wounds Swelling ulceration
<i>Abdominal region</i>	
	Brood patch in laying females – normal Swollen liver Distended ventriculus

**Table 8.7** Basic haematology (Altman *et al.*, 1997)

Haematologic, biochemical and morphometric reference ranges of selected raptor species

**a.** Haematological reference ranges of selected healthy adult captive raptors\*

Value	Red-tailed hawk (n = 10)	Great-horned owl (n = 10)	Bald eagle (n = 8)	Peregrine falcon (n = 14)	Gyrfalcon (n = 12)
PCV (%)	44.6 (2.6)†	43.3 (2.9)	44 (4)	44 (4)	49 (2)
Total protein (g/dl)	4.3 (0.5)	5.1 (0.6)	4.0 (1)	2.65 (1.18)	2.94 (0.38)
White blood cells ( $\times 10^3/\mu\text{l}$ )	6.0–8.0	6.0–8.0	12.8 (4.8)	8.7 (2.2)	4.6 (1.7)
Heterophils (%)	35 (11.1)	47 (10.7)	75 (13)	65 (12)	51 (5)
Lymphocytes (%)	44 (8.9)	27 (7.0)	18 (10)	35 (13)	47 (5)
Monocytes (%)	6 (3.2)	9 (3.6)	3 (3)	0 (0)	1 (1)
Basophils (%)	2 (1.3)	Rare	Rare	0 (0)	Rare
Eosinophils (5)	13 (3.8)	1 (1.2)	4 (3)	0 (1)	1 (1)

\*From Dr. P. Redig, The Raptor Center, University of Minnesota, St. Paul, MN 55108.

†Standard deviation in parentheses.

**b.** Haematological and morphometric measurements of wild red-tailed nestlings\*

Stage of development	Primary feather length (cm)	Central tail feather length (cm)	PCV (%)	Total protein (g/dl)	RBC ( $\times 10^3/\mu\text{l}$ )	Haemoglobin (g/dl)
Early (n = 5)	0–10	0–8	28 (1)†	3.4 (0.1)	1.74 (0.09)	9.79 (0.40)
Late (n = 5)	11–18	9–16	33 (1)†	4.0 (0.1)	2.35 (0.03)	10.98 (0.14)

\*From Dr. P. Redig, The Raptor Center, University of Minnesota, St. Paul, MN 55108.

†Means  $\pm$  standard deviations in parentheses.**c.** Serum biochemical reference values of selected raptor species\*

Value	Bald eagle (n = 8)	Peregrine falcon (n = 14)	Gyrfalcon (n = 12)	Red-tailed hawk (n = 10)	Great-horned owl (n = 10)
Acetylcholinesterase (delta pH units/h)	0.16 (0.06)	–	–	–	–
Alanine aminotransferase [ALT] (U/L)	25 (13)	62 (56)	–	31 (5)	39 (14)
Albumin (g/dl)	1.09 (0.18)	0.96 (0.13)	0.73 (0.09)	1.34 (0.41)	1.27 (0.35)
Alkaline phosphatase (U/L)	57 (12)	99 (44)	257 (61)	53 (18)	31 (7)
Amylase (U/L)	1158 (376)	–	–	–	–
Aspartate aminotransferase [AST] (U/L)	218 (63)	78 (31)	97 (33)	303 (22)	287 (65)
Bilirubin, total (mg/dl)	0.31 (0.08)	4.57 (2.04)	–	0.16 (0.08)	0.07 (0.06)
Blood urea nitrogen [BUN] (mg/dl)	3.10 (2.47)	3.25 (1.39)	4.67 (0.82)	4.67 (0.47)	5 (2.94)
Calcium (mg/dl)	9.94 (0.45)	8.93 (0.46)	9.61 (0.24)	–	10.19
Chloride (mmol/L)	120 (3)	114.38 (43.36)	125 (2)	125 (3)	122
Creatine kinase (U/L)	383 (300)	783 (503)	402 (163)	1124 (251)	977 (407)
Creatinine (mg/dl)	0.70 (0.26)	0.51 (0.22)	–	–	–
Glucose (mg/dl)	302 (25)	366 (29)	318 (39)	356 (16)	356
Osmolality (mmol/kg)	319 (6)	–	–	–	–
Phosphorus (mg/dl)	3.03 (0.51)	3.35 (0.70)	3.57 (1.13)	3.14 (0.5)	4.34
Potassium (mmol/L)	3.0 (0)	2.04 (0.81)	1.99 (0.56)	2.42 (0.73)	2.8
Protein, total (g/dl) (biuret)	3.51 (0.75)	2.63 (0.48)	2.89 (0.31)	4.17 (0.69)	4.33
Sodium (mmol/L)	156 (4)	143 (54)	160 (3)	157 (1)	156
Uric acid (mg/dl)	5.07 (3.33)	4.50 (4.24)	13.93 (5.64)†	10.84 (5.1)†	13.7 (10.8)†

\*From Dr. P. Redig, The Raptor Center, University of Minnesota, St. Paul, MN 55108. All samples were collected from healthy adult birds – either display/education or breeders or birds flown in falconry. All samples were collected after the birds had been anaesthetized for a minimum of 10 minutes with isoflurane.

†Postprandial samples.

a half a Sabouraud's dextrose plate for *Aspergillus* organisms. The other half of this same plate can be used to culture the pharynx for *Candida* spp. The results from the bacteriology will be available in 18–20 hours, while the fungal and yeast cultures will yield results in 48–72 hours if incubated at 37°C.

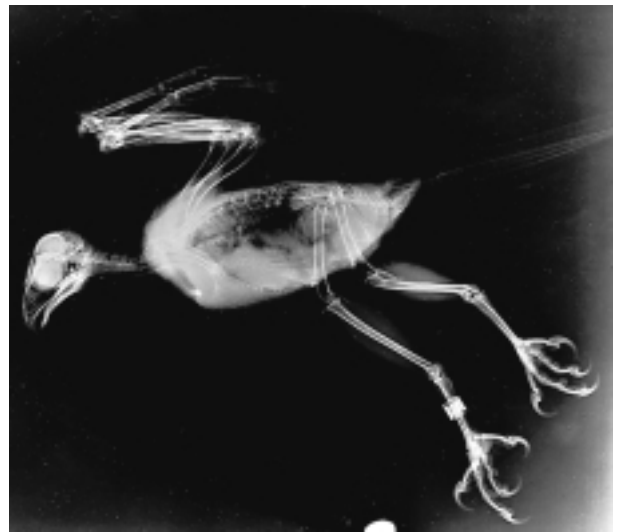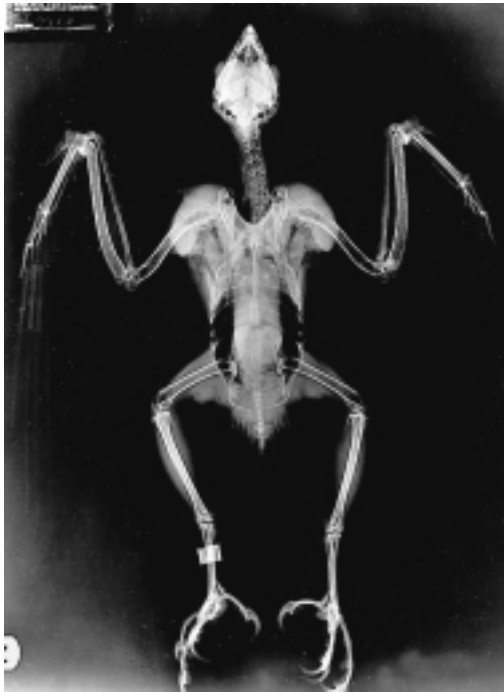With the exception of trichomonads, coccidia and external metazoans, most parasites are given little specific diagnostic attention. On the second or third day post-admission, patients are routinely given praziquantel and ivermectin orally. If external parasites are present, the raptors are sprayed lightly with a pyrethrin spray. Signs specifically referable to coccidia or trichomoniasis trigger further verifying diagnostics and treatment, as described in the previous section.

Radiology is mandatory for proper evaluation of any trauma case, and very useful in medical cases where the source of the problem is not immediately obvious. A tabletop technique using ultradetail film and rare earth screens (UltraDetail Rare Earth System® Veter-

inary X-ray Film, Animal Care Products, 3M HealthCare, St Paul, Minnesota) routinely yields diagnostic results. It is recommended that ventro-dorsal and lateral (right side down, head to the left) views be taken (Figure 8.13). The following diagnoses can be made radiographically, and are relatively unapparent without X-rays: fractures of the coracoid and furcula; luxations of joints in the limbs; foreign bodies in the GI tract; swelling of the liver, kidneys and spleen; lung contusions; air sac ruptures with internal organ displacement.

The last of the general procedures conducted at admission is ophthalmoscopy (Davidson, 1997). While a direct instrument is most often used, indirect ophthalmoscopy affords some advantages of distance from the subject. If an ophthalmic examination is conducted as part of the general examination under anaesthesia, no further mydriatic agent is needed.

The cornea and adnexia should be examined first. The lower lid should be pulled away from the eye and examined for foreign



**Figure 8.13** These show the proper radiographic positioning radiographic anatomy of a raptor (red-tailed hawk) in lateral and ventro-dorsal views. Note healed radial fracture. (Radiograph by T. Guarnera.)

bodies or inflammation of the palpebral conjunctiva, and the cornea examined for evidence of scratches or ulcers. A fluorescein uptake test is needed to confirm presence of such injuries, and is mandatory prior to the application of any topical agents to the eye. As usual, steroid-containing preparations should be avoided if there is ulceration of the cornea. The anterior chamber should be examined for hyphaema, iris prolapse and anterior synechia. The lens can be examined for evidence of cataracts and, most importantly, the retina must be examined for evidence of detachment or tearing in any trauma case.

Epiphora may be present as a result of a blocked nasolacrimal duct. The opening of this duct can be found in the medial canthus when the lower lid is extended, and it is possible to insert a small blunt needle into the duct and flush it with saline to alleviate this condition.

Further assessment of visual function can be made in the awake patient by:

- testing the ability of the bird to track a finger or hand moved in front of it across the field of vision
- assessing the response to a menace by quickly thrusting a hand or object toward the bird

- test flying the bird in a corridor with a perch at each end.

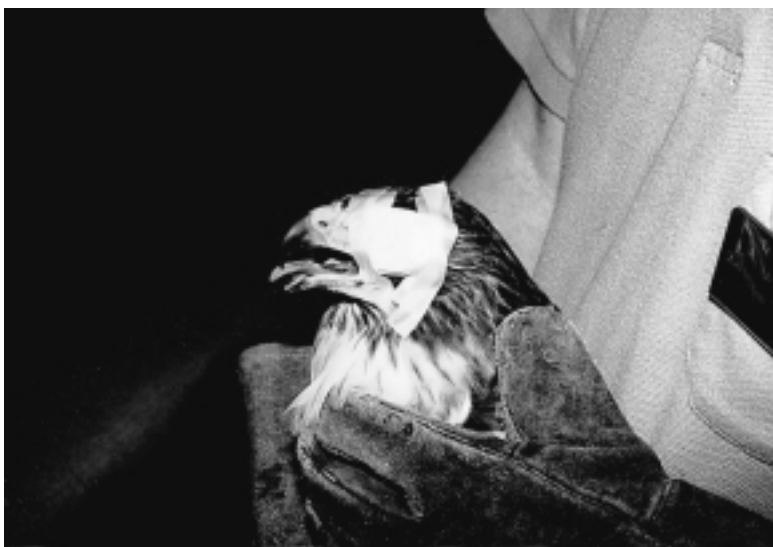By covering one of the other of the eyes with a soft gauze pad taped in place, each eye can be tested individually for evidence of blindness (Figure 8.14).

## Admission treatments

The majority of wild birds are submitted for traumatic injuries and related debilitating conditions. Accordingly, they can be assumed to have undergone food deprivation, weight loss, dehydration and blood loss. They are mildly to severely azotaemic, and in a state of metabolic acidosis. The standardized regimens described in Tables 8.8 (a and b) are recommended for all incoming raptors at the time of admission. Parts (or all) of these regimens are also recommended for captive-held birds that have been severely injured or are afflicted by debilitation.

## Triage

Once the initial assessment and stabilization is complete, the patient should be further assessed for the prospects of recovery and meeting programmatic goals. Where return



**Figure 8.14** The use of a unilaterally applied eye patch made of soft gauze and tape is useful for detecting visual deficits. (Photo by P. T. Redig.)



**Table 8.8a** Stabilization protocol (Forbes, 1996)

<i>Agent</i>	<i>Dose schedules</i>
Intravenous lactated Ringer's solution (LRS or Hartmann's)	10 ml/kg bolus injection through a 22–27G catheter or needle may be given at a rate of 10 ml/minute
Dexamethasone (2 mg/ml) or dexamethasone phosphate (4 mg/ml)	2 mg/kg, usually mixed with LRS as above
Iron dextran	10 mg/kg i.m.
B complex vitamins	Volume sufficient to provide 10 mg/kg thiamine from preparation in use, i.m.
High calorific enteral preparation	10–15 ml/mg. Stomach capacity of raptorial species is about 40 ml/kg
Enrofloxacin or other broad-spectrum antibiotic	15 mg/kg i.m. or p.o. b.i.d.

**Table 8.8b** Fluid therapy: sample problem

Patient:	Adult female red-tailed hawk with an open fracture of the humerus
	Bodyweight: 1040 g
	PCV: 28%
	TP: 2.6
	Hydration state: 10% dehydrated
Fluid:	Fluid deficit: $1040 \text{ g} \times 0.10 = 104 \text{ ml}$
Requirements:	Maintenance: 50 ml/kg/day
Plan:	Replace 50% of deficit (+ maintenance) in the first 24 hours; the remainder (+ maintenance) over the next 48 hours

<i>Therapy</i>	<i>Administration</i>
Day 1: 50% of deficit = 52 ml Maintenance = 50 ml Total = 102 ml	Administer 25 ml i.v. q.i.d. = total of 100 ml
Day 2: 25% of deficit = 26 ml Maintenance = 50 ml Total = 76 ml	Administer 25 ml i.v. t.i.d. = total of 75 ml Start oral alimantation
Day 3: 50% of deficit = 26 ml Maintenance = 50 ml Total = 76 ml	Administer 25 ml i.v. t.i.d. = total of 75 ml
Day 4: Maintenance = 50 ml	Provide maintenance fluids in two doses, i.e. 25 ml i.v. b.i.d. Oral alimantation as indicated. Increase solid intake to near normal levels

to the wild or full flight status is the desired outcome, birds that are clearly blind in one or both eyes or have irreparable damage to a wing or leg or such debilitating disease that full recovery is an obvious impossibility should be candidates for euthanasia. Where wild casualty birds are being received, about 25–30 per cent will be terminated after the

initial assessment. As the treatment programme progresses, further triage should be conducted frequently.

For patients going forward, wound management is the next procedure undertaken, taking advantage of the anaesthesia already in use for the examination and stabilization phase. Dead tissue and blood-matted feathers should be cut

away from the wound using iris scissors. The area around the wound should be further cleared of feathers, again cutting them next to the skin with scissors rather than plucking them, as that will probably result in tears in the skin. The area around the wound should be cleaned with povidone iodine, then the wound flushed several times with volumes (50–100 cm<sup>3</sup>) of warmed fluid – some clinicians recommend saline, others (including the authors) recommend lactated Ringer's solution. The cleaned and debrided wound should be daubed dry with sterile sponges and drawn partially closed; temporary closure can be rapidly obtained using skin staples. If the wound is more than 8 hours old, a gauze seton should be left in place for drainage. The wound should then be covered temporarily with a transparent semipermeable membrane dressing to prevent desiccation and the surrounding area dried with a hairdrier. After removing the temporary wound dressing, sterile absorbent wound dressing material should be applied over the wound and held in place with another piece of membrane dressing before applying further support bandaging using gauze and materials such as Vetrup<sup>®</sup>. Bandages should be changed daily, and the remainder of the protocol followed as is consistent with circumstances involving the wound.

## Other aspects of raptor medicine

Besides traumatic injuries, there are four other principal problems that occur frequently in managing raptors:

- 1 Anorexia with or without regurgitation.
- 2 Low condition/starvation.
- 3 Respiratory disease causing dyspnoea.
- 4 Nervous disorders.

Most disorders involving raptors are accompanied by anorexia, trauma being the one notable exception. Anorexia may be a primary problem, or it may occur secondary to some other ailment.

Causes of anorexia may be divided into primary and secondary categories (Table 8.9).

### Primary causes of anorexia

- 1 Biological agents:
  - trichomoniasis
  - *Candida albicans*
  - capillaria
  - bacterial stomatitis
  - viral stomatitis
- 2 Foreign bodies:
  - fish hooks
  - wire
  - segments of tendon from food items wrapped around the tongue
  - large bones from food items, e.g. chicken necks, vertebral columns.

### Secondary causes of anorexia

- 1 Other infectious agents:
  - aspergillosis
  - gastritis/enteritis of varying aetiologies
  - coccidia
  - viral infection of liver
- 2 Other causes:
  - low condition and sour crop

**Table 8.9** Causes of anorexia in raptors

Primary causes	Secondary causes	Foreign bodies
Trichomoniasis	Low condition and sour crop	Fish hooks
Candida	Gastritis/enteritis	Jesses
Bacterial stomatitis	Aspergillosis	Wire
Viral stomatitis	Coccidia	Skeletal parts pheasant and chicken necks rabbit legs (femur to foot) vertebral columns from chickens and pheasants
Capillaria		
Idiopathic		

- lead poisoning
- fractured coracoid with medial displacement of the distal fragment impinging on crop
- crop fistula – due to frost-bite, penetrating wound, etc.

The most common cause of anorexia is probably *Candida albicans* infections occurring during times of stress and/or in association with antibiotic therapy, as discussed in Part I.

Anorexia related to foreign bodies or lead poisoning involves complex treatments associated with removal of the offending material and supportive care.

### **Low condition/starvation**

The most life-threatening anorexia is that associated with sour crop and low condition/starvation (Redig, 1996b). Low condition is a unique metabolic state in raptors trained for falconry. After several weeks of being maintained in the state of lean body mass required for hunting, some birds enter a net catabolic state. Though not hypoglycaemic, they are dehydrated and unable to process a crop of ingested food. Having failed to turn their crop over, affected birds soon become secondarily overwhelmed with bacterial endotoxins produced in the moist anaerobic environment. Treatment is aimed at rapidly diluting the

crop contents and encouraging motility and digestion and/or regurgitation. If after 2 hours this modality has failed, then mechanical removal of the crop contents under anaesthesia is required. Aggressive fluid therapy and intense supportive care is also necessary. Above all, oral alimentation with solid food must be avoided for several days. Introduction of solid food at too early a stage will cause a second bout of sour crop.

### **Dyspnoea**

Respiratory problems in raptors arise from allergic (idiopathic) sources, upper airway obstruction (granulomatous or foreign body) or lower respiratory disease, most frequently aspergillosis. Parasites and bacteria are rarely implicated.

### **Central nervous system disorders**

There are four recognized causes of CNS disorders:

- 1 Lead and other heavy metal poisoning, especially common in bald eagles.
- 2 Cholinesterase-inhibiting poisons – carbamates and organophosphates.
- 3 Vitamin B deficiency.
- 4 Aberrant parasitism, in particular *Sarcocystis* spp. (Cawthorne, 1993).



**Figure 8.15** The star-gazing posture of this prairie falcon (*Falco mexicanus*) is attributed deficiency of B vitamin, possibly as a result of malabsorption arising from an enteritis. (Photo by P. T. Redig.)

Lead poisoning is diagnosed by determining blood lead levels using atomic absorption spectrophotometry. It is treated with calcium EDTA and supportive care, as discussed in Part I.

Cholinesterase-inhibitor toxicity is an acute, life-threatening toxicity. Convulsive seizures can be controlled by the administration of diazepam (0.5–1.0 mg/kg) and atropine or 2-PAM, as outlined in Part I.

Vitamin B deficiency is principally seen in large falcons, where it causes a star-gazing syndrome (Figure 8.15). The aetiology is obscure; however, Heidenreich (1997) proposed that it is caused by an enteritis that interferes with the absorption of B vitamins and leads to the neurological disorder. Aggressive parenteral therapy with a B complex in the acute stages is said to reverse the disease. However, the derangement can become permanent and unresponsive to therapy if not dealt with immediately.

Clinical differentiation of the above syndromes is based on history, clinical signs and laboratory diagnostic tests, including lead level determination and whole blood cholinesterase activity. Lead cases with blood levels above 1.2 ppm never recover, and should be triaged. Treatable cholinesterase-inhibitor cases will respond within 1–4 hours; failure to do so indicates a very grave prognosis. Aberrant parasitisms are unresponsive, and diagnosis has been made only at necropsy.

## Conclusion

While raptors as birds have many clinical aspects in common with other species, their presentation either as casualty patients or as athletic working birds used in the sport of falconry or flown in bird shows sets them apart and generates unique circumstances. Shock, dehydration and massive soft tissue and orthopaedic injuries challenge the clinician, and metabolic problems due to food restriction and heavy exercise create challenges on the medical side. Overall, however, they are sturdy birds that are easily maintained on a properly balanced carnivore diet. They are easy to anaesthetize, and are very tolerant of surgical and medical treatments. Those who wish to develop expertise in their management should become thoroughly

familiar with their natural history and the sport of falconry. Combining knowledge of these elements with a specific background in avian medicine will give specialists the tools needed competently to engage in the care and treatment of raptors.

## References

- AGUILAR, R. F. and REDIG, P. T. (1995). Diagnosis and treatment of avian aspergillosis. In: *Kirk's Current Veterinary Therapy XII* (J. D. Bonagura and R. W. Kirk, eds), pp. 1294–8. W. B. Saunders.
- AGUILAR, R. F., SHAW, D. P., DUBEY, J. P. and REDIG, P. T. (1991). *Sarcocystis*-associated encephalitis in an immature northern goshawk (*Accipiter gentilis atricapillus*). *J. Zoo. Wild. Med.*, **22**(4), 466–9.
- ALTMAN, R. B., CLUBB, S. L., DORRESTEIN, G. M. and QUES-ENBERRY, K. (eds) (1997). *Avian Medicine and Surgery*. W. B. Saunders.
- ARENT, L. R. and MARTELL, M. (1996). *Care and Management of Captive Raptors*. The Raptor Center, University of Minnesota.
- BEEBE, F. L. and WEBSTER, H. M. (1994). *North American Falconry and Hunting Hawks*. North American Falconry and Hunting Hawks.
- BOYDELL, I. P. and FORBES, N. A. (1996). Diseases of the head (including the eyes). In: *Manual of Raptors, Pigeons and Waterfowl* (P. H. Beynon, N. A. Forbes and N. Harcourt-Brown, eds), pp. 140–46. British Small Animal Veterinary Association.
- CARPENTER, J. W., MASHIMA, T. Y. and RUIPIPER, D. J. (1996). *Exotic Animal Formulary*. Greystone Publications, Manhattan, KN.
- CAWTHORNE, R. A. (1993). Cyst-forming coccidia of raptors: Significant pathogens or not? In: *Raptor Biomedicine* (P. T. Redig, J. E. Cooper, J. D. Remple and D. B. Hunter, eds), pp. 14–20. University of Minnesota Press.
- COOPER, J. E. (1985). *Veterinary Aspects of Birds of Prey*. Standfast Press.
- COOPER, J. E. (1996). Introduction. In: *Manual of Raptors, Pigeons and Waterfowl* (P. H. Beynon, N. A. Forbes and N. Harcourt-Brown, eds), pp. 9–16. British Small Animal Veterinary Association.
- DAVIDSON, M. (1997). Ocular consequences of trauma in raptors. *Sem. Avian Exotic Pet Med.*, **6**(3), 121–30. W. B. Saunders.
- DUBEY, J. P., PORTER, S. L., HATTEL, L. *et al.* (1991). *Sarcocystis*-associated clinical encephalitis in a golden eagle (*Aquila chrysaetos*). *J. Zoo. Wild. Med.*, **22**(4), 233–6.
- DUKE, G. E. (1986). Alimentary canal; anatomy, regulation of feeding and motility. In: *Avian Physiology*, 4th edn (P. D. Sturkie, ed.), pp. 269–88. Springer-Verlag.
- ELLIS, K. L. (1986). Bilateral bumblefoot in a wild red-tailed hawk. *J. Rapt. Res.*, **20**(3/4), 132.
- FORBES, N. A. (1996). Chronic weight loss, vomiting and dysphagia. In: *Manual of Raptors, Pigeons and Waterfowl*

- (P. H. Beynon, N. A. Forbes and N. Harcourt-Brown, eds), pp. 189–96. British Small Animal Veterinary Association.
- FORBES, N. A. (1997). Adenovirus infection in Mauritius kestrels (*Falco punctatus*). *J. Avian Med. Surg.*, **11**(1), 31–3.
- FORBES, N. A. and SIMPSON, G. N. (1997). *Caryospora neofalconis*: an emerging threat to captive-bred raptors in the United Kingdom. *J. Avian Med. Surg.*, **11**(2), 110–14.
- FWOLEY, M. E. (1986). Metabolic bone disease. In: *Zoo and Wild Animal Medicine*, 2nd edn (M. Fowler, ed.), pp. 69–90. W. B. Saunders.
- GENTZ, E. J. (1996). *Fusobacterium necrophorum* associated with bumblefoot in a wild great-horned owl. *J. Avian Med. Surg.*, **10**(4), 258–61.
- GREINER, E. (1997). Parasitology. In: *Avian Medicine and Surgery* (R. B. Altman, S. L. Clubb, G. M. Dorrestein and K. Quesenberry, eds), pp. 332–49. W. B. Saunders.
- HARCOURT-BROWN, N. (1996). Foot and leg problems. In: *Manual of Raptors, Pigeons and Waterfowl* (P. H. Beynon, N. A. Forbes and N. Harcourt-Brown, eds), pp. 147–68. British Small Animal Veterinary Association.
- HEIDENREICH, M. (1997). *Birds of Prey: Medicine and Management*. pp. 12–14, 52. Blackwell Wissenschafts-Verlag.
- HUNTER, D. B., MCKEEVER, K. and BARLETT, C. (1993). Cyathostoma infections in screech owls, saw-whet owls, and burrowing owls in southern Ontario. In: *Raptor Biomedicine* (P. T. Redig, J. E. Cooper, J. D. Remple and D. B. Hunter, eds), pp. 54–6. University of Minnesota Press.
- KRAMER, J. and REDIG, P. T. (1997). Sixteen years of lead poisoning in eagles. *J. Rapt. Res.*, **31**(4), 327–32.
- MALLEY, A. D. and WHITBREAD, T. J. (1996). The integument. In: *Manual of Raptors, Pigeons and Waterfowl* (P. H. Beynon, N. A. Forbes and N. Harcourt-Brown, eds), pp. 129–39. British Small Animal Veterinary Association.
- OAKS, J. L. JR. (1996). Immune and inflammatory responses in falcon staphylococcal pododermatitis. In: *Raptor Biomedicine* (P. T. Redig, J. E. Cooper, J. D. Remple and D. B. Hunter, eds), pp. 72–87. University of Minnesota Press.
- OROSZ, S. E., ENSLEY, P. K. and HAYNES, C. J. (1992). *Avian Surgical Anatomy: Thoracic and Pelvic Limbs*. W. B. Saunders.
- PARKS, J. E. and HARDASWICK, V. (1987). Fertility and hatchability of falcon eggs after insemination with frozen peregrine falcon semen. *J. Raptor Res.*, **21**(2), 70–72.
- POKRAS, M. A., WHEELDON, E. B. and SEDGEWICK, C. J. (1993). Trichomoniasis in owls: report on a number of clinical cases and a survey of the literature. In: *Raptor Biomedicine* (P. T. Redig, J. E. Cooper, J. D. Remple and D. B. Hunter, eds), pp. 88–91. University of Minnesota Press.
- PORTER, S. A. (1993). Pesticide poisoning in birds of prey. In: *Raptor Biomedicine* (P. T. Redig, J. E. Cooper, J. D. Remple and D. B. Hunter, eds), pp. 239–45. University of Minnesota Press.
- REDIG, P. T. (1996a). Nursing avian patients. In: *Manual of Raptors, Pigeons and Waterfowl* (P. H. Beynon, N. A. Forbes and N. Harcourt-Brown, eds), pp. 42–6. British Small Animal Veterinary Association.
- REDIG, P. T. (1996b). Raptors. In: *Avian Medicine and Surgery* (R. B. Altman, S. L. Clubb, G. M. Dorrestein and K. Quesenberry, eds), pp. 918–28. W. B. Saunders.
- REDIG, P. T. (1998). Recommendations for anaesthesia in raptors with comments on trumpeter swans. *Sem. Avian Exotic Pet Med.*, **7**(1), 22–30.
- RITCHIE, B. W., HARRISON, G. J. and HARRISON, L. R. (1994). *Avian Medicine: Principles and Application*. Wingers.
- SCHLOSBERG, A. (1976). Treatment of monocrotoplot-poisoned birds of prey with pralidoxime iodide. *J. Am. Vet. Med. Assoc.*, **169**(11), 989–90.
- SMITH, S. A. (1993). Diagnosis and treatment of helminths in birds of prey. In: *Raptor Biomedicine* (P. T. Redig, J. E. Cooper, J. D. Remple and D. B. Hunter, eds), pp. 21–7. University of Minnesota Press.
- TULLY, T. N. (1997). Formulary. In: *Avian Medicine and Surgery* (R. B. Altman, S. L. Clubb, G. M. Dorrestein and K. Quesenberry, eds), pp. 671–87. W. B. Saunders.
- WEAVER, J. D. and CADE, T. J. (1983). *Falcon Propagation: A Manual on Captive Breeding*. The Peregrine Fund, Inc.
- WHEELER, C. L. (1993). Herpesvirus disease in raptors: a review of the literature. In: *Raptor Biomedicine* (P. T. Redig, J. E. Cooper, J. D. Remple and D. B. Hunter, eds), pp. 103–7. University of Minnesota Press.

---

# Cranes

Glenn H. Olsen

## Introduction

In North America there are two species of cranes; the highly endangered whooping crane (*Grus americana*), numbering less than 450 birds, and the sandhill crane (*G. canadensis*). Sandhill cranes are divided into six subspecies in North America, which include the migratory greater (*G. c. tabida*), lesser (*G. c. canadensis*) and Canadian (*G. c. rowani*) sandhill cranes and the non-migratory Florida (*G. c. pratensis*), Mississippi (*G. c. pulla*) and Cuban (*G. c. nesiotus*) sandhill cranes. The latter two subspecies are both listed as endangered. Cranes are found not only in North America, but also in Africa, Europe, Asia and Australia. World-wide there are 15 species of cranes, and nine are considered endangered.

## Biology and Husbandry

Cranes are tall (over 1 m for sandhill cranes, and 1.25 m for whooping cranes), heavy-bodied birds (up to 6 kg for sandhill cranes and 7 kg for whooping cranes) with large wing spans (2 m for sandhill cranes and 2.5 m for whooping cranes). One characteristic that sets cranes apart from herons and egrets is that many crane species have bright-red thick skin with an irregular surface covering parts of their head and neck. With whooping cranes and sandhill cranes, the red skin covers the top of the head (Plate 20), and the size of the patch can be varied to reflect behavioural aspects of dominance or submissiveness. Using bright antibiotic sprays (such as furazolidone) on the head or neck can adversely affect a crane's acceptance by others of its species. Another distinguishing characteristic between cranes and herons or egrets is that cranes fly with the

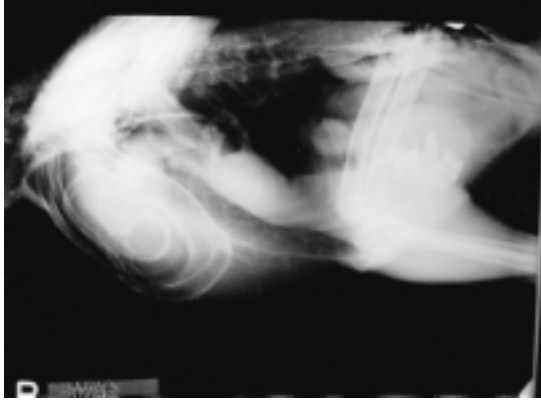
neck extended straight ahead, while herons and egrets fly with the neck held in a half circle and the head held back towards the body.

Crane feather coloration is generally grey or white for most species, with some cranes having areas of black or even brown coloration. Newly hatched chicks are covered with tan to brown down. Later they will have primarily tan to brown coloured feathers before moulting into adult plumage during the first year. A few crane species maintain some tan juvenile feathers into their second year. Cranes carry their tertiary wing feathers fluffed up over their rump.

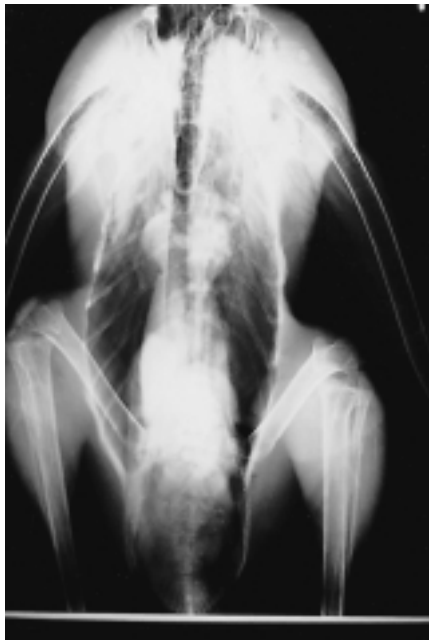Cranes have a long convoluted trachea that makes a loop within the sternum (Figure 9.1). This tracheal shape, similar to some brass musical instruments such as the trombone, makes it possible for cranes to produce a loud bugling call. Cranes share this tracheal characteristic only with swans (*Cygninae*). The looping trachea can lead to the build-up of mucus or fluids at certain points, resulting in severe dyspnoea. Some cranes, such as whooping cranes, also have a tracheal stenosis that may have a genetic basis. Because of the looping anatomy of the trachea in cranes, any tracheal flushes should be used with extreme caution.

## Handling/restraint

Cranes can be large, aggressive birds. In addition to a long, pointed beak, they have extremely sharp toenails, capable of slicing through the clothing or skin of the unwary handler. However, with the use of proper techniques even the larger species can be restrained safely. The best method of capturing a crane in an enclosure is to herd the bird into a corner of the pen. When the crane's head is orientated toward the fence, move forward,



(a)



(b)

**Figure 9.1** Dorso-ventral and lateral radiographs of a crane. The lateral view shows the convoluted loops of the trachea found within the sternum.

grasping the secondary and tertiary flight feathers of both wings with one hand to control the bird's ability to extend its wings. Move the other arm over the crane's body, keeping the crane's head pointed toward the rear of the handler (Figure 9.2). Grasp the legs at or just above the hocks and prevent the hocks from rubbing together by placing one or two fingers between the hocks (Figure 9.3). Now the bird is lifted and tucked under the arm of the handler.



**Figure 9.2** Catching a crane by grasping the tertiary feathers to restrain the wings and then reaching around the crane's body with the free hand to hold the legs at the hocks.

Once the crane's wings are restrained by the upper arm of the handler, the hand holding the tertiary feathers is free and can be moved around the handler's back to grasp the head of an aggressive crane (Figure 9.4). An alternative holding method moves the hand on the tertiaries down to the hock position, and the hand on the hocks moves up under the sternum to give additional support to the crane (Figure 9.5). Safety glasses or goggles should be worn by handlers.

## Anaesthesia

Cranes have been successfully anaesthetized with ketamine/xylazine (10–15 mg/kg ketamine, 1 mg/kg xylazine) or ketamine/diazepam (10–15 mg ketamine, 0.2–0.5 mg/kg diazepam) combinations. Once the injection is given, the crane should be held until anaesthetized to prevent injury when the bird



**Figure 9.3** Technique used to hold a crane's legs, using a finger to separate the hocks and prevent rubbing injuries.



**Figure 9.4** A normal handling position for an aggressive crane. The handler's right arm restrains the wings, while the hand grasps the legs at the hocks. The left hand is placed behind the handler's back and controls the crane's head.



**Figure 9.5** An alternative crane-holding position, with the right arm restraining the crane's wings and the right hand supporting the sternum. The left hand holds the legs at the hocks.



begins to lose its balance. Likewise, the crane needs to be held during recovery until it can stand and move without falling. Because of these requirements and the time involved, injectable agents are now used primarily in field situations whereas gaseous anaesthetic agents are used for most captive procedures.

Isoflurane is currently the gas anaesthetic of choice for most procedures requiring general anaesthesia. An appropriate facemask to accommodate the long beak of the crane can be made using a 60 ml plastic syringe case. After induction (at 4–5 per cent), the crane can be intubated and maintained at 1–3 per cent isoflurane and an oxygen flow of 1–2 l/min.

For tranquillization, diazepam at 0.5–1.0 mg/kg works well and lasts 4–6 h. The desirable dose for procedures such as shipping agitated cranes should be low enough to prevent loss of balance, but high enough to calm the bird. Local anaesthetics (lidocaine 0.5 ml, xylocaine 0.5 ml, or bupivacaine up to 2 mg/kg) can be infiltrated into areas for minor procedures such as wound suturing. Local anaesthetic agents may also be applied to surgery sites to reduce pain after recovery from general anaesthesia.

## Blood collection

The three most common sites for blood collection in cranes are the right jugular, the medial metatarsal or brachial veins. The feathers overlying the jugular and brachial veins can be wetted with isopropyl alcohol and the vein held off proximal to the desired withdrawal site. A large volume (up to 50 cm<sup>3</sup> for transfusions) can be obtained from the jugular vein rather quickly. However, if the crane struggles extensively – or the person assisting in holding the head fails to hold it firmly – the needle may lacerate the jugular vein, potentially leading to death of the crane. However, this is a very rare complication of jugular venepuncture. Using the medial tarsal or brachial/ulnar veins requires further restraint of the wing or leg, and there is an increased risk of a limb injury. A severe long bone fracture in a crane can lead to the loss of the crane due to frequently seen complications (Olsen, 1994). Normal blood values for North American cranes are listed in Table 9.1.

Injection sites are similar to those for most birds. The pectoral muscles are the recom-

**Table 9.1** Normal reported mean blood values for cranes (Olsen *et al.*, 1996a; Olsen and Carpenter, 1997)

	<i>Whooping crane</i>	<i>Sandhill crane</i>	<i>Siberian crane</i>	<i>Red-crowned crane</i>	<i>Wattled crane</i>
Haematocrit (%)	42	43	45	39	45
Haemoglobin (g/dl)	14.4	13.5	–	–	–
Red blood cells (10 <sup>6</sup> /mm <sup>3</sup> )	2.2	2.5	–	–	–
White blood cells (10 <sup>3</sup> /mm <sup>3</sup> )	13.4	17.0	10.8	14.9	12.7
Heterophils (%)	53	56	53	41	48
Lymphocytes (%)	40	41	39	48	39
Monocytes (%)	6	2	3	6	5
Eosinophils (%)	2	1	5	5	8
Total protein (g/dl)	3.8	3.9	3.6	3.3	3.1
Albumin (g/dl)	1.5	1.5	1.4	1.2	1.1
Globulin (g/dl)	2.3	2.3	2.3	2.1	2.0
A/G ratio	0.7	0.7	0.6	0.6	0.6
Glucose (mg/dl)	232	247	266	267	266
Uric acid (mg/dl)	8.1	9.7	9.0	7.8	7.7
Creatinine (mg/dl)	0.6	0.7	0.3	0.3	0.4
Cholesterol (mg/dl)	148	128	212	170	147
Aspartate aminotransferase (iu/l)	261	181	182	208	189
Lactic dehydrogenase (iu/l)	440	278	202	288	137
Alkaline phosphatase (iu/l)	46	164	45	226	37
Calcium (mg/dl)	9.1	9.7	10.5	10.8	10.8
Phosphorus (mg/dl)	2.8	3.6	3.8	3.5	2.7
Sodium (mmol/l)	147	148	149	148	146
Chloride (mmol/l)	107	108	109	107	108
Potassium (mmol/l)	3.4	3.4	2.9	2.8	3.2

mended sites for intramuscular injections. Subcutaneous injections can be given in a number of sites, but are often administered over the lateral thigh.

## Metabolic and nutritional disorders

High protein diets (32 per cent protein) fed to Florida sandhill and greater sandhill crane chicks resulted in increased rate of growth as compared to a lower protein diet (24 per cent protein) (Serafin, 1982). However, in the larger and faster-growing greater sandhill cranes there was a 17 per cent rate of leg deformities and 25 per cent rate of wing deformities on the 32 per cent protein diet during the period of rapid growth between days 7 and 28 post-hatch. The abnormalities seen in rapidly growing crane chicks include deformities in the proximal ends of the tibiotarsus and tarsometatarsus, the distal end of the tibiotarsus, and the intertarsal and tibiofemoral joints, due to weak legs being unable to support the rapid weight gain possible in this species. Likewise, rapid wing growth on a high protein diet leads to twisting deformities at the carpal joint, although this condition will respond to restraining the wings against the body in a normal folded position to prevent a permanent deformity. Usually restraint is needed only for a short period (48 h). Young whooping cranes are also subject to similar limb deformities (Kepler, 1978), and it is thought that any of the larger crane species that breed in temperate climates can potentially be subject to similar problems (Serafin, 1982).

Diets that promote slower growth of crane chicks are recommended. Using a 24 per cent protein diet with a low (0.73 per cent) sulphur amino-acid level slows crane growth sufficiently to reduce limb deformities. If the weight gain continuously exceeds 10 per cent daily in crane chicks during the critical 7–28-day age period, further management techniques such as food withholding for several hours are used to help slow growth (Wellinton *et al.*, 1996).

## Infectious diseases

### Viral diseases

Viral diseases such as avian pox and Newcastle disease, which occur in most species of birds, also occur in cranes. Two unique viral diseases have proved to be potential problems identified in captive cranes maintained in North America; eastern equine encephalitis and inclusion body disease of cranes.

#### *Eastern equine encephalitis (EEE)*

Eastern equine encephalitis (EEE) virus is found in the eastern USA and south-eastern Canada, the Caribbean and Central and South America. Most native birds are not infected themselves, but rather act as reservoirs for the potentially lethal spread of this disease to horses, other avian species or humans. The virus is transmitted by the ornithophilic mosquito *Culiseta melanura*, which breeds in wooded swamps. Whooping cranes (Dein *et al.*, 1986) and Mississippi sandhill cranes (Young *et al.*, 1996) are both susceptible to this virus.

Vaccination programmes for EEE, using commercially available equine vaccine or a formalin-inactivated human EEE vaccine, have been developed (Clark *et al.*, 1987) and used successfully in whooping cranes (Pagac *et al.*, 1992; Olsen *et al.*, 1997). Cranes are initially vaccinated with 0.5 ml<sup>3</sup> of formalin-inactivated human EEE vaccine in late July of their hatch year, then have a second injection of 1.0 ml<sup>3</sup> 3–4 weeks later. A similar schedule may be used with other EEE vaccines. Annual boosters are required to maintain titre levels and are again given in July or early August, as the mosquito activity and potential spread of EEE is greatest in late summer and fall (Pagac *et al.*, 1992). The vaccination programme has proved effective in preventing further losses of whooping cranes due to EEE when known virus-carrying mosquitoes were trapped in the area (Olsen *et al.*, 1997).

#### *Inclusion body disease of cranes (IBDC)*

This is a viral disease that causes lethargy and loss of appetite for 48 hours followed by diarrhoea (sometimes haemorrhagic diarrhoea) and death, and was first identified

in 1978 (Doeherty, 1987). A previously unknown herpesvirus was isolated as the causative agent. Mortality has occurred in blue cranes (*Anthopoides paradisea*), sandhill cranes (*G. canadensis*), red-crowned cranes (*G. japonensis*) and hooded cranes (*G. monacha*). Antibodies have been detected in sandhill cranes, blue cranes, hooded cranes, sarus cranes (*G. antigone*), European cranes (*G. g. grus*), red-crowned cranes (*G. japonensis*), demoiselle cranes (*Anthopoides virgo*) and East African crowned cranes (*Balearica regulorum gibbericeps*). All these cranes were captive, and all but the sandhill cranes were Old World species. In sampling 95 wild greater sandhill cranes in Wisconsin and Indiana, none of the birds had antibodies to the virus (Doeherty, 1987).

Gross pathological lesions include an enlarged liver and spleen with small (pinpoint to pinhead) yellowish-white lesions, and haemorrhage is seen in the thymus and intestines. Cranes that died did so acutely, as fat stores in the subcutaneous tissues were still abundant (Doeherty, 1987). Diagnosis is by viral isolation from affected organs, usually from the liver or spleen. In addition, on histopathology there are intranuclear inclusion bodies seen in tissues from the liver and spleen that are characteristic of IBDC (Doeherty, 1987).

There is no known treatment or vaccine for IBDC at the present time. The presence of antibodies in some captive cranes indicates that some birds survive exposure to the virus and may have some protection. Indeed, cranes surviving the initial infection may become carriers, spreading the disease to other cranes. However, the exact mechanism for transmission is unknown at this time, although there appears to be no transmission through the eggs (Doeherty, 1987). The antibody response seen in some cranes lasts for several years, and these birds may be considered potential carriers. A control programme is in place at many crane-keeping institutions; this includes testing all cranes periodically for antibody titres and removing or isolating any positive birds. Because the disease is apparently not found in wild North American cranes, it is of utmost importance to keep any potential carriers isolated from wild birds and to test all cranes scheduled for release to the wild.

### **Bacterial diseases**

Most common avian bacterial pathogens have been isolated from cranes, including *Pasteurella multocida*, *Mycobacterium avium*, *M. tuberculosis*, *Salmonella* spp., *Clostridium* spp., *Erysipelothrix* spp., *E. coli*, *Streptococcus* spp. and *Staphylococcus* spp. The pathogenesis varies; *E. coli* can be a normal gastrointestinal isolate, but can also cause severe diarrhoea, dehydration and death in some young chicks. Various *Salmonella* spp. have been found on culturing normal healthy cranes, but salmonellosis was also diagnosed as the cause of disease in at least one crane chick. The chick had diarrhoea, no weight gain, and was dehydrated and lethargic. Supportive care and appropriate antibiotic therapy resulted in complete recovery.

### **Avian tuberculosis**

*M. avium* has contributed to the death of some wild whooping cranes. One 5-year-old wild whooping crane found debilitated had a large, palpable, mid-coelomic mass, and a chronic cloacal prolapse with a mass 2 cm in diameter within the prolapsed cloacal tissues (Snyder, 1996). Radiographs also revealed splenomegaly. Removal and biopsy of the cloacal mass showed coalescing granulomata with necrotic centres and macrophage zones, and the necrotic centres contained rod-shaped acid-fast staining bacteria. *Mycobacterium avium* was isolated from the mass, and confirmed with a DNA-specific probe. The crane was treated with rifampin (45 mg/kg, once daily, Rifadin, Marion Merrill Dow, Inc.) and ethambutol (30 mg/kg, once daily, Myambutol, Lederle), both given for 1 year. Isoniazid (Isoniazid USP, Rugby Laboratories) was added at 30 mg/kg once daily to the treatment regimen on two occasions, but discontinued because the crane became anorectic both times. Two doses of *M. vaccae* antigen (0.05 ml) were given intradermally 8 weeks apart (Snyder, 1996).

About 10 months after discontinuing the antitubercular therapy, recrudescence was suspected, based on radiographic findings, weight loss and elevated WBC (Snyder, 1996). *M. avium* was not isolated on faecal culture. However, the crane was treated with azithromycin (Pfizer Laboratories, Inc.) 20 mg/kg once daily in food, later increased to 40 mg/kg.

The improvement in the bird during the 16-week course of treatment was described as dramatic (Snyder, 1996). However, later treatment with a combination of azithromycin and ethambutol produced a fatal adverse reaction. At the time of necropsy, no *M. avium* was isolated (Snyder, 1996).

### **Fungal diseases**

#### *Candida* spp.

*Candida* spp. has been isolated on occasion from the beak or mouth of a crane, often following an initial injury. Treatment with a topical nystatin cream has proved successful.

#### *Aspergillosis*

Aspergillosis is a serious respiratory pathogen, especially in chicks and debilitated adult birds suffering from other disease or injuries. *Aspergillus* spp. (usually *A. fumigatus*) have caused the death of many cranes, some as young as 9 days old. During the last 2 years, a treatment regime developed at the Patuxent Wildlife Research Center and based on earlier work with raptors (Joseph *et al.*, 1994) has resulted in a high success rate and return to normal function for the cranes treated. The treatment regime consisted of oral itraconazole given at the dose rate of 10 mg/kg p.o. q12h. Itraconazole comes as a capsule containing small granules, and there are approximately 285–290 granules in each 100 mg capsule; hence each granule averages 0.35 mg. The appropriate number of granules is therefore counted out and mixed with food to be given to the crane. A cleaned smelt works well for this, as the granules can be sprinkled inside the fish, and most cranes will eat small fish readily if trained to do so. In addition to oral itraconazole, enrofloxacin is given either by i.m. injection or (more frequently) orally, at a dose of 15 mg/kg q12h, to combat secondary bacterial invaders.

Each crane is also nebulized with clotrimazole 10 mg/ml in polyethylene glycol (Island Pharmacy Services, Woodruff, Wisconsin). The patient is placed in a small cage (tall enough to allow the crane to stand and wide enough to turn around). The clotrimazole (3–5 ml) is placed in an ‘up-mist’ medication nebulizer (cat. no. HK8955, Metropolitan Medical, Inc., Sterling, Virginia), and the

nebulizer is connected to an oxygen source. A flow rate of 5–8 l/min is required to achieve proper nebulization. Each bird is nebulized for 20 minutes three times daily (1 h in total per day).

The combination of itraconazole/enrofloxacin orally plus clotrimazole nebulization has been used successfully for 2 years now on several species of cranes. Usually a minimum period of treatment is 2 weeks, but if some symptoms are still present nebulization is continued for an additional week and oral itraconazole for an additional 2 weeks. To date, all but one crane treated in the above manner recovered. The one crane that died was a young chick, and it died less than 24 hours after initiating therapy. Itraconazole has been reported as possibly being toxic if used concurrently with clotrimazole (Carpenter *et al.*, 1996), but no toxicity problems have been seen in cranes given this treatment.

#### *Mycotoxins*

Mycotoxins produced as secondary metabolites of fungal moulds (primarily *Fusarium graminearum*) on corn and other crops have proved troublesome to cranes, and at least two cases of large-scale natural mortality in wild cranes have been attributed to mycotoxins (Roffe *et al.*, 1989; Windingstad *et al.*, 1989). In 1987, an epizootic in captive cranes in Maryland caused illness in 240 of 300 cranes and the death of 15 of these cranes (including two whooping cranes and two endangered Mississippi sandhill cranes) (Olsen *et al.*, 1995). Clinical signs were non-specific, and included weakness, necrosis of mucous membranes of the mouth or tongue, depression and dehydration, followed by ataxia, recumbency and death. Gross pathological findings were also inconclusive, consisting of dehydration, atrophy of fat, renal insufficiency and small spleens. Further research isolated *Fusarium* spp. mould from constituents of the pelleted diet and low levels of two mycotoxins, T<sub>2</sub> (1–2 ppm) and deoxynivalenol (0.4 ppm). Testing of all grain-based feeds prior to feeding to cranes is recommended to prevent such problems.

### **Parasitic diseases**

Parasites are often opportunistic and are clinically significant where cranes are stressed

or crowded, especially when kept in captivity. Clinical signs of parasitism can be very non-specific, and may include lethargy, weight loss, enteritis or dyspnoea. In the captive situation, a parasite monitoring and treatment programme is important for raising and maintaining healthy cranes. Reducing crowding and other stress factors, plus annual pen rotation and treatment of new birds during quarantine, can result in a relatively parasite-free flock.

Gapeworms (*Syngamus* spp. and *Cyathostoma* spp.) can cause severe tracheitis, bronchitis, dyspnoea and even death associated with mucus plugs forming in the trachea. Diagnosis can occasionally be made by observing the gapeworms in the upper trachea, or by tracheal washes. Fenbendazole given at 100 mg/kg p.o. once daily for 5 days has proved effective in eliminating the parasite in infected cranes (Olsen *et al.*, 1996a).

*Capillaria* spp., *Eucoleus* spp. and *Ascaridia* spp. all infect cranes, leading to weakness, lethargy, weight loss and, occasionally, enteritis. Diagnosis is easily made by faecal flotation. Treatment with a combination of fenbendazole 100 mg/kg p.o. and 0.2 mg/kg ivermectin s.c. or p.o., both given once and then repeated in 1–2 weeks, has proved effective in eliminating these common parasites (Olsen *et al.*, 1996a).

Acanthocephalans (spiny-headed worms) infest cranes and can produce a perforation of the intestines, resulting in a peritonitis that is often fatal. The condition is more commonly seen in crane chicks than in adults. The earthworm (*Lumbricus* spp.) is the most common intermediate host, and raising cranes indoors with no exposure to natural soil until they are fledgings may help to control this parasite. No effective treatment is known; controlling exposure is therefore of primary importance.

Cranes are especially susceptible to coccidial infections caused by *Eimeria gruis* and *E. reichenowi*. In both sandhill and whooping cranes, the coccidia are found in the intestines and are widespread in the other organs (Carpenter *et al.*, 1980, 1984; Novilla *et al.*, 1989). Because of this extra-intestinal pathological development, the disease is called disseminated visceral coccidiosis (DVC). In DVC, granulomatous nodules form in various tissues, and symptoms consistent with such

conditions as hepatitis, pneumonia, tracheitis, myocarditis or enteritis can be seen. The disease is most severe in chicks under 60 days of age, and can often be fatal. Characteristic white nodules are seen in the various tissues on necropsy.

Even though coccidia are found in wild cranes, the disease is much more of a problem in the captive situation due to husbandry practices that can lead to a concentration of coccidia in the soil. Yearly or even every third year (three pens per group of cranes) pen rotation helps to reduce coccidia concentrations. In addition, various food and water additives have proved useful in controlling DVC. These include amprolium (0.006 per cent in drinking water or 0.0125–0.025 mg/kg in feed) or monensin (90 ppm in feed) (Carpenter *et al.*, 1992).

Ectoparasites are seen on both captive and wild cranes. Five species of mites (order Acarina) and four species of biting lice (order Mallophaga) have been documented (Forrester *et al.*, 1976; Atyeo and Windingstad, 1979). Severe cases of ectoparasites, especially in chicks, can be debilitating. Control is achieved by dusting cranes with 5 per cent carbaryl or 0.10 per cent pyrethrin powders. Biting and stinging insects, including bees (*Apis* spp.), wasps (*Vepis* spp.), black flies (*Simulium* spp.) and deer flies (*Chrysops* spp.), will attack cranes, causing localized inflammation of the skin, excessive preening, discomfort and stress. Occasionally the mucous membranes in the mouth will be swollen if the crane tries to capture the insect and is stung in the process. This is a common occurrence in chicks around fledging age.

## Orthopaedic problems

Because cranes are large, long-legged birds that grow very rapidly initially, they are subject to a number of different orthopaedic problems at various stages in their lives. Orthopaedic problems can be serious and even fatal, due to complications seen with fractures. At the International Crane Foundation in Baraboo, Wisconsin, fractures and subsequent complications were listed as the cause of death of 10 per cent (n = 11) of all mortalities (Hartman, 1983). At the Patuxent Wildlife Research Center in Laurel, Maryland, fractures and complications contributed to 4 per cent (n = 5) of the deaths of

captive Mississippi sandhill cranes (*Grus canadensis pulla*) (Olsen and Gee, 1996) and 5 per cent (n = 5) of mortalities in captive whooping cranes (*Grus americana*) in a 14-year period (Olsen *et al.*, 1996b). Fractures in older birds are often associated with capture, handling and transport, and handlers should be careful to hold cranes in such a manner as to prevent or reduce orthopaedic injuries (Figures 9.2–9.5).

### Paediatric orthopaedics

Injuries and deformities in chicks are different from those seen in adult cranes. Fractures in birds less than 1 year of age commonly occur during the first four months, with 32 per cent of all fractures in young birds noted in the age range of 9–12 weeks, and 64 per cent occurring during the period of 5–16 weeks of age (Olsen, 1994). The high incidence of fractures during this period coincides with the period of open epiphyseal plates – closure of the epiphyseal plates takes place at 10–14 weeks. Crane chicks reared by artificial (hand-rearing) means have more orthopaedic problems than crane chicks raised by parent birds, and one possible reason for this may be the reduced levels of exercise

seen in the hand-reared chicks. Parent-raised birds spend most of their day walking behind or near parent birds.

Nutrition definitely plays an important role in raising healthy crane chicks. Although the specific nutrient requirements of cranes are not completely known, three diets for cranes of different age/breeding status have been formulated at the Patuxent Wildlife Research Center (Table 9.2) and are commercially produced (Ziegler Bros. Inc., P.O. Box 95, Garners, Pennsylvania). Chicks are normally fed the Starter diet until after fledging, and once the birds have fledged a Maintainer diet is provided. The Starter diet is higher in calcium and protein than the Maintainer (and the Breeder diet is still higher in calcium and only slightly lower in protein than the Starter diet).

Experimentally, diets containing higher levels of protein (32 per cent) and 1.13 per cent sulphur-containing amino acids had a 25 per cent incidence of wing disorders and 17 per cent incidence of leg disorders in one study (Serafin, 1982). The disorders were primarily weak and deformed proximal tibiotarsus, tarsometatarsus and distal tibiotarsus, all the typical sites for fractures in young birds.

**Table 9.2** Composition of the diets for crane chicks (Starter), non-breeding adults (Maintainer), and breeding adults (Breeder) (Swengel and Carpenter, 1996; Olsen and Carpenter, 1997)

<i>Ingredient/nutrient</i>	<i>Starter</i>	<i>Maintainer</i>	<i>Breeder</i>
Protein (%)	23.8	19.4	20.5
Metabolizable energy (kcal/kg)	2689	2530	2533
Calcium (%)	1.4	1.0	2.45
Phosphorus (%)	0.90	0.86	0.89
Methionine and cystine (%)	0.70	–	–
Lysine (%)	1.30	–	–
Ground yellow corn (%)	24.4	38.8	41.2
Soybean meal (44% protein) (%)	–	13.1	15.0
Soybean meal (49% protein) (%)	31.5	–	–
Wheat middlings (%)	12.0	12.6	10.0
Fish meal (60% protein) (%)	–	4.0	5.0
Ground oats (%)	11.5	15.7	7.5
Meal and bone meal (%)	–	5.2	4.0
Alfalfa meal (17% protein) (%)	5.0	5.2	5.0
Corn distiller's solubles (%)	3.0	–	1.5
Brewers dried yeast (%)	2.5	–	2.0
Corn oil (%)	3.3	–	–
Dried whey (%)	1.2	3.2	3.5
Limestone (%)	1.5	0.5	3.5
Dicalcium phosphate (%)	3.0	0.5	1.0
Iodized salt (%)	0.25	0.5	0.5
Vitamin/mineral premix (%)	0.5	0.5	0.5

Greater sandhill crane chicks fed a diet of 24 per cent protein and 0.73 per cent sulphur-containing amino acids had only a 2.5 per cent incidence of leg disorders (Serafin, 1980). Similarly, wing development is also affected by diet. Greater sandhill crane chicks raised on a diet containing 24 per cent protein and 0.87 per cent sulphur-containing amino acids had a 16 per cent rate of wing deformities (primarily rotation of metacarpals seen at the stage when feathers are developing). Crane chicks on a diet of 24 per cent protein and 0.73–0.78 per cent sulphur-containing amino acids had only a 5 per cent rate of such wing deformities, and those deformities that occurred were correctable with bandaging.

There are several orthopaedic problems seen post-hatching that appear unrelated to diet. Improper incubation techniques or exposure to slippery surfaces early in life may contribute to a condition resulting in splay-leg (a lateral deviation of one or both legs.) Normal chicks walk with the legs parallel to each other and the central toe of each foot pointed forward. Lateral deviations that occur can often be corrected by placing temporary hobbles on the legs (Figure 9.6). Hobbles are used intermittently over a period of 24–48 hours, and chicks must be monitored closely to ensure that they tolerate the hobbles.

Curled toes are another frequently seen problem. The problem seems to occur more commonly in crane chicks raised indoors by humans as compared to crane chicks reared by parent birds in a natural (grass-covered) enclosure. The problem may be related to



**Figure 9.6** Whooping crane (*Grus americana*) chick with splay leg syndrome corrected by the use of temporary hobbles made of adhesive tape. Hobbles are removed every 24 hours (or less) to evaluate progress.

decreased exercise or to improper substrate. The problem is usually correctable by using a small coaptation splint for 48 hours. The splint can be made out of something as simple as a round wooden applicator stick cut to length and taped to the outside curve of the deviated toe. A low-tack adhesive tape such as filament or packing tape works well, but ordinary adhesive tape sticks to the young chick's skin too well and is difficult to remove. Because of the rapid growth seen in young crane chicks, the splints should be removed after 48 hours and the leg allowed to rest, usually for 24 hours, before another splint (if needed) is applied. Occasionally a curled toe is seen in an older chick. The same theory of splinting the leg is appropriate; however, two wooden applicator sticks will be needed on each side of the toe.

Fractures in chicks under 5 weeks of age are very rare because the bones are so cartilaginous at this stage. Those fractures that do occur are often 'greenstick' fractures. Leg fractures predominate at this age, and coaptation splints work well to allow the bone to heal. The splint may have to be changed every 4–7 days, as the chicks grow very rapidly. Usually the bone heals in a minimal time, and the splint may be removed in as little as 3 weeks. Wing-bone fractures at a young age often cause severe disruption of the normal growth pattern, and the outcome is often a permanently crippled bird.

### Adult orthopaedics

Many of the fractures and orthopaedic injuries that occur in other species in general are a problem in cranes. Figure-of-eight bandages have been used successfully to treat fractures of the wing below the elbow. However, if additional stabilization is required, then intramedullary (IM) pins and external skeletal fixation (ESF) are used, with the techniques being the same as with most avian orthopaedics (Olsen, 1994; Olsen *et al.*, 2000). Fractures of the femur usually require IM pinning. Historically, wing fractures in captive cranes respond favourably to treatment. In one study, all cranes treated for wing fractures had a successful outcome (the fracture healed; however, as these were all captive birds, the full flight function of the fractured wings was never tested) (Olsen, 1994).

Orthopaedic problems in the pelvic limb have a more guarded prognosis because of the crane's reliance on two functional legs to survive. Any severe injury to a pelvic limb that renders the crane unable to stand may cause it to struggle excessively, to the point where it becomes exhausted or injures the bones of the other leg or wings. Repair of the fractured bone can be accomplished using standard orthopaedic techniques such as coaptation splints, IM pins or ESF, with the goal being for the crane to stand immediately after the surgery. If, however, the crane is unable to stand after the surgical repair is completed, it may be necessary to place the bird in a temporary sling. These have been constructed using a framework of PVC water pipes to support a heavy fabric sling (Olsen *et al.*, 1996a). Any crane placed in such a sling must be monitored carefully to determine how well the bird will tolerate the device. Giving small doses of a tranquilizer such as diazepam (0.5 mg/kg) may help during this adjustment period.

Joint luxations are rarely seen in cranes. Elbow luxations can be reduced if found early; however, there is a high probability of reduced function of the affected joint after such an incident. The author has seen two cases of coxofemoral luxation in cranes, and in both cases the luxation could not be reduced and maintained in a normal position. Surgery to remove the femoral head and neck was very successful in one case, but in the second case the crane never returned to a normal gait. This was possibly related more to the severe muscle damage that had occurred in the area than to the luxation itself and the subsequent surgery.

One serious complication occasionally noted in cranes is necrosis of the leg when a fracture occurs below the hock. There is very little soft tissue in this area, and any trauma can result in ischaemia. However, it is possible to amputate the leg at or just above the fracture site and build a prosthetic leg for the crane. The prosthesis can be made from a thin-walled PVC pipe 2.54 cm in diameter, with an inside diameter of 2.38 cm. The prosthesis is held onto the stump of the leg using adhesive tape, which is usually wrapped up around the hock to avoid slipping. The tape and the prosthesis must be changed every 30–60 days. One Mississippi sandhill crane lived for 20 years with such a device (Olsen, 1994).

## Neoplasia

Neoplasms are generally very rare in most crane species, and those reported include renal carcinoma and adenocarcinomas (Montali, 1977; Decker and Hruska, 1978), lymphocytic and granulocytic leukaemias (Montali, 1977; Wei, 1986) and metastatic cholangiocarcinoma (Allen *et al.*, 1985). There has been a high incidence of adenocarcinoma in the wild population of Mississippi sandhill cranes, with no corresponding cases seen in captive flocks of this species.

## Capture myopathy

Capture myopathy (also called exertional myopathy or exertional rhabdomyolysis) occurs in some wild animals after capture or restraint. The condition is not often reported in birds, but it does occur with some frequency in cranes. Reported cases have occurred in East African crowned cranes (*Balearica rugelorum gibbericeps*) (Brannian *et al.*, 1981), greater sandhill cranes (Windingstad *et al.*, 1983) and Mississippi sandhill cranes (Carpenter *et al.*, 1979). The presenting signs include pain on movement, stiff movements, swollen hard muscles, trauma to limbs associated with struggling, and peracute death from cardiac failure. One diagnostic aid is to find high serum concentrations of creatinine kinase, lactic dehydrogenase and aspartate aminotransferase (Windingstad *et al.*, 1983). If the crane does not succumb immediately to cardiac failure, the kidneys may fail due to increased myoglobinuria, uric acid production or dehydration associated with inability to move properly. Prevention of capture myopathy is important, and can be accomplished by minimal and proper handling of all cranes. Treatment is supportive; intravenous fluids, corticosteroids, antibiotics, vitamin E and selenium, and sodium bicarbonate (4–6 mmol/kg) for acidosis (Olsen and Carpenter, 1997).

## Intraspecific aggression

The leading cause of trauma in cranes is intraspecific aggression. At Patuxent Wildlife Research Center, 7.3 per cent of whooping



crane deaths over a 15-year period were caused by intraspecific aggression. This aggression is often associated with the formation of pair bonds in the spring (breeding season), and it is occasionally seen with dominance hierarchy formation in a group of cranes. The latter often occurs when a new crane is moved into a pen, and it is recommended that a new social unit (pair or group) should be formed in a pen new to all the cranes to decrease the possibility of intraspecific aggression. If this is not possible, the next best scenario is to introduce the new crane into an adjacent pen until the established cranes have the opportunity to accept it. The third type of aggression that occurs among cranes is termed 'divorce', and is seen when an established pair begins fighting. In spite of the ornithology books stating that cranes mate for life, not all pair bonds last this long.

Aggression is usually directed toward the head and neck, causing extensive soft tissue injuries and even skull fractures. The crane losing the engagement is often in deep shock when presented. Treatment consists of corticosteroids (dexamethasone 4–8 mg/kg or prednisolone sodium succinate 30 mg/kg intravenously), intravenous lactated Ringer's solution, and antibiotics. Radiographs and any extensive wound treatment are performed after the crane is stabilized. One result of aggression to the head is permanent scarring of the red skin on top of the head. The crane should never be reintroduced into the same social grouping.

## References

- ALLEN, J. L., MARTIN, H. D. and CROWLEY, A. M. (1985). Metastatic cholangiocarcinoma in a Florida sandhill crane. *J. Am. Vet. Med. Assoc.*, **187**, 1215.
- ATYEO, W. T. and WINDINGSTAD, R. M. (1979). Feather mites of the greater sandhill crane. *J. Parasitology*, **65**, 650–58.
- BRANNIAN, R. E., GRAHM, G. L. and CRESWELL, J. (1981). Restraint associated myopathy in East African crowned cranes. In: *Proc. Am. Assoc. Zoo Vet.* (M. E. Fowler, ed.), pp. 21–3. American Association of 200 Veterinarians.
- CARPENTER, J. W., THOMAS, J. J. and REEVERS, S. (1979). Capture myopathy in an endangered sandhill crane (*Grus canadensis tabida*). *J. Zoo Wildlife Med.*, **22**, 488–93.
- CARPENTER, J. W., SPRAKER, T. R. and NOVILLA, M. N. (1980). Disseminated visceral coccidiosis in whooping cranes. *J. Am. Vet. Med. Assoc.*, **177**, 845–8.
- CARPENTER, J. W., NOVILLA, M. N., FAYER, R. *et al.* (1984). Disseminated visceral coccidiosis in Sandhill Cranes. *J. Am. Vet. Med. Assoc.*, **185**, 1342–6.
- CARPENTER, J. W., NOVILLA, M. N. and HATFIELD, J. S. (1992). The safety and physiologic effects of the anticoccidial drugs monensin and clazuril in sandhill cranes (*Grus canadensis*). *J. Zoo Wildlife Med.*, **23**, 214–21.
- CARPENTER, J. W., MASHIMA, T. Y. and RUIPIPER, D. J. (1996). *Exotic Animal Formulary*. Greystone Publications.
- CLARK, G. C., DEIN, F. J., CRABBS, C. L. *et al.* (1987). Antibody response of sandhill and whooping cranes to an eastern equine encephalitis virus vaccine. *J. Wildlife Dis.*, **23**, 539–44.
- DECKER, R. A. and HRUSKA, J. C. (1978). Renal adenocarcinoma in a sarus crane (*Grus antigone*). *J. Zoo Animal Med.*, **9**, 15.
- DEIN, F. J., CARPENTER, J. W., CLARK, G. C. *et al.* (1986). Mortality of captive whooping cranes caused by eastern equine encephalitis virus. *J. Am. Vet. Med. Assoc.*, **189**, 1006–10.
- DOHERTY, D. E. (1987). Inclusion body disease of cranes. In: *Field Guide to Wildlife Diseases* (M. Friend, ed.), pp. 129–34. US Dept. Interior Fish and Wildlife Service.
- FORRESTER, D. J., WHITE, F. H. and SIMPSON, C. F. (1976). Parasites and diseases of sandhill cranes in Florida. In: *Proc. Int. Crane Workshop* (J. C. Lewis, ed.), pp. 284–90. Oklahoma State University.
- HARTMAN, L. M. (1983). Summary of mortality of 14 species of cranes at the International Crane Foundation, 1972–1982. In: *Proc. Int. Crane Workshop* (G. W. Archibald and R. F. Pasquier, eds.), pp. 555–70. International Crane Foundation.
- JOSEPH, V., PAPPAGIANIS, D. and REAVILL, D. R. (1994). Clotrimazole nebulization for the treatment of respiratory aspergillosis. In: *Proc. Assoc. Avian Vet.* (M. J. Kornelgen, ed.), pp. 301–6. Association of Avian Veterinarians.
- KEPLER, C. B. (1978). Captive propagation of whooping cranes: a behavioral approach. In: *Endangered Birds: Management Techniques for Preserving Threatened Species* (S. A. Temple, ed.), pp. 231–41. University of Wisconsin Press.
- MONTALI, R. J. (1977). An overview of tumors in zoo animals. *J. Am. Vet. Med. Assoc.*, **171**, 531.
- NOVILLA, M. N., CARPENTER, J. W., JEFFERS, T. K. *et al.* (1989). Pulmonary lesions in disseminated visceral coccidiosis of sandhill and whooping cranes. *J. Wildlife Dis.*, **25**, 527–32.
- OLSEN, G. H. (1994). Orthopedics in cranes: pediatrics and adults. *Sem. Avian Exotic Pet Med.*, **3**, 73–80.
- OLSEN, G. H. and CARPENTER, J. W. (1997). Cranes. In: *Avian Medicine and Surgery* (R. B. Altman, S. L. Clubb, G. M. Dorrestein and K. Quesenberry, eds), pp. 973–91. W. B. Saunders.
- OLSEN, G. H. and GEE, G. F. (1996). Causes of Mississippi sandhill crane mortality in captivity, 1984–1995. *Proc. North Am. Crane Workshop*, **7**, 249–52.
- OLSEN, G. H., CARPENTER, J. W., GEE, G. F. *et al.* (1995). Mycotoxin-induced disease in captive whooping cranes

- (*Grus americana*) and sandhill cranes (*Grus canadensis*). *J. Zoo Wildlife Med.*, **26**, 569–76.
- OLSEN, G. H., CARPENTER, J. W. and LANGENBERG, J. A. (1996a). Medicine and surgery. In: *Cranes, Their Biology, Husbandry, and Conservation* (D. H. Ellis, G. F. Gee and C. M. Mirande, eds), pp. 137–74. US Dept. of Interior.
- OLSEN, G. H., TAYLOR, J. A. and GEE, G. F. (1996b). Whooping crane mortality at Patuxent Wildlife Research Center, 1982–1995. *Proc. North Am. Crane Workshop*, **7**, 243–8.
- OLSEN, G. H., TURELL, M. J. and PAGAC, B. B. (1997). Efficacy of eastern equine encephalitis immunization in whooping cranes. *J. Wildlife Dis.*, **33**, 312–15.
- OLSEN, G. H., REDIG, P. T. and OROSZ, S. E. (2000). Limb dysfunction. In: *Manual of Avian Medicine* (G. H. Olsen and S. E. Orosz, eds), pp. 493–526. Mosby Inc.
- PAGAC, B. B., TURELL, M. J. and OLSEN, G. H. (1992). Eastern equine encephalomyelitis virus and *Culieta melanura* activity at the Patuxent Wildlife Research Center, 1985–1990. *J. Am. Mosquito Control Assoc.*, **8**, 328–30.
- ROFFE, T. J., STROUD, R. K. and WINDINGSTAD, R. M. (1989). Suspected fusariummycotoxicosis in sandhill cranes (*Grus canadensis*): clinical and pathological findings. *Avian Dis.*, **33**, 451–7.
- SERAFIN, J. A. (1980). Influence of dietary energy and sulfur amino acid levels upon growth and development of young sandhill cranes. In: *Proc. Am. Assoc. Zoo Vet.*, p. 30. American Association of Zoo Veterinarians.
- SERAFIN, J. A. (1982). The influence of diet composition upon growth and development of sandhill cranes. *Condor*, **84**, 427–34.
- SNYDER, S. B. (1996). Avian tuberculosis in a whooping crane: treatment and outcome. *Proc. North Am. Crane Workshop*, **7**, 253–5.
- SWENGEL, S. R. and CARPENTER, J. W. (1996). General husbandry. In: *Cranes, Their Biology, Husbandry, and Conservation* (D. H. Ellis, G. F. Gee and C. M. Mirande, eds), pp. 31–43. US Dept. of Interior.
- WELLINGTON, M., BURKE, A., NICOLICH, J. M. and O'MALLEY, K. (1996). Chick rearing. In: *Cranes, Their Biology, Husbandry, and Conservation* (D. H. Ellis, G. F. Gee and C. M. Mirande, eds), pp. 77–104. US Dept. of Interior.
- WEI, Y. C. (1986). Three cases of granulocytic leukemia in the red-crested crane. *Chin. J. Zoology*, **21**, 32–3.
- WINDINGSTAD, R. M., HURLEY, S. S. and SILEO, L. (1983). Capture myopathy in a free-flying greater sandhill crane (*Grus canadensis tabida*) from Wisconsin. *J. Wildlife Dis.*, **19**, 289–90.
- WINDINGSTAD, R. M., RICHARD, J. C., NELSON, P. E. *et al.* (1989). Fusarium mycotoxins from peanuts suspected as a cause of sandhill crane mortality. *J. Wildlife Dis.*, **25**, 38–46.
- YOUNG, L. A., CITINO, S. B., SECCARECCIA, V. *et al.* (1996). Eastern equine encephalitis in an exotic avian collection. In: *Proceedings of the Association of Avian Veterinarians* (J. LaBonde, ed.), pp. 163–5. Association of Avian Veterinarians.

# Ratites

*Thomas N. Tully, Jr.*

## Introduction

Ratites are classified into four different orders and five families. The common ratite species include ostriches, emus, rheas, cassowaries and kiwis. Ratites are native to most of the continents and a few large islands of the southern hemisphere (ostriches in Africa, rheas in South America, emus in Australia, cassowaries in Australia and New Guinea, kiwis in New Zealand; see Chapter 16). The birds are similar in being flightless, but each one is a different avian species with diverse physiological and anatomical features.

Historically ratites have been very popular animals in zoological collections, but recently there has been a world-wide interest in farming these birds. South Africa has been the major exporter of ostrich products and a leading ostrich producer for over 100 years. Ostriches are native to South Africa, thereby giving farmers the advantage of proper environmental conditions for optimum production. The South African farmer alone has maintained this market and generated a demand for ostrich skin and meat, but other countries have now seen the potential of ratites (including emus and rheas) as an alternative livestock commodity that can thrive in small unproductive areas of farm or ranch land. Currently, ratite producers around the world are working to develop a niche for the meat, hide and by-products of these avian species.

## Anatomical features

This chapter will focus on the two ratite species commonly raised for production purposes; the emu and the ostrich. It will include some information regarding the rhea, but the

number of rheas being raised in captivity at this time is relatively small.

The ostrich averages 2.5–3 m in height, and weighs approximately 150 kg. The emu averages 1.7 m in height and weighs about 45 kg. The male ostrich is larger on average than the female, while the female emu is generally larger than the male. Ratites as a group receive their name from their sternum, which is devoid of a keel. The sternum in flighted birds has a prominent keel from which the large pectoral muscles originate, but ratites do not need the large pectoral muscles to fly and therefore do not need a keel. Since ratites do not have large pectoral muscles, the injection sites of choice are the epaxial muscles or the large upper leg muscles.

One of the most medically significant differences between ostriches, emus and rheas concerns their digestive tracts (Table 10.1). The variations manifest themselves in common gastrointestinal disorders, especially in mismanaged ostriches. Ostriches and rheas primarily utilize their hindgut to digest their food, and animals that primarily use their caudal intestinal tract to digest food take a long period of time for the passage of digesta. The average length of time for the passage of digesta through the gastrointestinal tract is 48 hours in an ostrich, 18 hours in a rhea and 7 hours in an emu. The long period of time that is noted in

**Table 10.1** Comparative length of ratite intestines (cm) (Fowler, 1996)

Rights were not granted to include this table in electronic media.  
Please refer to the printed publication.

the ostrich predisposes these birds to impaction problems and colic, whereas emus rarely develop a gastrointestinal blockage or impaction due to mismanagement or stress. The ostrich's digestive system does however appear to benefit the producer raising the birds for a profit, as feed conversion is better with longer transit times than with shorter times.

Ostrich, rhea and emu males have protruding phalluses (Plate 21). All ratites are monomorphic when hatched and at birth, and vent or DNA blood sexing and feather colour characteristics may be used to sex the young birds. It does help to have experience in sexing young ratites, and the veterinarian's skill will increase with such experience.

## Husbandry

### Nutrition

Ratite species are typically omnivores, but the birds can live on just about any diet formulated for any animal. To achieve reproductive success and fast market growth, species-specific diets are required – ostrich food for ostriches, emu food for emus, breeder food for breeders, and growth diets for young birds. The nutritional requirements are simple; for success, feed a formulated diet.

Young birds require growth diets, but if they eat too much too fast they may develop musculoskeletal leg abnormalities (Plate 22). These abnormalities include rotation of the tibiotarsal bone and angular limb deformities. Once young ratites develop leg abnormalities, it is very difficult to treat the problem. Young birds should have exercise, access to grass and regulated feed intake.

### Restraint

Ratites (especially ostriches, emus and rheas) are very dangerous to handle, and it is important that veterinarians respect their ratite patients and use proper restraint techniques to examine and treat them. Experienced handlers should be the only people around adult ratites that are being captured.

Young ostrich and emu chicks should be supported in a sternal position with the legs

tucked under the bird in the arms of the handler, thereby reducing their struggles (Raines, 1998). Young birds should never be carried upside down by the legs because of susceptibility of musculoskeletal damage. Ostriches of any age can be sedated by 'hooding' – placing a cloth bag or sleeve over the bird's eyes. For larger birds, the handler may wear a sweatshirt sleeve that can be removed once the beak is captured, and placed over the bird's head. Young birds can be transported in large pet carriers that have substrates with traction to prevent leg injuries.

Juvenile and adult birds are captured and restrained in a similar manner. Emus should be captured by using a swing gate or by running the birds into a narrow chute. Once the bird is captured the holder should stay behind it, using one hand to grab the chest and resting the other on the dorsum of the back. Adult emus are strong, and kick hard and high. Using emu wings as handles may be effective, but these vestigial wings fracture easily during restraint and, although not life threatening, the wing fractures affect the general appearance of the bird. It is important that handlers always stay behind captured ratites, to protect both themselves and the birds. Ostriches are very big and may be aggressive during the breeding season. A head hook has been manufactured to aid in moving and capturing ostriches quickly, and is extremely useful. This hook may cause injury, as an ostrich's first instinct when captured is to back up; if the head is pulled at the same time, muscle damage may occur. Ostriches may be captured in appropriate catch pens or chutes by grabbing the head with a hook or the hands. If the head is controlled, then the animal is controlled. A bird with its head captured will back up in order to kick forward, and the bird should therefore be led by the head with one or two people pushing from behind.

Large ratites should be transported in a well-maintained stock trailer that provides adequate ventilation. Surfaces within the trailer must provide enough traction to prevent injury due to slippage.

### Sedation

Once restrained, large aggressive birds have to be sedated with chemical agents (Table

**Table 10.2** Tranquillizer/sedative dosages used in ratites (Cornick-Seahorn, 1996)

Rights were not granted to include this table in electronic media. Please refer to the printed publication.

**Table 10.3** Ratite normal physiological values (Cornick-Seahorn, 1996)

Rights were not granted to include this table in electronic media. Please refer to the printed publication.



**Figure 10.1** The right jugular vein is the recommended site for intravenous catheter placement.

10.2). The patient's vital signs should be monitored throughout the procedure if sedatives are used as an adjunct to restraint (Table 10.3). Ratites should be fasted for 12 hours if there is a planned anaesthetic procedure (Cornick-Seahorn, 1996). There are three main venous access locations in ostriches; the right jugular, the basilic and the medial tarsometatarsal veins (Figure 10.1). Emus do not have an adequate basilic vein for blood collection or catheter placement.

If the birds have to be placed under general anaesthesia, isoflurane is the agent of choice. Isoflurane is used at 4.0–5.0 per cent for induction, and the birds are maintained at 2.0–3.0 per cent (Cornick-Seahorn, 1996). A circle rebreathing system is used for birds over 7 kg, and respiration must be monitored closely because of the respiratory depressive effects of isoflurane.

## Health examinations

Veterinary communication and information is critical whether evaluating a single ratite or a flock. It is more likely today that veterinarians will be called for flock management at production units, and, as with many large agricultural ventures, money is made or lost on a very small margin. This small margin means that all areas are open for examination and improvement. When evaluating a ratite facility, the following factors are important criteria relating to production, health and growth: pen size; number of birds per pen; shelter; pen construction (durability); access to feed and water; pen topography; environment surrounding the pen; and stress associated with the surrounding environment (Tully, 1998). Birds should not be placed in

overcrowded pens or in pens with birds that are not of the same age and/or size. Overcrowding and mismatching of birds results in injuries and in poor growth and reproduction. Good management of the production facility means good bird health.

Prior to or during a physical examination, a veterinarian will benefit from taking a proper history regarding the bird in question. The following questions should be answerable by a ratite owner if the facility is being correctly managed (Tully, 1998):

- 1 How long have you owned the bird or cared for it at this facility?
- 2 Has the bird been recently transported?
- 3 Has the bird had previous problems, treatments or vaccinations?
- 4 Is the animal properly identified with proper papers (health certificate, interstate/international transfer, microchip certificate)?
- 5 What is the health status and history of the flock or farm, including past disease problems and deaths?
- 6 What is the previous history concerning congenital abnormalities, medication and surgery?
- 7 What is the sex and reproductive status of the animal?
- 8 How long has the patient been ill?
- 9 Has this bird (or any other) been examined by another veterinarian?
- 10 What food is available, and what does the bird consume?
- 11 What type of water is used (well or city supply)?
- 12 Have any pesticides or poisons been used around the cage?
- 13 Is there a quarantine procedure in place?

Once the bird has been captured and restrained, a 'hands-on' physical examination can take place. The bird should be evaluated from the tip of the beak to the tail. A symmetrical head and beak is normal, and any deviation must be examined more closely to determine the cause of the problem. The ocular examination should include conjunctival, corneal, retinal and anterior and posterior chamber examinations (Tully, 1998), and the dehydration status of the bird may be determined through the ocular examination by globe placement in the orbit and hydration of the cornea. Palpation and exam-

**Table 10.4** Young ratite diseases

Hatching birds	Malposition/improper incubation Iatrogenic drug/supplement toxicity Yolk sac infection/retention
Musculoskeletal disorders	Neck deformities at hatch Tumbling chick syndrome in emus Spraddle leg Angular leg deformities Rickets Osteochondrosis Rolled toes in ostriches Slipped gastrocnemius tendon
Gastrointestinal disease	Impaction Intussusception Intestinal torsion Cloacal prolapse

ination of the skin and feathers may reveal healed injuries, lacerations, abscesses or tumours (Tully, 1998). The left ventral aspect of the ostrich body cavity, caudal to the keel, should be palpated for proventricular impactions; if enlarged, gastrointestinal problems may be present (Tully, 1998). Wings and legs should be examined for developmental abnormalities, joint swellings, trauma and fractures. Toes should have normal placement and not be 'rolled', a common ostrich developmental abnormality where the toes deviate to the point where the medial or lateral surface of the digit contacts the ground. This is a potentially life-threatening injury if not corrected early in life (Plate 23).

Ratites less than 1 year of age have a number of developmental problems because of their rapid growth and dependence on legs for mobility after hatching (Table 10.4).

The veterinarian must advise the ratite owner that, if any bird dies of unknown circumstances, a necropsy examination is recommended. To have a proper necropsy examination performed by a pathologist usually takes 10–12 days, and the sooner an animal is examined the quicker the owner will receive the results. There are a number of infectious diseases that affect ostriches, emus and rheas (Table 10.5). Once the veterinarian makes a correct diagnosis regarding an infectious disease, the proper management and treatment can be initiated to prevent further loss (Tables 10.6, 10.7).

**Table 10.5** Ratite infectious diseases and parasites (Shane, 1998)

<i>System</i>	<i>Disease</i>	<i>Treatment</i>
Respiratory	Mycoplasmosis – prevent through adequate biosecurity and quarantine of new birds	Tylosin or a fluoroquinolone
	<i>Coryza</i> ( <i>Haemophilus</i> spp.) – prevent through biosecurity	Trimethoprim-sulfa or penicillin
	Aspergillosis – prevent through hygiene and proper management	Itraconazole
	Respiratory helminths ( <i>Syngamus</i> spp., <i>Cyanthostoma</i> spp.)	Ivermectin, fenbendazole or mebendazole
Gastrointestinal	Salmonellosis – prevent through biosecurity and management to reduce transmission	Fluoroquinolone
	Campylobacteriosis – prevent by chlorinating water supply	Erythromycin
	Clostridial enteritis	Zinc bacitracin
	Necrotizing typhlocolitis of rheas – prevent through proper management	Metronidazole combined with parenteral lincomycin
	Viral enteritidis – prevent through biosecurity	No treatment
	Zygomycosis	Ketoconazole or nystatin
	Candidiasis	Nystatin in combination with fluconazole
	Endoparasites	
	● <i>Libiostrongylus douglassii</i>	Ivermectin, fenbendazole and levamozole
	● <i>Trichostrongylus tenuis</i> , <i>Houttuynia struthionis</i>	Praziquantel
Integument	Pox	Supportive care
	Dermatomycosis – prevent through biosecurity and hygiene	Griseofulvin in drinking water
	Ectoparasites	Carbaryl (Sevin) dust (3–5%)
Systemic	Anthrax	No treatment
	Erysipelas	Parenteral penicillin or fluoroquinolone antibiotics
	Tuberculosis – prevent by disposing of affected birds	None recommended
	<i>Chlamydia psittaci</i>	Doxycycline
	Pasteurellosis – prevent through high level biosecurity	Tetracyclines in drinking water
	Colibacillosis – prevent through chlorinated water	Fluoroquinolone antibiotics
	Viscerotropic eastern equine encephalitis – prevent with vaccine	
	Avian influenza	None recommended for highly pathogenic strains
	Adenovirus	None
	Central nervous system	Western equine encephalitis – prevent with vaccine
Newcastle disease – prevent with vaccine or, if Newcastle-free, quarantine		Isolation and support
Borna disease – prevent with inactivated vaccine		Hyperimmune serum
Baylisascaris encephalitis – prevent by reducing exposure to intermediate host		No treatment
Chandlerella encephalitis – prevent through ivermectin treatment at the susceptible age (< 1 year)		No treatment

**Table 10.6** Ostrich blood values (Fudge, 1995)

Rights were not granted to include this table in electronic media.  
Please refer to the printed publication.

**Table 10.7** Emu blood values (Fudge, 1995)

Rights were not granted to include this table in electronic media.  
Please refer to the printed publication.

## Treatment

Ratite production facilities are getting larger in size and are holding more birds (Plate 24).

The emphasis on production has reduced the need for ratite surgery. Although not often performed at present, surgical techniques are based mainly on large animal and equine procedures. As the ratite producers intensify and integrate production, there will be a continuing need for veterinary care and expertise.

## References

- CORNICK-SEAHORN, J. L. (1996). Anesthesiology of ratites. In: *Ratite Management, Medicine and Surgery* (T. N. Tully and S. M. Shane, eds), pp. 79–93. Krieger Publishing Co, Malabar, FL.
- FOWLER, M. E. (1996). Clinical anatomy of ratites. In: *Ratite Management, Medicine and Surgery* (T. N. Tully and S. M. Shane, eds), pp. 1–10. Krieger Publishing Co, Malabar, FL.
- FUDGE, A. (1995). *Ratite Reference Ranges*. Californian Avian Laboratory, Citrus Heights, CA.
- RAINES, A. M. (1998). Restraint and housing of ratites. *Vet. Clin. North Am.*, **14**(3), 387–99.
- SHANE, S. M. (1998). Infectious diseases and parasites of ratites. *Vet. Clin. North Am.*, **14**(3), 455–83.
- TULLY, T. N. (1998). Health examinations and clinical diagnostic procedures of ratites. *Vet. Clin. North Am.*, **14**(3), 401–19.



# Waterfowl

*Andy Routh and Stephanie Sanderson*

## Introduction

The term waterfowl is generally used to refer to those waterbirds of the family *Anatidae* (ducks, geese and swans). These taxa occur throughout the world in a wide variety of aquatic habitats, and are commonly kept in zoological and ornamental collections as well as being the origin of the breeds kept commercially for agricultural purposes.

This family is diverse in anatomy, physiology and behaviour. The members are adapted to live in a wide range of habitats, usually (but not exclusively) associated with water. However, the majority of species are instantly recognizable as *Anatidae*, with their dense, waterproof plumage, webbed feet and short tarsometatarsi, which produce a waddling gait on land.

Typically, *Anatidae* moult twice a year; in winter they moult body and head feathers to acquire their breeding plumage. After the breeding season, in the summer, they undergo a full moult, including a simultaneous moult of the primary flight feathers. This is followed by a flightless period when birds are particularly vulnerable to predators until the primaries regrow. Many species will flock together on safe waters during this period. In sexually dimorphic ducks, the summer body feathers of the male are drab and resemble the female. This is called 'eclipse' plumage, and its non-descript nature may make identification more difficult. The winter moult of body feathers brings birds back into full breeding plumage.

## Taxonomy

The following taxonomy is according to Johnsguard (1978) and Livezey (1986), quoted in Madge and Burn (1988).

Taxonomically, waterfowl are classed as order *Anseriformes*, which contains three families:

- 1 The family *Anhimidae* (screamers) are gamefowl-like birds, and are not considered in this chapter
- 2 The family *Anseranatidae* contains only one species, the magpie goose
- 3 The family *Anatidae* contains the true waterfowl (ducks, geese and swans), and is divided into seven subfamilies.

### *Anseranatidae*

This family contains only one species, the magpie goose (*Anseranas semipalmata*). This is a unique goose, with some features linking the true wildfowl with the screamers (*Anhimidae*).

The goose has a long hind toe and half-webbed feet, which make perching in trees easy. There is a gradual moult progression and no flightless period. It breeds in trios of one male and two females. An elongated trachea forms subcutaneous coils over the pectoral muscles, enabling very low-pitched resonant call.

The magpie goose is native to tropical Australasia, and grazes on both land and in water. During the dry season it may travel long distances and form large flocks to find suitable grazing.

### *Anatidae*

These are true waterfowl, and there are seven subfamilies:

#### *Subfamily* Dendrocygini

This includes whistling ducks; for example the fulvous whistling duck (*Dendrocygna bicolor*).

These ducks are tropical waterfowl often referred to as tree ducks, although many of the species do not perch. They are typically long-legged, long-necked and short-bodied, and are equally at home on land or water. They are gregarious and form large flocks; they pair bond for life and are sexually monomorphic.

They range extensively across both tropics and four continents, and feed mainly on aquatic fringe vegetation, dabbling and up-ending in shallow water.

#### **Subfamily** Thalassorninae

This contains only one species; the white-backed duck (*Thalassornis leucotis*).

#### **Subfamily** Anserini

These are the swans and true geese. They are large, long-necked waterfowl and are typically monomorphic. Some species perform long migrations.

##### *Tribe* Anserini

These are the true geese; examples include the barnacle goose (*Branta leucopsis*). They are migratory, with three separate Arctic breeding populations, each with separate wintering grounds: the Greenland population winters in western Scotland and Ireland; the Svarlbad population winters in the Solway Firth in the Scottish Borders; and the Novaya Zembyla population winters in the Netherlands. They breed on islands and coastal cliffs, and have been reported to nest in association with gyrfalcons as protection against other predators. They graze on coastal grassland, with a strong preference for a short sward.

##### *Tribe* Cygnini

These are the swans, such as the mute swan (*Cygnus olor*). They are indigenous to Europe and Central Asia, and many populations derive from historical introductions and thrive in close association with man. They are gregarious except during the breeding season, when males are territorial and notoriously aggressive. Swans are found on a wide range of lakes; rivers and estuaries, and feed on waterweed within reach of their long neck, up-ending when necessary. They also graze on land.

#### **Subfamily** Stictinettinae

This includes the freckled duck (*Stictonetta naevosa*).

#### **Subfamily** Plectropterinae

This includes the spur-winged goose (*Plectropterus gambensis*).

#### **Subfamily** Tadorninae

This includes the shelducks and sheldgeese; for example, the shelduck (*Tadorna tadorna*). It is a large and varied subfamily, and all the members are equally at home in water or on land, some being mainly terrestrial. These birds are often seen as being intermediate between true geese and typical ducks.

They are widespread in Europe, and are large monomorphic ducks. They are gregarious, gathering into large flocks during the flightless period of the summer moult, and favour muddy estuaries where they filter-feed on algae and invertebrates in the mud. These birds usually feed by walking slowly forwards, swinging their heads from side to side through the surface layer, filtering food particles from the mud with their beak lamellae. They usually breed in old rabbit holes, and newly hatched chicks are then led to the water – often a considerable distance away. Chicks from a number of broods will form a crèche under the care of a few adults.

#### **Subfamily** Anatini

These are the ducks.

##### *Tribe* Anatini

*Anatini* are dabbling ducks, for example the mallard (*Anas platyrhynchos*).

This is a large tribe and contains most of the typical and familiar duck species. The ducks are typically strongly sexually dimorphic, with bright and attractive males; this, along with relatively undemanding husbandry requirements, makes this tribe popular in aviculture.

These are the most familiar ducks, and are the ancestors of most domestic breeds. They range throughout the Northern hemisphere, with several distinct races, and are found in a wide range of lowland habitats, including sheltered coasts. They become very tame in

parks and busy waterways, and mix freely with other species. Ducks feed by dabbling and up-ending in shallow water; they also graze and feed on stubble and root crop waste after harvest. They are mainly ground nesting, but will use a wide variety of other sites.

The perching ducks, for example the wood duck or Carolina duck (*Aix sponsa*), were formerly classified in a separate tribe, *Cairinini*. They are widely distributed on wooded lakes and marshes in North America, and elsewhere feral populations derived from escapees are common. They feed on aquatic vegetation by dabbling, but also graze on waterside grassland and are often seen standing in small groups on partially submerged branches or branches overhanging the water. They nest in holes in trees.

#### Tribe Aythini

This includes the pochards, for example, the canvasback (*Aythya valisineria*).

These are diving ducks with short, rounded bodies and are from freshwater habitats, although scaup are found coastally in the winter. The largest of the true pochards are widespread throughout North America, and are ducks of open marshes and estuarine lagoons. They feed on aquatic vegetation and invertebrates by diving, and favour relatively deep water. Nests are usually built floating in shallow water. These birds are sexually dimorphic.

#### Tribe Mergini

These are the sea ducks, and are mainly associated with coastal waters although some species are found on freshwater, especially during the breeding season. Most species have short, dumpy bodies with legs placed far caudally, and are ungainly on land, spending most of their time on water. Most species inhabit high latitudes, and have remarkably thick down to provide adequate insulation for an aquatic lifestyle in cold climates.

These birds are sometimes classified with other eiders of genera *Polysticta* and *Somateria* as a separate tribe; for example, the common eider (*Somateria mollissima*). They are widely distributed on northern coasts and estuaries. They are sexually dimorphic and, as full adult plumage is not attained until the third winter, there are many confusing intermediate plumages. They nest colonially on the ground,

usually on offshore islands, and line their nests thickly with down, 'eiderdown', which is still harvested commercially. These ducks feed on molluscs and invertebrates by diving.

Examples include the red breasted merganser (*Mergus serrator*), which is a long-bodied, long-necked duck with a long, thin, serrated 'sawbill' adapted for catching fish, and legs placed far caudally on the body, making it ungainly on land. It superficially resembles a grebe (*Podiceps* spp.) more than a typical duck, and is distributed throughout the Northern hemisphere, breeding close to water in rock crevices, burrows or tree holes. It is found on rivers, lakes and estuaries in the summer, but in the winter it generally remains on estuaries and the coast. It feeds by diving for fish.

#### Tribe Oxyurini

This includes the stiff-tailed ducks; for example, the ruddy duck (*Oxyura jamaicensis*).

These birds are freshwater diving ducks, although they are occasionally found on brackish water. They have short bodies with their legs placed far caudally, and large feet, making them ungainly on land. Their long, stiff tail feathers are typically held erect when resting on the water.

They are widely distributed in North and South America, and escapee feral populations in Europe threaten to hybridize with the endangered white-headed duck (*Oxyura leucocephala*).

The ruddy duck is a gregarious small duck that rarely leaves the water and nests at the water's edge, often on a floating platform of vegetation. It prefers to swim and dive rather than fly when threatened, although it migrates considerable distances. It is sexually dimorphic and feeds mainly by diving, on aquatic weed and invertebrates.

## Husbandry

### Housing

Wildfowl are one of the commonest exhibits in zoological collections. Many species are relatively tolerant of environmental conditions and thrive in overcrowded environments with highly contaminated land and water. Yet in a survey of deaths in a zoological collection,

waterfowl were the commonest fatalities, and bacteriological disease of environmental origin was the commonest cause of death (Kaneene *et al.*, 1985). Good management and disease control requires attention to all three media – air, land and water – that make up the captive environment.

### **Air**

Wildfowl may be kept flightless, either temporarily by cutting the flight feathers of one wing or permanently by surgical amputation of the terminal phalanx of one wing (pinioning). This removes the need for netting an airspace in the enclosure. However, wild birds are free to fly in and can act as vectors for a range of disease. Netted enclosures allow birds to be kept free flying. A soft, preferably knotless nylon mesh is durable yet unlikely to result in trauma to birds colliding with it.

### **Land**

Most enclosures consist mainly of earth and vegetation. Grazing species can gain a considerable proportion of their nutrition from well-managed grassland, and management of grazing follows the same principles as for domestic livestock. Overgrazing can result in poaching, and the sward can be overtaken by coarse unpalatable grass species. Unpalatable grass species are sometimes deliberately cultivated to provide a dense green covering to the enclosure which will not become overgrazed. Ova of nematode parasites *Amidostomum* spp., *Syngamus* spp. and *Cyathostoma* spp. can survive over winter, either on grass or in invertebrate transport hosts (earthworms), depending on their life cycle, and grazing cannot be considered clean unless it has been resown and rested for over 12 months. Juveniles grazing unclean areas are particularly at risk from parasitic infestation, and should be treated regularly with anthelmintics.

Trees and bushes can provide habitat variety, roosting sites, shelter and shade, but dense cover can produce damp, shaded areas where bacteria such as *Mycobacterium avium* can survive and build up high environmental contamination.

Natural pool surrounds are prone to erosion, whereas artificial surrounds such as stone or concrete with an abrasive finish can

predispose to foot trauma and pododermatitis. Swans and geese will peck at soil within reach from the water; therefore surrounds should be wider than the length of a bird's neck. Erosion at the junction between a pool surround and earth substrate will produce a damp, muddy area, and a suitable environment for the build-up of pathogenic bacteria such as *M. avium*.

In colder climates basic shelters can be provided for protection in winter, and tropical species may require supplementary heating.

### **Water**

Enclosed recirculating systems using sand filtration can be utilized, but the most commonly used systems depend on a through-flow of fresh water from a natural source. If there are a number of pools supplied from the same source, a parallel flow avoids spread of contamination or infection between pools. Before water flows back into a natural watercourse, measures should be taken to prevent environmental pollution. These measures can vary from simple sedimentation pools to modern reed-bed (*Phragmites* spp.) technology.

The required depth depends on the species kept; dabbling ducks favour shallow water, swans favour water of a depth equal to the length of their necks, and diving ducks require a depth of about 1 m.

## **Feeding**

### **Maintenance**

Dabbling ducks, geese and swans can be maintained on natural grazing and aquatic vegetation supplemented by grain. The contribution of naturally grown food will depend on climate and stocking density, and will vary with season. Wheat, barley or a mixed grain containing wheat, cracked maize, barley and oats can be used as a supplement. Alternatively, a proprietary pellet designed for maintenance can be used. Shell or limestone grit provides material for the grinding action of the gizzard and is a source of calcium.

Diving ducks can be fed on proprietary pellets designed for this purpose. Many

diving ducks such as eiders will adapt to eating grain and thrive well, although this is an unnatural diet.

Specialized fish eaters such as sawbills are best fed whole fish of a suitable size. Again, natural food may provide part of the diet.

### **Intensive care and convalescence**

Inappetent birds will need feeding by stomach tube. A mix suitable for all species, containing highly assimilable protein and high energy, is:

- 500 ml Lectade Plus (SmithKline Beecham) – oral rehydration fluid
- Two tins of A/D Diet (Hills Pet Nutrition) – a canine/feline convalescent diet
- 100 ml Ensure Plus (Abbott Laboratories) – a human liquid nutrition product
- ½ Aquavit (International Zoological Veterinary Group) – a vitamin supplement high in B1 and E
- One 200 mg ferrous sulphate tablet.

As a guide, a mallard should receive 60 ml b.i.d. and a mute swan 150 ml b.i.d.

Fully-grown wildfowl in rehabilitation will frequently be underweight, with a varying degree of emaciation and loss of muscle mass. A diet high in both protein and energy is desirable to promote the replacement of both muscle mass and fat reserves prior to release. For geese, swans and dabbling ducks, a mixture of grain (wheat is approximately 12 per cent protein) and poultry layers' pellets (17 per cent protein) provides a higher level of protein and energy and a source of vitamins, but contains no in-feed drugs. The high calcium content of the layers' pellets is offset by the low calcium-to-phosphorus ratio of the grain. The layers' pellets should not constitute more than 50 per cent of the diet by weight.

To tempt swans to eat, green food such as natural duckweed, chopped lettuce or other green vegetables should be offered. Swans will often also eat sprats or other small fish. Ducks will sometimes start feeding if offered softbill food or an 'insect mix'. Live food such as mealworms can tempt an inappetent duck.

Seaducks (not fish eaters) will eat chopped or whole oily fish such as sprats, shrimp or deshelled shellfish. Care must be taken because the fat from this diet can coat the lamellae of the beak and then be spread on the

feathers during preening, resulting in a loss of waterproofing. It is generally recommended that fish eaters should receive a supplement of 25 mg thiamin/kg of fish fed, but in practice this may not be necessary (see Chapter 15).

High fat and protein diets should be withdrawn once birds have gained adequate weight and body condition, and birds returned to a maintenance diet to avoid the potential for kidney damage and gout associated with excess protein intake, or obesity and fatty liver associated with excess energy intake.

## **Reproduction in Anseriformes**

### **Sexual maturity and breeding strategies**

Ducks become sexually mature at 1 year of age. As a group they are polygynous. In many species males will defend their mates until the start of incubation, but play no part in incubating and rearing the ducklings. Ducks show no mate loyalty.

Geese mature at about 2 years and swans at about 5 years. There is little morphological difference between the sexes and, unlike ducks, they show strong pair bonding, often pairing for life. The female is still exclusively responsible for incubating the eggs, but the male remains close by and defends the nest against predators. After hatching he will also aid in herding and brooding the young chicks.

Anseriformes copulate in water and exhibit a ritualized pre- and post-copulatory display. Most species show a marked change in behaviour during the breeding season, with many becoming highly aggressive both to each other and to other species. In ducks, severe feather picking and bruising along the neck and back ('rape' injuries) are common amongst both sexes. Females are sometimes drowned by mobs of rival males during mating.

Waterfowl have a wide range of preferred nesting sites; some nest in crevices, some in thick vegetation, some out in the open. There are also parasitic species, notably the redhead (*Aythya americana*), in which the female will sometimes lay in a host nest and show no parental care. Most species do not actively collect nest material, but merely pull anything

within reach round their preferred site and then line it with a thick layer of down (Humphreys, 1986).

Clutch size is generally inversely proportional to size – typically three to six eggs in geese and swans, and six to twelve or more in ducks. Females of smaller species tend to lay one egg a day, the larger species laying every other day, usually early in the morning. As the clutch size increases, the female spends more and more time on the nest. Incubation is generally around 25 days for ducks, 30 days for geese and 35 days for swans and muscovy ducks (*Cairina moschata*) (Forbes and Richardson, 1996). Hatching is synchronized by the acoustic stimuli of brood mates, and is usually complete within 16–24 hrs.

Wildfowl have nidifugous young; they are down-covered and capable of walking, swimming, diving and eating immediately after hatching. Maternal care consists of protection, brooding the young chicks and leading them between food, water and safety.

## Captive breeding

The following is intended as an overview of waterfowl breeding. There is a wealth of information on the subject, both published and available by consulting those active in the field.

### Group size and composition

Gregarious ducks will breed successfully in mixed species groups. Hybridization is a risk, and subspecies should not be kept together. Strongly territorial species such as swans require separate enclosures or very large areas to avoid inter- and intra-species aggression (Forbes and Richardson, 1996).

### Environment

Optimum breeding will occur when the individual species are provided with an environment similar to their natural habitat. For example, photoperiod is an important trigger for breeding in polar waterfowl, and this may require artificial light in lower latitudes (Humphreys, 1986).

Birds should be provided with suitable nest sites, free from disturbance and predators,

with nesting material readily available. Artificial islands with nest boxes are ideal.

### Artificial rearing

Most captive Anseriformes will be able to raise a brood successfully with minimal human intervention. Some active ducks will lose or exhaust their brood, and will benefit from being confined to small enclosures. Artificial incubation and rearing can potentially increase brood size and decrease losses due to predation and abandonment. The main disadvantages are that specialized equipment and expertise are required, and that there is a risk of imprinting.

### Egg collection and storage

By the regular removal of eggs, the hen can often be persuaded to lay more than normal clutch number. A dummy egg is left in the nest to encourage the hen to continue laying. However, hens should not be chased off the nest to allow egg collection, as they may not return to finish the clutch. In geese it is often more successful to wait until the clutch is completed and then to remove the eggs. Some keepers destroy the nests to induce a new lay.

Eggs are collected at one of two stages; either as soon as possible after laying, or after they have been 'set' (i.e. after the hen has incubated them for the first 5–7 days). The latter leads to increased fertility, but also to increased egg contamination. The eggshells of waterfowl are particularly porous, and the contents are easily invaded by pathogenic bacteria such as *Staphylococci* spp., *Salmonella* spp. and *Escherichia coli*, all common causes of foetal and neonatal death (Humphreys, 1986). Any cracked, grossly contaminated or deformed eggs should be discarded, and the remainder should be washed, dried and disinfected before storage. A variety of disinfection methods are currently used, including dipping in 1 per cent formalin, fumigation with potassium permanganate, and exposure to ultraviolet light. Eggs may be stored blunt end up at 15–21°C for up to 14 days before incubation (LaBonde, 1992).

### Incubation

Foster hens provide a simple method of incubation. This method requires the least

expertise, but runs the risk of disease transmission from the foster hens. It is important to remove the eggs at pipping to avoid imprinting and later problems with mate recognition.

There are many brands of incubator available commercially. Successful incubation requires accurate control of temperature and humidity and ease of sanitation. The exact requirements of different species vary, and experienced breeders can advise on optimum temperature and humidity. As a general guide, Humphreys (1986) found that incubating at 37.7°C and 50 per cent humidity until pipping and then transferring the eggs to a hatching incubator kept at 37.5°C and 70 per cent humidity produced good results.

Regular candling (viewing the contents of the egg via transmitted light) from the first week onwards is a useful procedure for assessing egg viability during incubation. It can help to identify causes of poor hatchability, and allows the prompt removal of cracked, infected and sterile eggs. Foetal death before 5 days is most likely to be due to faulty incubator temperature, jarring or inbreeding, whereas late deaths are often due to faulty temperature, humidity or turning (Forbes and Richardson, 1996). Deaths due to bacterial contamination at laying or during incubation can occur at any stage.

### *Brooding*

After hatching and drying, the young chicks should be transferred into brooder accommodation. The key factors in duckling rearing are good hygiene and the provision of a thermal gradient, which allows individuals to select their preferred temperature zone. This is usually achieved by the use of a heat lamp that can be raised and lowered as appropriate. As a guide, the heated area of the brooder accommodation should be 37.2°C (99°F) initially, lowered gradually over a period of 3 weeks to 21.1°C (70°F) or ambient temperature (Olsen, 1994). In temperate climates most ducklings can survive without artificial heat from 2 weeks of age; however, should the weather turn cold, heat should be provided (especially at night) until they have a complete covering of contour feathers.

As down feathers have an open structure lacking barbs or barbules, soiling of the plumage of newly hatched chicks rapidly results in failure of waterproofing. Access to

water then results in soaking and hypothermia. Chicks of dabbling ducks and geese can be kept away from water on a dry substrate until they have developed a full layer of contour feathers. Vinylized wire or plastic mesh, stippled rubber matting, synthetic turf, newspaper or wood shavings can be used as flooring. Hay and straw are a source of spores of *Aspergillus* spp., and should not be used. Use of poultry drinkers or a shallow dish filled with pebbles allows unrestricted access to water without allowing chicks to become soaked. Such chicks can be reared in simple unspecialized accommodation.

Species highly adapted to an aquatic lifestyle, such as stifftails, require access to water from an early age. Rearing such chicks is more difficult, and requires specialized facilities. An area of water must be provided which should have a constant flow, draining from the surface (surface skimming). A dry brooding area should consist of mesh or stippled rubber matting and be equipped with an overhead heat source. Food should be provided in containers that will not easily spill and contaminate the pen. Placing food containers directly over the surface drain ensures that all spilt food is immediately removed.

Food and water should be provided within 24 hours of hatching, although many birds will not start feeding for at least 48 hours. A starter crumb of about 20 per cent protein is suitable for most ducks during the first 2–3 weeks of life, after which a grower ration with 16 per cent protein can be used until 4–6 months of age. Swans and geese are predominately grazers and are adapted to a low protein diet; consequently cygnets and goslings are particularly prone to growth deformities exacerbated by excessive growth due to high protein rations. They should be restricted to a diet of 16 per cent protein or less, and provided with greens from hatching onwards.

Fostering young Anseriformes is possible, particularly in swans and geese. Cross-species fostering should be avoided because this may lead to imprinting and later problems with mate selection. Fostering must be done at the egg stage, as parents will usually kill a strange gosling or cygnet, even if introduced straight after hatching. Particular care should be taken to avoid cross-fostering polar and temperate species of swans, e.g. whooper swans (*Cygnus cygnus*) and mute swans (*Cygnus olor*), as the

former tend to brood their cygnets on land and the latter on their backs while still on the water. Whooper swan cygnets fostered onto mute swan parents will come out of the water when they wish to be brooded while the foster swan may stay on the water, resulting in the cygnets becoming fatally chilled.

## Conditions of neonate and growing waterfowl

### Chilling

Most young wild birds seen in general practice will be abandoned or orphaned and suffering from hypothermia and hypoglycaemia. Treatment is symptomatic. Olsen (1994) described a syndrome of death a few days after rewarming. The aetiology is poorly understood, but mortality may be decreased by the repeated use of high doses of rapidly metabolized steroids during initial stabilization.

### 'Starve out'

'Starve out' is a term coined by poultry pathologists to describe a condition where young birds fail to start to eat. It is one of the most common causes of neonatal death in artificially brooded waterfowl. Death typically occurs between 7 and 14 days after hatching. On postmortem the gastrointestinal tract is empty and contracted, the gall bladder is distended and the liver is shrunken and yellow. Hatchlings should not be expected to start eating for the first 24–48 hours, until their yolk sac is absorbed. If they remain inappetent, steps should be taken to encourage feeding. Some specialized species such as harlequin ducks (*Histrionicus histrionicus*) and scoters (*Melanitta* spp.) may be particularly difficult and require hand feeding for some time. Mimicking the conditions normally encountered by a wild hatchling seems to be very effective. Some of the stimuli used include:

- colour – yellow and green foods such as grass and crumbled boiled egg; yolk can be mixed with the food

- company – the presence of other ducklings, especially if already eating well
- physical stimuli – in the wild the young of off-the-ground cavity nesters such as mandarins and wood ducks would fall 20 m or more when first leaving the nest. Emulating this by tossing them into the air and letting them fall to the ground has been reported to stimulate feeding behaviour (Kear, 1986).

### Yolk sac problems

These fall into three inter-related categories; yolk sac retention, yolk sacculitis/omphophlebitis and yolk sac rupture.

#### *Yolk sac retention*

The yolk sac provides nourishment and a source of maternal immunoglobulin. Most of it is resorbed in the first week, and its presence beyond 2 weeks is considered abnormal. The aetiology and pathogenesis of yolk sac retention are unknown, and untreated birds will usually die. Clinical signs include abdominal distension, dyspnoea, exercise intolerance, inability to stand, inappetence and general failure to thrive. Surgical removal is the only effective treatment (Kenny and Cambre, 1992).

#### *Yolk sacculitis/omphophlebitis*

Yolk sacculitis and omphophlebitis are due to bacterial contamination of the umbilicus, either through damage to or excessive soiling of the egg or poor incubator and brooder sanitation. Low incubator humidity also seems to be associated with increased rates of infection (Olsen, 1994). The two conditions can occur concurrently or independently. Omphophlebitis is characterized by oedema and inflammation of the abdominal wall in the area of the umbilicus. An infected yolk sac is enlarged, hyperaemic, and contains brown or yellow coagulated yolk. Gram-negative bacteria such as *Salmonella* spp. and *E. coli* are the most common isolates. Treatment is generally impractical, but control by good hygiene and incubation techniques is effective.





**Figure 11.1** 'Angel Wing' deformity in a mute swan cygnet.

### Yolk sac rupture

Yolk sac rupture occurs either as a result of trauma in the first 2–3 days of life or secondary to yolk sac retention or infection. Rupture leads to shock and a rapidly fatal peritonitis. Treatment is generally impractical.

Other miscellaneous infectious diseases are discussed later in this chapter.

### Developmental/nutritional disease

Though more common in captive birds, developmental musculoskeletal disease is also seen in free-living birds (Figure 11.1; Table 11.1).

## Clinical techniques

In general, waterfowl are easy to handle, make good patients and are rewarding to treat. The basic principles of examination, clinical testing, imaging and nursing have been discussed in detail in previous chapters. The aim of this section is to mention only those aspects peculiar to waterfowl.

### Handling and restraint

Various equipment has been developed for the capture and restraint of large Anseriformes, notably the swan bag and hook (Figures 11.2, 11.3).

### Examination and radiology

Physical examination and survey radiography (Figures 11.4, 11.5) can be carried out using a combination of manual restraint, swan bags and light sandbags. For diagnostic radiography of the appendicular skeleton, general anaesthesia is recommended.

Features of radiographical anatomy peculiar to Anseriformes include the following:

- 1 The thoracic vertebrae are separate – they are not fused to form the notarium.

**Table 11.1** Common developmental syndromes of waterfowl (based on Olsen, 1994)

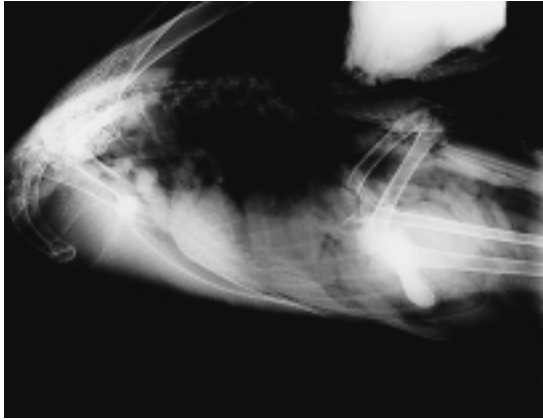
Condition	Pathogenesis/clinical signs	Comments and therapy
Valgus reverse (angel wing, or tilt, crooked, spear, slipped, healed over, sword, aeroplane or rotating wing)	Relative weight of rapidly growing flight feathers on a poorly mineralized skeleton produces excessive stress on the weak muscles of the carpal joint, leading first to drooping of the wing at the carpus and then, if untreated, to irreversible outward twisting, rendering the bird flightless	Proposed aetiology includes excessive growth rates induced by overfeeding and high protein diets (> 18%), vitamin D and E deficiency, manganese deficiency, genetic predisposition. Most common in <i>Anseriformes</i> with slow natural growth rates. Unknown in fast growing Arctic species such as the snow goose ( <i>Anser caerulescens</i> ). Taping the wing tip onto itself for 3–5 days may reverse angel wing during the early stages. Restrict feeding of slow-growing species. Encourage exercise (swimming, etc.)
Perosis (slipped tendon)	Cartilage deformity at hock joint leading to medial Achilles tendon luxation, swelling and non-weight bearing	High protein diet (> 18%), manganese deficiency, may be exacerbated by calcium supplementation. Splinting usually unsuccessful, swimming exercise and dietary restriction may be helpful during early stages, surgical correction possible



**Figure 11.2** Swan being released from a 'swan bag' – a simple rectangle of tough plastic which is wrapped around the bird and held with three strips of velcro.



**Figure 11.3** Use of swan hook. The head and neck are restrained with the hook for long enough for the wings to be restrained. Here the handler holds the humeri together over the back with one hand.

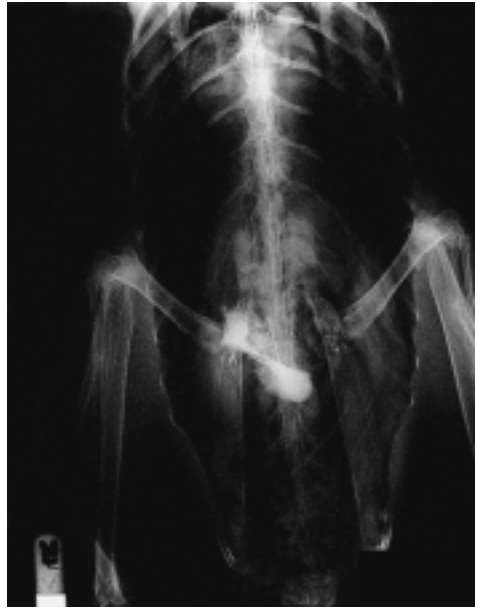

**Figure 11.4** A normal lateral radiograph of a mute swan.

- 2 Male ducks, with the exception of stifftails, have a syringeal bulla, which is seen radiographically at the thoracic inlet.
- 3 Trumpeter (*Cygnus buccinator*), whooper and Bewick (*Cygnus bewickii*) swans have a loop of their trachea coiled into an excavation in their sternum. This is often more prominent in the male (see Chapter 4).

## Anaesthesia

Waterfowl ingest large quantities of water whilst feeding, hence oesophageal reflux and subsequent inhalation is a significant danger during general anaesthesia. Starving for 2–6 hours before induction and the use of a well-fitting cuffed endotracheal tube significantly reduces the risks. Waterfowl also produce copious tracheal secretions during anaesthesia, which can block the tube, particularly in narrower gauges. Use of atropine leads to thickening of the secretions and is contraindicated. The anaesthetist should check the patency of the tube at regular intervals, and the authors suggest changing the tube every 20 minutes throughout the



**Figure 11.5** A dorso-ventral view of a mute swan. There is a small penetrating foreign body in the wall of the gizzard. This is a common incidental finding.

procedure. Removal of a minimum number of contour feathers during preparation for surgery will enable retention of a complete waterproof layer, and the bird will be ready for an early return to water.

Both injectable and volatile agents have been used successfully for induction in Anseriformes. Some of the more common injectable agents and their dose rates are listed in Table 11.2.

The authors' method of choice is to induce and maintain anaesthesia by inhalation of isoflurane. By creating a snug-fitting mask using a latex glove and a commercially produced face mask, it is possible to achieve smooth and rapid induction with minimal wastage and environmental contamination, factors for which mask induction is often criticized. Some authors comment that ducks, particularly diving ducks, are prone to breath-holding and are difficult to induce by gaseous agents alone, but the authors have not experienced this problem. If the use of a mask is unsuitable, then propafol (8 mg/kg) is the induction agent of choice.

Recovery should be in a quiet, dark environment, and extubation carried out when the

**Table 11.2** Injectable anaesthetic agents for waterfowl

<i>Agent</i>	<i>Dose</i>	<i>Route</i>	<i>Species</i>	<i>Comments</i>	<i>Reference</i>
Propofol	8.0 mg/kg	i.v.	Mute swan	Very short acting	Goulden (1995)
Alphaxolone/ alphadolone	4.2 mg/kg	i.v.	Mute swan	Coles (1997) believes this drug has been superseded in waterfowl by safer alternatives	Cooke (1995)
Ketamine + xylazine	12.5 mg/kg (7.2–24.0) + 0.28 mg/kg (0.16–0.53)	i.v.	Mute swan	Using a 9:1 mixture of ketamine:xylazine, the average swan dose is 1.0 ml. Used with less success in other species of waterfowl	Authors' unpublished data.
Medetomidine + ketamine	200 µg/kg + 10 mg/kg	i.m.	Waterfowl	Induction takes 2–3 minutes after i.m. injection	Coles (1997)
Diazepam + ketamine	1.0–1.5 mg/kg + 10–30 mg/kg	i.m. or i.v.	Avian – not specified	Smoother induction than with ketamine alone (see text)	Lawton (1996)

bird has regained voluntary control of its head and neck.

Analgesic agents for waterfowl are listed in Table 11.3.

### Venepuncture and fluid therapy

The medial metatarsal vein is particularly prominent in waterfowl, and is a convenient site both for routine venepuncture for blood collection (Tables 11.4, 11.5) and for the placement of indwelling catheters for fluid therapy.

### Sexing

Most adult ducks are sexually dimorphic. Even in monomorphic duck species, many adult males have 'drake feathers' – three feathers that curl forward from the tail. All Anseriformes can be accurately sexed by direct visualization of the phallus in males. The procedure is simple, and with practice can be used successfully even on young birds. The bird should be held with its head down between the knees of the person sexing the bird, so that the belly can be seen. By placing the thumbs on either side of the cloacal lips

**Table 11.3** Analgesic agents for waterfowl

<i>Agent</i>	<i>Dose</i>	<i>Route</i>	<i>Species</i>	<i>Comments</i>	<i>Reference</i>
Carprophen	4 mg/kg s.i.d.	s.c.	All waterfowl	Have used on three successive days	Authors' unpublished data
	2 mg/kg	i.m.	Not specified	Post-operative	Coles (1997)
	5–10 mg/kg	Not specified	Not specified	Proposed synergy when combined with buprenorphine	Lawton (1996)
Ketoprophen	1 mg/kg s.i.d.	i.m.	All waterfowl		Forbes and Harcourt-Brown (1997)
	1–10 days 5–10 mg/kg	i.m.	Not specified		Lawton (1996)
Flunixin	1 mg/kg s.i.d.	s.c.	All waterfowl	Have used on three successive days	Authors' unpublished data
	1–10 mg/kg	i.m.	Not specified		Lawton (1996)

Table 11.4 Haematology

Parameter	Unit	Mute swan (1)	Mallard (2)		Snow goose (3) (mean only; n = 10–14)	Canada goose (3) (mean only; n = 10–14)
			pre-remige moult (n = 7)	post-remige moult (n = 7)		
Total haemoglobin (Hb)	g/dl	10.6–16.1 (n = 18)	16.6–16.8	13.3–13.5	14.5	14.3
Red blood cell count (RBC)	10 <sup>12</sup> /l	1.85–2.76 (n = 18)	3.00–3.04	2.42–2.48	2.24	2.01
Packed cell volume (PCV)	l/l	0.350–0.500 (n = 18)	38.8–38.2	38.6–39.6	0.457	0.454
Mean cell volume (MCV)	fl	169.1–194.6 (n = 18)	126.5–128.5	159.4–161.6		
Mean cell haemoglobin (MCH)	pg	51.2–63.0 (n = 18)	55.0–55.6	54.2–56.2		
Mean cell haemoglobin concentration (MCHC)	g/gl	30.3–36.0 (n = 18)	43.2–43.6	33.9–34.5		
Total white cell count (WBC)	10 <sup>9</sup> /l	8.8–35.0 (n = 18)	26.0–27.0	6.8–7.5	20.1	20.8
Heterophil count	10 <sup>9</sup> /l	4.31–17.25 (n = 18)	12.8–13.8	2.4–2.8		
Lymphocyte count	10 <sup>9</sup> /l	0.66–19.25 (n = 18)	9.9–11.0	3.8–4.2		
Monocyte count	10 <sup>9</sup> /l	0.26–2.64 (n = 18)	0.5–0.6	0.1–0.1		
Eosinophil count	10 <sup>9</sup> /l	0.23–3.50 (n = 18)	0.8–1.1	0.3–0.4		
Fibrinogen	g/l	(n = 3)	13.6–17.0	11.9–14.3		

and exerting firm but gentle pressure downwards and outwards, the phallus can be everted. It may take some time to overcome the strong cloacal sphincter. Females have two small labia-like structures.

## Infectious diseases

Waterfowl are susceptible to a wide range of infectious diseases, and these are summarized in Table 11.6.

Some of the more significant diseases will be discussed below.

## Bacterial diseases

### Avian cholera

Avian cholera is an important disease responsible for annual die-off of thousands of over-wintering wild birds in North America.

Though present in Europe, it does not seem to cause such dramatic or frequent mortalities. It is caused by *Pasteurella multocida*, and Anseriformes are uniformly highly susceptible. The bacteria persists in carcasses for several weeks, and the disease will also affect scavengers (eagles, vultures and corvids). Transmission is by direct contact or environmental contamination. The bacteria is shed in vast quantities in the faeces and oronasal discharge of affected birds, and can persist for 3–4 weeks in water and up to 4 months in the soil (Olsen, 1994).

Clinical signs can vary from peracute death, where birds can literally 'fall out of the sky', to a chronic wasting disease sometimes seen in older birds and characterized by dyspnoea and diarrhoea. Most show the acute syndrome, with anorexia, profuse mucoid oronasal discharge, diarrhoea and loss of balance leading birds to walk or swim in circles. Birds dying peracutely often show no gross pathology. Those with the acute disease show pathology consistent with an

Table 11.5 Biochemistry

Parameter	Units	Mute swan	Mallard	
			pre-remige moult (n = 8)	post-remige moult (n = 7)
Urea	mmol/l	0.2–1.2 (n = 17)		
Sodium	mmol/l	135.9–144.6 (n = 17)		
Potassium	mmol/l	3.2–4.9 (n = 16)		
Total protein	g/l	42.7–52.8 (n = 17)	44.0–45.8	40.5–41.9
Albumin	g/l	14.9–20.0 (n = 17)	21.0–21.8	20.1–20.8
Globulin	g/l	25.7–34.7 (n = 17)		
Alb/glb ratio		0.43–0.68 (n = 17)		
Calcium	mmol/l	2.22–2.86 (n = 16)		
Inorganic phosphate	mmol/l	0.81–1.26 (n = 17)		
Urate	µmol/l	137.0–1444.0 (n = 17)	398.5–422.3	317.2–339.0
Alkaline phosphatase	iu/l		67.3–74.7	95.5–114.5
Alanine transaminase (ALT)	iu/l	10.1–55.3 (n = 17)		
Gamma glutamyl transferase (GGT)	iu/l	0.1–82.1 (n = 17)	41.3–46.7	40.2–55.8
Aspartate transaminase (AST)	iu/l	5.6–99.5 (n = 17)		
Creatine kinase (CK)	iu/l	137.7–3577 (n = 17)		
Iron	umol/l			
Cholesterol	mmol/l	2.8–7.0 (n = 17)		
Glucose	mmol/l	3.5–13.1 (n = 13)	15.0–15.5	13.0–13.3
LDH	iu/l	190.4–876.7 (n = 17)		

Sources: Driver (1981); RSPCA/Grange Laboratories own data; Williams and Trainer (1971).

acute septicaemia; petechial and ecchymotic haemorrhages on the myocardium and mesentery, a swollen copper-coloured liver with pinpoint white spots of necrosis throughout the parenchyma, and sometimes a catarrhal haemorrhagic enteritis. In the subacute and chronic cases, thoracic lesions predominate. There is pulmonary haemorrhage and areas of consolidation, fibrinopurulent pleurisy, pericarditis and air sacculitis.

Differential diagnoses should include DVE, *E. coli*, *Erysipelas* spp. and, in the chronic form, *Pasteurella anapestifer* (Table 11.7).

Staining of heart blood smears with methylene blue, Giemsa or Wright's stain should reveal vast numbers of bipolar rod organisms. Diagnosis is confirmed on bacterial culture. Treatment with penicillin and tetracycline has proved effective. In large free-living colonies, prompt carcass removal followed by incineration, liming or burying is the main method of control. It is contentious whether driving birds from the affected area is beneficial or merely acts to spread the disease. Vaccines developed for Galliformes have been tried. Several different strains of *P. multocida* exist,

**Table 11.6** Infectious diseases of waterfowl

Disease	Agent and transmission	Susceptible species	Relative occurrence	Clinical signs and lesions	Diagnosis and differentials	Treatment and control	Zoonotic importance
<b>Bacteria</b>							
Avian Tuberculosis	<i>Mycobacterium avium</i>	All	Common especially in long established waterfowl collections	See text	See text. Pseudo-tuberculosis (poss. <i>E. coli</i> or <i>Salmonella</i> spp. at PM)	See text	Significant in immuno-suppressed individuals
Pseudotuberculosis	<i>Yersinia pseudotuberculosis</i> . Through a break in the skin or mucous membranes or by ingestion. Rodents and wild birds may act as carriers infecting food supplies. Many soil invertebrates act as mechanical vectors. Organism can propagate outside the host at low temperatures if organic nitrogen available	All	Rare	Weight loss, anorexia, dyspnoea, diarrhoea, enteritis. In acute disease, enlarged liver and spleen. In chronic disease, nodules in liver, lungs, spleen and breast muscles	Bacterial isolation may take up to 2 weeks to grow, may need to store culture in fridge first. TB, <i>E. coli</i>	Improve sanitation, no reliable vaccine, mostly refractory to antibiotics	Minimal
Erysipelas	<i>Erysipelothrix rhusiopathiae</i> . Unknown, possibly wound infection or ingestion, can propagate outside the host even in seawater and reservoirs, carried by rodents and pigs	All. May cause 30% mortality in ducklings	Not uncommon. Can cause epidemics in winter	Acute death, lesions consistent with acute septicaemia	Bacterial isolation. Culture from spleen, liver and bone marrow. Acute septicaemia	Antibiotics, penicillin drug of choice, improve hygiene	Wound infection, erysipeloid
Avian cholera	<i>Pasteurella Multocida</i>	All	See text	See text	See text	See text	None
New duck disease (anatipestifer, infectious serositis)	<i>Pasteurella</i> spp. (now reclassified as <i>Cytophaga anatipestifer</i> , formerly <i>Pasteurella</i> )	All, sporadic outbreaks in the wild, more common in captive collections. Acute form in duckling < 6 weeks of age. Chronic, localized form seen in older birds	Acute form is not uncommon and has approx. 75% mortality; chronic form is rare	Listlessness, ocular discharge, diarrhoea, CNS signs, air sacculitis, pericarditis, meningitis, fibrinous membranes on viscera	Bacterial isolation, ELISA test. <i>E. coli</i> septicaemia, DVH, DVE, <i>Salmonella</i> spp.	In early stages novobiocin and lincomycin in feed, penicillin parenterally	None

Colibacillosis	<i>Escherichia coli</i> – many species of varying pathogenicity. Primary or secondary invader. Ingestion, wound infection	All	Common	Acute septicaemia, air sacculitis, fibrinous pericarditis, enlarged necrotic spleen, caseous peritonitis. Common isolate from mucoid sinusitis salpingitis and bumble foot	Bacterial isolation on histology serofibrinous inflammation with plasma cells in liver and kidney. Other causes: acute septicaemia, TB, <i>Salmonella</i> spp.	Antibiotics according to sensitivity, improve sanitation	None
Salmonellosis (notifiable disease in UK)	<i>Salmonella</i> spp.( over 2000 spp.) commonly <i>S. typhimurium</i> . Ingestion; carriers common; human carriers may be source of infection	All	Common	Vary from acute septicaemia and sudden death to chronic non-specific illness. Enteritis, meningitis, focal hepatic necrosis caseous caecal plugs	Bacterial isolation, serology. <i>E. coli</i> , other enteric pathogens and causes of acute septicaemia	Antibiotics according to sensitivity, improve sanitation	Gastroenteritis
Other Enterobacteriaceae	<i>Pseudomonas aeruginosa</i> and <i>Aeromonas hydrophilia</i> . Both organisms may be incidental post-mortem findings. Usually secondary pathogens producing potent extracellular toxins. Ingestion, can propagate in cool water contaminated by organic waste, also contaminated food	All	Common	Both have similar clinical signs, localized respiratory tract infection, dyspnoea, diarrhoea. Sometimes acute septicaemia and death	Bacterial isolation	Antibiotics according to sensitivity, improve sanitation	None
<i>Camphylobacter</i> spp. (common isolate from the guts of healthy animals)	Pathogenic strains of <i>C. jejuni</i> . Dogs and other mammals may act as carriers. Ingestion of food or water contaminated by human sewage. Not stable in the environment	All	Not uncommon	Subacute or chronic illness. Lethargy, weight loss, anorexia, diarrhoea (often yellow), hepatitis. Enlarged liver with prominent lobules and focal necrosis, mucoid haemorrhagic enteritis. Common cause of chronic hepatitis	Bacterial isolation from faeces and affected tissues. Must use transport medium for swabs. Other pathogens causing hepatitis together with enteritis	Antibiotics according to sensitivity, improve sanitation	Gastroenteritis
Goose gonorrhoea	Neiseria-like organism. Direct cloacal contact and vertical transmission	Captive geese. 10% mortality in ganders	Uncommon	Cloacitis, inflammation and ulceration of the phallus	Clinical signs suggestive	Antibiotics according to sensitivity.	None



Table 11.6 Continued

Disease	Agent and transmission	Susceptible species	Relative occurrence	Clinical signs and lesions	Diagnosis and differentials	Treatment and control	Zoonotic importance
Avian mycoplasmosis	<i>Mycoplasma</i> spp. <i>Acholeplasma</i> spp. Colonizers of respiratory and urogenital tract, require a breach in the mucosa to allow invasion. Transmission requires close contact egg transmission and long latent periods can also occur. Very unstable in the environment, can survive 2–4 days in drinking water	All	Not uncommon	Signs can include chronic conjunctivitis, rhinitis, sinusitis, tenosynovitis, arthritis and stunted growth. Marked serofibrinous, cell-mediated inflammatory response. Haematogenous spread especially to joints, brain and egg follicles. These often become colonized by secondary invaders, producing a wide range of pathology	Culture and isolation. Intracytoplasmic inclusion bodies in Giemsa stained impression smears. Serology often not useful though has been used in poultry. Common secondary pathogens include <i>Staphylococci</i> spp., <i>Streptococci</i> spp. and <i>E. coli</i> spp. <i>Chlamydia psittici</i> , other pathogens causing upper respiratory signs	Aminoglycosides are the most useful antibiotics. Oxytetracyclin may have some efficacy. Decrease stocking density, careful sanitation before disinfection	None
Ornithosis	<i>Chlamydia psitticae</i> . Inhalation, airborne contaminated faecal material. Frequent asymptomatic carriers, no identifying test presently available	Ducks, geese and possibly other Anseriformes. 20–70% mortality in infected ducklings	Common carriers. Clinical syndrome rare	Purulent conjunctivitis, rhinitis, sinusitis, lethargy, greenish diarrhoea. Serofibrinous pericarditis and airsacculitis, splenomegaly, hepatomegaly	Isolation, Geimsa stained impression smears. Serology. Mycoplasmas, other pathogens causing upper respiratory signs	Tetracyclines daily or weekly for 6 weeks or enrofloxacin for 14 days	Important: fever with respiratory involvement
Secondary bacterial invaders	<i>Staphylococci</i> spp., <i>Streptococci</i> spp., <i>Proteus</i> spp., <i>Pseudomonas</i> spp., <i>Corynebacterium</i> spp.	All	Very common	Secondary invaders not normally prime cause of disease	Isolation	Antibiosis according to culture and sensitivity. Seek cause of primary insult	Minimal
<b>Viruses</b>							
Duck viral enteritis (duck plague)	Herpesvirus	See text	See text	See text	See text	See text	None
Goose viral hepatitis (goose influenza, goose plague)	Parvovirus. Lateral transmission, oral and nasal exudate	Domestic geese, Canada geese, muscovy ducks	Mortality 100% under 20 days of age, resistant after 70 days old. Common in Europe; undocumented in USA	Diarrhoea, ataxia, coryza, fibrinous plaques under tongue. Signs consistent with acute viraemia or septicaemia, ascities, serofibrinous pericarditis	Virus isolation, serology VN and ELISA tests. DVE, acute bacterial/viral septicaemias, gosling reovirus (primarily respiratory signs)	Vaccination of stock 3–6 weeks prior to breeding	None

Duck viral hepatitis	Type 1: picorna virus	Duck Type 2: astrovirus	Ducklings from 2 weeks of age, mallard infected but do not show clinical signs	Not uncommon; mortality up to 100%	Sudden death. Some may show terminal opisthotonus	Inoculation embryonated chicken eggs	None
	Type 2: astrovirus probably spread by gulls	Only in east of England	Mortality 10–50%	Hepatomegaly and splenomegaly with petechiae	DVE, acute bacterial septicaemia, coccidiosis, mycotoxicosis	None	
	Type 3	Only in USA, mallards and domestic ducks	Mortality up to 30%	Often secondarily infected with <i>Salmonella</i> spp. or <i>Chlamydia</i> spp.			
Avian encephalomyelitis (epidemic tremor)	Picornavirus. Vertical transmission	Ducklings 1–6 weeks old	Occasional	CNS signs, tremors, inco-ordination, paralysis (decreased egg production in adults)	Inoculation embryonated chicken eggs. ID and ELISA test. Histopathology of brain. Vitamin E/selenium deficiency, Newcastle's disease	None, prognosis usually hopeless, vaccination available	None
Eastern and western equine encephalitis and other encephalomyelitis	Arboviruses. Transmission by insect vectors, mainly in the Americas	All. Very susceptible	Rare. Not reported in free-living waterfowl	Up to 80% mortality. CNS signs, sometimes haemorrhagic enteritis	Virus isolation from brain homogenate. HI and ELISA tests	None. Horse vaccine has been used in ratites and pheasants	Encephalitis
Newcastle's disease (notifiable disease in the UK)	Paramyxovirus serotype group 1. Faeco-oral route. <i>Anseriformes</i> not very susceptible	All	Rare, often latent infection	Usually mild but sometimes severe including respiratory signs, diarrhoea, CNS signs: wing drooping, torticollis, opisthotonos, paralysis	Virus isolation, HI test. Faecal and respiratory tract swabs, chilling and special transport media required	Vaccination	Severe conjunctivitis
Avian influenza (fowl plague)	Orthomyxovirus, influenza 'A'	All	Rare in captive collections, no record of the disease in the wild	Ranges from a subclinical sinusitis to severe respiratory disease	Virus isolation and serology	Prevent stress especially overcrowding and severe weather conditions	Important, may lead to human pandemics
Avian pox (Avian diphtheria, contagious epithelioma)	Pox virus – many distinct viruses identified, may be species-specific. Biting arthropod vectors, mosquitoes can retain virus for up to 8 weeks	All	Mild cases common	Typical wart-like lesions on feet; rarely in pharynx or around eyes.	Clinical signs, virus isolation	Self-limiting. control insect vectors, may be more prevalent in birds with hypovitaminosis A	Efficacy/safety of fowl pox vaccine undetermined

Table 11.6 Continued

Disease	Agent and transmission	Susceptible species	Relative occurrence	Clinical signs and lesions	Diagnosis and differentials	Treatment and control	Zoonotic importance
<b>Fungal</b> Aspergillosis	<i>Aspergillus</i> spp. Over 200 species all of which are normally saprophytic and found in damp environments. Spores ubiquitous. Inhalation of spores. Clinical syndrome varies with immuno-competence and pathogenic load	All, particularly sea and diving ducks and swans	Common, especially following a stressor such as capture, transportation, oiling, concurrent disease. Injudicious use of antibiotics and steroids. Hypo-vitaminosis A	Three main syndromes: 1. Acute: sudden death, neurological signs initially in respiratory system then haematogenous spread to viscera, especially CNS and cardiac muscle; 2. Upper respiratory tract (URT) obstruction, localized plaques around syrinx and tracheal bend in swans. Change in voice common presenting sign; 3. Chronic air sacculitis, lethargy, gradual weight loss. May be precursor to acute form	History and clinical signs often suggestive isolation from tracheal swab, fungal colonies usually visible on sebourards medium after 48 hours. bronchoscopy, radiography. PM lesions include granulomata, yellow miliary nodules in lung parenchyma, grey/white fungal plaques. Serology, ELISA test, titres increase during disease and fall during remission. Causes of sudden death, syngamus, trichomoniasis, candida, Tuberculosis, Paratuberculosis, E. coli Salmonellosis	Prevention, avoid stressors, prophylaxis in at-risk birds. Early detection by serological monitoring (QIA) of at-risk populations. Wide variety of antifungal agents used. Isole antifungal show good penetration but slow onset of action so usually used with initial short course of Amphotericin B. Amphotericin B has poor penetration and is best delivered by nebulizer or intra-air sac route; treatment suspended once antibody levels fallen to background (usually 4–6 weeks). Surgical removal of tracheal form followed by systemic and topical antifungals	Minimal
Candidiasis	<i>Candida</i> spp. Usually secondary opportunist; may occur as part of normal gut flora. Predisposing factors include, concurrent disease, poor diet, poor hygiene and injudicious use of antibiotics	All. Particularly common in captive sea ducks denied access to salt water. Secretions from the salt glands seem to inhibit yeast growth	Not uncommon	Listlessness inappetence, weight loss. In sea ducks lesions often in mouth, conjunctiva and nictitating membrane. At PM, oesophageal mucosa thickened, overlaid by soft white cheesy deposits. Occasionally also proventriculus, cloaca, respiratory tract and skin	Smear from mucosa stained with lacto phenol blue or 'Diff Quick' to demonstrate organism. Trichomoniasis, aspergillosis, tuberculosis, paratuberculosis, differentiate oesophageal plaques from DVE	Avoid predisposing factors. Topical treatment with nystatin 100 000 units per 300 g bird bid for 7–14 days (not absorbed form alimentary tract, care when stomach tubing not to miss lesions proximal to delivery site)	None

<b>Protozoa</b> Trichonomiasis	<i>Trichomonas gallinae</i> . Direct transmission, contaminated food source	All	Uncommon	Listlessness, inappetence, weight loss, occasionally dyspnoea if lesions obstruct larynx. At PM, yellow/white cheesy deposits anywhere from pharynx to ventriculus	Immediate microscopic examination of mucosal smear in warm saline will reveal highly motile trichomonads. Candidiasis, tuberculosis, aspergillosis, renal coccidiosis para- tuberculosis. Differentiate oesophageal plaques from DVE	In severe cases usually unsuccessful, debridement followed by treatment with dimetridazole or metronidazole, treat in contact birds for 12 days	None
Haematozoa	<i>Plasmodium</i> spp.	All	Rarely diagnosed	Often asymptomatic. May cause anaemia, subcutaneous bleeding, swollen eyelids, acute death. Hepatospleno- megaly	Stained blood smear, pigmented parasite found in leucocytes and erythrocytes. Leucocytozoon	Antimalarials	None
	<i>Leucocytozoon</i> spp. Simuliidae (black flies) principal vector	All. Only in black fly areas, young, stressed birds most susceptible	Common. Heavy mortality and regular die offs in the wild, may be main factor limiting population size in some areas	Anaemia, inappetence, weakness. Hepato- splenomegaly	Blood smear, parasite found in leucocytes but only during first period of infection. Schizonts found in impression smears of viscera; malaria	Where possible avoid contact with black flies	None
Sarcocistis	<i>Sarcocystis ridleyi</i>	Ducks, especially dabblers, more common in adults	Rare in UK; common in USA	Usually non- pathogenic; can cause muscular weakness and lethargy. White rice grain-type lesions within muscle	Gross pathology	Usually unnecessary	30-day course of pyriethamine. Possible
Renal coccidiosis	<i>Eimeria truncata</i> . Localize in kidneys	All. Especially young geese	Not uncommon	Leg weakness, tendency to tip forwards, listlessness, inappetence, weight loss, diarrhoea. Kidneys grossly swollen with white pinpoint foci made up of urates and cellular debris	Gross pathology. Lead poisoning, botulism, trichonomiasis, candidiasis, tuberculosis, aspergillosis, para- tuberculosis	Clazuril or sulphonamides	None
Enteric coccidiosis	<i>Eimeria</i> spp., <i>Tyzzeria</i> spp., <i>Wenyella</i> spp. Many species-specific. Occasionally <i>Cryptosporidia</i> spp.	All	Not uncommon	Varies from acute death, muco- sanguineous diarrhoea to asymptomatic	Faecal flotation, histopathology : enteric lesions contain morzoites	Improve hygiene. Amprolium	None

Table 11.6 Continued

Disease	Agent and transmission	Susceptible species	Relative occurrence	Clinical signs and lesions	Diagnosis and differentials	Treatment and control	Zoonotic importance
<b>Nematodes, cestodes and trematodes</b>							
Proventricular worms (Acuaria)	<i>Echinuria uncinata</i> and <i>Echinuria autralis</i> (less pathogenic). <i>Daphnia</i> spp. intermediate host. Each may carry up to 20 infective larvae. Adults possess an array of spikes to anchor themselves in proventriculus wall. The posterior ends of females protrude into the lumen and shed their eggs into the gut	Ducks, swans, occasionally geese. Of most significance in young birds, can cause high mortality in cygnets on shallow water in hot summers	Not uncommon in birds with access to slow moving water. Seasonal, <i>Daphnia</i> spp. more common in warm weather	Stunted growth, anorexia, starvation, anaemia. Severe damage to proventriculus wall and excessive mucus production. Nodules containing parasites may impair passage of food	Demonstration of eggs in faeces. Small elliptical egg containing single larva. PM lesions. Thorny headed worms, gizzard worms	Increase water flow through ponds to discourage build up of <i>Daphnia</i> spp. Treatment with anthelmintics rarely effective in clinical cases as scarring and fibrosis remain, repeated dosing of young birds may prevent infection from becoming pathogenic	None
Gizzard worms	<i>Amidostomum</i> spp. Direct life cycle, eggs hatch in water, larvae ingested. Small hair-like worms living beneath horny gizzard lining	Mainly geese and ducks, diving ducks rarely affected. Most significant in young birds	Not uncommon	Stunted growth, anorexia, erosion and necrosis of koilin leading to ventricular disfunction	Demonstration of egg in faeces: oval, thin walled, embryonated, slightly larger than ascarid egg. PM lesions. Acuaria, thorny headed worms	Anthelmintics. Removal from or drainage of infected water courses	None
Caecal worm	<i>Heterakis</i> spp.	All	Common PM finding	Asymptomatic	Faecal flotation, thick-walled ellipsoidal eggs	Unnecessary	None
Thorny headed worms (Acanthocephala)	<i>Filicollis anatis</i> and <i>Polymorphous</i> spp. Invade intestinal mucosa; cylindrical non-segmented parasites found in lower SI, often bright yellow or orange. Crustacea intermediate hosts	All. Especially swans and eiders	Uncommon. Can be common in geographically localized areas. High mortality in young birds	Rapid weight loss, enteritis. May cause gut rupture and peritonitis	Demonstration of parasite on post-mortem. Spindle-shaped embryonated egg in faeces containing embryo with rostral cirlet of hooks. Gizzard worms, acuaria	Anthelmintics. Removal from or drainage of infected water courses	None
Goose gapeworms	<i>Cyathostoma bronchialis</i> . Direct life cycle, carrier adults contaminate pasture, earthworm may act as a vector. Worms found in bronchi and trachea	Geese. Most mortalities in young birds	Not uncommon. Seasonal, rare in prolonged dry weather	Unthriftness secondary to anaemia, blood tinged tracheal mucus, soft cough, yawning, rarely dyspnoea	Eggs and adults in tracheal mucus and faeces. Worms in bronchi and trachea	Avoid grazing young goslings on land contaminated by adults. Regular use (every 10 days) of anthelmintics in at-risk birds	None

Gapeworms	<i>Syngamus trachea</i> . Direct life cycle, snails, slugs and earthworms may act as vectors	All	Rare	Dyspnoea, coughing, unthriftiness	Bioperculate eggs in faeces, adults in trachea, sometime causing total obstruction	Anthelmintics	None
<i>Avioserpens taiwana</i>	<i>Avioserpens taiwana</i> . Cyclops intermediate host	Ducks. Taiwan, Indo-China, North America	Common in areas with high numbers of cyclops	Parasite containing tumours on underside mandibles and chin, occasionally on thighs and shoulder	Clinical signs	If required; excision	None
Flukes	Multiple trematode species. Most species Non-pathogenic. Molluscs and crustacea act as intermediate hosts	All	Not uncommon. Occasional enzootics	Range from haemorrhagic enteritis to emaciation and hepatic fibrosis depending on species	Fluke eggs in faeces	Control difficult, praziquantel, chlorsulon levamisole 25–50 mg/kg p.o.	None
Dwarf tapeworm	Numerous species, <i>Hymenolepididae</i> spp. common isolate. Fresh water intermediate hosts	All fresh water species	Not uncommon. Large numbers in debilitated birds	Usually asymptomatic. Found throughout GI tract. Catarrhal enteritis, diarrhoea, emaciation	Faecal flotation, proglottides in faeces. Adult sometimes seen on cloacal examination	Niclosamide (toxic to geese). Praziquantel	None
<b>Ectoparasites</b>							
Lice – chewing	<i>Mallophaga</i> spp. Most species host-specific. Direct contact, life cycle 2–3 weeks. Feed off feather debris	All, especially common in swans	Very common	Usually asymptomatic, some local irritation. Numbers increase dramatically in debilitated animals	Black or brown and cigar-shaped, 2–8 mm in length, seen scuttling around feather vane	5% carbaryl powder, ivermectin. In heavy infestations investigate underlying cause	Enjoy patrolling human hair, local irritation only.
Shaft lice (wet feather)	<i>Holomenopen leucoxanthom</i> . Feed on contents of soft feather quills	Most	Not uncommon	Destruction of normal feather structure leading to loss of waterproofing and moist appearing feathers. Severe irritation	Direct visualization. Examine a freshly plucked feather with a hand lens. Other causes of loss of normal feather structure: lack of preening, soiling of feathers, chemical contaminants, physical damage	Topical acaricide. Avoid oily preparations as they will themselves cause a loss of waterproofing	None
Leeches (hirudinea)	<i>Thiomyzon</i> spp. Over 20 species recorded in waterfowl	Most	Common	Head shaking, constant sneezing, conjunctivitis, bloody nasal discharge, nasal obstruction. Anaemia, often fatal in ducklings, sporadic deaths in adults	Direct vizualization. Found in nasal passages, sinuses, mouth and periobital region	Drainage and disinfection of affected pond or suspend use for 1–2 years. Physical removal using ivermectin 200 µg/kg single dose p.o., i.m. or s.c.	None

Sources include: Benyon *et al.*, 1996; Coles (1997); Fowler (1986); Ritchie *et al.*, 1994.

**Tables 11.7 a–d** Differential diagnosis. These tables are intended as an aid in differential diagnosis during disease investigation. The more common diseases of wildfowl are listed, with the major organ systems affected**a. Disease causing increased mortality in young birds**

Disease	Age	Systemic	Gastrointestinal (GI) tract	Central nervous system (CNS)	Respiratory system	Cardiovascular system (CVS)	Renal system
DVE (duck viral enteritis)	All	+	+				
DVH (duck viral hepatitis)	2–10 weeks		+	+	+		
NDD (new duck disease)			+	+	+		
<i>E. coli</i> spp.	All	+					
<i>Salmonella</i> spp.	All			+	+		
Encephalomyelitis	1–6 weeks			+			
Aspergillosis	All			+			
Cyanostoma	Fledgling/juveniles		+			Anaemia	
Acuria	Fledgling/juveniles		+			Anaemia	
Amidostomum	Fledgling/juveniles		+				
Renal coccidiosis	Fledgling/juveniles						+
Leeches						Anaemia	

**b. Large die-offs of all ages, characterized by sudden death**

Avian cholera  
 Duck viral enteritis  
 Leucocytozoon  
 Erysipelas  
 Eastern and western equine encephalitis  
 Botulism  
 Mycotoxins  
 Phytotoxins

**c. Acute diseases all ages**

Disease	Systemic	Gastrointestinal (GI) tract	Central nervous system (CNS)	Respiratory system	Cardiovascular system (CVS)	Musculoskeletal system
Avian cholera	+					
Colisepticaemia	+					
<i>Salmonella</i> spp.		+	+			
<i>Erysipelas</i> spp.	+					
DVE (duck viral enteritis)	+	+				
Eastern and western equine encephalitis			+			
Avian influenza				+		
<i>Aspergillus</i> spp.			+	+	+	
Pseudo-tuberculosis		+		+		
Botulism		+	+	+		
Mycotoxins		+	+			
Lead poisoning		+	+			+
Zinc poisoning		+	+			+
Electrocution			+			+

**d. Chronic wasting diseases**

Disease	Gastrointestinal (GI) tract	Central nervous system (CNS)	Respiratory system	Cardiovascular system (CVS)	Musculoskeletal system
Avian tuberculosis	+				
Pseudotuberculosis	+		+		
<i>Campylobacter</i> spp.	+				
<i>Salmonella</i> spp.	+	+			
Ornithosis	+		+		
<i>Aspergillus</i> spp.			+		
<i>Candida</i> spp.	+				
<i>Trichomonas</i> spp.	+		+		
<i>Plasmodium</i> spp.				+	
<i>Leucocytozoon</i> spp.				+	
Lead poisoning	+	+			+

and the killed vaccine does not seem to be effective in waterfowl. The modified live vaccine has been implicated in a disease outbreak when used in pheasants, and at present its use is discouraged (Jessup, 1986).

## Avian tuberculosis

Avian tuberculosis, caused by *Mycobacterium avium*, is endemic world-wide and, due to its preference for damp conditions, waterfowl are particularly at risk. Those species feeding on or by fresh water are most frequently affected. Spread is by the faeco-oral route. Avian TB is particularly prevalent in long established captive collections for two reasons:

- 1 The persistence of bacteria in the environment (up to 4 years).
- 2 The slow insidious onset of disease leads to birds becoming infective many months before they show clinical signs.

The disease is characterized by a syndrome of weight loss and muscle atrophy, generalized weakness, lameness, plumage deterioration, diarrhoea and, in advanced cases, ascites. On postmortem there are caseous necrotizing granulomatous lesions varying from pinpoint and miliary to several centimetres in size, involving the parenchyma of any organ, but most commonly the liver, spleen and gastrointestinal tract. Diagnosis is usually on post-mortem examination, but lesions can sometimes also be detected on endoscopic examination. The presence of acid-fast bacilli on faecal examination is suggestive, but affected animals are often intermittent shedders. An ELISA test capable of detecting subclinical infection has been developed and seems promising, though it is not presently commercially available (Forbes *et al.*, 1993). Work is also being undertaken to develop a PCR test for more accurate isolation and differentiation of *M. avium* from other acid-fast bacilli.

*M. avium* is very resistant to chemotherapy. Control is based on euthanasia of affected and in contact animals, the removal and liming of topsoil, decreasing stocking densities, quarantine and serological testing of new stock, and improving general levels of hygiene. A vaccine is currently being trialled at the Wildlife and Wetlands Trust, Slimbridge, UK (Cromie *et al.*,

1993). *M. avium* is mildly infective to humans, and this should be taken into consideration in collections where there is close contact between birds and children or the elderly.

## Viral diseases

### Duck viral enteritis

Duck viral enteritis (or duck plague) is caused by a herpesvirus. It is an important cause of mass mortalities in captive wildfowl, and in the UK is thought to be endemic, causing sporadic deaths in the wild population. The disease is seen at all times of year, but seems particularly prevalent in the UK in the late spring and autumn. This may coincide with the immigration of free-flying waterfowl. The epizootology in North America may be slightly different, with the disease postulated as being an exotic infection spreading to wild birds from captive collections (Jessup, 1986). All Anseriformes can be affected, but there seem to be a wide range of susceptibility both between species and individuals. As a general rule, muscovys (*Cairina moschata*), wood ducks (*Aix sponsa*) and teal (*Anas crecca*) seem most susceptible and mallard (*Anas platyrhynchos*), domestic Peking ducks (*Anas platyrhynchos*) and pintails (*Anas acuta*) more resistant. Symptomless carrier wild mallard are often blamed for disease outbreaks in collections in the UK. Transmission from contaminated feed and water can occur via oral, nasal and cloacal routes, and incubation is 3–7 days. Birds are typically found dead. Those exhibiting clinical signs may be photophobic, lethargic, anorexic, ataxic, and have a serosanguinous nasal discharge and watery or bloody diarrhoea. Most die within 24 hours, showing terminal convulsions and, in males, a prolapsed phallus. Pathology is due to acute viral damage to the endothelial lining of small blood vessels, lymphoid tissue and selected epithelial tissues. Gross pathology is consistent with an acute septicaemia (see Avian cholera for a description). Inconsistent but more specific findings include exanthematous plaques under the tongue and around the cloaca and in longitudinal rows in the oesophagus. In species with well-organized and distinct gastrointestinal lymphoid tissue these may become haemorrhagic and later necrotizing;



forming annular bands in some species of ducks and button-like structures in geese. Intraliminal haemorrhages and mucosal ecchymoses are also common. Herpesvirus inclusion bodies are often (but not always) seen on histopathological examination of the liver, reticuloendothelial system and the mucosa underlying any oesophageal or cloacal lesions (Wobeser, 1981; Jessup, 1986; Brown and Forbes, 1996).

Typical post-mortem signs are suggestive of DVE but, due to their variability, a definitive diagnosis by virus isolation should be sought. There is no treatment for DVE, and the condition is often self-limiting. Immunity is thought to occur in recovered animals, but this is not reliable. In an open population, each outbreak may last for several weeks and frequently the disease recurs with new susceptible arrivals or as carriers fly on. A modified live vaccine specifically developed for Anseriformes has been developed by Central Veterinary Laboratory, Weybridge, UK, and hopefully will become commercially available in the UK in the near future. A similar vaccine has been used for sometime in the US and continental Europe (M. Brown, personal communication, 1998).

## Non-infectious diseases

### Lead poisoning

#### *Aetiology*

Lead poisoning is caused by the ingestion of lead shot used as anglers' weights or spent shotgun pellets, or unusually by the ingestion of soil or sediments contaminated with high lead levels (e.g. from mining or smelting activity). Lead shot in the proventriculus and gizzard is dissolved by the acid fluid, the process being enhanced by grinding action, and absorbed into the blood. Lead shot in other tissues is not a source of lead poisoning.

#### *Pathogenesis and clinical signs*

The absorbed lead ions inactivate enzymes in major metabolic pathways. The tissues affected include kidney, bone, CNS and the haemopoietic system. The clinical signs produced are wide ranging, and include anorexia, anaemia, green diarrhoea and weight loss. Muscular

weakness in swans leads to a characteristic weakness of the neck, which is held resting on the back. There is a flaccid paralysis of the oesophagus, which frequently results in impaction with food material. The vocalization may change. CNS signs include ataxia, which in geese and ducks often results in a high stepping gait and a tendency to fall over backwards. Eventually there is collapse, coma and death. Post-mortem findings include an emaciated carcass, a dark-coloured liver (which may be enlarged or shrunken) with greenish bile staining and an enlarged gall-bladder with viscous bile, a dark-coloured caeca, watery green faeces and enlarged spleen and kidneys.

#### *Confirmation of diagnosis*

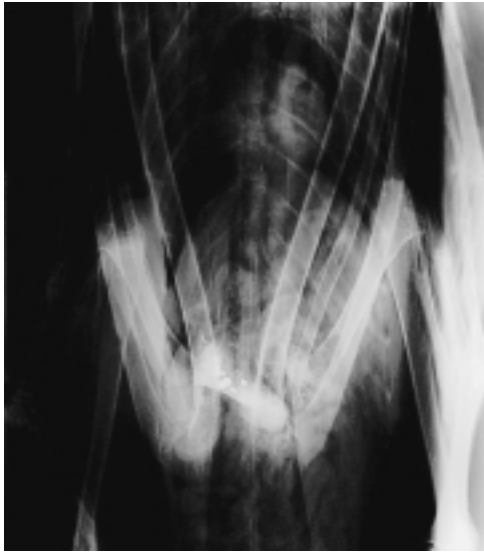
Two tests are regularly used to confirm a diagnosis of lead poisoning; radiography of the GI tract and analysis of whole blood. Both have problems of interpretation.

A dorsoventral radiograph of the abdomen can be taken in the conscious bird, using restraint with sandbags or a swan bag. The X-ray beam should be centred in the midline about the level of the elbows, and the view should include the gizzard, proventriculus and caudal oesophagus. The presence of strongly radiodense material is suspicious of lead, but it may not be distinguishable from modern lead-free shot (Figures 11.6, 11.7). Degernes *et al.* (1989) found that 25 per cent of birds diagnosed as suffering from lead poisoning had no radiographically visible lead.

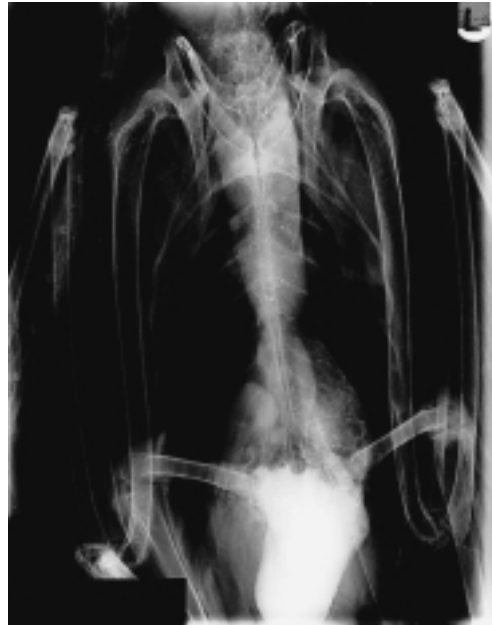Heparinized blood, or blood in lithium heparin (minimum 1 ml) can be analysed for blood lead concentration. However, there appears to be no consistent toxic threshold, and the result must be interpreted in the light of the clinical and radiological findings. The authors use the procedure represented in Table 11.8 (page 260), which uses 2 µmol/l in the presence and 5 µmol/l in the absence of clinical signs as a threshold for practical decision making.

#### *Treatment*

Particulate lead can be removed from the gizzard of an anaesthetized bird by the method described by Forbes (1993). With an endotracheal tube in place, the bird is tilted



**Figure 11.6** Dorso-ventral radiograph of a mute swan showing lead shot in the gizzard. This swan has been radiographed in a normal resting position with the wings folded. The elbow joints obscure the view of the gizzard. There is a sharp penetrating foreign body as an incidental finding.



**Figure 11.7** Dorso-ventral radiograph of a mute swan suffering from lead poisoning. The lead shot is visible, together with a dilated gizzard and proventriculus and a dilated and impacted oesophagus.

head down to an angle of more than 45 per cent. A stomach tube is passed into the gizzard and copious quantities of warmed water are flushed through by means of a gravity or hand pump. It is important to ensure that the oesophagus is not obstructed with vegetable matter or other food material, because if water cannot escape, pressure can build up and rupture the proventriculus. Removal of lead is confirmed by radiography. The whole of the head and neck should be radiographed to ensure no pellets remain in the upper oesophagus or pharynx. Individual large pellets can be removed by endoscopy using a grasper. Occasionally, large pieces of lead may become embedded in the koilin layer of the gizzard and ventriculectomy may be required to remove them.

Sodium calcium edetate (EDTA) is the most commonly used drug, and recommended doses range from 12–40 mg/kg s.c. or i.v., b.i.d. or t.i.d. The authors' treatment of choice is EDTA at 35 mg/kg s.c. b.i.d. for 5 days, followed by 5 days with no treatment. The bird is resampled and treated again for 5 days until the blood lead is below 5  $\mu\text{mol/l}$

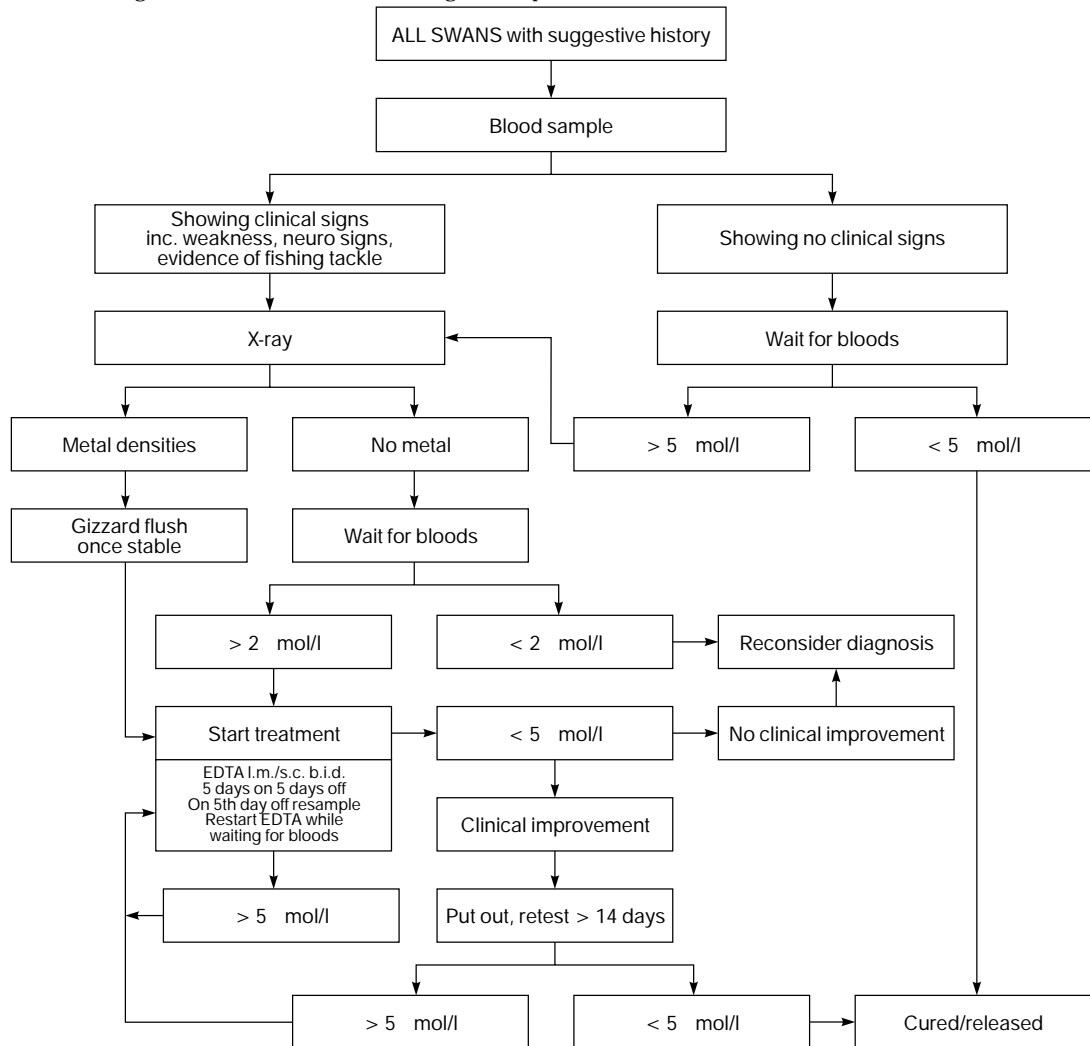
and the bird is clinically improving. A high-calcium oyster or cockleshell grit should be provided throughout the treatment period, and EDTA-induced hypocalcaemia has not been encountered.

The use of oral D-penicillamine at a dose of 55 mg/kg b.i.d. for 7–14 days has also been recommended (Forbes and Harcourt-Brown, 1996). This has the advantage that it can be administered to free-living birds, but in the authors' experience it produces a poor response. Its use in conjunction with EDTA has been recommended (Olsen, 1994), but an apparent adverse reaction to this protocol has been reported (Keeble, 1997), so caution is recommended.

Meso-2,3 dimercaptosuccinic acid (DMSA) is a water-soluble heavy metal chelating agent that has been used in the US, but it is currently not available in the UK.

### **Prognosis and prevention**

Simpson *et al.* (1979) reported a poor prognosis for birds with a haematocrit of below 29 per cent. Severe emaciation or evidence of liver or

**Table 11.8** Diagnostic flowchart for determining lead exposure in waterfowl

kidney damage on blood test carry a poor prognosis. However, the prognosis is not affected by blood lead alone, and birds with very high levels can make spectacular recoveries.

In the UK, the ban on the use of lead in fishing weights of under 28 g has drastically reduced the incidence of lead poisoning in mute swans. However, over 25 per cent of swans treated at the Royal Society for Prevention of Cruelty to Animals (RSPCA) wildlife hospitals are still diagnosed with lead poisoning. Lead used up to two decades ago can still be ingested, but the most recent contamination is the most frequently inges-

ted. A ban on use of lead by anglers and hunters is therefore effective in reducing the incidence of lead poisoning. In grit-free habitats, lead shot may be picked up selectively; scattering grit can reduce ingestion of lead shot. Birds recovered from lead poisoning may develop a pica and selectively ingest lead shot, or their feeding strategy may expose them to a high risk. Birds treated and released once are more likely to be affected a second time (Sears, 1988).

The significance of high lead levels in relation to birds suffering from other conditions is difficult to determine, although it is possible that debility due to subclinical lead

poisoning increases the incidence of collision with power lines and other traumatic injuries (O'Halloran *et al.*, 1988).

## Botulism

Botulism is a paralytic disease that affects vertebrates. It is caused by the toxin of the anaerobic bacterium *Clostridium botulinum*, and is an intoxication rather than an infectious disease. It is contracted only by the ingestion of toxin preformed in suitable media. Type C toxin causes sporadic deaths in birds worldwide, but type E toxin is largely restricted to the Great Lakes of North America. *C. botulinum* cannot survive, or its toxin persist, in a saline environment equivalent to seawater. However, deaths of birds in brackish water environments have occurred. High temperatures, shallow, still or slow-moving water and decaying organic matter create a nutrient-rich anaerobic environment that predisposes to outbreaks of botulism from the germination of *C. botulinum* spores found naturally in soil. Carcasses of botulism casualties and maggots feeding on them are rich sources of toxin, and will cause further deaths if ingested.

Clinical signs are an acute progressive flaccid paralysis of voluntary muscles. Wings, legs and neck are affected first. Classic clinical signs are ataxia and 'limberneck', a weaving motion with the head and neck and eventual collapse of the neck as paralysis progresses. Death is due to respiratory or cardiac arrest or drowning. However, early signs may be as little as a single drooping wing or an inability to swallow. Birds often show respiratory distress with open mouth breathing before the head carriage becomes affected. The prognosis has been linked to the severity of clinical signs (Forbes, 1996) but, in the authors' experience, is often unpredictable. However, once birds are unable to stand, and hold their heads resting on their backs, the prognosis is poor.

Treatment consists of aggressive fluid therapy, both oral and parenteral, aimed at flushing out or diluting any toxin present, followed by the administration of intestinal adsorbents (activated charcoal and/or bismuth) with good general nursing. Specific antitoxins, manufactured for the treatment of horses, are available, but are reported to be ineffective (LaBonde, 1996).

Confirmation of diagnosis can be made by detection of toxin in serum or stomach contents. However, the authors have that found samples from birds showing classical clinical signs frequently fail to reveal the presence of toxin. Once ingested, toxin is rapidly bound to nerve endings and disappears from the gut and circulation. The time elapsed since ingestion of toxin is usually unknown, and this is perhaps the reason for the unreliability of treatment, prognosis and toxin identification.

Control measures include the removal of carcasses, drainage or oxygenation of affected water, and removal of birds from affected environments. The use of bird scarers to drive wild birds away from affected areas is controversial. A vaccine produced commercially for use in mink has been reported successfully to prevent disease in groups of waterfowl at high risk (Cambre and Kenny, 1993).

## Algal toxins

Eutrophic freshwaters exposed to warm temperatures and long hours of sunlight can suffer explosive blooms of toxin-producing phytoplankton of a range of species, usually referred to as blue-green algae. Very high concentrations of toxins can result. These toxins can be neurotoxic, hepatotoxic and locally irritant. Clinical signs include irritation of the skin and eyes, salivation, regurgitation, collapse and death. Diagnosis is often based on circumstantial evidence, presence of toxic blooms and clinical signs or sudden death in a wide range of species of different taxa, which can include both birds and mammals. Treatment is symptomatic. The toxins are also toxic to humans, and care must be taken when handling affected birds or carcasses, or in contact with affected water.

Toxic algae in the marine environment are discussed in Chapter 15.

## Various other toxicities

Other toxicities that occur in wildfowl but do not differ significantly from disease seen in other species include:

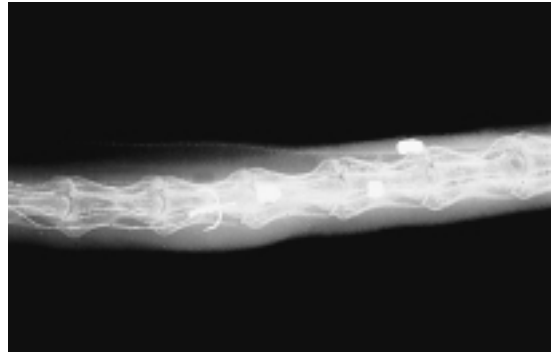- mycotoxicosis, due to fungal toxins in mouldy food. Most are hepatotoxic. Ingestion of toxic plants can occur in captivity, although is rarely seen in the wild

- zinc toxicity, which can occur from ingesting galvanized metal or some coins. Clinical signs include weight loss, lethargy, anorexia and posterior paresis
- environmental contaminants and oil pollution. These are discussed in Chapter 15.

## Fishing tackle injuries

Sports fishing is popular all over the world, and takes place in most aquatic habitats. It is Britain's most popular participation sport. It is therefore not surprising that there is interaction between wildfowl and fishing tackle. On crowded waterways close to centres of human population, fishing tackle entanglement or ingestion (see previous comments on lead toxicity) is a major cause of injury or illness.

Modern monofilament nylon line is strong, elastic, persists in the environment and is almost invisible in water. Line may be accidentally lost or carelessly discarded, as loose line or attached to hooks, weights or lures. It can be left loose on the ground or entangled in vegetation or round obstructions such as branches above or below the water. Line entangled around extremities will restrict circulation and gradually penetrate tissues, eventually severing all tendons and blood vessels or even bone. Care must be taken to remove all nylon, which may be deeply embedded in (or even overgrown by) granulation tissue, especially when very fine line is wrapped repeatedly around a leg. Even after line removal, annular scar tissue can dry and contract to restrict circulation. Wounds should be carefully debrided to remove hard scar tissue, and kept moist and supple with cellulose gel (Intrasite – Smith & Nephew Medical Ltd) or petrolatum jelly until healed. Wounds to the propropatigium are prone to severe contraction of the wound edges, and longstanding wounds often result in permanent flightlessness. Ducks can sometimes survive the amputation or loss of function of a leg, but heavier geese and swans almost invariably develop pressure necrosis over the keel and protrusion of the keel bone. Hooks can tear skin – again the propropatigium is vulnerable – or become embedded in muscle,



**Figure 11.8** Radiograph of a swan's neck showing two hooks and a wire trace in the oesophagus. The airgun pellets are an incidental finding.

tendons or joints, resulting in physical damage and secondary infection.

Birds presented with line hanging from the mouth should first be checked for tackle entangled externally, or around the beak, tongue or glottis. Radiography of head neck and body caudally as far as the gizzard will reveal the presence of ingested hooks, weights or lures (Figure 11.8). If no hooks are present, the line can be cut and allowed to be ingested and work its way out naturally. If one end of the line has entered the gizzard it is usually difficult to extract, and there is a danger of 'cheesewire' cuts if excess traction is applied. Once in the gizzard, line is ground into pieces, and it is very unusual for intact line to pass on into the intestine. It is important to be alert for loops of line wrapped around the upper or lower beak, tongue or larynx. In these cases the line will be gradually pulled into the gizzard, increasing tension on the loop and resulting in the restriction of extension of the neck and a palpable tense band in the oesophagus, followed by the rapid development of 'cheesewire' cuts.

Hooks can be barbed or barbless, single or multiple. They may be attached direct to the line or to a lure in various combinations. Large triangular treble hooks are particularly traumatic. If traction has been applied to the hook, it can be deeply embedded or cause tearing of the oesophagus. Embedded barbed hooks can be difficult to remove and create considerable damage. It is important to check for small hooks embedded in the

tongue or upper pharynx. Single hooks can be removed from the pharynx with long handled forceps. Further down the oesophagus, hooks can be 'disgorged' by passing the attached line through a fisherman's disgorging or, for longer-necked species, a suitable semirigid rod such as a bovine uterine irrigation catheter. With the line gently taut, the disgorging is slid over the shank of the hook, which is pushed away from the direction of penetration. Barbless hooks will often disengage easily and can be withdrawn. Barbed hooks may be more firmly embedded, and excessive pressure should not be applied. Visualization of the site with a flexible endoscope and inflation of the oesophagus can facilitate disgorging.

Large hooks can sometimes be manipulated to protrude through the skin. The bend of hook can then be cut with pincers, allowing the shank to be easily removed by traction.

Surgery is indicated when hooks are deeply embedded, or when there is a sizeable tear in the oesophageal wall. Surgical approach is routine, but careful debridement and removal of any necrotic tissue is essential. Closure of the oesophagus is best achieved using a synthetic absorbable monofilament material (Monocryl, Ethicon) on a swaged atraumatic needle, using a continuous inverting suture pattern. Postoperative antibiotic cover should be provided and, if necessary, feeding carried out by careful gavage for the first 3 days.

Hooks are usually made of bronzed or stainless steel, both of which will rust and eventually disintegrate in the digestive tract. The remains of hooks, surrounded by necrotic material and walled off by foreign body reaction, are not uncommon incidental post-mortem findings in the upper GI tract. Small, deeply embedded hooks causing no clinical signs may not warrant surgical intervention. Occasionally large hooks are encountered deeply embedded and far caudal to the thoracic inlet, making surgical approach difficult, yet the bird may display no clinical signs once the excess line has been removed. The authors have kept such birds without treatment, with no signs of inappetence or discomfort, and suggest that conservative treatment may produce a natural resolution without resorting to high risk surgery.

## Power lines

Large birds such as swans require space to manoeuvre in the air and are prone to collision with overhead power cables, which can be difficult for birds to see and avoid. Birds suffer physical trauma due to the collision and subsequent crash landing. Moreover, if a bird's extremities touch or are close to two differently charged wires, an electrical discharge can result, causing added electrical trauma.

Birds may immediately show clear signs of electrical shock or burning, including large open wounds with charred or coagulated flesh and a smell of burning. Cold oedematous areas, especially the wing distal to the carpus, the ventral abdomen or thigh muscles, are indicative that there has been irreversible coagulative necrosis. These areas of tissue will slough, and prognosis is poor (Cooper, 1996). There is no evidence that therapy is effective, and prognosis is poor and euthanasia indicated unless the affected area is small. Post-mortem examination often reveals the presence of additional areas of electrical coagulation in internal organs. Some birds show paralysis of one or more limbs without associated signs of either physical or electrical trauma. Such paralysis is usually unresponsive to treatment and permanent.

Some birds known to have hit power lines show no immediate evidence of electrical trauma but develop clinical signs later, eventually suffering widespread sloughing of tissue. For this reason it is recommended that all birds having collided with power cables be hospitalized for a minimum of 5 days. Injuries due to physical trauma should be treated as appropriate. If there is no evidence of electrical trauma after 5 days, it can be presumed that electrocution did not occur.

Cables sited on regular flight paths into feeding or roosting area can be marked with large, brightly-coloured lightweight plastic spheres. These can be very effective in reducing birdstrikes. The incidence of birdstrikes can be greatly increased in foggy weather, when flocks may repeatedly circle regular landing sites because they are unable to see well enough for their final approach.

## Gout

Visceral and articular gout are unusual in wildfowl, but swellings in tendon sheaths containing glistening white paste-like solids are urate crystals caused by gout.

## Bumblefoot (pododermatitis)

Hard or excessively abrasive surfaces can cause swelling, skin erosion and secondary infection of any of the joints on the plantar surface of the foot (Plate 25). Early or mild signs may be treated conservatively by providing soft floor surfaces (rubber matting, natural grass, Astroturf or woodshavings) and encouraging time spent on water. Application of steroid and antibiotic in dimethylsulphoxide (DMSO) has been recommended (Olsen, 1994). More severe cases may require surgical debulking and antibiotic therapy, preferably based on culture and sensitivity testing. Post-surgical dressing is achieved by cutting a template of the extended foot from a semirigid material such as plastic or stiff card. Soft dressings are applied to the plantar surface of the foot, which is then extended and stuck to the template with zinc oxide tape applied to the dorsal surface. The whole is then covered with a water-repellent dressing.

## References

- BENYON, P. H., FORBES, N. A. and HARCOURT-BROWN, N. H. (eds) (1996). *Manual of Raptors, Pigeons and Waterfowl*. BSAVA Publications.
- BROWN, M. J. and FORBES, N. A. (1996). Respiratory diseases. In: *Manual of Raptors, Pigeons and Waterfowl* (P. H. Benyon, N. A. Forbes and N. H. Harcourt-Brown, eds), pp. 315–16. BSAVA Publications.
- CAMBRE, R. C. and KENNY, D. (1993). Vaccination of zoo birds against avian botulism with mink botulism vaccine. In: *Am. Assoc. Zoo Vet. Annual Proc.*, 383–5.
- COLES, B. H. (1997). *Avian Medicine and Surgery*. Blackwell Science Ltd.
- COOKE, S. W. (1995). Swan anaesthesia. *Vet. Rec.*, **136**(18), 476.
- COOPER, J. E. (1996). Physical injury. In: *Non-infectious Diseases of Wildlife* (A. Fairbrother, L. N. Locke and G. L. Hoff, eds), pp. 163–5. Manson Publishing Ltd.
- CROMIE, R. L., BROWN, M. J., FORBES, N. A. *et al.* (1993). A comparison and evaluation of techniques for diagnosis of avian tuberculosis in wildfowl. *Avian Pathol.*, **22**, 617.
- DEGERNES, L. A., FRANK, R. K., FREEMAN M. L. and REDIG, P. T. (1989). Lead poisoning in trumpeter swans. In: *Proc. Assoc. Avian Vet. Ann. Conf.*, pp. 144–55. AAV Boca Raton, FL.
- DRIVER, E. A. (1981). Haematological and blood chemical values of mallard (*Anas platyrhynchos*) drakes before, during and after remige moult. *J. Wildlife Dis.*, **17**(3), 413–21.
- FORBES, N. (1993). Treatment of lead poisoning in swans. In *Practice*, **15**(2), 90–91.
- FORBES, N. A. (1996). Nervous conditions. In: *Manual of Raptors, Pigeons and Waterfowl* (P. H. Benyon, N. A. Forbes and N. H. Harcourt-Brown, eds), pp. 317–21. BSAVA Publications.
- FORBES, N. A. and HARCOURT-BROWN, N. H. (1996). Appendix formulary – waterfowl. In: *Manual of Raptors, Pigeons and Waterfowl* (P. H. Benyon, N. A. Forbes and N. H. Harcourt-Brown, eds), p. 352. BSAVA Publications.
- FORBES, N. A. and RICHARDSON, T. (1996). Husbandry and nutrition. In: *Manual of Raptors, Pigeons and Waterfowl* (P. H. Benyon, N. A. Forbes and N. H. Harcourt-Brown, eds), pp. 289–98. BSAVA Publications.
- FORBES, N. A., CROMIE, R. L., BROWN, M. J. *et al.* (1993). Diagnosis of tuberculosis in wildfowl. In: *Proc. Assoc. Avian Vet. Ann. Conf.*, pp. 182–6. AAV Boca Raton, FL.
- FOWLER, M. E. (ed.) (1986). *Zoo and Wild Animal Medicine*. W. B. Saunders
- GOULDEN, S. (1995). Swan anaesthesia. *Vet. Rec.*, **136**(17), 448.
- HUMPHREYS, P. N. (1986). Ducks, geese, swans and screamers (Anseriformes): reproduction. In: *Zoo and Wild Animal Medicine* (M. E. Fowler, ed.), pp. 355–7. W. B. Saunders.
- JESSUP, D. A. (1986). Ducks, geese, swans and screamers (Anseriformes): infectious diseases. In: *Zoo and Wild Animal Medicine* (M. E. Fowler, ed.), pp. 342–52. W. B. Saunders.
- KANEENE, J. B., FLINT TAYLOR, R., SIKARSKIE, J. G. and MEYER, T. J. (1985). Disease patterns in the Detroit Zoo: a study of the avian population from 1973 through 1983 *JAVMA*, **187**(11), 1129–31.
- KEAR, J. (1986). Ducks, geese, swans and screamers (Anseriformes): feeding and Nutrition. In: *Zoo and Wild Animal Medicine* (Fowler, M. E., ed.), pp. 335–41. W. B. Saunders.
- KEEBLE, E. (1997). Suspected allergic reaction to penicillamine in mute swans. *Vet. Rec.*, **140**(17), 464.
- KENNY, D. and CAMBRE, R. C. (1992). Indications and techniques for the surgical removal of the avian yolk sac. *J. Zool. Wildlife Med.*, **23**(1), 55–61.
- LABONDE, J. (1992). The medical and surgical management of domestic waterfowl collections. In: *Proc. Assoc. Avian Vet. Ann. Conf.*, pp. 223–33. AAV Boca Raton, FL.
- LABONDE, J. (1996). Private collections of waterfowl. *Proc. Ann. Conf. Expo. Assoc. Avian Vet.*, **6**, 215–23.
- LAWTON, M. P. C. (1996). Anaesthesia. In: *Manual of Pigeons, Raptors and Waterfowl* (P. H. Benyon, N. A. Forbes and N. H. Harcourt-Brown, eds), pp. 79–88. BSAVA Publications.

- MADGE, S. and BURN, H. (1988). *Wildfowl, an Identification Guide to the Ducks, Geese and Swans of the World*. A&C Black Publishers Ltd.
- O'HALLORAN, J., MYERS, A. A. and DUGGAN, P. F. (1988). Lead poisoning in swans and sources of contamination. *Ireland J. Zool.*, **216**, 221-3.
- OLSEN, J. H. (1994). Ansiformes. In: *Avian Medicine: Principles and Application*. (B. W. Ritchie, G. J. Harrison and L. R. Harrison, eds), pp. 1237-75. Wingers.
- RITCHIE, B. W., HARRISON, G. J. and HARRISON, L. R. (eds) (1994). *Avian Medicine: Principles and Application*. Wingers.
- SEARS, J. (1988). Regional and seasonal variations in lead poisoning in the mute swan (*Cygnus olor*) in relation to the distribution of lead and lead weights, in the Thames Area, England. *Biolog. Cons.*, **46**, 115-34.
- SIMPSON, V. R., HUNT, A. E. and FRENCH, M. C. (1979). Chronic lead poisoning in a herd of mute swans. *Environ. Poll.*, **18**, 187-202.
- WILLIAMS, J. I. and TRAINER, D. O. (1971). A haematological study of snow, blue and Canada geese. *J. Wildlife Dis.*, **7**, 258-65.
- WOBESER, G. A. (1981). *Diseases of Wild Waterfowl*. Plenum Press.



# Galliformes

Brian H. Coles

## Introduction

The order Galliformes (fowl-like birds), in line with the most up-to-date taxonomic information derived from DNA and other biochemical techniques (Sibley and Ahlquist, 1990) is now divided into three families:

- 1 Phasiandidae
- 2 Numididae
- 3 Odontophoridae.

These families, showing various representative species and the general characteristics, are listed in Table 12.1.

Until comparatively recently, taxonomists included within the order Galliformes two other avian families, the Cracidae (i.e. guans, chachalacas and curassows) and the Megapodiidae (megapodes, scrub fowl and brush-turkeys). However, the latest taxonomic information now places these families in a separate order, the Craciformes. Both Galliformes and Craciformes are now included in the super order Gallomorphae (or Gallo-morphs). Within this super order there are some 283 species, the original representatives of which were found in all the world's continents except Antarctica, and on many islands except those of Polynesia and New Zealand.

Although the Galliformes range in size from the relatively small Chinese painted quail (body length 13 cm) to the much larger turkeys and peafowl (approximately 117 cm), most are medium-sized birds similar in size, body form and behavioural characteristics to domestic chickens. The Galliformes are considered to be rather primitive, unspecialized birds that probably evolved early in the evolutionary cycle. They all have relatively large stout legs and feet, with three forward-pointing digits and a smaller hind digit. Many of these birds are

mostly terrestrial, and are incapable of prolonged sustained flight. In most species within the order the mode of flight is a short but rapid take-off, and then gliding or fluttering for short distances. The majority of these birds are non-migratory. However, both grouse and guinea fowl can fly quite strongly, and the Old World quail and some species living in high altitudes do undergo a partial migration to better feeding grounds in winter.

## Veterinary anatomy and physiology

### The skeleton

This is similar in all Galliformes to that of the domestic chicken, with well-developed muscular legs consistent with the relatively stout legs needed for a terrestrial life style and scratching the ground in search of food. Some species (e.g. turkeys) have ossified leg tendons. All Galliformes have an anisodactyl foot with three cranially-directed digits and a fourth, the hallux, situated somewhat higher up the tarsometatarsus and directed caudomedially. In some families or subfamilies (e.g. jungle fowl, turkeys, pheasants) the cock birds have an extra osseous sharp-pointed spur situated above the hallux and directed medially, which is used for fighting and territorial dominance. In the common pheasant (*Phasianus colchicus*), annual rings are formed at the base of the spur and can be used for ageing the bird. Care must be taken when handling such birds, since they can injure the handler. The green peacock will make a positive attack on humans and other animals

**Tables 12.1 a–c** Families, genera and representative species within the order Galliformes. The following are most likely to be encountered by the veterinarian, as they are often kept in captive collections

**a. Family: Phasianidae**

**i. Subfamily Phasianinae (pheasants); 8 genera containing 21 species.**

In most species the male bird has highly coloured plumage whilst the female is more dowdy. Most cock pheasants have exceptionally long tails which are vaulted, i.e. in cross-section they are like an inverted V. The tail is used by the cock bird for display purposes when courting. The fourth digit (the hallux) is located more proximally on the metatarsus than the three forward-directed digits. In many species there is a pointed spur placed proximal to this fourth digit on the metatarsus. This appendage is used by the male birds for fighting to gain territory. Some species of pheasant have coloured facial skin on the head. Most pheasants make a whirring wing noise during territorial display and are also quite vocal.

<i>Genus</i>	<i>Species</i>	<i>Characteristic</i>	<i>Size</i>	<i>Global distribution and normal habit</i>
Gallus	<i>G. gallus</i>	The red jungle fowl: like the domestic chicken. From this species all the numerous breeds of domestic fowl have originated. The Red jungle fowl will hybridize with domestic chickens. The species was probably first domesticated during the Bronze Age, and was originally kept for cock fighting. Unlike other pheasants, it has a more longitudinally arched tail and the cock has well-developed comb and wattles	66 cm (body), 28–30 cm (tail)	SE Asia (Kashmir, Central India, Burma, Thailand, Malaysia, Sumatra and Java). Inhabits tropical rain forest, secondary growth scrub and rice stubble
	<i>G. sonneratii</i>	The grey jungle fowl; Sonneray's jungle fowl: A somewhat larger, more dowdy bird than the Red jungle fowl. Will hybridize with above species	76 cm (body), 41 cm (tail)	Western and Southern India. Habitat: forest scrub, bamboo
Lophura	<i>L. nycthepera</i>	The Silver pheasant: Male bird, marked comb and red facial skin, silver grey wings and tail, black under parts. Will hybridize with above species	122 cm (body) 61–66 cm (tail)	South China, Burma, Thailand, Laos, Vietnam. Habitat: forest
	<i>L. swinhoii</i>	Swinhoe's pheasant; Formosan pheasant: Marked comb and wattles, white neck, brown and dark blue/green plumage, dorsal tail white	150 cm	Taiwan. Habitat: mountainous up to 2800 m
	<i>L. diandi</i>	Siamese fire-back pheasant: Male has crest, grey mantle, golden back patch, black tail	81–86 cm (body)	Burma, Thailand, Indo-China
Phasianus	<i>P. colchicus</i>	Common pheasant: Two varieties; the white ring-necked form and the dark-necked form	60–90 cm (body), 52 cm (tail)	Eurasia, China, Taiwan. Introduced to N America, Hawaii, New Zealand, UK. Habitat: grass scrub, temperate woodland
Syrmaticus	<i>S. reevesii</i>	Reeves' pheasant, bar-tailed pheasant: Body plumage golden with feathers edged with black. Tail long, silver banded with dark brown	86 cm (body), 101–152 cm (tail)	N and Central China. Habitat: open woodland with pine, cypress and oak, tall grass and bushes

Tables 12.1 Continued

Genus	Species	Characteristic	Size	Global distribution and normal habit
Chrysolophus	<i>C. pictus</i>	Golden pheasant: Red under neck and breast, head and back golden, wings green, red, blue and brown, tail brown	39 cm (body), 76–79 cm (tail)	Central China, introduced locally in UK. Habitat: bushy slopes, bamboo, terraced fields
	<i>C. amherstiae</i>	Lady Amherst's pheasant: Body plumage shows patches green and white, silver, golden. Very long silver and brown tail	55 cm (body), 76–117 cm (tail)	SE Tibet, SW China, Burma. Habitat: wooded slopes, bracken hill sides, bamboo, thickets
The eared pheasants – all have exceptionally long, rather bushy tails				
Crossoptilon	<i>C. crossoptilon</i>	The White eared pheasant, Tibetan eared pheasant	91 cm (body)	SE Tibet to NE Yunan and Central Szechwan. Habitat: Coniferous and mixed forest, rhododendron scrub, grassy slopes
	<i>C. manchurian</i>	The Brown eared pheasant, Manchurian eared pheasant: Body brown, red facial skin with white collar and ear tufts	99 cm (body)	NE China. Habitat: stunted conifer or birch, rocky open shrub, coarse grass
	<i>C. uritum</i>	The Blue eared pheasant, Mongolian eared pheasant	97 cm (body)	W China. Habitat: conifer and mixed forest, bushy alpine meadow
<b>ii. Subfamily Tragopinae; 5 species</b>				
Tragopan	<i>T. Satyra</i>	Satyr tragopan or Crimson horned pheasant: White-specked orange and crimson plumage, back and tail base olive brown. Scapulars crimson but wing otherwise brown. Head, crest and throat black, tail reddish brown barred black and rather truncated	69 cm body which looks plumpish	E Palaearctic, Central and Eastern Himalayas. Habitat: high forests. Migrates down hill in winter
<b>iii. Subfamily Lophophorinae; 3 species</b>				
The monal pheasants: heavy bodied birds with a shorter, more square-shaped tail rather like a turkey. The cock birds have an iridescent plumage.				
Lophophorus	<i>L. impeyan</i>	The Himalayan monal or Impeyan: Male has an upright crest, white lower back and lower rump. Upper tail coverts dark glossy blue-green, tail reddish-brown. Body and wings dark metallic green to purple, underparts black.	71 cm (body)	Afghanistan Himalayas, SE Tibet. Habitat: open forest up to 3000 m
<b>iv. Subfamily Argusianinae; 3 genera, 8 species</b>				
Argusianus	<i>A. argus</i>	The great argus pheasant: Male bird rusty brown plumage with black circled eye spots and mottling. Long tail with two central tail feathers broad and very long. Head bare, blue skin	72 cm (body and tail)	Indochina, Sumatra, Borneo. Habitat: primary tropical rain forest up to 1500 m

Tables 12.1 Continued

Genus	Species	Characteristic	Size	Global distribution and normal habit
Polyplectron	<i>P. bicalaratum</i>	The grey peacock pheasant, Burmese peacock pheasant: Male greyish brown, light-coloured throat and under parts. Large violet ocelli on back and tail. Crest, yellowish facial skin	30 cm (body), 41 cm (tail)	Central and S Burma, Thailand, Laos, N Vietnam. Habitat: humid forest, lowlands and mountains up to 1800 m
	<i>P. empharum</i>	Palawan peacock pheasant, Napoleon peacock pheasant: Male darkish brown with iridescent blue-green pointed crest. Tail has large blue-green eye spots. Facial skin reddish, white cheek patch	26 cm (body), 25 cm (tail)	The island of Palawan in the Philippines, North of Borneo. Habitat: humid forest, lower elevation tropical rain forest
v. Subfamily Parvoninae; 2 genera, 3 species				
Peafowl: all have well-developed spurs.				
Parvo	<i>P. cristatus</i>	Common peafowl, Indian peafowl, blue peafowl: It is only the cock bird, the peacock which develops the spectacular train and this does not develop until the third year. The long ornamental feathers of the tail are not true rectrices but elongated covert feathers	198–229 cm	India, Sri Lanka. Habitat: moist dry deciduous lowland forest up to 1500 m
	<i>P. muticus</i>	Green peafowl, Javanese green peafowl, Green necked peafowl: Large bird, long train, brilliant green plumage, blue and yellow facial skin	213–244 cm	SW China, Assam, Burma, Thailand, Vietnam, Laos, Malaysia, Java. Habitat: open forest, riverbanks, forest edge, sometimes found up to 1000 m.
Afroparvo	<i>A. congensis</i>	The African peafowl: Male dark glossy green and bronze on back rump. Underside dark green, violet iridescent back of neck and sternum. Crown white and black spots. Facial skin blue	60–68 cm	Zaire (Congo Basin). Habitat: dense lowland tropical rain forest
vi. Subfamily Tetraonidae; 6 genera, 17 species				
The grouse: birds in this subfamily have feathered external nares as well as feathered tarsi and sometimes feathered digits, particularly the ptarmigan, which inhabits colder regions. Grouse do not have tarsal spurs. During the breeding season some species (e.g. the prairie chicken, black, sharp-tailed and sage grouse) gather at traditional display arenas or lecks, where the males carry out an intricate repetitive dance to hold territory and attract females. All grouse are powerful fliers.				
Lagopus	<i>L. lagopus</i>	Willow grouse, Willow ptarmigan in N America: A stout, short winged bird, reddish brown in colour with white wings. Wedge-shaped tail with darker outer feathers. Moults three times yearly. White in winter except tail. Male has inflatable red skin combs above eyes. Will burrow under snow for food and shelter	38 cm	N Palaearctic, temperate and subarctic. Introduced to Belgium. Habitat: tundra and taiga, heather moorland, willow, birch and juniper scrub, peat bog. Migrates to lower ground in winter
	<i>L. lagopus</i> subspecies <i>scoticus</i>	Red grouse: The same species as above but moults completely to red brown in summer without retaining the white wings		Scotland. W Norwegian population is intermediate between red and willow grouse

Tables 12.1 Continued

Genus	Species	Characteristic	Size	Global distribution and normal habit
Lagopus (Continued)	<i>L. mertus</i>	Ptarmigan, rock ptarmigan in N America: A similar species to willow grouse, retains white wings, belly and legs throughout year. In breeding season plumage blackish brown mottled. In winter completely white except outer tail feathers. Red eye combs. Smaller than above species	33 cm	Holarctic as for willow grouse. Habitat: tundra but higher altitudes than <i>L. lagopus</i> and more barren rocky slopes
Lyrus	<i>L. tetrix</i>	Black grouse: Black cock and grey hen, male plumage blue/black. Unusual lyre-shaped tail in male also white wing bar and pronounced red eye combs	Male 50 cm, female 38 cm	Palaearctic, UK, Eurasia, NE Siberia and E China. Habitat: Peat bog with rushes and scrub with some trees. Rocky heather moorland up to 2000 m
Drenragapus	<i>D. canadensis</i>	Spruce grouse, Franklin grouse, Fool-hen: Male has dark head and neck, flecked white on breast otherwise brownish. Pronounced red eye combs, when erected with fan shaped tail looks like small turkey cock	41 cm	Canada. Habitat: coniferous forest with dense undergrowth
	<i>D. obscurus</i>	Blue grouse: Not unlike spruce grouse but cock bird greyer and larger. Male displays yellowish or red skin covered inflatable oesophagus	51 cm	Western N America to California. Habitat: open mixed woodland and conifer. Lowland and mountain slopes, dry sage brush. Will roost under snow
Centrocercus	<i>C. urophasianus</i>	Sage grouse: Male a very large bird (female smaller) mainly brownish in colour with white ruff on breast. Inflatable oesophagus yellow eye combs. Pointed tail feathers	71 cm	Western N America. Habitat: sage brush, foothills and plains
Bomasa	<i>B. umbellus</i>	Ruffed grouse: Plumage reddish brown to grey. Dark edge to fan-shaped tail. Dark ruff around neck. No eye combs	43 cm	Canada, Alaska and N America. Habitat: deciduous and mixed woodland
Tympanuchus	<i>T. cupido</i>	Greater prairie chicken – similar species; lesser and Attwater's prairie chicken: Plumage buff-coloured markedly barred with dark brown. Male has large yellow eye combs and inflatable yellow skin covered oesophagus. Small rounded tail. Male shows prominent forwardly directed ruff of upper neck feathers which could be mistaken for a head crest	43 cm	Mid-West to Southern US. Habitat: tall grass prairie, open and scrubby grassland. Will burrow in snow to roost.
Tetrao	<i>T. urogallus</i>	Capercaillie: A huge grouse. Male slate grey, wings brown, head and throat dark. Small red eye combs. Black tail flecked white, also on abdomen. Hens may hybridize with blackcock	79–84 cm	Palaearctic and temperate W Europe to USSR. Habitat: coniferous and mixed forest, Taiga

Tables 12.1 Continued

Genus	Species	Characteristic	Size	Global distribution and normal habit
<b>vii. Subfamily Meleagridinae; 2 genera, 2 species</b>				
Turkeys: large powerful grouse-like birds in which the male bird carries on the head and neck coloured erectile caruncles (wattles) over bill, used during courtship. The cock turkeys have tarsal spurs and will fight to the death. There is a square-ended fan-shaped tail. Rattle wing quills during courtship.				
Meleagris	<i>M. gallopavo</i> (5 distinct races)	Wild turkey: Slightly smaller than the domesticated varieties. First domesticated by the Mexican Indians in the sixteenth century	94 cm	N America to Mexico. Habitat: woodland and open forest thickets
Agriocharis	<i>A. ocellata</i>	Ocellated turkey: Has eye spots on the tail. No expandable crest wattles as in common turkeys. Skin of head more blue than red of common turkey	86 cm	Yucatan in Guatemala. Habitat: subtropical lowland
<b>viii. Subfamily Perdicinae; 20 genera, 106 species</b>				
The Old World quails, francolins, partridge and snowcocks: all tend to be rather small, rotund birds with much shorter tails than pheasants. The Old World quails are all small birds with almost non-existent tails. The genus Coternix contains the only migratory Galliformes.				
Coternix	<i>C. japonica</i>	Japanese quail: Dull, grey/brown with light coloured streaks and eye stripes. Domesticated by the Japanese	15 cm	SE Asia, Burma, Thailand, Laos to Hong Kong and Japan, Taiwan Introduced to N America. Habitat: grassland and cultivated areas
	<i>C. delegorguei</i>	Harlequin quail, Delegorgue's quail	15 cm	Senegal to Ethiopia and S Africa. Habitat: savannah and grassland
	<i>C. coromandelica</i>	Rain quail, black-breasted quail	15 cm	India, Sri Lanka, Burma
	<i>C. coturnix</i>	Eurasian quail: Rather like Japanese quail with black throat and rufous upper breast. Migrated in huge numbers in Biblical times and collected by the Children of Israel in the Sinai	16 cm	Southern UK, Europe, migrate across Mediterranean to N Africa. Habitat: rough grassland, cropland with grass tussocks
Exalfacteria	<i>E. chinesis</i>	Chinese painted quail, King quail, Blue breasted quail: Female, like other female quail, brownish, but male brilliant blue eye stripe, neck and flank. Black neck and white collar	13 cm	SE Asia and Australia. Habitat: grass and scrub
The Partridges, francolins and snowcocks – all medium-sized birds with fairly short tails. A few species have tarsal spurs.				
Rollulus	<i>R. rollulus</i>	The Roul roul, partridge, crested green wood partridge, crowned wood partridge, green partridge: Upper parts of body bright green. Only male has pronounced chestnut crest with iridescent black/blue breast and wing coverts. Female mostly green with brown wings	28 cm	Malaysia, Sumatra and Borneo. Habitat: dense tropical forest but prefers drier more open clearings. Up to 1500 m elevation

Tables 12.1 Continued

Genus	Species	Characteristic	Size	Global distribution and normal habit
Perdrix	<i>P. perdrix</i>	Common or grey partridge: Upper parts brown streaked black and white, brownish wing coverts. Face and throat orange/brown. Male has brown inverted horseshoe markings on breast	28 cm	UK, most of Europe except S Spain, Sicily and Sardinia, across to central Asia. Introduced to N America. Habitat: pastures, moorland, cultivated land, wasteland, sand dunes, semi desert, shingle
Alectoris	<i>A. rufa</i> subspecies <i>A. graeca</i>	Red-legged partridge: Distinguished from above species by white eye stripe, white throat, mottled black 'bib'. Red bill and red legs	34 cm	SW Europe, Southern UK, introduced to UK, Azores, Madeira, Canary Isles and N America as a game bird. Habitat: lowland scrub, drier land and heath. Dry cultivated land
	<i>A. chukar</i>	Chukar partridge: Upper parts grey brown, flanks noticeably barred black and white	36 cm	Asia and Asia Minor. Introduced to N America as a game bird. Habitat: Similar to <i>A. rufa</i>
Francolinus (circa 41 species)	<i>F. francolinus</i>	Black francolin: A brownish bird, the male has black under parts markedly white flecked, also white cheeks	36 cm	Cyprus, Syria, Iran to Pakistan, India and Assam. Introduced to Louisiana and S Florida, N America. Habitat: grass and cropland
Tetraogallus	<i>T. himalayensis</i>	Himalayan snowcock: All snowcocks (5 species and many subspecies) are very large partridge-like birds	71 cm	Himalayas up to 6000 m, Afghanistan, India, W China. Introduced to mountainous areas of N America. Habitat: steep stone covered slopes with sparse vegetation, alpine meadow
Lerwa	<i>L. lerwa</i>	Snow partridge: Body form like other partridge but slightly longer. Tail plumage grey brown faintly barred white. Breast deep chestnut streaked white	35 cm	Himalayas up to 5000 m, Pakistan, India, Tibet, W China. Habitat: alpine meadow, rocky slopes above tree line

**b. Family: Odontophoridae (9 genera, 31 species)**

The New World quail. Small compact birds with a short bill that shows a serrated or toothed mandible. The fourth digit (the hallux) is above the level of the other digits. There are no tarsal spurs. Many species have a prominent plume on the forehead. Generally somewhat larger than Old World quail, to which they are quite unrelated.

Lophortyx	<i>L. californicus</i>	Californian quail, valley quail, crested quail: Small pigeon-sized bird. Brownish grey upper breast, under parts flecked white, black throat, white collar, prominent teardrop-shaped plume	25 cm	Western N America, West of the Rockies to S California. Introduced New Zealand, Chile, Hawaii, Canada. Habitat: low tree shrub, open ground with low cover, city parks, sage brush
Callipepla	<i>C. squamata</i>	Scaled quail, blue quail: Greyish brown. Tinge of blue from scaled breast and neck. Crest not typical quail type, more triangular and white tipped	24 cm	SW N America and Mexico. Introduced to Washington State and Nevada. Habitat: barren semi-desert and scrubby grassland

Tables 12.1 Continued

Genus	Species	Characteristic	Size	Global distribution and normal habit
Collinus	<i>C. virginianus</i>	Bob White quail: Brownish with distinct white flecking and scaling on breast and flanks, white throat, white eye stripe, crest not well developed	23–27 cm	SE Canada to Mid West and Eastern N America to Mexico and Central America. Introduced to Britain and New Zealand. Habitat: scrub, open farmland, cities, road sides, derelict land
c. Family: Numididae (4 genera, 7 species)				
The guinea fowl: there are four genera and seven species, all of which are found only on continental Africa and the adjacent island of Madagascar. All are medium-sized birds tending to be rather plump and heavy bodied with a fairly long neck, which together with the head is naked and the skin variously coloured. Some species have casques (e.g. helmeted and tufted guinea fowl) or occipital feather crests or wattles. Their plumage is mostly dark or grey. The tail of guinea fowl is small and drooping. Although mainly terrestrial birds that tend to run rather than walk, the guinea fowl can fly quite strongly.				
Acryllium	<i>A. vulturinum</i>	Vulture guinea fowl, so-called because it looks rather like a vulture with an almost vulturine bill. Black spotted white, underparts cobalt blue. Marked cape around neck of streaked black and white feathers	58 cm	S Somalia, E Uganda, Kenya, NE Tanzania. Habitat: desert, thorn scrub, occasional forest
Numida	<i>N. meleagris</i> subspecies ( <i>N. meleagris mitrata</i> )	Tufted guinea fowl, helmeted or hooded guinea fowl: 20 subspecies occur regionally. Very noisy birds which have often been used as good watchkeepers. Domesticated by the Romans in c. fourth century BC	56 cm	Most of Africa from Cameroon to Central Africa, Chad, Sudan, Ethiopia, Kenya, Tanzania, Zaire, Angola, S Africa. Habitat: dry thorn, bush, grassland and cultivation

using the spurs, and turkey cocks will fight to the death.

Some breeds of domestic chicken (e.g. Chinese silks, Dorkings and Houdans) have five digits, with the extra digit situated medial to the hallux.

The skull of the sand grouse (*Pteroclididae* spp.) has a well-developed fossa that contains the large salt gland, which acts as a supplementary excretory organ in these species. The helmeted guinea fowl (*Numida meleagris*) carries a spongy bone extension situated at the junction of the nasal and frontal bone, which is covered by pigmented skin. This structure, together with the wattles, is better developed in male birds.

In Galliformes, there are two deeply and cranially-directed non-ossified incisions covered in fibrous sheets on each side of the sternal plate. It should be noted that these

leave the underlying liver exposed and vulnerable to deep intramuscular injection if due care is not exercised. The furcula (i.e. the 'wishbone') in the crested and plumed guinea fowl and in the capercaillie (*Tetrao urogallus*) is cup-shaped to receive the elongated trachea.

## The integument

The most obvious characteristic of the Galliformes is the presence of well-developed eye combs, wattles and 'beard' (in the common turkey), all of which are highly coloured (usually red) and inflatable. Some grouse also have inflatable coloured cervical air sacs. In some species (jungle fowl, pheasants, turkeys and some grouse) the tail feathers are well developed for display purposes, but the tail of the peacock is not formed of true rectrices but



of elongated coverts. Most Galliformes moult annually after the breeding season, but ptarmigan moult three times yearly in line with the changes in colour of their sub-Arctic habitat. They also moult the claws. The capercaillie and ptarmigan also fractionally moult the horn of the beak. When handled, grouse tend to shed some feathers as a normal defence reaction against attack. Most Galliformes have a bilobed preen gland with an associated wick of feathers, but its presence in grouse and turkeys is variable. Sand grouse have modified breast feathers during the breeding season for carrying water to the chicks left in desert nest sites.

### The respiratory system

In some species the trachea is elongated into loops, particularly in the male bird. This occurs in crested and plumed guinea fowl and in the capercaillie. The extended section of the trachea lies subcutaneously over the thorax and abdomen. Its presence may be important for the anaesthetist, because if respiration becomes depressed these birds may require assisted positive pressure long before a similar situation would arise in other species.

Normal respiratory rates in the common turkey (28–49 per minute) are approximately twice the rate in the domestic fowl (12–37 per minute); also, the common turkey has no caudal thoracic air sac.

Heart rates in the domestic turkey (93–163 per minute), in contrast to respiratory rates, are much lower than in the domestic fowl (220–360 per minute). Respiratory and cardiac rates are not documented for other species.

### The alimentary canal

In the grouse, the beak is more robust than in most other Galliformes, being adapted to dealing with coarse vegetation. The New World quail have a 'toothed' lower beak. All Galliformes except snowcocks have a well-developed crop, which is, of course, an expansion of the oesophagus; in snowcocks its absence is compensated for by a dilatable oesophagus. Some male North American grouse (sage grouse, *Centrocercus urophasianus*; blue grouse, *Drenragapus obscurus*; prairie

chickens, *Tympanuchus cupido*) have an inflatable diverticulum of the oesophagus covered with featherless, brightly coloured skin (red or yellow), and this is used during courtship and territorial displays.

The ventriculus (gizzard) is well developed muscularly in all Galliformes except for the sage grouse, which consumes softer food. Muscular development of the ventriculus is particularly pronounced in most other grouse because of their coarse vegetable diet. Also, certainly in the red grouse (*Lagopus lagopus scoticus*), the length of the intestine changes seasonally in line with the seasonal change in diet and its digestibility, a physiological adaption also recorded in species other than Galliformes.

A gallbladder and well-developed caecae are present in all Galliformes.

### Reproductive system

Although usually white or buff in colour, the testicles of some Galliformes such as the capercaillie and some breeds of poultry are pigmented a darker colour. The cock birds in all Galliformes have a non-intromittent phallus formed by two lateral folds (the lymphatic phallic bodies) situated on the ventral lip of the vent. During ejaculation, which is very rapid, the lymphatic bodies are momentarily engorged with lymph and the protruding vent is quickly applied to the protruding oviduct of the female. Semen is channelled between the two dilated lateral lymphatic phallic bodies.

Young wild turkeys are sexually mature at 2 years of age. New World quail are sexually mature at 1 year, although amongst the Old World quail (and certainly the Japanese quail, *Coturnix japonica*), some are developed and able to breed at 6 weeks! Grouse mature at 1 year. The male peafowl is not sexually active until 3 years, whilst the hen is mature at 2 years. The common pheasant (*Phasianus colchicus*) is sexually mature at 1 year, whilst in the golden pheasant (*Chrysolophus pictus*) the male bird is not mature until 2 years whilst the hen breeds at 1 year (Plate 26). Differential sexual maturity between the sexes may be an adaption to limit breeding between siblings and so disperse the gene pool.

Hybridization occurs between some species. The grey jungle fowl (*G. sonneratii*)

hybridizes with the red jungle fowl (*G. gallus*), and of course the latter will breed with domestic chickens. The grey hen (*Lyrus tetrix*) will hybridize with the male capercaillie. Some other hybrids may occur between some species of wild grouse.

## Basic biology

The Galliformes are mainly terrestrial birds, and are found in a variety of habitats (Table 12.1). However, all these birds feed mainly on the ground, searching for food by scratching with the feet (except for the eared and monal pheasants, which prefer to use the beak for digging) for seeds, fallen fruit, nuts, roots and invertebrates. The latter are particularly important for growing chicks. Some adult birds are more specialized feeders, such as red and willow grouse, which eat freshly growing heather (*Calluna* spp.) shoots; the spruce grouse, which consume pine shoots; or the sage grouse, which feed on sage tips (*Artemisia* spp.).

Although spending much of their time on the ground, Galliformes, except for those species inhabiting treeless landscape (tundra, moorland, prairie or desert), all prefer to roost in trees.

In all cases the nest is simple, with the grouse, guinea fowl (Plate 27) and quail being satisfied with a scrape in the ground. Pheasants and turkeys will embellish the scrape with a few leaves or twigs. In all cases, the eggs are white or monochrome. Average clutch size and incubation times are indicated in Table 12.2. The downy chicks are nidifugous and able to feed themselves from the time of hatching. In all cases the remiges of the chicks grow rapidly, and all chicks can fly before they are fully-grown. Quail fly at 7 days and grouse at 10 days of age, whilst wild turkey chicks are 2 weeks old before they fly.

## Husbandry

### Housing

All Galliformes need dry frost- and weather-proof shelters or huts placed away from

prevailing wind and direct hot sunshine. Some species, such as the Siamese fireback pheasant, are particularly liable to frostbite. For some species the birds need to be indoors in more substantial buildings supplied with supplementary heating during the winter months; this applies to Bob White and Chinese quail and also to Palawan peacock pheasants. Some guinea fowl and francolins also need good winter protection, although the helmeted guinea fowl, a domesticated bird, is fairly tough provided it has frost protection. In contrast, some of the pheasants (such as Swinhoe's, silver, golden, Lady Amherst's and monal pheasants) are much more hardy and need only an open-fronted shelter with high off-the-ground perches, situated away from direct wind and hot sunshine. The common peafowl is also a hardy bird, in contrast to the green peafowl and the Congo peafowl, both of which need good protection and supplementary heat in severe winter weather.

All shelters and housing should provide appropriate perches, which, in the case of Reeve's and argus pheasants and peafowl, need to be well above ground level so that the long tail feathers do not become damaged. Also, all such shelters and housing should be attached to suitably sized and spacious aviaries. These should provide a minimum of 2–3 square metres of floor space per bird for birds the size of pheasants. About half this floor space should be provided for shelter accommodation. Outside aviaries should be on dry and well-drained ground and preferably have a concrete base, which can be covered with a good layer of sand or peagravel that can periodically be cleared out. However, some species (such as the eared and monal pheasants) like to dig with their beaks in the ground in search of roots and invertebrates. This activity helps to maintain the beak to the correct length, and if these birds cannot dig the bill tends to become overgrown.

The mesh of aviaries should be small enough to prevent the entry of rodents and small predators such as rats and weasels. Loose nylon fish netting placed across the top of an aviary (height approximately 2 m) instead of the more rigid wire netting may help to prevent startled birds that suddenly take off from injuring themselves by collision with an unyielding obstruction.

**Table 12.2** The breeding biology of representative species of Galliformes

<i>Genera/species</i>	<i>Mono- or polygamous</i>	<i>Clutch size</i>	<i>Incubation time in days</i>	<i>Particular characteristics and any special requirements</i>
PHASIANIDAE	With few exceptions (where indicated) mostly polygamous in captivity; one male to four or five females			Most pheasants do not make good mothers. They tend to scatter the eggs. Many semi-domesticated species have lost their normal breeding behaviour and the eggs have to be artificially incubated
<i>Gallus</i> sp. (Jungle fowl)		5–10	20–21	
<i>Lophura</i> sp. (Silver pheasant)		6–12	22–27	
Swinhoe's pheasant		8–12		
Siamese pheasant)		5–8		
<i>Crossoptilon</i> sp. (White, brown and blue eared pheasants)		4–12	24–28	
<i>Syrmaticus</i> sp. (Reeve's pheasant)		8–12	24–25	
<i>Chrysolophus</i> sp. (Golden and Lady Amherst's pheasant)	In the wild monogamous, in captivity one male to three or four females	6–12	23–24	Good mothers: the female matures at 1 year, the male at 2 years. Both sexes quite aggressive during breeding season
<i>Tragopinae</i> e.g Satyr tragopan	Monogamous	4–10	27–37	Often nests in trees. May need to incubate the eggs artificially
<i>Lophophorinae</i> e.g. Himalayan monal pheasants	Monogamous	4–6	27–28	Male bird aggressive to female and needs a large aviary
<i>Argusianinae</i> e.g. Peacock pheasants		2	18–23	All species can be difficult breeders. Both male and female pheasants will defend breeding territory
Argus pheasants		2	24–25	It is wiser to restrict the time the male is left with the female
<i>Parvoninae</i> <i>Parvo</i> sp. (Common pea fowl)		3–8	28–30	Male matures at 3 years, female matures at 2 years
Green pea fowl				Male green pea fowl are very aggressive
<i>Afro parvo</i> sp. (Congo pea fowl)	Monogamous	3–4	26–27	Nest in trees
<i>Tetraonidae</i> Grouse Willow/red grouse, ruffed, hazel, spruce and blue grouse, rock ptarmigan	All are monogamous	All species a minimum of 9 with some species laying up to 30	21–24	The wild species will hybridize if a male of the same species is not available but that of a related species with similar plumage and behavioural characteristics is at hand, e.g. female capercaillie will mate with a male blackcock
Black grouse, sharp-tailed and sage grouse, capercaillie, prairie chicken	All are polygamous and associate in lecking grounds	5–15	24–29	

Table 12.2 Continued

<i>Genera/species</i>	<i>Mono- or polygamous</i>	<i>Clutch size</i>	<i>Incubation time in days</i>	<i>Particular characteristics and any special requirements</i>
<i>Meleagridinae</i> Common turkey, ocellated turkey	Polygamous	8–15	28	Wild hen birds normally associate in a flock in winter. Males will fight to the death. Only the female rears the young, but both male and female guard them
<i>Perdicinae</i> <i>Coturnix</i> sp. (Japanese, harlequin, rain quail)	May be polyandrous in the wild	6–14; if eggs pulled will go on laying up to 200 in a year	16–20	Female birds not good brooders. May need to incubate artificially.
<i>Exafacteria</i> sp. (Chinese painted quail)		5–12	16	Male bird can be aggressive to the chicks, which are extremely small and can escape through small-gauge wire mesh
<i>Partridges</i> <i>Rollulus</i> sp. (Roul Roul, crested green and wood partridge)		2–4	18–20	Can be a difficult species to breed and may need artificial incubation or the use of a bantam hen
<i>Alectoris</i> sp. (Red-legged and Chukar partridge)	Monogamous	8–16	24–26	The male can be aggressive. The hens may not incubate the eggs and a bantam hen may have to be used, but not if the young are to be released for game shooting
<i>Galloperdicine</i> <i>Francolinus</i> sp. (Black francolin)		4–8	19–23	Eggs incubated by the female but tend to be rather erratic breeders
<i>Odontophorinae</i> <i>Callipela</i> sp. (Blue quail)		10–12	22–23	Both the male and female live together in large groups (coveys) outside the breeding season. The cocks become aggressive to young male birds at the start of the breeding season. Females may not brood eggs and artificial incubation may be necessary
<i>Lophortyx</i> sp. (Californian quail)		10–15	22–23	A very easy species to hatch and rear artificially
<i>Colinus</i> sp. (Bob White quail)	Captive varieties are partially polygamous; one male to two females	6–30	22–25	The female bird is an erratic sitter and artificial incubation may have to be used
<b>NUMIDIDAE</b> <i>Acryllium</i> sp. (Vulturine guinea fowl)	Polygamous	8–20	23–28	
<i>Numida</i> sp. (Helmeted guinea fowl)		8–20	24–28	

Galliformes do not require water in which to bathe, but most species appreciate a dust bath; this is particularly important for francolins and Roul Roul partridge.

The aviary can be provided with suitable plants, shrubs and grasses, preferably planted in tubs or shallow pots. These will give some shade and security, enabling birds to hide if they feel the need. This facility is particularly appreciated by such species as Bob White, harlequin and rain quail.

## Aggression

In general it is not good avicultural practice to mix species, although with experience and foreknowledge large mixed aviaries can be successfully maintained. In mixing species there is always a risk of inter-species aggression. There is also the danger of the transmission of infectious disease from a species that is relatively resistant and a latent carrier of a pathogen to a species that is much more susceptible (e.g. turkeys can be latent carriers of histomonas, to which other species are more susceptible).

However, jungle fowl usually mix well with any of the pheasants, and most pheasants and the blue and California quail are safe with arboreal Passeriformes. In contrast, Bob White quail, Japanese quail and partridges are not safe with any other birds. The Chukar partridge will even attack larger species. The male green peafowl is a particularly aggressive bird which not only attacks other birds but also mammals and even humans, using its spurs with devastating effect. In some species the male birds are not safe even to members of their own species, especially to the chicks when the cock bird is in breeding condition. This applies to blue, Californian and Chinese painted quail, and also to the monal pheasants. The cock silver pheasant will try to fight through the wire of an adjoining aviary, and some monogamous grouse will even attack the female bird if the two are confined in too small an aviary. Breeding pairs of some species need to be housed out of sight and sound of similar pairs. In contrast to these aggressive species, all species of guinea fowl do much better if kept in family groups.

## Diet and feeding

The diet provided for captive birds should be as near to their natural diet as possible. However, apart from the domesticated species (domestic chickens, turkeys and, to some extent, guinea fowl, quail and reared pheasants and partridge) for which commercial diets at various age ranges, etc. are available, little scientifically-based information is documented. Much of the following data is derived from the practical experience of aviculturists (Woolham, 1987) and the staff of the North of England Zoological Society.

For Galliformes the following general principles apply:

- 1 Birds should not be overfed. Obese birds do not breed. Captive grouse species do better if the diet has plenty of roughage during the winter non-breeding period.
- 2 Protein needs to be increased during the breeding season and for growing chicks, then gradually reduced.
- 3 Any changes to the diet should be made gradually, since all birds tend only to accept food that they recognize.
- 4 Commercial poultry foods containing coccidiostats may upset the caecal autochthonous flora of some species for which they were not designed, and may even prove toxic.
- 5 Growing chicks need abundant live food. For instance, in the wild, Chukar partridge and grouse will take many kinds of invertebrates such as small snails, slugs and earthworms, and the larvae or pupa of a variety of insects. As the chick grows it gradually changes from a protein-dominated diet to one containing more energy-producing constituents, which again reduces as the bird reaches adult weight. As an alternative to live food, some aviculturists use cottage cheese or hard-boiled egg for growing chicks.

The following give an indication of suitable diets for more specific groups of Galliformes.

### ***Diet A – suitable for adult pheasants, monals, guinea fowl, wild turkeys, jungle and pea fowl***

Equal parts of cereal grains composed of wheat, maize, corn and barley together with game bird pellets. It is probably best to feed

late in the day and let the birds actively search the ground for food early in the day. Some green food such as spinach, cabbage, lettuce, diced carrot, dandelion leaves, clover, chickweed, chives and wild berries (e.g. rowan and bilberry) should be included.

***Diet B – suitable for Californian, blue, Bob White and Japanese quail***

Four parts of plain canary seed (i.e. mixed millet), four parts of chick starter crumbs, three parts of wheat, three parts of split or kibbled maize (i.e. corn) and one part groats (i.e. crushed oats). Some fresh green food such as cress, spinach leaves and a little lettuce should also be included. A vitamin–mineral supplement (such as Vionate or SA37) should also be given.

This diet can also be used for Chukar and red-legged partridge, francolins and peacock pheasants if some live food and wild berries (when available) are added. Live food, either by itself or mixed with a commercial live food substitute (e.g. Nekton Products), can be used. Suitable live food includes mealworms reared on a bran diet, wax moth larvae (these are soft bodied and easily digestible), crickets, locusts and fruit flies. Note that both mealworms and maggots pupate and eventually produce adult insects and, if maggots are fed to birds kept inside, the flies will infest the building. Maggots are probably best avoided because of the danger of botulism, especially if they have been cultured on carcasses. If they are used, let the maggots pupate and then feed the pupa to the birds; however, it may take birds some time to recognize these pupa as food.

***Diet C – suitable for harlequin and Japanese painted quail (i.e. the smallest Galliformes)***

Three parts of each of canary seed, yellow millet, white millet and panicum millet. Green food and a vitamin–mineral supplement should be included as in Diet B.

This diet is also suitable for the Roul Roul partridge if some mixed fruit (for examples, four parts diced pear or apple together with three parts sliced tomato and one part sliced grape) is included. Live food should also be provided as in Diet B.

***Diet D – suitable for tragopans, captive grouse species and snowcocks***

All these birds feed almost entirely on fairly coarse vegetation. They can be fed on branches of willow and birch (catkins and leaves), raspberry plants (leaves and berries), grass, berries, fresh vegetables, fruit (apple), spinach, lettuce and cucumber. A little grain (e.g. oats) or commercial game bird pellets can be added.

***General***

All species need an adequate supply of mixed composition grit of a size suitable for the particular species concerned. This should regularly be completely changed, as the birds tend to select the parts they require. Mixed grit should be composed of limestone chips, oyster shell and cuttlefish bone.

***The management of red grouse on grouse moors***

Unlike pheasants and partridge, grouse for game shooting cannot be reared and subsequently successfully released onto the moor. Numbers of grouse for shooting have to be encouraged by the management of their natural habitat. Red grouse feed predominantly on heather (*Calluna vulgaris* and *Erica* spp.), but will also eat the shoots and flower heads of other plants and the berries of bilberry (*Vaccinium* spp.). The flower heads of cotton grass (*Eriophorum* spp.), which is really a sedge and not a grass, are particularly important for the egg-laying female bird, as the plant contains twice the amount of crude digestible protein as heather.

To encourage the new growth of heather for the grouse to feed on, controlled burning of the plant takes place in the late winter or early spring. The top growth is burnt off, leaving the root stock unharmed. The heather is fired in strips approximately 40 m wide, and this is carried out on a 12–15-year cycle so that a patchwork of varying growth is produced. Fresh nutritious shoots are produced in the spring, whilst taller stands of heather are left for cover in which the grouse can nest. Mammals, especially sheep, carry ticks (*Ixodes ricinus*), and these arthropods carry louping ill

virus, which affects both sheep and grouse. The population density of ticks varies regionally, and is affected by moisture, temperature and the underlying vegetation. In some regions louping ill in grouse can be reduced by vaccinating the sheep. In other areas the ticks are maintained at too high a density by feeding on deer, hares and other small mammals.

Another important factor affecting the numbers of grouse on the moor is predation. Predators have traditionally been controlled by gamekeepers, but this activity is now limited by the Wildlife and Countryside Act, 1981, in the UK. Principle among the predators is the fox, the numbers of which tend to be influenced by the availability of rabbits. The peregrine falcon (*Falco peregrinus*) is also an important predator, as is the occasional hen harrier (*Circus eyaneus*). Both bird species are fully protected by law in the UK.

Grouse numbers are influenced by the nematode *Trichostrongylus tenuis*, which infects the birds' caeca and can prove fatal in heavy infections – or at least reduce fertility in female birds. Heavily parasitized birds are also more liable to predation. Survival of the parasite is favoured by warm, moist conditions, and its numbers tend to rise as the grouse population increases. The larvae of the worm crawl up the heather plants and are ingested by the grouse.

In conclusion, it can be appreciated that the numbers of grouse on the moor can be affected by a complex web of influences. These include the many single interest human activity groups such as sheep farmers, foresters, deer stalkers, hill walkers, bird protection societies interested in the protection of falcons and hen harriers and, of course, the game-keepers.

### **Pheasant and partridge management on shooting estates**

During the nineteenth century large numbers of grey partridge (*Perdix perdrix*) were shot as game birds on big private estates in the UK, and hand rearing of some birds occurred up to the beginning of the Second World War. However, with the reduction in the numbers of gamekeepers employed together with the legal restrictions of the Wildlife and Countryside Act 1981 there has been a consequent

increase in natural predators such as foxes, stoats, weasels and aerial raptors. This change has occurred simultaneously with changes in farming practice, such as the removal of hedgerows and the marginal land surrounding arable crops, and the intensive use of selective herbicides to control weeds – which has at the same time reduced insect food suitable for partridge chicks. Furthermore, all types of insect life have been reduced by the use of pesticides on crops. The net result is fewer and less suitable cover and nesting sites for partridge, with little, if any, insect larvae for growing chicks. Grey partridge are not an easy species to rear in captivity and release successfully.

On the other hand, the red-legged partridge (*Alectoris rufa*) is in some ways less vulnerable to these changes and easier to hand rear. The chicks are much less dependent on insect food from the time of hatching, and will eat grass and search for weed seeds. Red-legged partridge hens will lay two separate clutches of eggs, one of which she will incubate whilst her mate, the cock bird, simultaneously incubates the second clutch. Productivity is therefore doubled. In the wild, however, red-legged partridge are not so good at hiding their nests, so they are more susceptible to predation. Up until 1992, red-legged partridge were crossed with the related Chukar partridge (*Alectoris chukar*) and the hybrids were very successfully released; however, this practice has now been stopped because it was having a detrimental effect on wild-bred red-legged partridge.

Undoubtedly the most important game bird to be hand reared in large numbers is the common pheasant (*Phasianus colchicus*). These birds can be reared intensively using the techniques of the commercial poultry industry, with artificial incubators and large hatcheries dealing with up to 1500 eggs at a time. The newly hatched chicks can then be placed in heated brooders and gradually given access to outside runs. They are subsequently placed in release pens at 6–7 weeks, where they can familiarize themselves with the surrounding habitat. Eventually the birds are released into suitable woodland and game crops. Throughout this period the chicks will be fed on a variety of commercially developed diets, and some feeding often continues after release to retain birds on the estate. Many pheasants still

breed in the wild on shooting estates, particularly where farming practices are such that suitable cover for nesting birds is provided and the ground living predators controlled, and where modern farming procedures have not devastated the insect life.

A suitable balance between hand-reared and wild-bred birds has to be maintained, as evidence suggests that artificially-reared birds are not so viable for the following reasons:

- 1 Truly wild birds are more alert and will react quicker to predators.
- 2 Wild birds take and survive better on a greater range of wild foods.
- 3 Hand-reared birds are less resistant to the parasite *Heterakis* spp.
4. Muscle development in hand-reared birds is heavier and take-off flight is therefore less rapid and at a shallower angle.

In the past game birds' eggs have been incubated and hatched under bantam hens, but it has been shown that the behavioural responses to predator attack learned from the bantam hen may be inappropriate to the game bird chick; hence mortality rates were higher.

When investigating disease in all game birds, it is essential that the veterinarian takes a broad holistic view and is aware of the complexity of environmental influences on the overall health of these birds.

## Breeding and sexing Galliformes

Most species of Galliformes are markedly sexually dimorphic, with the male having more colourful plumage, often a larger body size, a longer tail and the presence of combs or wattles. In a few species of Phasianidae, which are not so easy to distinguish, the cock birds have spurs on their legs. In guinea fowl that are not sexually dimorphic the male usually has a voice with a greater range of sound, and in the helmeted and plumed guinea fowl the appendage on the head is slightly larger. In both Old and New World quail, the sexes are similar in appearance but have behavioural differences. Most Galliforme chicks are not sexually dimorphic and can only be sexed, like domestic poultry, by the meticulous examination of the cloaca by a skilled technician. However, grouse chicks are distinguishable, the males being slightly larger.

Some species of Galliformes are monogamous, whilst in other species a cock bird can be kept with several hens. In some species the cock birds are particularly aggressive during the breeding season, not only to other species of birds but also to their own hen birds – particularly if they can see or hear another cock.

### *Some general principles when breeding Galliformes*

- 1 When introducing a new cock bird to an unfamiliar hen, always place the hen in the aviary first.
- 2 Many male birds will chase the female during normal courtship behaviour, but the female does need a sufficiently large aviary to escape if she so desires. It also may be helpful to clip the cock bird's wings. If there is a definite difference in size between male and female, the two sexes can be kept in adjoining aviaries with a connecting passage only just large enough for the hen bird to pass through. This system can be used for capercaillie.
- 3 Most Galliformes lay their eggs in a primitive nest on the ground but some species are tree nesters, and these should be provided with a flat wooden tray or basket containing hay, moss and dried leaves and situated approximately 1–2 m above the ground level. Typical tree-nesting species include the Congo pea fowl, bronze-tailed peacock pheasant and crested argus pheasant. All nesting sites, whether in trees or on the ground, should be provided with visual security.
- 4 In some species, greater breeding success is achieved if the eggs are incubated artificially. Such species include the New World quail, blue quail, Californian quail, Bob White quail and also Japanese quail from the Old World.
- 5 Fostering using a broody bantam or Japanese silky hen to incubate and rear the chicks is a practice used by many aviculturists when a particular species is difficult to breed in captivity. If the foster hen is sitting quietly and tight, her eggs are exchanged for those to be hatched after 3 days. Species where this technique has been used include the common pheasant, partridges (Chukar, red-legged, Roul Roul and green wood),



tragopans (Plate 28) and Palawan peacock pheasants, and grouse.

- 6 After the chicks have hatched and dried, they should be placed in boxes approximately 50 × 100 cm with a heat source so as to maintain a floor temperature of 40°C. A 150 W infrared lamp can be used. Damp cloths can be used on the sides of the box to maintain a relative humidity of 60 per cent. Placing the chicks on towels (changed frequently) spread on the floor will help to prevent splayed legs. After 8–12 days, the chicks can be placed in a large rearing pen outside if the weather is suitable. This is best provided with a wire mesh floor to prevent slipping and splayed legs.

### ***The investigation of infertility in a breeding pair of birds***

- 1 In some birds, particularly grouse, the hen chooses the cock bird with which to mate. If the male bird provided is not of her choice or is incompatible, mating will not take place even though infertile eggs may be laid.
- 2 If male or female have recently been acquired from different countries of different latitudes, even if they are of the same species, their breeding cycles may not be synchronized.
- 3 If two cock birds spend all their time fighting through the wire of their adjoining aviaries, they may not have time to mate with their hens.
- 4 The age and general condition of the bird should be considered. Aged and particularly obese hens do not breed.
- 5 Finally, infectious disease should be ruled out.

## **Disease in Galliformes**

The important infectious diseases of Galliformes are listed in Table 12.3 and organized according to their presenting clinical signs. Each disease in these notes has been numbered to make cross-referencing easier.

Rarely is any disease syndrome entirely due to a single pathogen. Usually the condition originates from a multiplicity of causes, some of which may be management related.

It is essential to consider all possible predisposing factors.

Standards of hygiene are not always high, nor is prophylactic vaccination or regular systemic control of parasites always routinely carried out.

### **Considerations when investigating disease**

First consider whether the problem is primarily management related or a serious epizootic (i.e. an epizootic disease of birds). The latter, particularly viral infection, is usually seen in birds kept in flocks through which disease can spread rapidly.

#### ***Management problems***

Inadequate housing, hygiene and diet can predispose to disease.

#### ***Inadequate housing***

Housing must be suitable for the species. Some species require supplementary heating in winter. Overcrowding of birds in a corner of a house in cold weather not only results in smothering but can also lead to a localized build-up of ammonia fumes, causing coryza, corneal ulceration, blindness and a predisposition to respiratory problems. Accommodation should be completely wind- and weather-proof. Perches must provide adequate space between perched birds, be periodically renewed and be the correct height from the ground. There should be sufficient floor space and space in the outside aviaries. Overcrowding leads to increased stress, aggression, feather picking and cannibalism, which in some cases may need to be controlled by plastic spectacles or beak clipping. Overcrowding in aviaries can also result in an unsustainable parasite load. However, in cases with low parasite levels and in otherwise healthy stock this can sometimes confer a degree of resistance to the parasite.

#### ***Hygiene***

The housing should be thoroughly cleaned out and disinfected and the outside aviaries sufficiently rested before new stock is introduced. Very many pathogens (see disease Nos. 3, 4, 6, 7, 10, 12, 18, 19 20, 21, 22, 23, 25, 27, 28, 29, 30, 35,

Table 12.3 Avian diseases

No.	Disease	Primary Cause	Species susceptible	Particular disease characteristic	Diagnosis
<b>Diseases primarily exhibiting respiratory signs (i.e. sneezing, wheezing, coughing, rattling with each respiration, gasping for air, dyspnoea and often ocular or nasal discharge together with anorexia)</b>					
1.	Mycoplasmosis ('Roup')	<i>Mycoplasma</i> spp. Many species and strains, primary spread by close contact. Latent carriers Turkeys are infected venereally	All species of Galliformes	May be an asymptomatic infection. Often secondary infection governs the severity of the disease. Usually the infra-orbital sinuses swollen, but the bird's joints may be affected	PM, histopathology, serology, culture (special transport media)
2.	Chlamydiosis Ornithosis. Zoonosis	<i>Chlamydia</i> sp. Several strains. Intermittently shed in faeces	All Galliformes but particularly turkeys.	Respiratory signs may be accompanied by diarrhoea. Some birds exhibit only a vague debility	PM, histopathology, serology, cytology, culture
3.	Infectious laryngotracheitis	Herpesvirus carried by latently infected birds. Can persist in fomites for at least 3 months	Mainly chickens and peafowl but also pheasants and turkey poult	Can be a mild or subclinical to a severe infection with birds having extended head and neck, gasping for air. May die in 2-3 days. The sinuses may be swollen (Compare to No. 1) and the birds may cough a bloody mucus. Oropharynx and trachea may show diphtheritic membranes	PM, histopathology, virus isolation
4.	Newcastle disease ('fowl pest'). Zoonosis	Group I Paramyxovirus: Virus is contained in infected faeces	All species of Galliformes, particularly backyard fowl. All grouse tend to be fairly resistant and in partridges the infection may be asymptomatic	Respiratory signs may be accompanied by a greenish, watery diarrhoea and some birds exhibit CNS signs. Grouse may <i>only</i> show a conjunctivitis together with loss of weight	PM, serology, virus isolation
4a.	Pigeon paramyxovirus disease	Group I Paramyxovirus (pigeon variant)	Can affect chickens, pheasants and peafowl	In UK many wild pigeons are carriers. Signs similar to Newcastle disease	
5.	Turkey rhinotracheitis ('swollen head syndrome')	Pneumonovirus. Related to the paramyxoviruses	Principally turkeys but also pheasants, chickens, Guinea fowl. Can cause egg drop in chickens	Upper respiratory signs with swollen sinuses (Compare to Nos 1 & 3) and conjunctivitis. Morbidity and mortality can be high	PM, serology, virus isolation

Table 12.3 *Continued*

<i>No.</i>	<i>Disease</i>	<i>Primary Cause</i>	<i>Species susceptible</i>	<i>Particular disease characteristic</i>	<i>Diagnosis</i>
6.	Avian influenza (fowl plague of the 1890s; also known as 'fowl pest'). Zoonosis	Influenza A viruses. Many strains, fairly environmentally stable in faeces, particularly free-ranging waterfowl	All Galliformes but particularly pheasants, chickens and Japanese quail	The subtypes of the virus are constantly changing so that morbidity and mortality vary together with secondary infections. Respiratory signs vary from mild to severe. Oedema of the head and neck may occur (Compare to Nos. 1, 3 & 5) as well as egg drop	PM, virus isolation
7.	Fowl adenovirus ('vent gleet')	Group I fowl adenovirus. A number of serotypes. Birds may be latently affected	Chickens, particularly backyard fowl, also Guinea fowl and Japanese quail and pheasants	Infection can be subclinical to a moderately severe respiratory disease accompanied by mucoid pasty white droppings causing an offensive smell and adherent to the vent. Mortality can be 10–30%. There may be an egg drop syndrome. Guinea fowl can develop a pancreatitis or marble spleen-like disease (No. 9). Pheasants may die suddenly with no premonitory signs	Serology, virus isolation, PM, histopathology (oviduct)
8.	Quail bronchitis	Group I adenovirus	Bob White quail	100% of very young chicks under a week old may suddenly die. Older chicks up to 6 weeks show severe respiratory signs with greenish diarrhoea and the occasional dropped wing and die in 24–48 hours	Serology
9.	Marble spleen disease	Group II adenovirus	Pheasants, Guinea fowl, chickens.	This is not primarily a respiratory infection but the grossly enlarged spleen may cause dyspnoea through pressure on the air sacs (see No. 27 for more detail)	See No. 28
10.	Infectious bronchitis ('blue comb of turkeys')	Coronavirus. Virus shed in faeces, spreads in contaminated water and food or from poultry-manured fields. Different serotypes in chickens, pheasants, Guinea fowl, Japanese quail, turkeys	All Galliformes but particularly pheasants	Respiratory signs may be mild with only a drop in egg production. Pheasant chicks (8–10 weeks) may sustain a 40% mortality. Guinea fowl may develop an enteritis and pancreatitis and chicks as young as 3 days old may die but are usually protected by maternal antibody	PM, serology

Table 12.3 Continued

No.	Disease	Primary Cause	Species susceptible	Particular disease characteristic	Diagnosis
11.	Aspergillosis ('brooder pneumonia')	<i>Aspergillus fumigatus</i>	All Galliformes, particularly turkey and pheasant	Usually seen in chicks up to 4 weeks old. Can vary from sudden death to a chronic wasting disease with some respiratory signs. Occasional paralysis in older birds	PM, serology, culture
12.	Syngamiasis ('gapes')	<i>Syngamus</i> spp. Transport hosts, e.g. earthworms, slugs and beetles	All Galliformes particularly those in overstocked grass aviaries	Typical gasping for air (compare to No. 3) cough, head shaking, anorexia and loss of condition. Usually individual birds affected sporadically	Faecal exam, visual exam
13.	Trichomoniasis	Protozoan	All Galliformes but particularly pheasants	Dyspnoea may result from exudate obstructing the airway (See No. 36)	See No. 36
14.	Cryptosporidiosis	A coccidial protozoan parasite which grows on all mucosal epithelia. Ingestion or inhalation of sporulated oocyst. Resistant to many disinfectants	Recovered from the respiratory tract of many Galliformes	May be a primary pathogen but often a secondary invader of immunosuppressed birds causes inflammation and typical upper respiratory signs also diarrhoea (See No. 32).	PM, faecal exam (Giemsa stained)
15.	Avipox	Fowl pox virus infects pheasants and peafowl. Quail pox distinct virus but can infect chickens and turkeys. Biting insects may act as transport vectors	All Galliformes	Lesions on skin dry. Diphtheric lesions on respiratory mucosa. May cause severe respiratory signs and death. May be egg drop. Can cause up to 30% mortality in quail	Culture, cytology
16.	Infectious coryza	<i>Haemophilus</i> spp.	All Galliformes but usually chickens, turkeys and pheasants	Often cultured as a secondary infection from other primary disease. Signs include rhinitis, sinusitis, air sacculitis and pneumonia	PM, culture
17.	Turkey coryza	<i>Alcaligenes</i> spp. <i>Bordetella</i> spp. Shed in faeces and contaminate water and food supply	Usually turkeys	Opportunistic pathogens, sometimes occurring as secondary invaders associated with turkey rhinotracheitis (See No. 5)	Culture
18.	Cryptococcosis, torulosis, blastomycosis, histoplasmosis. Zoonosis	Saprophytic fungi which may occur in old wooden and insanitary aviaries. Inhalation of spores	All Galliformes	Can cause gelatinous granulomatous lesions on the mucous membranes of respiratory and gastrointestinal tracts. Also systemic lesions in the viscera. Individual birds affected sporadically	Faecal exam, culture, histopathology

Table 12.3 Continued

No.	Disease	Primary Cause	Species susceptible	Particular disease characteristic	Diagnosis
19.	Avian mycobacteriosis	<i>Mycobacterium avium</i>	All Galliformes	Peafowl are documented as having been presented with rattling sounds due to granulomata in the trachea (See No. 69)	Culture, histopathology
<p>Many commonly known bacteria such as <i>Staphylococci</i> spp., <i>Streptococci</i> spp., <i>E. Coli</i> and <i>Klebsiella</i> spp. act as secondary invaders of avian respiratory disease</p>					
<p><b>Diseases primarily presented with signs of alimentary disorder (i.e. diarrhoea in varying forms) occasionally vomiting accompanied sometimes by malaise and loss of condition</b></p>					
20.	Salmonellosis. Zoonosis	<i>S. typhimurium</i> , <i>S. enteritidis</i> . Faecal dust, carriers: wild birds, rodents. Vertical transmission and latently infected birds	All Galliformes, particularly backyard fowl	Depression and diarrhoea, death may occur, also death without any premonitory signs	PM, culture
21.	Pullorum disease, bacillary white diarrhoea	<i>S. gallinarum</i> , <i>S. pullorum</i> . Latent carrier birds. Poor hygiene	All Galliformes, but common in backyard fowl	Enteritis, malaise. In Pullorum disease malformed ovules in the ovary, enlarged liver and spleen	PM, culture, serology
22.	Coli bacillosis	<i>Escherichia coli</i> . Ingestion and inhalation of faecal dust. Some strains produce a potent toxin. Can be a primary or secondary pathogen	All Galliformes, but particularly backyard fowl. Also turkeys, peafowl, partridge and capercaillie	Coliform septicaemia may cause acute deaths or a brownish diarrhoea with stunted growth and poor feathering. Birds may develop coliform granulomata in the liver and spleen and a peritonitis and air sacculitis due to coli septicaemia	PM, culture
23.	Campylobacteriosis. Zoonosis	<i>Campylobacter</i> spp. Many serotypes shed in faeces, which contaminate food and water supplies. Poor hygiene	All Galliformes	Weight loss, yellowish diarrhoea (caused by hepatosis) sometimes bloody and eventual death. At PM, focal necrosis of the liver. Spontaneous recovery and relapse are not uncommon. Spread through a flock is often slow	PM, culture (special transport media)
24.	Clostridial enterotoxaemia	<i>Clostridium perfringens</i>	All Galliformes but particularly game birds, i.e. grouse and New World quail	In young birds (10 days and over) a haemorrhagic enteritis leads to bloody diarrhoea with polydipsia and death. In older birds the infection is more chronic with gradual weight loss before death. At PM, hepatomegaly and necrotic enteritis	PM, culture, toxin identification

Table 12.3 Continued

No.	Disease	Primary Cause	Species susceptible	Particular disease characteristic	Diagnosis
25.	Chlamydiosis. Zoonosis	<i>Chlamydia</i> sp. Intermittently shed in faeces	All Galliformes, but only well documented in turkeys	Diarrhoea, respiratory signs, unthriftiness (See No. 2)	See No. 2
26.	Newcastle disease. Zoonosis	Group I paramyxovirus, also Group I paramyxovirus (pigeon)	All Galliformes	May be a greenish diarrhoea together with or without respiratory and CNS signs (See Nos. 4 and 4a)	See No. 4
27.	Fowl adenovirus disease ('vent gleet')	Group I fowl adenovirus. In faeces. Persistent in the environment. Hygiene important	Chickens, Guinea fowl, Japanese quail	An enteritis with white pasty mucoid droppings adherent to the vent and causing an offensive smell (See No. 7)	See No. 7
28.	Turkey haemorrhagic enteritis	Group II adenovirus. Shed in faeces. Very environmentally persistent	Turkeys, chickens, pheasants	Only documented in domesticated birds, not in wild turkeys. Affects young birds from 4–12 weeks causing up to 60% mortality. Can be asymptomatic or cause severe and haemorrhagic enteritis	Serology
29.	Pheasant marble spleen disease	Group II adenovirus. Virus may persist in the environment for months. Good hygiene is imperative, particularly in rearing pens	Primarily pheasants, but can also affect Guinea fowl and chickens, and documented in blue grouse	Only documented in captive birds, not in wild free-living birds. Affects young birds 3–8 months old causing highest mortality (i.e. 20%) in young birds. Pheasants may die suddenly or become anorexic, depressed and show diarrhoea and dyspnoea (See No. 9)	PM, serology
30.	Coccidiosis	<i>Eimeria</i> spp. Protozoan parasites generally host- specific so cross- species infection does not usually take place. Can be environmentally persistent	All Galliformes, particularly young birds circa 3 weeks. Adults may act as latent carriers	Disease may be exhibited as anything from a vague pathogenic syndrome causing listlessness to a severe enteric disease with mucoid bloody faeces dependant on parasite load and other predisposing causes	Faecal exam
31.	Cryptosporidiosis	<i>Cryptosporidium</i> spp. A coccidial protozoan.	All Galliformes	Invades the whole of the alimentary tract causing diarrhoea and malabsorption (See No. 14)	See No. 14
32.	Hexamitiasis	<i>Hexamita</i> spp.	Turkeys	Can cause heavy loss in turkey poults around 3 weeks of age causing diarrhoea and unthriftiness	Faecal exam

Table 12.3 Continued

No.	Disease	Primary Cause	Species susceptible	Particular disease characteristic	Diagnosis
33.	Quail herpes or Colinus disease	Herpesvirus	Bob White quail under 4 weeks	Depression, anorexia and diarrhoea and death in 3–4 days. Focal necrosis of enlarged liver and spleen	PM, serology
34.	Histomoniasis ('blackhead')	<i>Histomonas meleagridis</i> . A protozoan carried by the ova of caecal worms. <i>Heterakis</i> spp. earthworms may act as vector	All Galliformes but particularly turkeys, pheasants. Partridge if in close contact with chickens	Yellowish diarrhoea (because of hepatopathy). Sometimes birds just unthrifty. Particularly common without regular deworming	PM, faecal exam
35.	Helminth worm infestation	<i>Ascaridia</i> spp., <i>Capillaria</i> spp. <i>Heterakis</i> spp. Ova persist in environment	All Galliformes	All helminths may cause a mucoid diarrhoea or just general unthriftiness. Occasional sudden death	PM, faecal exam
36.	Candidiasis	<i>Candida albicans</i> . Opportunistic yeast	All Galliformes, especially young turkeys, partridge and captive grouse	Primary or secondary pathogen of upper alimentary tract results in delayed crop emptying and vomiting with sporadic death	Cytology
37.	Trichomoniasis	<i>Trichomonas gallinae</i> . A flagellated protozoan. Thrives in poor hygiene	All Galliformes, but particularly pheasant chicks in crowded conditions	Causes cheesy exudate in oropharynx resulting in vomiting, diarrhoea, dyspnoea. Unthriftiness and sporadic death, particularly in chicks	Cytology
38.	Gumboro disease ('infectious bursitis')	A Birna virus disease so called from first identification at Gumboro, USA. Very environmentally persistent in contaminated faeces	Chickens 3–6 weeks old. Pheasants (up to 80% mortality), turkeys	Necrotic bursa of Fabricius results in severe immunosuppression resulting in secondary infection. Affected chicks may be anorexic with watery diarrhoea and die	PM, histopathology, virus isolation
39.	Spirocheatosis	<i>Borrelia gallinarum</i> . Transport host ticks. Also sometimes mosquitoes	All Galliformes. Young chicks 4–8 days reared on rough pasture inhabited by ticks	May be sudden death or dullness with yellow diarrhoea, ataxia and then death. Mortality up to 100%. Hepatomegaly with necrotic foci	PM, serology, stained blood smear
40.	Tagoviruses	See disease No. 47	All Galliformes	Sometimes cause diarrhoea (See No. 47)	Virus isolation
41.	Stunting and runting syndrome ('viral enteritis')	Reo- and rotaviruses	All Galliformes	Infection sometimes results in diarrhoea (See No. 64)	Virus isolation
42.	Reticulo-endotheliosis	Reticulo-endothelial virus	All Galliformes	Infection occasionally exhibits signs of an enteritis (See No. 65)	Virus isolation

Table 12.3 Continued

No.	Disease	Primary Cause	Species susceptible	Particular disease characteristic	Diagnosis
43.	Helminth worms in grouse	<i>Trichostrongylus tenuis</i> . Worm thrives in warm moist heather	Grouse	Worm invades and severely damages the caecal mucosa causing a haemorrhagic enteritis. Birds usually found dead. May be unthrifty with bloody diarrhoea	PM, faecal counts not reliable
43a.	Vitamin C deficiency in grouse chicks	Young growing chicks up to 4 weeks do not produce sufficient endogenous Vitamin C. Need to obtain it from wild berries, etc.	Only documented in willow ptarmigan, but may be a factor in other grouse chicks	Weight loss, petechiae in muscles, weakness, enteritis, fractures and bone dystrophia, death	PM
<b>Diseases presented with clinical signs related to either the nervous or locomotor systems (i.e Torticollis, opisthotonos, dropped or trailing wings, paralysis, lameness, etc.)</b>					
44.	Marek's disease	Herpesvirus. Very environmentally persistent in feather debris. Latently infected chickens maintain infection. Tends to be geographically localised	All Galliformes. Mortality in adults 10–15%, in chicks up to 40%.	Young chicks under 3 weeks rarely affected. Usually affects female birds 6–12 weeks up to time of laying. Lymphoid thickening of peripheral nerves and visceral tumours. Results in lameness, dropped wing, paralysis, emaciation, death. Vaccine breakdowns occur. Compare Nos. 67 and 45	PM, histopathology, serology, virus isolation
45.	Avian sarcoma leucosis syndrome	Caused by a number of RNA viruses. Very environmentally stable. Disease may flair up in periods of stress. Latently infected birds	All Galliformes, especially chickens and pheasants. In contrast to Marek's Disease (No. 44) usually affects birds over 14 weeks old	Note: partridge and quail affected by a distinct species-specific virus. Female birds more susceptible. Multiple tumours seen throughout body. Clinical signs similar to Marek's (No. 44) but vary with site of neoplasm. Tumours may cause thickening of legs	PM, histopathology, serology
46.	Newcastle disease ('fowl pest')	Group I paramyxovirus, also pigeon variant	All Galliformes, particularly backyard fowl	A variety of CNS signs, together with respiratory and enteric disease signs (See Nos. 4 and 4a)	See No. 4



Table 12.3 Continued

No.	Disease	Primary Cause	Species susceptible	Particular disease characteristic	Diagnosis
47.	Eastern and Western equine encephalitis and similar infections. Zoonosis	Togaviruses, EEE and WEE virus. Restricted to USA. Similar viruses occur in other parts of the world. Transmitted by biting insects, e.g. mosquitos, therefore a seasonal disease	All Galliformes. Mortality in turkeys 6%, pheasant 5–8%, quail 40–90%, partridge 30–90%	Can be asymptomatic. Mortality is highest in those species non-indigenous to a region. A variety of clinical signs of CNS as well as anorexia, ruffled feathers, diarrhoea and sudden death	Histopathology, virus isolation
48.	Specific avian encephalomyelitis ('epidemic tremor')	An enteropicornia virus shed in faeces. Can persist in litter for years. Both vertical and horizontal transmission	All Galliformes, but not in free-living wild birds	Young birds up to 16 weeks, particularly 2–4 weeks old. Acute epidemic with variety of CNS signs. Survivors exhibit persistent eye lesions. Adult birds show drop in egg production. Note: folic acid deficiency can be responsible for paralysis of the neck in turkey poults	Serology
49.	Louping ill (so called because infected sheep 'loup' or stagger). Zoonosis	A flavivirus, transport host ticks. Restricted to British Isles	Grouse and pheasants on tick infested rough pasture and woodland also grazed by mammals	Produces a variety of CNS signs. A serious problem on some grouse moors. May be asymptomatic, birds just found dead	Serology
50.	Turkey meningio-encephalitis virus	A flavivirus, only so far documented in Israel and S Africa. Vector unknown	Turkeys over 10 weeks, mortality 10–80%, also in Japanese quail and chickens	Virus recovered from free-ranging wild birds, causes paralysis and a drop in egg production	Serology
51.	Fowl adenovirus infection	Group I fowl adenovirus.	Chickens, particularly backyard fowl, Guinea fowl, Japanese quail	In addition to other clinical signs, may cause CNS signs (See No. 7)	Virus isolation
52.	Botulism	<i>Clostridium botulinum</i> . Toxin, may be contained in maggot-infested carcasses or in sewage	All species particularly backyard fowl	Not nearly so common in Galliformes as in waterfowl. May cause paralysis, usually found dead	Serology
53.	Bacterial encephalitis	A variety of pathogens from systemic infection	All Galliformes	A variety of CNS signs usually with accompanying other clinical signs. Possibly also signs of trauma	Histopathology, PM, culture
54.	Toxins	A great variety of agricultural and industrial chemicals may pollute water supplies or the atmosphere. Misused chemotherapeutics	All species	Free-ranging wild birds may be affected at the same time. A variety of CNS and other clinical signs are seen, often just found dead	Deep frozen, separately wrapped tissues

Table 12.3 Continued

No.	Disease	Primary Cause	Species susceptible	Particular disease characteristic	Diagnosis
55.	Reovirus ('stunting and runting' syndrome)	Reo- and rotaviruses	All Galliformes, particularly chicks	Infection may produce a tenosynovitis and arthritis with enlarged hocks and ruptured gastrocnemius tendons (See No. 64)	See No. 64
56.	Reticulo-endotheliosis	Reticulo-endothelial virus	All Galliformes, particularly chickens 3-8 weeks	Apart from other clinical signs may show lameness, dropped wings and other CNS signs (See No. 65)	See No. 65
57.	Bumblefoot	A pododermatitis caused by a variety of pathogenic bacteria invading a traumatized foot in unhygienic conditions	All Galliformes, but particularly backyard fowl kept in unhygienic conditions	Swelling of the foot and occasionally the hock. Lameness and loss of condition. Old birds on worn out or unsuitable perches	
58.	Fractures	Usually caused by rough handling	All Galliformes	Lameness, paralysis, dropped wing	

**Diseases that show few, if any, premonitory signs but which may cause unthriftiness and loss of condition**

59.	Pullorum disease	See disease No. 20			
60.	Colibacillosis	See disease No. 21			
61.	Spirochaetosis	See disease No. 39			
62.	Ornithosis	See disease No. 2			
63.	I.L.T.	See disease No. 3			
64.	Marek's disease	See disease No. 44			
65.	Avian sarcoma leucosis syndrome	See disease No. 45			
66.	Pox virus infection	Avipox virus may be spread by biting insects. Virus in faeces. Fowl pox virus infects only chickens, grouse and pheasants. Turkey pox, quail and pheasant pox and peafowl pox viruses infect chickens	All Galliformes. Common in unvaccinated flocks of pheasants. Some free-living wild bird pox viruses infect chickens, e.g. sparrow pox, starling pox, magpie pox, some pigeon pox. Free ranging wild turkey pox infects domestic birds	Sometimes an apparently asymptomatic subacute to chronic infection. Yellowish brown scabs on skin of head and legs. Diphtheritic lesions in oropharynx and trachea cause dysphagia and asphyxia (See No. 15). Compare to disease Nos. 3, 11, 35 and 36. Tends to occur seasonally when biting insects (mosquitoes, mites) are abundant. Morbidity in wild free ranging New World quail is quite high. Mortality in captive quail can up to 40%	Histopathology, virus isolation, faecal exam. by electronic microscopy, culture, serology

Table 12.3 Continued

No.	Disease	Primary Cause	Species susceptible	Particular disease characteristic	Diagnosis
67.	Stunting and runting syndrome (viral enteritis)	Reo- and rotaviruses. Adult birds may act as latent carriers. Biting insects may spread viruses, which are environmentally stable	All Galliformes, the young being more susceptible: chickens 4–10 days, partridge 6–56 days	An immunosuppressive disease affecting alimentary mucosa causing malabsorption. May also be abnormal feathering. May have diarrhoea, secondary infection produces other signs	PM, virus isolation, faecal exam. by electronic microscopy, serology
68.	Reticulo-enderthelial virus	Reticulo-endothelial virus	All Galliformes, particularly chickens 3–8 weeks. Mortality may be 100%	Weight loss, anaemia, growing feathers fail to exsheath. Subcutaneous nodules on head and oral mucosa or sinusitis. Multivisceral neoplasms. Compare to diseases Nos. 44 and 45	Histopathology, virus isolation, serology
69.	Aspergillosis	<i>A. fumigatus</i>	All Galliformes	Can be presented as a chronic wasting disease (See No. 11 )	Culture, serology
70.	Avian tuberculosis and paratuberculosis. Zoonosis	<i>Mycobacterium avium</i> . 3 subspecies. Infected birds shed large numbers of organisms in faeces. Environmentally persistent. Ectoparasites act as vector	All Galliformes, particularly backyard fowl	Chronic wasting disease often quite alert, appetite unaffected. Anaemia, dull plumage. Possibly sporadic diarrhoea and occasional lameness. May be granulomata in oropharynx or in conjunctival sac. Compare to disease Nos. 3, 11, 35, 36 and 65	PM, culture, histopathology
71.	Coccidiosis	See disease No. 29			
72.	Cryptococcosis	See disease No. 18			
73.	Histoplasmosis	See disease No. 33			
74.	Hexamitiasis	See disease No. 31			
75.	Leucocytosis	A haemoprotozoan parasite, <i>leucocytozoon</i> spp. transmitted by biting flies <i>Simulium</i> spp. and <i>Culicoides</i> spp.	All Galliformes, particularly young birds	Can cause anaemia, unthriftiness and anorexia	Haematology
76.	Helminthiasis	<i>Ascaridia</i> spp. Proventricular and gizzard worms, capillariasis, heterakis (caecal worms), trichostrongylidiasis (in grouse)	All Galliformes	All these helminth infections may cause loss of condition without any other clinical signs	Microscopy

Table 12.3 Continued

No.	Disease	Primary Cause	Species susceptible	Particular disease characteristic	Diagnosis
77.	Ectoparasitosis. All may act as mechanical vectors of other pathogens	Lice	All Galliformes	Only heavy infection important, usually species-specific therefore cross-species infection unlikely. Whole life cycle on host	Diagnosis by shaded light at night
		Fleas, a number of types		Not so species-specific as lice but eggs and larvae environmentally persistent	
		<i>Dermanyssus</i> spp. (red mite, roost mites)		Can cause severe anaemia, unthriftiness and death in young. Environmentally persistent	
77a.	Feed nightly. Zoonosis	<i>Ornithonyssus</i> spp. (fowl mites)		Signs as for <i>Dermanyssus</i> spp. but parasite never leaves host, therefore more pathogenic. High mortality	
		<i>Trombicula</i> spp. (harvest mites)		Seasonal causing pruritus and damage to plumage	
		<i>Knemidocoptes</i> spp. ('scaly leg')		Causes pruritus. Compare to disease No. 65	
		Ticks ( <i>Ixodes</i> spp. and others)		Pruritus, anaemia, occasional fatal toxin kills chicks	

38, 44, 45, 48, 70, 76 and 77 in Table 12.3) are environmentally persistent in dirty wooden buildings with faeces, exudate and formites. Water supplies and food containers easily become contaminated, particularly by some pathogens (e.g. disease Nos. 2, 4, 6, 10, 17, 22, 23, 37, 38, 52, 54 and 70). Invertebrate vectors may help in maintaining disease in empty enclosures or may transmit or themselves cause disease (e.g. disease Nos. 12, 15, 34, 47, 49, 66, 67, 70 and 77). Vermin and wild free-living wild birds may carry disease, and can infect an aviary with their faeces or exudate if these are allowed to enter the bird enclosure (e.g. disease Nos. 4a, 6, 20, 23 and 39).

#### Diet

This must be adequate in quantity and properly balanced, particularly for the growing stage of chicks or in relation to the breeding

cycle. Food should be stored properly so that it is not mouldy or contaminated with the droppings of vermin or with forage mites (note: some mycotoxins, besides being overtly poisonous, can be immunosuppressive). A sudden increase in the number of cases of visceral gout in a flock may be the result of a faulty water supply or dietary imbalance. All fresh vegetables must be adequately washed (they may be contaminated by wild bird faeces or industrial aerial pollution).

#### First thoughts on infectious disease

##### Age group affected

First consider whether the problem is confined to a certain age group of birds.

**Chicks from hatching up to approximately 10 days of age**

Some of these chicks may be weak, not feeding properly and failing to thrive. This can be due to faulty incubation (humidity may be wrong), or they may just be genetically small. Small chicks easily get chilled (or can overheat) if in the brooder or with a bad hen. The artificial brooder ventilation may be faulty; there may be a build-up of fumes (ammonia, possibly carbon monoxide). All these predisposing causes may be presented as an *E. coli* or aspergillosis infection. Alternatively, poor incubator hygiene may be seen as umbilical or yolk sac infection.

Chicks in this age group that fail to thrive may be affected by an acute form of runting syndrome (see disease No. 67 in Table 12.3). Sudden death in very young quail chicks may be caused by an adenovirus (Disease listed No. 8). Sudden death in young chicks of all species in outside aviaries could be due to spirochaetosis (disease No. 39).

**Disease in older chicks from about 10 days to approximately 11 weeks**

These birds are also liable to runting syndrome (disease Nos. 67 and 68), Marek's disease (disease 44) and Gumboro disease (disease 38). All these diseases are immunosuppressive, so the clinical signs may be caused by a secondary infection. Other disease problems in this age range include coccidiosis (disease No. 30), necrotic enteritis (24 and 28) and infectious bronchitis (10). Hexamitiasis can be a problem in turkey poults (23). The possibility of mycotoxins should always be considered.

**Conditions affecting older growing birds over about 11 weeks of age**

This age group may also be affected by Marek's disease (disease No. 44), particularly if they are female birds coming up to lay. However, they are more likely to be affected by the avian sarcoma leucosis virus (45). Pheasants in this age group are often severely affected with marble spleen disease (29). Both candidiasis (36) and trichomoniasis (37) can be a problem in young growing birds, particularly turkeys, pheasants, partridge and captive grouse.

**Mixed species collections**

Mixing widely different taxa of birds is never a good idea because some species are much more susceptible to certain diseases, whilst others can be asymptomatic and act as latent sources of infection (e.g. disease Nos. 4, 34, 7 and 10).

**Quarantine**

Owners of backyard flocks often purchase their stock from a variety of sometimes dubious sources – markets, pet shops or poultry shows – or acquire them from friends or relations. Most of these birds will be unvaccinated, and many will be carrying parasites. Some will be sera-positive for adenoviruses and mycoplasma, and may be latent carriers of disease. All new stock should be adequately quarantined from the main flock for at least 90 days. When newly acquired chicks are all obtained from one source, a period of 30 days may be sufficient.

**Use of vaccines**

Appropriate prophylactic vaccination is good practice, but some live vaccines may exacerbate a problem if given to birds infected with an immunosuppressive virus. A vaccine administered in the water supply may be inactivated by chlorine. The vaccine used should always be licensed for the particular species concerned.

**Seasonal occurrence of disease**

Some diseases, particularly those transmitted by biting insects, only occur or are prevalent when the weather and/or the presence of nearby standing water is conducive to an increase in the insects (for instance the mosquito *Simulium* spp. etc.), e.g. disease Nos. 39, 47, 49, 52, 66, 67, 75 and 77.

**Specific diseases according to clinical signs**

To make differential diagnosis easier, these diseases are listed in Table 12.3 according to their commonly presented clinical signs. Zoonotic diseases and suggested diagnostic routines for each disease are also indicated.

**Egg drop syndrome**

The following causes can be responsible for a drop in egg production and production of malformed eggs:

- 1 Specific egg drop syndrome adenovirus – affects many species besides Galliformes; environmentally persistent in faeces
- 2 Infectious bronchitis virus – see disease Nos. 4 and 4a (Table 12.3)
- 3 Newcastle disease virus – see disease Nos. 4 and 4a
- 4 Influenza A virus – see disease No. 6
- 5 Fowl adenovirus Group I – see disease No. 7
- 6 Pullorum disease – see disease No. 20
- 7 Specific avian encephalomyelitis Picorna virus – see disease No. 48
- 8 Turkey meningio-encephalitis virus – see disease No. 49

- 9 Turkey rhinotracheitis pneumovirus – see disease No. 5
- 10 Diet – take into account the nutritional content of the diet
- 11 Husbandry – is the husbandry, housing, etc. satisfactory? Are stressors operative?
- 12 Egg stealing – always note the possibility of egg stealing, particularly in backyard flocks
- 13 Neoplasms and torsions – in single birds, note the possibility of neoplasms and torsion of the oviduct and other causes of egg binding.

**References**

- SIBLEY, C. G. and AHLQUIST, J. E. (1990). Galliformes. In: *Phylogeny and Classification of Birds*. Yale University Press.
- WOOLHAM, F. (1987). *A Handbook of Aviculture*. Blandford Press.

# Ramphastids

*Amy B. Worell*

## Introduction

Toucans are members of the family of birds Ramphastidae, which is part of the order Piciformes. These colourful and interesting birds are further subdivided into six different genera, encompassing approximately 35 separate species. An additional further division into three general categories, the larger toucans, the smaller toucanettes and the small and slender aracarís, is also useful for descriptive purposes.

Toucans as a group are considered tropical birds, with a range that starts in southern Mexico and extends to Bolivia and northern Argentina. Most species inhabit lowland rain forests, though some of the species can be found in mountainous regions.

The most prominent and distinguishing feature of the family Ramphastidae is the presence of the large protruding bill (Table 13.1). Bills vary in colour from black to bright or multicoloured, and are actually quite lightweight, being composed of a thick outer covering of keratin with an intricate inner network of trabeculae. The prominent

**Table 13.1** Anatomical variations found in ramphastids

Grossly visible anatomical characteristics:

- Lack of a discernible crop
- Presence of a gallbladder that is elongated in shape
- Frequent presence of pigmented gonads
- Keratinized bill with an inner intricate pattern of trabeculae
- Slender and elongated fibrous tongue

Radiographically visible anatomical characteristics:

- Ventral deviation of the trachea at the thoracic inlet (this characteristic is present in Piciformes)
- Reticulated pattern in the protruding bill

bill is thought to function in species recognition, in procuring food items that might otherwise be beyond their reach, and possibly in courtship rituals.

Toucans are not commonly kept as aviary or pet birds. While there are several large collections of ramphastids in the world, and a few birds are kept as pets, the relative numbers are quite small when compared to captive psittacines. When toucans are kept as pets, the birds that become the best companions are handled individuals. Though toucans are unable to talk, these energetic birds are able to vocalize, and produce a variety of interesting sounds. The most common species found in captivity are the Toco toucan (*Ramphastos toco*) and the sulphur-breasted or keel-billed toucan (*Ramphastos sulfuratus*) (Plate 29).

## Biology and husbandry

Ramphastids have been noted to be relatively gregarious birds, but unlike psittacines, which fly in compact formations, toucans tend to fly in a more staggered formation (Perrins and Middleton, 1985). Like many birds, ramphastids prefer high treetops for security. Toucans prefer to remain in a cluster of trees, hopping from branch to branch, instead of flying over long distances for food and shelter.

Ramphastids are cavity nesters, utilizing holes made by other birds or animals or naturally occurring decay holes. They may enlarge the nest spot with their beaks, but do not usually line their nests with gathered materials such as grasses and twigs. The incubation period for ramphastids is 16 days. The larger species often lay three and occasionally four white eggs, while the smaller

species average four eggs; clutches of three or five eggs may also be found. As with other altricial species, toucans are born featherless and sightless. Although altricial, ramphastids have developed an interesting anatomical adaptation for additional body support during this critical life phase, in the form of a temporary heel-pad on the caudal aspect of the hock. It is present at birth, and gradually regresses at 4 weeks of age. Depending on the species, toucans fledge at between 5 and 7 weeks of age.

## Housing


Toucans that are kept as companion animals thrive in large horizontally-oriented cages (Figure 13.1). As these colourful birds move about by hopping, it is preferable to have a large cage with several perches for them to hop back and forth both for exercise and to aid psychological well being. Toucans need food bowls that will allow them easy access with their large bill to the food items. As they drink by scooping up water with their bill, the water bowl must accommodate the large bill. There should be at least three bowls in the cage; one

for water, one for dry food, and one for daily fresh fruits.

Toucans that are housed as aviary birds, or those pets maintained in large cages, benefit from being kept in the largest cage that is practical within the confines of the compound. Aviaries 3–6 m in length, 2–4.5 m wide and 2–3 m in height are preferable for housing these active birds in captivity (Figure 13.2). Aviary birds are generally kept as pairs, but several combinations of birds are possible for a holding cage or in a mixed aviary. This practice is possible for all species of ramphastids presently in captivity except the emerald toucanette (*Aulcorhynchus prasinus*). These aggressive and territorial birds will often attack and kill other birds that are introduced into their environment.

Two females may be placed together but, as with males of many animal species, two mature toucan males may show aggression towards one another when housed in the same enclosure.

In each aviary there should be at least two perches positioned high in the cage and at opposite ends of the flight. The diameter of the perches should be based on the bird's foot



**Figure 13.1** Ramphastid caging consists of large horizontally-oriented cages.





**Figure 13.2** Perches for toucans.



**Figure 13.3** A palm tree nest box.

position while resting; the foot should not extend more than half way around the perch circumference (Figure 13.3). Ideally, perches should be of different diameters to aid in the prevention of plantar foot lesions.

Toucans in the wild nest in excavated tree holes, and in captivity most toucans prefer nest logs over traditional psittacine-type nest boxes. There are, however, well-documented cases in which toucans have successfully laid eggs and fledged young in the latter. Although any species of tree may be utilized for captive nesting sites, the most common is the palm tree (Figure 13.4). Palm tree sections can be hollowed out with a chain saw and an entrance hole placed near the top of the log. Nest logs should be securely anchored in the aviary and placed as high in the enclosure as possible.

The aracaris generally will sleep in their nest log, while the toucans prefer to sleep standing on a perch with their tail extended upwards. Aracaris kept as pets also seem to feel more secure hiding in a nest box at night.

Both cement floors and natural dirt floors have been used for toucan aviary flooring. Cement is easier to keep clean, but dirt is more aesthetically pleasing. Toucan aviaries can be extensively planted with foliage, as these birds do not destroy growing vegetation. The ramphastids appear to feel more secure in moderately planted aviaries than in those left barren and devoid of vegetation (Figure 13.5).

Plants in the flight should be non-toxic to the resident birds.

## Diet

Dietary recommendations for captive ramphastids focus on concern about a life-threatening condition called haemachromatosis, which affects many of the commonly kept ramphastid species in captivity. Haemachromatosis (or iron storage disease), which will be discussed in greater detail later in this chapter, results in an abnormal absorption and resulting deposition of iron in a variety of tissues in the body. Even though the aetiology of iron storage disease is not presently known in ramphastids, there are concerns about iron levels in the diets of captive toucans. As a general note, it should be pointed out that human medicine has concluded that dietary iron does not contribute to or augment the deposition of iron in the human body (Niederer *et al.*, 1987; Dambro, 1996). How this human finding relates to ramphastids is not known at this time.

Present dietary recommendations for captive toucans include one of the commercially available low iron softbill diets and a variety of fresh fruits (Figure 13.6). Depending on the geographical location, there may be access to less expensive and equally acceptable high-quality kibbled dog food as a basis for the diet



Figure 13.4 A planted toucan flight.



**Figure 13.5** A toucan diet contains a variety of fresh fruits sliced into correct sizes.



**Figure 13.6** Handfeeding a ramphastid species.

of captive toucans. Any ramphastid diet should ideally meet the recommendation for poultry with regard to dietary iron levels (40–60 ppm) (Kincaid and Stoskopf, 1987). Practically speaking, and considering the products currently available commercially, the author suggests using a product that contains less than 100 ppm of iron.

The selected dry component of the diet should be offered on an *ad lib* basis. A variety of fresh, diced fruits should be offered daily in a separate bowl. As ramphastids swallow their food items whole rather than separately, the fruit must be chopped into bite-sized

pieces. Fruits that have a high moisture content, such as grapes, berries, melons and papaya, are readily accepted by toucans. Other fruits such as apples, pears, bananas, and peaches are also acceptable. Fruits high in vitamin C, such as oranges, may actually enhance the absorption of iron, and should therefore be eliminated or offered only in very limited amounts (Worell, 1997).

Neonatal and young toucans that are hand-fed may be offered a variety of hand-feeding diets. As ramphastids do not have a discernible crop, food items should be offered in small quantities on a frequent basis. One option for feeding toucans utilizes commercially available psittacine hand-feeding formulas. This type of mixture can be fed alone, or with the addition of finely diced or pureed fruits. It can additionally be gavage-fed into the mid-oesophagus region, or can be offered orally. Another option for feeding infants and young is the use of small soaked kibble and finely diced fruit, offered at the onset of a feeding response. As stated earlier, because small ramphastids cannot store food, babies need to be fed frequently (i.e. once an hour). When the chick is full it will turn its head, or more commonly regurgitate the offered food items.

### Sex determination

It is important to determine the sex in birds that are intended for breeding purposes, and

surgical sexing is the commonly used definitive method for sex determination in monomorphic ramphastids. Currently, commercial laboratories are not able to use DNA chromosome techniques for sex determination in ramphastids; a surgical procedure is the only definitive method.

The surgical sexing procedure is similar to that in psittacines. Fasting for 4 hours is recommended prior to surgical procedures. Because of their enlarged bills, anaesthetic masks must be extended to accommodate the entire structure. Isoflurane is the anaesthetic agent of choice. Gonads in toucans may be dark green in colouration.

Several of the species are dimorphic, and thus can be sexed visually. Dimorphic species include most of the lowland toucanettes (genus *Selenidera*) and two of the aracaris, *Pteroglossus viridis* and *P. inscriptus*. In these species, sexual gender is easily determined by the coloration of the feathers on the head; males can be identified by black head feathering, and females by brown head feathering. There are two exceptions in the genus *Selenidera*, and of these only *S. culix*, or the Guianan toucanette, is presently kept in captivity. In these toucanettes the female displays a chestnut-coloured neck feathering and grey underparts, while the male of the same species has black feathering in the same areas (Worell, 1996).

Additionally, many ramphastids demonstrate visible bill length differences. Males often will have longer, narrower bills than females of the same species. The females' bills, generally, are shorter and broader. These differences can be quite clear or sometimes non-existent in many bird species. This method can be helpful in an initial visual inspection of ramphastids, in particular if a group of the same species is present.

## Breeding ramphastids

Breeding ramphastids can be compared to breeding psittacines, in that the smaller species of psittacines (e.g. budgies and cockatiels) generally breed more readily in captivity than do the larger species (certain species of cockatoos and many species of Amazons). This trend also generally holds true for toucans;

the smaller species (e.g. *Selenidera maculirostris*, or spot-billed toucanette) breed much more readily than the more commonly kept large Toco toucan (*Ramphastos toco*).

Ramphastid reproduction is most successful in long flight cages. Palm nest logs are recommended for a nesting site, with or without bedding material. The larger species of toucans become sexually mature around 2 years of age, and the smaller species at about 12 months. The captive life span for ramphastids is approximately 20 years, and productive breeding may occur well into later years with some of the larger toucan species. The reproductive activity of some of the smaller species rapidly decreases after 5–6 years of annual breeding.

The majority of ramphastids that have been captive bred have been parent reared rather than incubator hatched. Incubator-raised babies are possible, and some breeders routinely incubate a large number of their eggs. Neonatal ramphastids can be successfully raised from day one, and a variety of hand-feeding foods have been utilized.

The majority of ramphastid chicks are incubated by the parents, and either fledge with the parents or will be pulled for hand-feeding after several weeks of parental care. Some toucan pairs will not feed their offspring properly or even, quite commonly, will eat or mutilate their young. Trauma to the babies may occur shortly after birth or as late as 3–4 weeks of age. Stress to the parents or the lack of live food to feed the babies is often thought to be the reason for the abuse. Once young disappear from the nest or are found mutilated, the remaining offspring should be removed for their own safety. These offspring can either be placed with foster parents or hand-fed. Immediate removal of eggs for incubation is warranted in those pairs that ingest their eggs. For subsequent clutches produced by abusing toucan pairs, management changes should ideally be enforced that will lead to less stress for the parents while they are feeding young birds.

Frequently offering live food, such as crickets, mealworms or small mammals, is suggested for ramphastids when they are incubating eggs and rearing young. The live food is readily accepted by breeding pairs in most cases, and may lend to less aggression towards the babies and less egg ingestion.

## Handling and restraint

The handling of ramphastids is similar to that for other types of avian species, and includes using the bill as a handle for improving control over the bird. When toucans bite, they grasp and manipulate the object with their bill; if this object is a handler's arm or hand, it can be quite painful. Therefore, when removing an untamed bird from a carrier, the bird should be rapidly grasped by its protruding bill and removed from the carrier. The body is held in the same way as for other avian species.

Restraining toucans is easier when holding the bill than when holding the bird by the back of the head. The technique is, of course, a matter of personal preference, but bill holding is better in the larger species of toucans, where the bill is quite formidable. Smaller species, such as some of the toucanettes, are easily held with the hand placed on the back of the bird's head.

## Blood collection and injection sites

The technique for blood collection is similar to that utilized in other species. The patient should be held in a left lateral position by the technician, with one hand on the bird's mid-bill and the other on the body. Blood is easily collected from the right jugular vein by this method. The feather tracts of ramphastids differ from those in psittacines, and feathers simply need to be moved to one side to expose a substantial section of skin so that the jugular vein can be viewed. A 1 ml syringe with a 26- or 28-gauge needle may be used for the phlebotomy.

Other venepuncture sites used for blood collection include any externally accessible vein on the bird's body; however, haematoma formation is more likely at these sites. Blood samples may also be obtained by cutting the tip of the bird's toenail, but this method takes more time and causes more stress, both to the bird and blood collector, and is not recommended.

The most common areas used for injections are the pectoral muscles. These muscles are readily accessible, large, and are the recom-

mended site for intramuscular injections. Subcutaneous injections can also be given in a variety of locations, including the pectoral muscle area, the lateral flank and the interscapular area. The right jugular vein is recommended for intravenous injections, but the brachialis or ulnar veins are also acceptable.

## Basic surgery

The three most common forms of surgery performed on ramphastids are exploratory surgery, keyhole incisions for hepatic biopsy (endoscopic biopsy may be used), and laparoscopy for surgical sexing. Surgery generally involves exploration of the body cavity for abdominal distension, and the approach is through a medial abdominal incision. The bird's feathers may not need to be pulled if feather tracts are not in the area of the incision.

Hepatic biopsy may be performed via a keyhole incision. In this case the approach is through a small, horizontal incision approximately 1.25 cm just distal to the distal ventral aspect of the sternum and to the right of the midline. The distal tip of the right liver lobe is exteriorized or visualized, and a small wedge of tissue is removed. If there is a concern over bleeding, a commercially available product such as Gelfoam can be placed on the bleeding liver lobe.

For surgical sexing or laparoscopy, the approach can be behind the last rib, close to the proximal third of the femur on the left side of the body.

## Metabolic and nutritional disorders

Three conditions involving metabolic and/or nutritional disorders occur with varying frequencies in ramphastids; metabolic bone disease, diabetes mellitus and haemachromatosis.

### Metabolic bone disease

Metabolic bone disease (MBD) has been observed in a number of immature toucans. All reported cases of MBD have occurred in



(a)



(b)

**Figure 13.7** (a) and (b) Metabolic bone disease can cause soft folds or distal tip compressions in the bills of ramphastids.

keel-billed toucans (*Ramphastos sulfuratus*). The affected birds were obtained from multiple sources and had been on various diets. These birds presented with soft folds in their bills or lateral and/or distal tip compression of the bill (Figure 13.7). Many of the bill lesions were the direct result of trauma (such as flying into the aviary wall) but appeared to have an underlying component of metabolic bone disease, because the bills were abnormally soft for the age and stage of development of the bird. Lesions commonly found in avian species diagnosed with metabolic bone disease (deviations in the ridge of the keel, or bowing of the legs) have not been observed in cases affecting keel-billed toucans.

Dietary assessment and modification is necessary to prevent further skeletal changes. Dietary manipulation, such as addition of foods high in calcium or supplementation

with a vitamin–mineral powdered supplement, may be warranted. Covering aviary walls with varied opaque netting may aid in preventing trauma-related bill damage to birds being treated for MBD.

The majority of these affected birds' bills remodel to closely resemble a normal appearance following dietary and aviary modifications. Even with a substantial amount of damage to the distal bill (involving the mandible, maxilla, or both), these birds adjust to their condition and thrive. One bird's bill that suffered significant damage involving compression of the distal maxilla has remodelled itself over the years to become more normal in appearance.

## Diabetes mellitus

Diabetes mellitus is a relatively common condition that affects many different species of animals and birds. Among the ramphastids, only two species have been reported as being affected by diabetes mellitus (Worell, 1988); the Toco and keel-billed toucans. As relatively large numbers of these two species of toucans are presently in captivity, and relatively few individuals are affected, the overall incidence of diabetes in toucans appears to be quite low.

Birds affected with diabetes mellitus demonstrate the classical signs of the disease, including weight loss, polyuria, polydipsia, polyphagia and significantly elevated glucosuria and hyperglycaemia. The glucosuria will generally be 0.056 mmol/l on a urine test strip, and the blood glucose levels exceed 55.51 mmol/l. Blood glucose levels over 111.02 mmol/l have been documented (Murphy, 1992).

As is the case with other avian species, glucose metabolism with regard to hormonal regulation in the avian body is not yet completely understood. Glucagon, rather than insulin, may actually be the regulating hormone. Currently, affected birds (including toucans) are treated with Ultralente insulin injections for the regulation of diabetes. Initial treatment should be instituted utilizing less than one unit of Ultralente insulin once daily. Dosages ranging from 0.06–3.3 U/kg intramuscularly have been suggested (Oglesbee, 1997). The initial amount should be selected by the clinician, taking into account factors such

as blood glucose, body weight of the bird, physical condition of the bird, and the clinician's experience in treating diabetes in birds. Clinical hypoglycaemia is displayed as in mammals, and may produce signs of weakness, lethargy, ataxia and disorientation. If hypoglycaemia results, oral or injectable glucose products, or glucose-containing foods, can be given.

Toucans, as with other avian species affected by diabetes mellitus, may be difficult to monitor and regulate (Cornelissen and Ritchie, 1994). Insulin injections may optimally regulate blood glucose if given once daily, twice daily, or on a schedule such as every other day. One study suggests that dietary changes may be advantageous in the regulation of diabetes in toucans (Murphy, 1992).

Many diabetic toucans eventually succumb to the disease. Post-mortem examinations, when permitted, have demonstrated changes including pancreatic islet cell hyperplasia (Worell, 1988; Murphy, 1992), and deposition of iron in the pancreas (Worell, 1988).

## Haemachromatosis

Haemachromatosis, or iron storage disease (ISD), is the most common life-threatening disease to affect captive ramphastids (Table 13.2). Haemachromatosis results when an excessive amount of iron accumulates in various body tissues. In affected individuals, an iron-containing pigment may be identified microscopically in diseased tissues. When excessive iron is deposited in the body's parenchymal cells and cellular damage

occurs, this is considered to be haemachromatosis. Haemosiderosis is defined as the excessive deposition of iron in the body's parenchymal cells that does *not* result in cellular damage (Lowenstine and Petrak, 1979). In those cases where iron deposition results in cellular damage, organ dysfunction, disease and death may occur.

Haemachromatosis occurs in several different species of mammals and birds, including mynahs, birds of paradise, quetzals, cranes, starlings, hornbills and tanagers (Worell, 1988). Iron storage disease may present differently in the various avian species affected, but the disease process results in death. Although various avian species show different clinical presentations, the disease process is a progressive debilitating condition toward death.

In man, there are two different forms of the disease. In the secondary form, excessive iron deposition is related to chronic anaemia, a variety of haemolytic disorders, and exogenous iron administration. In the primary or idiopathic form, the disease is due to a recessively transmitted autosomal disorder, which involves a defect in the mucosal cells of the intestinal tract. The defective gene is found on the short arm of chromosome six. Even though the exact nature of the defect is not presently known, it is thought that the normal controls affecting iron metabolism are lost in these individuals, and hence excessive iron is absorbed. Idiopathic haemachromatosis in man is not thought to be related to the amount of iron in the diet (Worell, 1988). There has not been any correlation between avian haemachromatosis and the human forms of the disease.

Current research and present knowledge of this disease in toucans has not identified a specific aetiology for this condition. Since there is a lack of uniformity of clinical signs, there is speculation that differing aetiologies may be present in avian species affected with haemachromatosis. It is not known whether the amount of iron in the ramphastid diet is significant in controlling or preventing ISD, and it is also currently unknown which factors, if any, have a bearing on the clinical development, progression and manifestation of this disease in toucans. Susceptible species of ramphastids should be fed diets that are compatible with poultry recommendations for dietary iron levels (40–60 ppm). To date,

**Table 13.2:** Species of ramphastids affected with haemachromatosis

---

Channel-billed toucan ( <i>Ramphastos vitellinus</i> )
Toco toucan ( <i>Ramphastos toco</i> )
Keel-billed toucan ( <i>Ramphastos sulfuratus</i> )
Red-billed toucan ( <i>Ramphastos tucanus</i> )
Ariel toucan ( <i>Ramphastos vitellinus ariel</i> )
Choco toucan ( <i>Ramphastos brevis</i> )
Plate-billed mountain toucan ( <i>Andigna laminirostris</i> )
Pale mandible toucanette ( <i>Pteroglossus erythropygius</i> )
Chestnut-eared aracari ( <i>Pteroglossus castanotis</i> )
Black-necked aracari ( <i>Pteroglossus aracari</i> )
Spot-billed toucanette ( <i>Selenidera maculirostris</i> )
Saffron toucanette ( <i>Bailloni baillioni</i> )
Emerald toucanette ( <i>Aulacorhynchus prasinus</i> )

---

thirteen species of ramphastids have been identified as being susceptible to haemachromatosis. The most common ramphastid species affected by haemachromatosis are also the most commonly kept species in captivity, the Toco, keel-billed and red-billed toucans.

Clinical signs in affected toucans are often not apparent to the carer. Even though the clinical signs may be subtle and difficult to identify, depression and minor disease signs are likely present in affected birds prior to death. Often, affected birds are found dead without apparent clinical abnormalities. The lack of overt disease signs may be due to the strong instinctual preservation nature of birds.

Iron storage disease is most accurately diagnosed through histopathological examination of liver tissue obtained by biopsy techniques. Previous serology by the author explored serum iron determinations to render an ante-mortem diagnosis of haemachromatosis. However, further work demonstrated that hepatic biopsy is, at this time, the gold standard for diagnosis of the disease in affected birds (Worell, 1991a, 1993). Liver samples can be obtained either by endoscopy or through a small ventral abdominal incision. The obtained sample can be analysed for characteristic histopathological changes as well as exact iron levels.

Once a bird has been diagnosed with ISD, the outlook is guarded and the bird will eventually die of the disease although the disease process may take several years. The recommended treatment for birds diagnosed with haemachromatosis is similar to that for humans; i.e. the once- or twice-weekly removal of blood (phlebotomies) in an attempt to lower the iron level in the body. In man it may take 2–3 years to achieve the endpoint where excess iron is removed, resulting in a mild anaemia. The lifetime maintenance therapy involves intermittent phlebotomies at a rate of four to six a year. This method leads to normalization of the serum iron levels (Dambro, 1996). Further information may be obtained by visiting the Iron Overload Diseases Association, Inc. at their World Wide Web page ([http://www.emi.net/~iron\\_od/](http://www.emi.net/~iron_od/)).

In affected toucans, birds undergo weekly phlebotomies for more than a year. Birds are seen on a weekly basis, and 10 per cent of the

bird's blood volume is removed each time. Bird blood volume is calculated by taking 10 per cent of the bird's body weight in grams. For example, if a bird's weight is 450 g, the total blood volume will be 45 ml<sup>3</sup>. The calculated safe volume of blood that can be removed, calculated at 10 per cent of the blood volume, is therefore 4.5 mls. To put it another way, it is safe to remove an amount of blood equal to 1 per cent of the toucan's body weight on a weekly basis (Worell, 1991b). Weekly haematocrits are submitted, even though no appreciable drop in this value has been documented. In man, if the haematocrit drops below 36 per cent (normal range 37–47 per cent in women), or if the haemoglobin is less than 10, then the phlebotomy is not performed. Suggested criteria for toucans would be to perform the phlebotomy if the bird's oral mucous membrane is pink and if the haematocrit is greater than 30 per cent.

The ideal diagnostic path for ISD would be to perform a hepatic biopsy for both histopathological examination and quantitative determination of hepatic iron levels. If the hepatic tissue demonstrated haemachromatosis, then weekly liver tissue submissions should be considered and instituted. Serial hepatic tissue samples should be considered at intervals of 6–12 months. Assuming a response is seen in the hepatic tissue, then a maintenance protocol for phlebotomies could be instituted on a once-monthly basis. This protocol is recommended to clients with birds in which ISD has been confirmed.

Additionally, as a screening test, whole body radiographs are useful in suggesting the presence of ISD in those avian species known to be affected with the disease. Both lateral and ventro-dorsal views can be taken, but the most useful is the ventro-dorsal view. The attending clinician must be able to distinguish a normal liver from hepatomegaly in radiographs. As this non-invasive radiographic technique is not diagnostic for haemachromatosis in ramphastids, a differential diagnosis for liver enlargement should always be considered. The most likely diagnosis with significant radiographic hepatic enlargement in a toucan is haemachromatosis, and the main differential for this diagnosis is avian tuberculosis.

In man, if patients are too severely anaemic for phlebotomies, treatment is attempted with



the iron chelating drug deferoxamine mesylate (Desferal). While phlebotomies are the treatment of choice, Desferal is an alternative. There have been several non-documented cases of the use of deferoxamine in toucans, and one documented study (Cornelissen *et al.*, 1995). In this study, a 4-month protocol of daily subcutaneous injections with deferoxamine (100 mg/kg) was given to a channel-billed toucan. Monthly biopsies were performed and, at the completion of the 4-month study, the bird was considered free of iron storage disease.

The author is presently using deferoxamine in several ramphastids that have been diagnosed with severe haemachromatosis by hepatic biopsy. The injections are given once daily into the pectoral muscle mass. Initially dosages of 100 mg/kg were administered, with the current dose being closer to 200 mg/kg. To date, subsequent tissue samples have not demonstrated a decrease in iron deposition in the liver. Visually, on subsequent hepatic samples, the livers have appeared more abnormal than on previous submissions. These visual changes include continuing hepatomegaly and grossly visible tissue bronzing. However, the owner of the birds perceives that the birds are clinically more alert and active. Studies with deferoxamine are continuing in order to determine its clinical effectiveness.

In individual toucans that succumb to haemachromatosis, post-mortem examinations will often demonstrate a bird in good body condition. Gross internal changes that are noted include a markedly enlarged liver that is orange to bronze in colour. Both visibly and histologically, the liver is usually the only organ or tissue that is affected. This is in marked contrast to the clinical effects of iron deposition seen in man, where iron deposition commonly occurs in multiple body organs and tissues, resulting in serious complications (Worell, 1988; Dambro, 1996). Occasionally, on histopathological examination of body tissues of deceased birds, iron deposition may be noted in the spleen, kidneys, pancreas and small intestines, although this is an extremely uncommon finding. Additionally, ascites, which is commonly seen in mynah birds with haemachromatosis, has not been documented by the author in affected toucans.

Microscopic changes in the livers of affected birds, demonstrated with the use of special

stains such as Prussian Blue, usually include varying degrees of iron deposition in both hepatocytes and Kupffer cells. Often, minimal non-affected and potentially functioning hepatic tissue is noted during the histopathological examination.

## Infectious diseases

As a whole, ramphastids are quite hardy birds. Their most common medical problem is iron storage disease in those species affected by this condition. Ramphastids are occasionally affected by a small variety of other conditions (Table 13.3). Upper respiratory infections occasionally occur, as do generalized unspecified infections that respond to broad-spectrum antibiotics.

## Viral diseases

To date, viral diseases in ramphastids have almost been non-existent. In the later part of 1996, lesions resembling proventricular dilatation disease of psittacines were identified in two toucans (D. Reavill, personal communication). Additionally, lesions resembling psittacine polyomavirus have been identified in an aracari (A. Fudge, personal communication). Whether viral diseases affecting psittacines or other avian species will potentially mutate or modify and spread into the Piciformes is as yet unknown, but this may occur.

In late 1987, a female toucan of unknown species was diagnosed with a herpesvirus infection that involved a severe necrotizing hepatitis. Intranuclear inclusions were isolated in both the liver and spleen. The affected bird had been in contact with two red-fronted macaws (*Ara rubrogenys*) that had died within the preceding week and had also been diagnosed with severe herpesvirus hepatitis (Charlton *et al.*, 1990).

## Chlamydial infections

Presently, there are no documented cases of ramphastid chlamydial infections.

## Fungal and yeast infections

Occasional *Aspergillus* spp. infections have been noted in ramphastids, but the overall occurrence appears to be very low. *Candida albicans* may frequently be found in ramphastids, and is diagnosed using techniques such as gastrointestinal tract cytology or microbiology. The presence of this organism may be considered as normal flora or a pathogen, depending on the individual presentation. If the bird is clinically healthy and the organism has been identified from the gastrointestinal tract of an individual, the organism should be considered a normal inhabitant. If the bird is a neonate being hand-fed, or is a poor doer and losing weight, the organism should be considered as a potential pathogen.

## Parasitic infections

The present day incidence of internal parasites in captive toucans is quite low. In years past, when larger numbers of ramphastids were imported from their countries of origin, infections with lice, ascarids, *Capillaria* spp., giardiasis and coccidiosis were common. Since importation has decreased, there are very few case presentations of long-term captives or domestically reared toucans with external and/or internal parasites. Imported toucans should still be closely screened for both internal and external parasites.

## Bacterial infections

Although the overall incidence is low, bacterial infections are the most common organisms affecting ramphastids. Most bacterial infections in toucans are isolated in the upper respiratory or gastrointestinal systems. As with other avian species, most potentially pathogenic bacteria are Gram-negative organisms. An investigative study in which five species of clinically normal toucans were examined for the presence of cloacal microflora demonstrated the presence of large numbers of *Staphylococcus* spp., *Streptococcus* spp. and *Escherichia coli* (Cornelissen *et al.*, 1991). The results of the cloacal study parallel the isolates from the numerous cloacal cul-

tures that have been performed by the author. Additionally, *Lactobacillus* spp. are commonly isolated from clinically healthy birds and should be considered normal flora in these cases. *E. coli* should be considered a potential pathogen, especially when isolated from a clinically ill patient. Since the serotypes of *E. coli* have not been explored in clinically healthy and clinically ill birds, it is unknown which serotypes are pathogenic, potentially pathogenic, or commensals. The entire clinical picture of the individual patient should be considered when deciding pathogenicity of a bacterial isolate.

Choanal and oesophageal cultures taken from ramphastids frequently demonstrate the presence of varying numbers of bacteria that may be considered either normal inhabitants or potential pathogens in these birds. Once again, the entire clinical picture should be assessed to determine the significance of the isolates.

Ramphastids are considered to be very susceptible to *Yersinia pseudotuberculosis*, a Gram-negative bacteria. *Y. pseudotuberculosis* infections commonly result in acute or peracute deaths in affected birds. Chronic infections with the bacteria also occur, but appear to be less frequent in ramphastid species. Postmortem findings typically demonstrate hepatomegaly, splenomegaly and, sometimes, the presence of granulomatous lesions in various body organs. The enlarged liver and spleen usually demonstrate the presence of small white or yellow foci (Dhillon and Shafer, 1987).

Transmission is thought to occur from ingestion of rats and mice or their droppings. Rodent control in an aviary experiencing infection due to *Y. pseudotuberculosis* is of paramount importance to stop the spread of the disease.

*Mycobacterium* spp. infections in ramphastids are occasionally encountered. Birds infected with tuberculosis present with depression, emaciation and hepatomegaly. Hepatic biopsy will usually confirm the diagnosis *Mycobacterium* spp. infection, because the commonly used faecal acid fast test is not sensitive. Affected birds from both pet and aviary situations seem to be isolated cases. This has been documented on subsequent postmortems or hepatic biopsies of in-contact toucans and psittacines. Affected birds may demonstrate

**Table 13.3** Diagnosis of medical problems in ramphastids with regard to clinical signs

<i>Problem</i>	<i>Occurrence</i>	<i>Clinical signs</i>	<i>Aetiology</i>	<i>Differential diagnosis</i>	<i>Confirmative diagnostic tests</i>	<i>Treatment</i>
Respiratory problems	Upper respiratory infections occur with a small frequency in ramphastids. Many of these are quite chronic in nature, and may never completely resolve	Congestion, wheezing, and intermittent insufflation of the cervical air sacs are most commonly seen. Occasionally sneezing and a clear nasal discharge may be evident	A definitive diagnosis is not reached in most upper respiratory infections. Unretrievable bacterial and/or viral organisms may possibly be involved	Lower respiratory infections	None. Radiographs, Gram stains and choanal cultures may be helpful	Affected birds may be treated with broad-spectrum antibiotics and nasal flushes. Nebulization therapy is often useful. Treatment may be lengthy
Diarrhoea	Uncommon, or difficult to distinguish from normal loose droppings	Loose faecal component of the droppings. It should be noted that ramphastids will often pass chunks of undigested food in their droppings	Most commonly due to bacterial or parasitic infections	Polyuria; could be normal for the bird's diet or due to recently ingested food	Faecal parasite examinations. Gram stains or cloacal cultures	Broad-spectrum antibiotics or anthelmintics
Anorexia	Not common	Not eating	No specific condition	All conditions affecting toucans	Should do thorough work-up, including CBC, serum chemistries, BA, cultures or Gram stains, faecal parasite examination, EPH and radiographs	Broad-spectrum antibiotics, two to three times daily gavage feeding with a commercially available psittacine hand-feeding formula
Nervous signs	Not documented in ramphastids					
Polyuria/polydipsia	Very few birds are affected	Drinking large amounts of water with subsequent polyuria	Most commonly due to diabetes mellitus in those affected species (Tocos and keel-billed)	Any condition, similar to mammals, that could cause PU/PD, such as renal or hepatic involvement in particular. Does not occur with haemachromatosis	CBC, serum chemistries and urinalysis	Insulin injections. At this time, Ultralente is the recommended insulin

Breeding problems	Very varied. Probably depends on keeper's management style and familiarity with birds. A percentage of toucans molest and cannibalize their young. Frequency rates have not been documented. Difficulty may be encountered with getting the larger species of ramphastids to breed in captivity (similar to breeding some of the wild-caught psittacines in captivity)	Depending on the specific problem. May be disappearance of young, or finding partially ingested young. May have no breeding in larger ramphastids	Probably related to over managing and not enough security for a pair of birds. May also be related to not enough live food. Could be related to incompatible pairs of birds	Should run diagnostic tests on non-producing pairs or modify aviary situations		
Foreign body ingestion	Potentially could occur in any ramphastid, but only documented by the author in aviary birds. Incidence is related to environment and management	Vague. May not see signs of a sick bird	Ingestion of foreign body – most commonly metal objects such as wire or nails in the author's experience	Would depend on if clinical signs were observed	May be visualized on radiographs depending on the density of the object. Many of these are found on post-mortem examination	If the foreign body is discovered prior to death and the object can not pass, surgery may be the treatment of choice unless the object is removable via endoscopy through entrance into the oesophagus
Damage to the bill	Incidence is low. Most commonly occurs in young, growing birds	Deformed beak due to stage of development of the beak, age of the bird and increased malleability of the bill. May also see that a distal section of either the maxilla or mandible is missing. Occasionally seen as defect on lateral surface of either bill	Trauma to the bill. Often precipitated by underlying metabolic bone disease	None	None. Could perform a CBC plus serum chemistries to rule out underlying disease	Generally not necessary. Some of the defects can be repaired, but repair may be unsuccessful in the long run

Table 13.3 *Continued*

<i>Problem</i>	<i>Occurrence</i>	<i>Clinical signs</i>	<i>Aetiology</i>	<i>Differential diagnosis</i>	<i>Confirmative diagnostic tests</i>	<i>Treatment</i>
Haemachromatosis	Very high in those species known to be affected with the condition	Ranges from none to general signs of a sick bird, or finding a dead bird	Due to excessive absorption and deposition of iron in the liver. Specific cause of this condition is unknown	Avian tuberculosis, hepatic disease due to other causes, other systemic disease	Hepatic biopsy	Weekly phlebotomies for several years, monitored by intermittent hepatic biopsies, gradually adjusting to a more intermittent schedule of phlebotomies for the remainder of the bird's life
Ankylosis of the tarso-metatarsal joint	Most commonly occurs in birds that have been imported or shipped	Swelling and decreased range of motion of this joint	Trauma to this joint in transit. May potentially involve bacterial invaders if the skin is punctured	Fractures in the distal tibiotarsus or proximal metatarsus	Radiographs. May consider joint cytology, culture if indicated	Return to normal function is generally unrewarding. Success may be related length of time between injury and presentation. Antimicrobial therapy can be utilized if indicated. Otherwise, some relief may be obtained by topical use of DMSO and anti-inflammatory products

the presence of these acid-fast organisms in addition to iron storage disease.

## Zoonotic diseases

Currently occurring potentially zoonotic diseases affecting toucans include infection due to *Mycobacterium* spp. and *Giardia* spp.

### *Mycobacterium* spp.

Affected birds are commonly diagnosed on post-mortem examination and using acid-fast stains on tissue samples. Clinically ill birds may present with weight loss and lethargy. Total body radiographs demonstrate a markedly enlarged liver, and a faecal acid test is usually unreliable. Confirmation of a diagnosis may be provided using hepatic biopsy. Treatment protocols can follow those utilized for psittacines if treatment is desired for this potentially zoonotic disease. Exposed birds of many species potentially can be observed, undergo multiple faecal acid-fast screens, have liver and/or intestinal biopsies performed, or be euthanized. This decision, as with the choice of therapy, is dependent on the clinician's philosophy and belief concerning this disease.

### *Giardia* spp.

Ramphastids affected with giardiasis may present with no apparent clinical signs of disease or diarrhoea. Diarrhoea is often difficult to accurately assess in a toucan, as the droppings may normally be consistently or intermittently loose. Accurate diagnosis can be made through direct faecal smears, with or without the use of special stains. Treatment for *Giardia* spp. is as with other avian species. Prevention may involve management evaluation of the environment and checking the water source for the organism.

## References

- CHARLTON, B. R., BARR, B. C., CASTRO, A. E. *et al.* (1990). Herpes viral hepatitis in a toucan. *Avian Dis.* **34**(3), 787–90.

- CORNELISSEN, H. and RITCHIE, B. W. (1994). Rhamphastidae. In: *Avian Medicine: Principles and Application* (B. W. Ritchie, G. J. Harrison and L. R. Harrison, eds), pp. 1276–83. Wingers.
- CORNELISSEN, H., DUCATELLE, R. and ROELS, S. (1995). Successful treatment of a channel-billed toucan (*Ramphastos vitellinus*) with iron storage disease by chelation therapy; sequential monitoring of the iron content of the liver during the treatment period by quantitative chemical and image analyses. *J. Avian Med. Surg.* **9**(2), 131–7.
- DAMBRO, M. R. (ed). (1996). *Griffith's Five Minute Clinical Consult*. Williams & Wilkins.
- DHILLON, A. S. and SHAFER, D. (1987). Yersinia pseudotuberculosis infection in two Toco toucans and a turaco. In: *Proc 1st Int. Conf. Zoo Avian Med.*, pp. 37–8. American Association of Zoological Veterinarians.
- GRIMES, L. G. (1985). Toucans, honeyguides and boubets. In: *The Encyclopaedia of Birds* (E. M. Perrins and A. L. A. Middleton, eds.), pp. 286–90. Facts on File Inc.
- KINCAID, A. and STOSKOPF, M. (1997). Passerine dietary iron overload syndrome. *Zoo Biol.* **6**, 79–88.
- LOWENSTINE, L. and PETRAK, M. L. (1979). Iron pigments in the livers of birds. In: *Comparative pathology of Zoo Animals* (R. J. Montali and G. Myaki, eds.), pp. 127–35. Smithsonian.
- MURPHY, J. (1992). Diabetes in toucans. In: *Ann. Proc. AAV, New Orleans*, pp. 253–62. Association of Avian Veterinarians.
- NIERDERAU, C., STREMMEL, W. and STROHMEYER, G. (1987). Hemachromatosis. *Ergrbnidder Inneren Medizin und Kinderheilkunde*, pp. 117–48.
- OGLESBEE, B. (1997). Diseases of the endocrine system. In: *Avian Medicine and Surgery* (Altman, R. B., Clubb, S. L., Dorrestein, G. M. and Quesenberry, K. E., eds). W. B. Saunders.
- SMITH, S. A. and SMITH, B. J. (1992). *Atlas of Avian Radiographic Anatomy*, pp. 77–81. W. B. Saunders.
- WORELL, A. B. (1988). Management and medicine of toucans. In: *Ann. Proc. AAV, Houston*, pp. 253–62. Association of Avian Veterinarians.
- WORELL, A. B. (1991a). Serum iron levels in ramphastids. In: *Ann. Proc. AAV, Chicago*, pp. 120–30. Association of Avian Veterinarians.
- WORELL, A. B. (1991b). Phlebotomy for treatment of hemachromatosis in two sulfur-breasted toucans. In: *Ann. Proc. AAV, Chicago*, pp. 9–14. Association of Avian Veterinarians.
- WORELL, A. B. (1993). Further investigations in ramphastids concerning hemachromatosis. In: *Ann. Proc. AAV, Nashville*, pp. 98–107. Association of Avian Veterinarians.
- WORELL, A. B. (1996). Medicine and surgery of toucans. In: *Disease of Cage and Aviary Birds*, 3rd edn. (W. J. Rosskopf and R. W. Woerpel, eds), pp. 933–43. Williams and Wilkins.
- WORELL, A. B. (1997). *Avian Medicine and Surgery* (Altman, R. B., Clubb, S. L., Dorrestein, G. M. and Quesenberry, K. E., eds), pp. 910–17. W. B. Saunders.

# 14

## Pigeons

*Peter De Herdt and Luc Devriese*

### Introduction

Among the many representatives of the Columbiformes, the rock dove *Columba livia* is the most universally kept by humans on all continents. A large variety of breeds have been developed, the most famous of which, the homing pigeon, is used in races. This chapter is intended mainly for use with racing pigeons, but most of the data presented are easily applicable to other breeds.

The objective of homing pigeon fanciers is to achieve good results with their birds in competition races. What counts is the overall performance of the group rather than that of the individual pigeon, and consequently, pigeon fanciers are especially concerned about the overall health of their pigeon flock and less so about individual pigeons. For this reason, pigeon medicine focuses on infectious diseases. It is impossible to discuss all infectious pigeon diseases in this chapter, so the most important ones have been selected. The section devoted to non-infectious pigeon diseases includes only those conditions specific to pigeons, as most non-infectious diseases of pigeons are similar to those seen in other birds and referral can therefore be made to the relevant chapters dealing with these problems.

This chapter approaches the different pigeon diseases in a practical manner; nevertheless, data that may help with comprehension are included.

### Handling pigeons

Pigeons are easy to handle with practice. There is one golden rule: the bird should always be held in the hand with its chest

facing the handler (Figure 14.1), otherwise it will invariably try to escape if the hand grip is loosened even slightly. The sternum of the pigeon rests in the palm of the hand and the thumb is placed over the tail base and the wing tips. The legs are held with the free hand between the index and the middle finger of the hand that is holding the bird.

### Anatomy

As in other birds, but not mammals, the oesophagus is situated at the right side of the trachea. The narrow part is short and widens into the crop, which has a special function in pigeons. The so-called crop milk consists of rapidly desquamating crop cells (Plate 30). During the time that squabs are fed with this substance, the crop surface appears as if covered with cooked rice and the mucosa is heavily congested. This should not be mistaken for a pathological condition such as crop candidiasis.



**Figure 14.1** The proper restraint technique for a pigeon.

The gizzard contains many stony particles. When palpating the abdomen, it should not be confused with an egg.

Although pigeons do not have a gall-bladder, bile is abundantly produced. When pigeons do not eat the production of faeces diminishes but bile continues to be produced, resulting in green droppings. This is not a pathological condition in itself, but it may indirectly indicate clinical disease-related inappetence. Normal intestinal peristalsis also flushes bile into the stomach, resulting in a strong green aspect of the horny layer of the gizzard.

When examining pigeon droppings, it should be remembered that urine is excreted together with faeces. Urine is usually solid, but in the course of some diseases affecting the kidneys it may become very fluid. This is often interpreted by pigeon fanciers as diarrhoea, but is in fact polyuria. Inappetent diseased pigeons defecate almost exclusively fluid urine, with one or two small flakes of greenish faecal matter. This may also be erroneously interpreted as a sign of enteritis. Non-infectious factors such as nervousness or vitamin D<sub>3</sub> overdose may also lead to polyuria.

## Infectious diseases

### Paramyxovirosis

#### *Aetiology*

Paramyxovirosis in pigeons is caused by a serotype 1 paramyxovirus that is closely related to, but not identical with, the paramyxoviruses causing Newcastle disease in poultry (Alexander *et al.*, 1985). The virus can easily be cultivated in the allantoic sac of embryonated chicken eggs.

#### *Epidemiology*

Paramyxovirus infections in pigeons typically occur in the late summer and autumn, predominantly from August to November. During this period, the disease counts for approximately 20 per cent of the diagnoses in pigeons made at the University of Gent. The prevalence of clinical paramyxovirosis is, however, easily influenced by vaccination.

### *Pathogenesis*

The pathogenesis of paramyxovirosis in pigeons has not been thoroughly studied. Pigeons are probably infected aerogenically or orally, as in poultry (Alexander, 1991). In pigeons, the viruses typically spread to the kidneys and/or the central nervous system. Following viral replication in the kidneys an interstitial nephritis arises, resulting in a diminished blood flow through the mammalian-type nephrons and an augmented blood flow through the reptilian-type nephrons. The reptilian-type nephrons of birds are unable to absorb water efficiently because they lack the loops of Henle. Because of this, multiplication of paramyxovirus in the pigeon kidneys results in polyuria and subsequent polydipsia. Replication of paramyxovirus in the central nervous system often leads to demyelination and perivascularitis. These lesions can be associated with central nervous disorders. The incubation period of the pigeon paramyxovirus infection is between 5 and 35 days (Viaene *et al.*, 1983).

### *Clinical signs and lesions*

At autopsy, no macroscopic lesions can be seen. Histologically, an interstitial nephritis is evident, which in the subacute phase evolves to cause destruction of tubular epithelium and diffuse infiltration of lymphocytes. Due to these lesions, polyuria and polydipsia will develop. These clinical signs spread to the entire population within a few days. Polyuria and polydipsia can last for 6–8 weeks. Pigeons that are not cured within that period often suffer from irreversible lesions and show polyuria for the rest of their life. Notwithstanding the extreme polyuria, the general condition of the pigeons remains well, and they show no or only slight weight loss. Indeed, the intestinal tract keeps its normal absorption capacity because of the absence of lesions. Furthermore, the uric acid concentration in the blood is normal since the glomeruli and the proximal tubules are intact.

Between 1983 and 1986, at the beginning of the pandemic spread of this disease, central nervous disorders were the main clinical expression of paramyxovirosis (Viaene *et al.*,



1983). Nowadays, however, nervous signs are observed only sporadically. These signs consist of torticollis, inco-ordination of head movements, trembling wings and complete or partial paralysis (Plate 31). After 1 week there may be already spontaneous clinical improvement of the birds, and approximately 70 per cent of pigeons recover completely. Lesions in affected animals consist of a suppurative encephalitis with perivascularitis and demyelination.

When paramyxovirosis occurs during moult, the growth of replacement feathers may be interrupted and, when growth is initiated again, an indentation in the vane may remain. The younger part of the feather will grow to its normal size while the older part often breaks off.

Morbidity in paramyxovirosis is usually 100 per cent. Mortality, on the other hand, is always very low, usually less than 5 per cent. This 5 per cent comprises pigeons that became unable to eat or drink due to nervous disorders, as well as nestlings that died suddenly. Indeed, nestlings infected with paramyxovirus usually do not develop clinical signs but just die very suddenly.

Except for birds with irreversible brain lesions, most pigeons resume their previous racing performances after an outbreak of paramyxovirosis. Chronic polyuria does not influence racing results except during hot weather, when it results in rapid dehydration of affected pigeons. Pigeons with chronic lesions can be used for breeding without adverse effects.

Finally, it must be noted that pigeons suffering from paramyxovirosis do not develop diarrhoea or respiratory distress. This is clearly different to paramyxovirosis (NCD) in poultry.

### **Diagnosis**

The diagnosis of paramyxovirosis is usually made on the basis of typical clinical signs of polyuria and polydipsia in the absence of weight loss. Occasional nervous signs and a low mortality rate are useful additional indications, and only in the rare cases of vitamin D<sub>3</sub> intoxication are identical clinical signs observed. It is important to distinguish between polyuria and diarrhoea, and lay people often fail to make this distinction.

When a suspected diagnosis needs confirmation, haemagglutination inhibition (HI) of paramyxovirus with pigeon sera can be used (Viaene *et al.*, 1983). For a reliable serological diagnosis, paired sera of multiple pigeons should be tested. However, veterinary practitioners usually try to interpret serological results on the basis of single samplings. The test can be performed using homologous pigeon paramyxovirus and/or heterologous chicken La Sota paramyxovirus as an antigen. The comparison with both types of antigen can be very useful for the interpretation of HI titres. During an outbreak of paramyxovirosis, HI titres against the homologous antigen will be higher than titres against the heterologous antigen, at least in the early stages of the infection. This can lead to an early diagnosis. Most laboratories only use the chicken La Sota strain as an antigen. When four haemagglutinating units of La Sota virus are used in the test, the authors' interpretation of geometric mean HI titres is as follows (Viaene *et al.*, 1983):

<i>Mean HI titre</i>	<i>Interpretation</i>
< 2	Pigeons have not been in contact with paramyxovirus, either by infection or vaccination
2-4 in pigeons that have not been vaccinated	Paramyxovirus infection
2-4 in pigeons that have been vaccinated	Usually vaccination titres. Test these pigeons again after 1-3 weeks
> 4 in pigeons without clinical signs	Pigeons have been infected with paramyxovirus but have not developed clinical signs due to vaccinal immunity
> 4 in pigeons with clinical signs resembling paramyxovirosis	Paramyxovirus infection in pigeons that were not vaccinated, in pigeons that were vaccinated with live La Sota vaccine, or in pigeons incorrectly vaccinated with inactivated vaccine

Histologic lesions in the kidneys and the brains can also be indicative for paramyxovirus. However, the kidney lesions are not pathognomonic and non-suppurative encephalitis is not always present.

Pigeon paramyxovirus furthermore can easily be isolated in embryonated chicken eggs or in cell culture.

### **Control**

Pigeons suffering from paramyxovirus can be supplemented with vitamins and essential amino acids or fed with a low protein diet in order to relieve the function of the kidneys. However, a real aetiological therapy is not available.

Preventive vaccination against paramyxovirus is advisable. Both inactivated and live vaccines are available and even legally obliged in numerous countries. Best results are obtained with inactivated adjuvated vaccines, containing either a pigeon paramyxovirus strain or a poultry La Sota strain (Viaene *et al.*, 1983; Duchatel and Vindevogel, 1986). Pigeons can be subcutaneously injected with these vaccines from the age of 5 weeks. If possible, they should be vaccinated during the late winter or early spring. Protective immunity will be built up within 3 weeks and last for 1 year. After a year, pigeons should be revaccinated. In the past (when inactivated vaccines were not yet available), live La Sota vaccine of poultry was advised for the vaccination of pigeons (Viaene *et al.*, 1983). Recently, however, this practice has been discouraged, since only weak immunity is obtained and vaccine breaks occur very frequently unless the pigeons are vaccinated repeatedly at 4-week intervals. La Sota vaccine can be administered via eye and nose drops or drinking water. For the eye and nose drop method, 1000 La Sota vaccine doses should be suspended in 50 ml water and one drop of the resulting suspension administered into each nostril and each eye. For the drinking water method, 1000 La Sota vaccine doses should be suspended in 1–10 l of a 9 : 1 ratio of distilled water and skimmed milk. Vaccine-supplemented water should be consumed completely within 2 hours; therefore, drinking water should be withheld for 12 hours before administration of the vaccine.

## **Adenovirus infections**

Adenoviruses are responsible for two clinical disease entities in pigeons; adenovirus type I and adenovirus type II (De Herdt *et al.*, 1995a). The postscripts I and II refer to the clinical signs and lesions caused by these adenoviruses, and not to the antigenic nature of the agents. Both types of adenovirus infections have a large impact on pigeon populations. The aetiological agents of adenovirus type I and II in pigeons are adenoviruses, as determined by electron microscopy, and the isolation of adenoviruses from pigeons has occasionally been described (McFerran *et al.*, 1976a; Hess *et al.*, 1996). In these reports it is not always clear how the agents were cultivated, and/or if the isolation concerned adenoviruses causing type I or type II disease. Furthermore, it is not known to which antigenic type(s) adenovirus type I and II agents belong. To date, the distinction between the two agents and disease entities is based mainly on disease course, epidemiology in Europe and histological lesions.

### **Adenovirus type I**

#### **Epidemiology**

Adenovirus type I, first diagnosed in the 1970s (McFerran *et al.*, 1976b), occurs worldwide in pigeons younger than 1 year. Pigeons over 1 year old are not affected (Coussement *et al.*, 1984). The disease has a typical seasonal appearance from March to July, peaking in frequency in June (Uyttebroek and Ducatelle, 1991). In the second half of the year, only sporadic cases are noticed.

#### **Pathogenesis**

To date, the pathogenesis of adenovirus type I infections is not studied sufficiently. Most outbreaks of adenovirus type I occur after the initial races of the young pigeons (Coussement *et al.*, 1984; Uyttebroek and Ducatelle, 1991), and it is supposed that these pigeons are orally infected with adenoviruses by cross-contamination in the common baskets. The viruses replicate in the nucleus of epithelial cells of the intestinal tract, resulting in severe intestinal damage. Due to these lesions, proteins and ions are lost via the intestinal tract. This

alteration of the intestinal environment often leads to mass multiplication of facultative pathogenic agents that are part of the normal intestinal flora, predominantly *E. coli*, and these bacteria may aggravate the intestinal lesions and even cause septicaemia. Viruses are spread via the droppings, thereby infecting all other young pigeons in the loft within a period of 4–5 days. It is remarkable that only pigeons less than 1 year of age develop clinical signs, while older pigeons remain clinically healthy. This may indicate age-related resistance or a strong acquired immunity in these animals. The adenoviruses may spread from the intestinal tract to the internal organs, predominantly the liver, where replication will also take place.

### **Clinical signs and lesions**

Macroscopically, adenovirus type I lesions are characterized by catarrhal enteritis in young pigeons. Histologically, there is an atrophy of the villi and intra-nuclear inclusion bodies can be observed in the epithelial cells of the small intestine. Pigeons suffering from such lesions show a bad general condition, watery diarrhoea, vomiting and weight loss. These clinical signs usually disappear within 1 week, since the adenoviruses are apparently eliminated very quickly, and the epithelium of the intestinal tract regenerates within a few days. Secondary *E. coli* infections may, however, lead to a more severe and prolonged disease. In such complicated cases, pigeons suffer from a green and foul diarrhoea, emaciation and severe weakening, eventually resulting in death. Furthermore, some pigeons die per acutely from *E. coli* septicaemia.

After the recovery of diseased pigeons, racing performances remain low for several weeks. This may be due to slowly healing liver lesions following multiplication of adenoviruses in the hepatocytes. During this hepatic replication phase intra-nuclear inclusion bodies are formed with degenerative lesions. Affected pigeons will therefore acquire less racing experience and may drop behind non-infected contestants.

### **Diagnosis**

In most cases, adenovirus type I can be strongly suspected on a clinical basis: sudden appearance in the entire group; typical signs

of diarrhoea and vomiting; young pigeons only affected; and a typical seasonal appearance. However, the disease should not be confused with paramyxovirus, salmonellosis or hexamitiasis, and these three diseases should be excluded and/or the adenovirus infection itself demonstrated. The definite diagnosis of adenovirus type I can be made by the demonstration of intra-nuclear inclusion bodies in the liver or in the intestinal epithelium using histology and/or cytology. Hepatic inclusion bodies are usually numerous and large, and extensive necrosis is not present (Coussement *et al.*, 1984). These criteria can be used to differentiate adenovirus type I from type II histopathologically.

### **Control**

No preventive vaccines or therapeutic drugs are available at the moment. However, clinical improvement can be obtained by rehydration of affected pigeons and the control of complicating bacterial infections. In the authors' experience, spectacular results can be obtained in most cases by the administration of 200 mg trimethoprim, 100 mg ronidazole and 20 g glucose per litre of drinking water for 5 days. An antibiogram of complicating bacteria can be useful when pigeons do not respond to this treatment.

## **Adenovirus type II**

### **Epidemiology**

Adenovirus type II was first recognized in Belgium in October 1992 (De Herdt *et al.*, 1995a). Later, the disease was diagnosed not only among the Belgian pigeon population but also in pigeons originating from neighbouring countries. From 1993 onwards, adenovirus type II was diagnosed in 15 per cent of the pigeons necropsied at the University of Gent, becoming the most prevalent systemic pigeon disease diagnosed at the institute. Seasonal variations in the prevalence of the disease are not seen, strongly contrasting with the situation in adenovirus type I.

### **Pathogenesis**

Only very few data on the pathogenesis of adenovirus type II infections are available.

However, it is clear that the viral agent is able to induce extensive hepatic necrosis, which may result in sudden death of the pigeons. *Escherichia coli* bacteria secondarily invade the liver and other internal organs in approximately 15 per cent of cases (De Herdt *et al.*, 1995a), and *Staphylococcus intermedius* is also occasionally observed as a complicating factor in adenovirus type II. However, the authors believe that these secondary bacterial infections do not essentially influence the course of the disease.

### **Clinical signs and lesions**

The disease in pigeons suffering from adenovirus type II always follows a characteristic course (De Herdt *et al.*, 1995a). Clinical signs are always minimal, since all affected pigeons die within 24–48 hours. The only clinical signs occasionally seen are vomiting and production of yellow, liquid droppings (Plate 32). Sudden deaths can continue for 6 weeks, with new cases occurring intermittently. Mortality in affected pigeon lofts is usually about 30 per cent, but in some cases amounts to 100 per cent. It is remarkable that in colonies where acute deaths due to adenovirus type II occur, pigeons that do not die remain completely normal and show no clinical signs. Sometimes nestlings even grow up completely normally (provided they are already able to feed themselves or are raised by other pigeons) after one or both of their parents have died of the disease. Adenovirus type II has been observed in pigeons between 10 days and 6 years of age. No correlation exists between the occurrence of the disease and the pigeons' physiological condition, sex or obvious stressing factors.

The most typical necropsy finding in pigeons that have died from adenovirus type II is a yellow, pale and swollen liver with a red sheen. Histological and cytological examination of such livers always reveals extensive focal or diffuse hepatic necrosis and eosinophilic or amphophilic intra-nuclear inclusion bodies.

### **Diagnosis**

Adenovirus type II can be suspected from the owner's complaint of acute deaths in pigeons of all ages without premonitory signs except for occasional short-term vomiting and

diarrhoea. Adenovirus type II does of course have to be differentiated from other causes of sudden death, such as intoxication, streptococcosis, *E. coli* septicaemia and salmonellosis. The ultimate diagnosis can be made at necropsy on the basis of the typical macroscopic aspects of the liver, and extensive hepatic necrosis with intra-nuclear inclusion bodies at histological or cytological examination. These inclusion bodies are less numerous and smaller than in adenovirus type I (De Herdt *et al.*, 1995a).

### **Control**

Neither preventive nor curative measures are available for the control of adenovirus type II in pigeons. The administration of antibiotics is useless; pigeons do not die from secondary bacterial infections, but from the extensive hepatic necrosis induced by the virus. The use of glucocorticoids must be discouraged since it has been proven experimentally that pigeons become more susceptible to the disease following administration of these products. Pigeon fanciers dealing with an outbreak of adenovirus type II should always be advised to maintain excellent hygienic conditions within the loft combined with good ventilation, in order to keep infection pressure as low as possible.

## **Herpesvirus infections**

### **Aetiology**

Pigeon herpesviruses all belong to the same antigenic type (PHV1) (Vindevogel *et al.*, 1980). They are antigenically different from psittacine herpes types or herpesviruses from other animals. PHV1 can be isolated in chicken embryo fibroblast cell cultures or in embryonated chicken eggs.

### **Epidemiology**

More than 50 per cent of racing pigeons possess antibodies against PHV1 (Vindevogel *et al.*, 1981), and this usually indicates latent infections. Clinical disease occurs very seldom; at Gent University, herpesviruses are found to be responsible for clinical disease in only 0.2 per cent of the necropsied pigeons. PHV1 is widespread in the pigeon environment. A

German study (Holz, 1992) demonstrated that up to 60 per cent of pigeon transport baskets may be positive for herpesvirus.

### **Pathogenesis**

The majority of the pigeon population is latently infected with herpesviruses. These birds may intermittently shed the agents, especially when under stress. Stressing factors that contribute to virus excretion are breeding and transport conditions of high temperature and high occupation density. Squabs with maternal antibodies do not usually develop clinical disease following a herpesvirus infection, but they become latently infected for the rest of their lives. Clinical herpesvirus infections predominantly prevail in squabs from uninfected parents and in immunosuppressive pigeons. Herpesvirus may cause systemic disease between 2 and 10 weeks of age, while in older pigeons the agents may play a (small) role in problems of coryza.

### **Clinical signs and lesions**

Systemic herpesvirus infections in nestlings cause acute deaths without clinical signs (Vindevogel *et al.*, 1975). In affected animals, the liver is enlarged and shows focal necrosis. Histologically, intra-nuclear herpes-type inclusion bodies are found in the hepatocytes surrounding necrotic areas (Vindevogel and Pastoret, 1981). Necrosis may also be present in the spleen. The herpes-type inclusion bodies are smaller and less numerous than adenovirus inclusions.

The role of herpesviruses in outbreaks of coryza is discussed elsewhere in this chapter. Pigeons with respiratory herpesvirus infections may develop diphtheric inflammation of the larynx, oesophagus and trachea (Vindevogel and Duchatel, 1978) (Plate 33). Nuclear inclusion bodies can also be observed in these lesions.

### **Diagnosis**

Herpesvirus infections can be diagnosed through isolation of the agents from lesions or through the demonstration of nuclear inclusion bodies. Herpesvirus as a cause of acute death in nestlings must be differentiated from other infectious agents that may cause similar

problems, such as paramyxovirus, *Salmonella* spp., *S. gallolyticus*, *E. coli*, *Trichomonas* spp. and *Hexamita* spp.

Diphtheric lesions in the mouth may also originate from infections with pox viruses, *Trichomonas* spp. and *Candida albicans*. Furthermore, they should be differentiated from sialolytes, which are white concretions that may occur at the back of the pharynx. These plugs originate in the fundus of the salivary glands, and their aetiology and significance are unknown. Racing performances of pigeons presenting sialytes are often poor.

### **Control**

No preventive or curative control measures against herpesvirus infections in pigeons are available to date.

## **Pox virus infections**

### **Aetiology**

Two different types of clinical pox virus infections are known in pigeons. The first type is the 'typical' pox virus infection (Tripathy, 1991), while the second type is 'atypical' pox or 'blood pox' infection (Hartig and Frese, 1973). Viruses that cause the two diseases are probably unrelated. The typical virus is host-specific and has common antigens with fowl pox viruses. This agent can be cultivated on the chorio-allantoic membrane of embryonated chicken eggs. Isolation of atypical pox viruses has not been described. The pox virus aetiology of atypical pox disease has been demonstrated by electron microscopy.

### **Epidemiology**

The occurrence of typical pox virus infections in pigeons is strictly correlated with the availability of vectors responsible for the transmission of the disease. Therefore, these infections may have a typical distribution in time and space. Under moderate climatic circumstances, typical pox virus infections prevail in late summer and autumn because of the large numbers of vector mosquitoes occurring at that moment. Clinical outbreaks predominantly occur in young pigeons. Spread of the disease is usually very slow, and may take

several weeks. Atypical pox occurs very sporadically and, in contrast with typical pox, only one or a few pigeons in the loft are affected. These birds are usually less than 2 years old.

### **Pathogenesis**

Typical pox virus infections in pigeons are initiated when the aetiological agents are inoculated in skin defects (Eleazer *et al.*, 1983). After an incubation period of 10–20 days, viral replication will lead to typical epithelial pox lesions. From this primary site of entry the virus may spread to internal organs and, through a secondary viraemia, reach distant parts of the skin as well as different mucosae. This will result in further dermal diphtheroid and mucosal lesions, respectively. The virus is shed predominantly through desquamation of infected epithelial cells. Transmission of pox virus occurs through direct contact with infected birds (e.g. during fighting) or indirectly through stinging and blood-sucking parasites (such as mosquitoes and ticks) that may act as vectors. In such vectors, the virus does not replicate but retains its infectivity for life. Besides spreading the virus, vectors are important for creating dermal defects. During non-lethal infections, pox lesions will spontaneously regress after 7–21 days, when immunity is built up. The pathogenesis of atypical pox in pigeons is unknown. Blood pox spontaneously shrivel and disappear without residual lesions after 3–4 weeks.

### **Clinical signs and lesions**

Clinical manifestations of typical pox in pigeons are extremely characteristic. Traditionally, a more common cutaneous form and a less common diphtheroid form are distinguished. In the cutaneous form, lesions consist of hypertrophic proliferation of epithelium, predominantly around the beak and on the eyelids (Plate 34). Swollen eyelids can inhibit the pigeon's vision and consequently the uptake of feed, resulting in starvation. In the diphtheroid form, pseudomembranous lesions are found in the anterior part of the oral cavity (Plate 35). These lesions may also lead to starvation when they interfere with feed intake. Histologically, typical pox viruses induce hyperplasia and necrosis of epithelial cells (Tripathy, 1991). At the border of necrotic foci, eosinophilic cyto-

plasmic inclusion bodies, the so-called Bollinger bodies, can be found (Plate 36). Inclusion bodies become particularly evident in the epidermal cells during the subacute or chronic stages of the disease.

Atypical pox are wart-like lesions that are predominantly located on the body or wings of pigeons. Usually they are solitary lesions, but sometimes several of them are present. They grow until they measure 1–3 cm, and black, bloody contents glimmer through an intact skin. When these wart-like lesions are damaged they may bleed heavily, occasionally leading to death of the pigeon. Pigeons with atypical pox are not visibly sick. Histologically, there is proliferation of the epithelium of the feather follicles or of the skin. The cells contain melanin and cytoplasmic inclusion bodies.

### **Diagnosis**

Cutaneous and diphtheroid forms of typical pox as well as atypical pox can generally be diagnosed easily by the characteristic lesions. The clinical diagnosis can be confirmed by histological examination. Typical pox agents can also be isolated in embryonated chicken eggs. The diphtheroid form of typical pox must be differentiated from trichomoniasis, candidiasis or herpesvirus infections. Atypical pox must be distinguished from melanomata.

### **Control**

Typical pox virus infections can be prevented by vaccination with live, attenuated, homologous pigeon pox viruses. Vaccines can be administered from the age of 6 weeks, either by the feather follicle method or by subcutaneous injection. A strong protective immunity is induced within 2 weeks and lasts for at least 1 year. Vaccination can also be a useful measure during an outbreak; however, under such circumstances, care must be taken not to spread the infectious virus via the equipment used. Curative treatment of pigeons suffering from typical pox virus infections is not possible. Drugs can be used to prevent complicating infections with bacteria or *Trichomonas* spp. Forced feeding may be useful in valuable pigeons with severe beak or eyelid lesions.

Preventive vaccines or curative treatments against atypical pox in pigeons do not exist. In order to prevent mortality through bleeding

of the lesions, affected pigeons are best kept in isolation until they have fallen off. For the same reason, no attempt should be made to remove the lesions surgically.

## Salmonellosis

### Aetiology

In pigeons, salmonellosis means infection with a pigeon-specific pathogenic *Salmonella* serotype, notably *S. Typhimurium* var. Copenhagen (Pohl *et al.*, 1983), which is a Gram-negative, facultative intracellular bacterium belonging to the family Enterobacteriaceae.

The bacteria can be cultured from internal organs on non-selective Columbia agar with 5 per cent bovine blood, or from intestines or faeces on selective agars such as Brilliant Green agar. Enrichment media for the selective isolation of *Salmonella* spp. from contaminated materials are also available, e.g. tetrathionate broth.

### Epidemiology

*S. Typhimurium* var. Copenhagen is found in poultry, bovines and humans as well as in pigeons, but strains are different with regard to biochemical and antigenic properties and phage susceptibility (Pohl *et al.*, 1983). This strongly host-specific association implies that the infection is limited to pigeons and their environment only, and that pigeons play no role of any importance in the spread of salmonellosis in humans or in other animal species (Nastasi *et al.*, 1993).

### Pathogenesis

Pigeons suffering from salmonellosis excrete the bacteria in the droppings, thereby effecting horizontal spread of the disease. Pigeons are infected by oral uptake of the agent from contaminated feed, drinking water, baskets, etc. *Salmonella* spp. first colonizes the pigeons' intestinal tract, and from this primary site of replication often invades the bloodstream, causing bacteraemia. During haematogenic spread the bacteria reach different parts of the body, such as the lungs, liver, spleen, testis, ovary, brains, muscles, eyes, skin and joints,

where they also multiply. Localization of *Salmonella* spp. in the gonads, as well as eggshell contamination, may eventually cause vertical spread of the disease.

Pigeons can clinically recover from a *Salmonella* spp. infection, either spontaneously or following antibiotic treatment. Some of these pigeons, however, do not manage to eliminate all the bacteria, and become asymptomatic carriers. *Salmonella* spp. bacteria may survive inside different cell types, such as macrophages, or within necrotic lesions. Carriers play an important role in the pathogenesis of pigeon salmonellosis, since they intermittently shed the bacteria and thereby infect other pigeons. Because of this, salmonellosis is often chronically present in pigeon lofts.

Replication of *Salmonella* spp. generally induces lesions and clinical signs, but lesions may also arise in the absence of bacteria. Typical in this respect is an extreme swelling of the elbow joint that may develop months to years after the bacteria were eliminated from the loft. The pathogenesis of this type of lesion is unknown. Fluid obtained from such elbows often contains large amounts of antibodies against *Salmonella* spp.

### Clinical signs and lesions

The ability of *Salmonella* spp. to replicate in various pigeon organs is reflected by a variety of lesions found in affected birds. Depending on the organs affected and the extent of the lesions, several specific and general clinical signs may occur either solely or simultaneously (Devriese, 1986).

In acute salmonellosis, intestinal lesions with fibrinous enteritis and focal ulceration are consistently present. When septicaemia occurs, enlargement of the intestinal organs is seen, caused by inflammatory activity of heterophilic granulocytes and macrophages. Clinically, this acute form of the disease generally begins with one single pigeon in the loft that refuses to eat and eventually shows a slimy or bloody diarrhoea. Only small amounts of droppings are produced, and they consist almost exclusively of green-stained urates. Polyuria may be present. After a few days, the affected pigeon either dies or starts to recover. Meanwhile, other pigeons generally develop similar signs.



**Figure 14.2** *Salmonella* spp. induced arthritis of the *canalis triosseus*.

The acute organ lesions may evolve to focal necrosis and formation of abscesses and granulomata. Pigeons suffering from such lesions show a bad general condition, until they eventually succumb. When specific organs are involved in the disease process, lesion-dependent signs may occur. Arthritis of the legs and the wings results in lameness and inability to fly, respectively. Extensive swelling of the elbow is an almost pathognomonic sign, although the shoulder joint and the *canalis triosseus* may also be involved (Figure 14.2). Infertility and/or embryonic death are associated with multiplication of the bacteria in the gonads, and blindness can be ascribed to *Salmonella*-panophthalmitis. Dermal lesions include small abscesses in the eyelids or in the subcutis of the neck region, as well as occasional exudative dermatitis on the lower side of the wing. Sporadically, opisthotonus occurs when the infection localizes in the brain. Respiratory signs are not associated with salmonellosis; nevertheless, necrosis and abscess formation in the lungs and air sacs are often characteristic lesions.

Sudden and virulent outbreaks of salmonellosis are seen exclusively in nestlings. Nestlings can be infected during an outbreak of acute salmonellosis in the loft, or when asymptomatic carrier pigeons are used for breeding. Carrier pigeons may infect their progeny by vertical or neonatal transmission, resulting in mass mortality of nestling, usually starting from day 5. In less acute cases, nestlings may show retarded growth, paralysis and non-unfolding feathers.

### Diagnosis

In pigeons that die from salmonellosis, the aetiological agent can be isolated from internal organs at necropsy. Bacteriological examination of the droppings can confirm the diagnosis in live animals, but the method is not very reliable for chronically affected individual pigeons since they may excrete the bacterium intermittently. It is therefore best to pool faecal samples over a period of 5 days. *Salmonella* spp. should be seen both on direct inoculation of culture plates and following enrichment.

For a rapid diagnosis of salmonellosis, a slide agglutination test can be used (Devriese, 1986). In this test, one drop of formaldehyde-inactivated *Salmonella* group B bacteria is mixed with one drop of plasma from suspected pigeons and placed on a slide. The slide is then rocked and tilted slowly for 2 minutes, and a positive reaction demonstrates the presence of antibodies resulting from Salmonellosis or possibly vaccination against salmonellosis. False negative reactions occur, because only 25 per cent of infected pigeons build up agglutinating antibodies. It is mainly pigeons suffering from acute salmonellosis with severe clinical signs that react positively in the slide agglutination test. Chronically infected pigeons, as well as asymptomatic carriers, usually remain negative. The slide agglutination test can also be performed with fluid obtained from the joints of pigeons with arthritis. More sensitive serological tests have been described, but they are usually time-consuming and expensive, which make them less useful in clinical practice.

Clinical disease due to *Salmonella* spp. infections must be differentiated from other diseases with rather similar signs, e.g. streptococcosis, adenovirus, hexamitiasis, ascaridiosis, capillariosis and paramyxovirus.

### Control

Control of salmonellosis is possible but difficult. Eradication programmes for infected lofts include four points that must be rigorously followed: sanitation, antimicrobial treatment, vaccination and bacteriological checks of the faeces. Sanitation must be performed first (Devriese, 1986), and this includes euthanasia of clinically diseased pigeons, since these animals may develop



chronic lesions and become asymptomatic carriers. Valuable pigeons, which the owner refuses to sacrifice, must be treated in quarantine, and can only be reintroduced to the loft when repeated bacteriological examinations of faecal samples have proved them free of *Salmonella* spp. Further sanitary measures include thorough cleaning and disinfection of the loft. Breeding must be interrupted, and over-population avoided. After sanitation, the remaining pigeons must be treated with antimicrobials for at least 10 days. *In vitro* the bacteria are sensitive to a large number of antimicrobials, but *in vivo* the best results are obtained with enrofloxacin (200 mg/l) or trimethoprim (200 mg/l) (Uyttebroek *et al.*, 1991). Treatment does not, however, guarantee complete elimination of the bacteria, and an inactivated vaccine for administration immediately after completion of antimicrobial treatment has been developed (Uyttebroek *et al.*, 1991). This vaccine is not intended to protect pigeons against infection with *Salmonella* spp., but rather to stimulate the cellular immunity of infected pigeons so that they will spontaneously eliminate the infection. Following vaccination, pigeons may become serologically positive for 3–18 months. Side-effects resulting from an intense immunological response to the *Salmonella* antigens in the vaccine may occur, mainly in pigeons previously infected with *Salmonella* spp. Occasionally, a pigeon dies within 24 hours of vaccination. In some lofts, large subcutaneous nodules with histiocyte accumulations of the 'foreign body' type may develop at the site of injection 7–10 days after vaccination. These granulomata cause pain, anorexia, bad general condition and eventually death. In severe cases, they have to be removed surgically. The outcome of the control programme has to be assessed on the basis of regular bacteriological examinations of pooled faecal samples, for example 1 month after treatment and subsequently every 6 months. When samples appear positive, the treatment protocol must be repeated.

### Streptococcosis

Streptococcal infections were first described in pigeons in 1990 (Devriese *et al.*, 1990). Since then, streptococcosis has been recognized as an important systemic disease in pigeons (De Herdt *et al.*, 1992a).

### Aetiology

The aetiological agent of streptococcosis in pigeons is *Streptococcus gallolytius*, a Gram-positive bacterium. Within this species, different types have been recognized in pigeons: there are five biotypes, two sub-biotypes, five serotypes and six supernatant-phenotypes (De Herdt *et al.*, 1992b; Vanrobaeys *et al.*, 1996). The biotypes and sub-biotypes are determined by their haemolytic properties, polysaccharide production and carbohydrate fermentation; the serotypes are distinguished by agglutination; and supernatant-phenotypes are identified on the basis of the presence of four proteins (A, T1, T2, T3) in the supernatant of *S. gallolytius* broth cultures.

*S. gallolytius* isolates from pigeons can be cultured on non-selective media such as Columbia agar with 5 per cent bovine blood. Slanetz and Bartley agar can be used as a selective medium. The medium needs to be boiled for at least 5 minutes for optimal recovery of *S. gallolytius*, and the media should preferably be incubated in the presence of a 5 per cent elevated CO<sub>2</sub> concentration.

### Epidemiology

Approximately 40 per cent of all pigeons carry *S. gallolytius* in the intestinal tract without showing clinical signs (De Herdt *et al.*, 1994a). These bacteria may belong to different biotypes, serotypes and supernatant-phenotypes. The carriage rate is not related to the season or to the age of the pigeons. Healthy carrier pigeons can be found in approximately 80 per cent of pigeon lofts, indicating that *S. gallolytius* can be part of the normal intestinal flora in pigeons. On the other hand, *S. gallolytius* is also an important cause of bacterial septicaemia in pigeons. Therefore, the bacterium must be considered a facultative pathogenic agent. The incidence of *S. gallolytius* septicaemia in pigeons is higher between January and August than between September and December (De Herdt *et al.*, 1994a). At the Veterinary Faculty of the University of Gent, *S. gallolytius* septicaemia is diagnosed in approximately 10 per cent of all necropsied pigeons, indicating the high clinical importance of this disease.

### Pathogenesis

As long as *S. gallolytius* bacteria are limited to the intestinal tract of pigeons, no clinical signs are observed. Clinical disease problems will, however, occur when the bacteria enter the bloodstream and cause septicaemia. *S. gallolytius* septicaemia often occurs in pigeons held under poor hygienic conditions. The incidence of streptococcosis is also high in female pigeons during breeding (De Herdt *et al.*, 1991; De Herdt *et al.*, 1994b). Finally, *S. gallolytius* septicaemia sometimes complicates *Salmonella* spp. infections.

Morbidity and mortality during an outbreak of streptococcosis will depend on the virulence of the causative strain. It has been demonstrated that the supernatant-phenotypes T1, AT1, AT2 and AT3 are highly virulent, while the T3 strains are moderately virulent and the T2 isolates are almost apathogenic (De Herdt *et al.*, 1994c; Vanrobaeys *et al.*, 1997). Virulent strains have several virulence mechanisms. First, they are able to multiply intracellularly in macrophages, resulting in a protection against humoral defence mechanisms and, consequently, promotion of the invasive character of the bacteria (De Herdt *et al.*, 1995b). Furthermore, *S. gallolytius* bacteria can adhere to muscle fibres and they probably also form toxins (De Herdt *et al.*, 1994c). These two virulence factors may contribute to the formation of some specific necrotic lesions, e.g. in the pectoral muscles.

The course of an infection can of course be influenced by the immune status of the pigeons. At present, immunity against *S. gallolytius* septicaemia is not well understood and data on this subject are scarce (De Herdt *et al.*, 1995c). It has been demonstrated that pigeons suffering from *S. gallolytius* septicaemia with a serotype 1 or serotype 2 strain build up protective immunity against re-infection with the serotype 1 strain. However, no protection against serotype 1 septicaemia was induced after infection with a serotype 3 strain.

### Clinical signs and lesions

Acute or hyperacute death in pigeons of all ages is the most constant clinical sign related to *S. gallolytius* septicaemia, occurring in nearly half the pigeon lofts dealing with

outbreaks of the disease. In pigeons that die very suddenly, an overwhelming multiplication of *S. gallolytius* has usually taken place in different internal organs such as the liver, spleen, kidneys and myocardium. In these organs, inflammatory activity and focal necrosis can be observed. The most typical lesion of streptococcosis consists of a large, well-circumscribed area of necrosis in the pectoral muscle (Plate 37). When present, this lesion can be seen through the skin. Pigeons with pectoral muscle necrosis always die within a few hours of the lesion(s) developing.

Another typical sign is drooping of the wings and an inability to fly, which is observed in approximately 6 per cent of affected pigeons. Lesions in affected pigeons include tenosynovitis of the tendon of the deep pectoral muscle and/or arthritis of the shoulder joint. Sometimes, large amounts of oedematous or viscous fluid, occasionally with fibrin clots, are accumulated at these sites. The lesions result from multiplication of *S. gallolytius* around the deep pectoral muscle tendon in the *canalis triosseus* or the shoulder joint.

Lameness occurs in approximately 8 per cent of cases. Lesions consist of arthritis of the stifle joint or the hock joint, as a reaction to replication of *S. gallolytius*. In 17 per cent of the outbreaks, pigeon owners' anamnesis includes the production of green, slimy droppings and/or polyuria. The green, slimy droppings do not result from intestinal tract lesions, but are probably due to malfunction of the liver. Polyuria can be explained by tubular necrosis in the kidneys.

Inappetence and emaciation are predominant signs in 9 per cent of the lofts affected by streptococcosis. Usually, most internal organs show coagulation necrosis and inflammation resulting from multiplication of the bacteria.

Nervous disorders can also be associated with *S. gallolytius* septicaemia (approximately 9 per cent of cases). CNS signs include complete paralysis and leaning on the forehead in trying to stand up. Meningitis and/or encephalitis in the cerebrum and the cerebellum occurs in these pigeons.

Pigeons suffering from the clinical signs mentioned above usually show a bad general condition. However, in 7 per cent of all diagnoses of *S. gallolytius* septicaemia, a wasting condition is the only clinical expression of the disease. Organ lesions under these

conditions are often rather mild, although live bacteria are present.

It is important to keep in mind that, in lofts identified as having an outbreak of *S. gallolytius* septicaemia, the different clinical signs may occur either simultaneously or singly (De Herdt *et al.*, 1994b).

### Diagnosis

The diagnosis of streptococcosis can be suspected on the basis of the clinical signs. However, these signs are not specific to streptococcal infections. Acute death, the most constant clinical sign in *S. gallolytius* septicaemia, is also associated with adenovirus type II infections, intoxication, *E. coli* septicaemia and acute salmonellosis. Chronic salmonellosis, trauma or hypocalcaemia may lead to an inability to fly. Lameness can be ascribed to trauma or salmonellosis. Green, slimy droppings can indicate *Hexamita* spp. or adenovirus type I and paramyxovirus or *Salmonella* spp. infections, respectively. For a definite diagnosis of streptococcosis, necropsy is required. Typical lesions have to be present, and/or the bacterium has to be isolated from affected organs. Isolation of *S. gallolytius* from intestinal contents or droppings cannot be used for diagnostic purposes because of the occurrence of healthy carrier pigeons.

### Control

Antimicrobials can be used for the treatment of pigeons suffering from streptococcosis (De Herdt *et al.*, 1993). *In vitro*, *S. gallolytius* strains from pigeons are always (so far) sensitive to penicillin G, ampicillin and amoxicillin. Acquired resistance to macrolides, lincomycin, chloramphenicol, nitrofurans and tetracyclines was found to occur in approximately 6 per cent, 9 per cent, 3 per cent, 1 per cent and 41 per cent of the strains respectively. All strains are intermediately sensitive to neomycin, gentamicin and enrofloxacin. Pigeon *S. gallolytius* strains are resistant to trimethoprim or sulphonamides. In practice, the administration of ampicillin 2 g/l for at least 7 days is the treatment of choice. Doxycycline 500 mg/l and erythromycin 1 g/l are good alternatives when the infecting *S. gallolytius* strains do not have acquired resistance to these drugs.

Antibiotics do not eliminate *S. gallolytius* from the intestinal tract, even after an otherwise successful treatment. If the factors predisposing to septicaemia and disease are still present when excretion of *S. gallolytius* resumes, a new outbreak of streptococcosis may occur. Since poor hygiene is often involved, antibiotic treatment should be accompanied by hygienic measures. In this respect, keeping the pigeons on wire floors is very effective. This inhibits re-infection of pigeons with *S. gallolytius* bacteria from the droppings, thus reducing the re-inoculation of the agent in the intestinal tract.

## *Escherichia coli* septicaemia

### Aetiology

*Escherichia coli* is a Gram-negative rod-shaped bacterium that belongs to the family Enterobacteriaceae. There appears to be great variety in the biochemical properties of pigeon *E. coli* strains, and the antigenic properties of pigeon *E. coli* bacteria have not yet been determined. *E. coli* isolates from pigeons can easily be cultivated on numerous media, for example on non-selective Columbia agar with 5 per cent bovine blood, or on selective McConkey agar.

### Epidemiology

*E. coli* bacteria are present in the intestinal tract of approximately 97 per cent of all pigeons as a part of the normal flora (De Herdt *et al.*, 1994d). On the other hand, *E. coli* also is an important cause of bacterial septicaemia in pigeons, representing 7 per cent of the necropsy diagnoses at Gent University. To date, no differences have been found in *E. coli* strains isolated from healthy and diseased pigeons, indicating that *E. coli* is a facultative pathogenic agent in pigeons.

### Pathogenesis

Very little is known of the pathogenesis of *E. coli* septicaemia. *E. coli* bacteria are normal inhabitants of the intestinal tract in pigeons. Factors leading to septicaemia and disease include adenovirus infections and probably numerous other conditions that are unknown. Most *E. coli* strains isolated from pigeons

produce aerobactin and resist the bactericidal activity of pigeon serum (De Herdt *et al.*, 1994d). The possible relationship between these properties and virulence is unclear.

### **Clinical signs and lesions**

Clinical disease can occur either solely in the nestlings or in pigeons of all ages. In the first case, *E. coli* septicaemia may cause sudden death in nestlings, usually between days 3 and 5. The parents do not usually develop clinical signs. Nestlings from the same parents may suffer from *E. coli* septicaemia in successive nests.

In other outbreaks, pigeons of all ages are affected (De Herdt *et al.*, 1994d). The main clinical signs in these birds are sudden death, diarrhoea, vomiting and weight loss, which occur in 55 per cent, 23 per cent, 23 per cent and 13 per cent of cases, respectively (De Herdt *et al.*, 1994d). The lesions in the affected pigeons resemble septicaemia, but are not typical: congestion or paleness of organs, and infiltration of inflammatory cells and bacteria in the affected organs.

### **Diagnosis**

It is very difficult to establish the diagnosis of *E. coli* septicaemia on a clinical basis only. Vomiting is more or less typical for *E. coli* septicaemia, but it also occurs with adenovirus and heavy infestations of ascaridia or capillaria. Acute death in nestlings can be attributed to trichomoniasis, salmonellosis, paramyxovirus and tick infestations. Sudden death and/or diarrhoea in pigeons of all ages can also be associated with adenovirus, intoxication, streptococcosis and salmonellosis.

*E. coli* septicaemia can only be diagnosed at autopsy. Lesions indicative of septicaemia have to be present, and the bacterium has to be isolated from affected organs in pure culture. Isolation of *E. coli* from intestinal contents or droppings is not diagnostic because of the occurrence of healthy carrier pigeons.

### **Control**

Antimicrobials are generally used for the treatment of pigeons with *E. coli* septicaemia.

The choice of antimicrobial should preferably be based on the results of antibiograms, since pigeon *E. coli* strains may have very high levels of acquired antibiotic resistance. Acquired resistance is especially high against tetracyclines, nitrofurans and chloramphenicol (De Herdt *et al.*, 1994a). When the bacteria are sensitive, good results are obtained with enrofloxacin 150 mg/l or trimethoprim 200 mg/l.

## **Ornithosis (*Chlamydophilia psittaci*) and respiratory disease**

### **Aetiology**

Respiratory disease in pigeons is a multifactorial problem that may include infectious and non-infectious components. Non-infectious factors include the climate and the environment of the pigeon loft; hygiene, humidity, temperature, population density, draught, ventilation, dust, etc. The infectious agents that cause respiratory disease in pigeons have not yet been fully determined. In the literature there is much confusion and disagreement concerning the identity of respiratory pathogens in pigeons. In the authors' experience, the following agents can be primarily or secondarily involved: herpesvirus; *Chlamydophilia psittaci*; *Escherichia coli*; *Staphylococcus intermedius*; *Pelistegea europaea* and *Aspergillus fumigatus* (De Herdt *et al.*, 1998). However, it is suspected that yet unidentified viruses may also play a role. Although occasionally mentioned in handbooks on pigeon medicine, paramyxovirus serotype 1, *Mycoplasma* spp. and *Haemophilus* spp. are not respiratory pathogens in pigeons, as opposed to the situation in poultry.

### **Epidemiology**

Respiratory disease may occur throughout the year and in all age groups. However, clinical signs are most obvious in young birds. Problems are typically seen in late winter–early spring, or in summer. These periods coincide with the beginning of the open and racing seasons respectively.

*C. psittaci*, *E. coli*, *P. europaea* and *S. intermedius* are the main agents that cause respiratory disease of pigeons. *A. fumigatus*, on the other hand, is seen only very rarely, and almost always affects individual cases. Herpesvirus is widely spread among pigeon populations, but only occasionally causes clinical infections.

### **Pathogenesis**

Non-infectious factors may predispose pigeons to infection with respiratory pathogens, and unfavourable environmental conditions also contribute to the severity of infectious respiratory diseases.

The pathogenesis of herpesvirus infections is discussed earlier in this chapter. Infection of pigeons with *C. psittaci* occurs through inhalation of the bacterium (Schachter and Caldwell, 1980). The agent multiplies inside epithelial cells of the respiratory and intestinal tract, and in various internal organs. This often leads to respiratory signs and generalized disease. Many pigeons become asymptomatic carriers and excrete the bacterium through nasal secretions, faeces and crop milk (Burkhart and Page, 1971). The pathogenesis of *E. coli*, *S. intermedius* and *P. europaea* infections has not been studied in pigeons.

*A. fumigatus* is a ubiquitous fungus that occurs particularly in warm and humid environments. Pigeons may develop aspergillosis infections when they are infected with a high number of spores. High infection pressures tend to prevail during overcrowding and under poor hygienic conditions; for example in lofts with low ventilation, putrefying droppings, contaminated litter and decayed feed. Spores are easily spread by air, causing subsequent infections of air sacs and lungs. Intercurrent disease, long-term antibiotic treatment and corticosteroids may furthermore predispose pigeons to aspergillosis.

### **Clinical signs and lesions**

The clinical signs associated with respiratory disease in pigeons are very diverse. In obvious cases, pigeons may produce rattling respiratory noises and nasal mucus. This condition is known as coryza. Pigeon coryza is

purely a clinical disease entity, and does not indicate an infection with specific agents. This is different to the situation in poultry, where coryza indicates infection with *H. paragallinarum*. An extremely valuable sign of respiratory disease in pigeons is open mouth breathing, even when this is very discrete, as clinically healthy pigeons always breathe through their noses, except during hot weather or after heavy physical effort. Another respiratory sign is conjunctivitis, which may occur in one or both eyes. This usually indicates a chlamydophilial infection. In severe cases, the third eye lid may hang down. In some pigeons, respiratory signs are less obvious. Pigeon owners often note swollen heads and insufficient patency of the pigeons' nostrils, and such pigeons often sneeze abundantly during a massage of the nostrils or larynx. Feathers next to the auditory canal are typically erected, and tracheal noises can occasionally be heard.

In lofts that suffer chronically from chlamydophilial infections, respiratory signs may be less pronounced. Complaints may rather include poor racing performances and intermittent production of somewhat green, pasty droppings.

In most pigeons suffering from respiratory disease, lesions are confined to rhinitis, sinusitis, conjunctivitis, tracheitis or airsacculitis. The nature of this inflammatory process is usually catarrhal, but it may become purulent in some cases. In clinical herpesvirus infections, necrotizing tracheitis with fibrin formation as well as focal hepatic necrosis can be seen. Generalized chlamydophilial infections lead to swelling and inflammation of several internal organs, predominantly the spleen and liver. Lesions in pigeons suffering from aspergillosis are comparable to those described in parrots.

### **Diagnosis**

The diagnosis of respiratory disease must be made by a thorough clinical examination. In live animals, it is not always easy to identify the infectious agent that causes the problems. It is possible, however, to determine whether *Chlamydia* spp. is involved, and this may be important with respect to the treatment. *Chlamydia* spp. can be traced by microscopic examination of swab samples from

the conjunctiva and cloaca, stained with the modified Giménez stain (Vanrompay *et al.*, 1992). The results must be interpreted with care: positive samples may indicate a pigeon suffering from ornithosis as well as a *Chlamydia* spp. carrier pigeon. In pigeons suffering from ornithosis, numerous cells of the conjunctiva are usually positive for the bacterium; in carrier pigeons only a low number of conjunctival cells contain chlamydiae. When pigeons are negative for ornithosis, it can be useful to stain a swab sample of the nose contents or trachea with a rapid blood staining technique. Large numbers of coccidial bacteria may indicate a staphylococcal infection.

Autopsy of affected pigeons may give additional information when the aetiological agent can be demonstrated in internal organs, air sacs or sinuses. Herpesvirus infections can most easily be diagnosed on the basis of the presence of intra-nuclear inclusion bodies in tracheal or hepatic lesions examined by exfoliative cytology or histology. Isolation of herpesvirus is also possible. Identification of most bacteria and *Aspergillus* spp. requires isolation, except for *Chlamydia* spp., which can also be demonstrated cytologically.

### Control

A first measure that must be taken in all outbreaks of respiratory disease in pigeons is to improve the climate in the pigeon loft. Besides that, curative therapy must be directed against the infectious cause of the disease. Infections with *Chlamydia* spp., Staphylococci and *E. coli* are controlled most effectively with doxycycline (600 mg/l for at least 14 days), and enrofloxacin (150 mg/l for 5 days), respectively. Infections with *S. intermedius* and *P. europaea* respond well to treatment with amoxicillin (1.5 g/l for 5–10 days.) When an antibiogram indicates acquired resistance of bacteria to some of these products, other drugs such as trimethoprim, macrolides or sulphonamides must be used.

Control of aspergillosis in pigeons consists of the elimination of the source of infection. Treatment of individual pigeons is useless. No curative or preventive treatment exists against herpesvirus infections.

## Trichomoniasis

### Aetiology

Trichomoniasis in pigeons is caused by *Trichomonas gallinae*, a 5–19- $\mu$ m parasite with four anterior flagella (Levine, 1985a). The pigeon is the primary host, but *T. gallinae* also occurs in a number of other birds, including hawks, falcons and eagles, that feed on pigeons.

### Epidemiology

*T. gallinae* is extremely common in domestic pigeons. However, severe lesions or clinical signs are predominantly seen in nestling and young pigeons, and not in adult birds.

### Pathogenesis

Pigeons suffering from trichomoniasis shed the parasites through the saliva and the crop milk. Trichomonads have no cysts and is very sensitive to drying, so direct contamination is necessary. Pigeons are infected with the parasite by the uptake of contaminated water or oral contact with affected pigeons during fighting or feeding of squabs. The parasites colonize the upper digestive tract, predominantly the crop. In severely infected pigeons, Trichomonads may descend to the oesophagus and eventually break through the intestinal wall, affecting the large blood vessels and the liver. The parasites may also multiply in the umbilical region, causing inflammation.

### Clinical signs and lesions

Lesions and clinical signs due to trichomoniasis largely depend on the virulence of the infecting strain and the age of the pigeons. Most strains are of low virulence, and the majority of pigeons suffering from trichomoniasis do not show macroscopic lesions. Early lesions in the mouth consist of irregular yellow plugs and exudate on the mucosa of the soft palate. Small, yellowish, circumscribed areas can increase in number and become progressively larger, finally developing into very large, caseous masses that may invade the roof of the mouth and even extend to the sinuses (Plate 38). The early lesions in the pharynx, oesophagus and crop are small, whitish to yellowish caseous nodules that may also grow to thick necrotic

masses. It is very typical that these lesions can be easily removed without bleeding. In squabs, similar 'yellow button' lesions can be found in the liver and in the umbilical region when the parasites multiply in these parts of the body.

In adult pigeons, trichomoniasis is associated with poor racing performance and no manifest clinical signs. Heavily infected pigeons usually show somewhat fluid droppings with a sour odour. Rarely, adult pigeons may die acutely when the parasite affects the large blood vessels. Sudden death and wasting are complaints associated with trichomoniasis in nestlings.

Immunity can apparently be achieved with great difficulty, although in chronically infected lofts very old pigeons may remain consistently negative. There is usually cross-protection between virulent and less virulent strains of *Trichomonads*.

### **Diagnosis**

Crop samples from pigeons can easily be obtained using a swab or an inoculating loop. Contents from the crop collected in this way should be suspended immediately in a drop of phosphate-buffered saline solution on a cover slip, and observed microscopically at a magnification of 100×. Trichomonads can be recognized as a wriggling flagellar parasite. The water used for this examination should preferably be sterile, since tap water may contain saprophytic flagellates.

Mouth lesions due to Trichomoniasis should not be confused with diphtheric lesions due to a pox virus infection. The latter lesions are more voluminous, are localized in the front of the mouth and bleed if attempts are made to remove them. Furthermore, sialolytes (very small white or yellowish nodules in the roof of the pharynx) and herpesvirus-associated lesions should not be misdiagnosed as trichomoniasis.

### **Control**

Pigeons suffering from trichomoniasis can be treated with different 5-nitro-imidazoles such as ronidazole (100–200 mg/l), dimetridazole (400 mg/l) and metronidazole (1 g/l) (Devriese, 1986). Treatment is usually over 5 days using ronidazole and metronidazole,

and 3 days for dimetridazole. Pigeon fanciers often give metaphylactic treatments with these products in the same dose; for example for 2–3 days at regular intervals during the racing season.

In some countries, 5-nitro-imidazoles are also registered as tablets for single administration in pigeons. These tablets are especially useful for the treatment of individual pigeons.

## **Hexamitiasis**

### **Aetiology**

*Hexamita columbae*, which is also called *Spiro-nucleus columbae*, is a host-specific protozoan organism that causes hexamitiasis in pigeons (Levine, 1985b). This parasite has six anterior and two posterior flagellae, and it measures 5–9 µm (Plate 39).

### **Epidemiology**

Clinical signs due to hexamitiasis occur mainly in young pigeons during the spring or summer (Devriese, 1986).

### **Pathogenesis**

Pigeons are infested with *Hexamita columbae* by oral uptake of contaminated droppings, feed or water. The parasite multiplies in the intestinal tract by longitudinal binary fission. This replication results in severe intestinal damage, predominantly in squabs. Bacterial invasion of the lesions may exacerbate the disease in infested birds. Hexamitiasis can occur as a primary disease, but it also constitutes an important complication in adenovirus type I.

### **Clinical signs and lesions**

Replication of *Hexamita* spp. in the intestinal tract results in catarrhal enteritis with small ulcerative lesions in the ileum and rectum. Due to these lesions, pigeons will develop vomiting, diarrhoea, polydypsia, weight loss, dehydration and a poor general condition. The faeces are watery or contain mucus, and have an intense green colour and a bad odour. When left untreated, infested birds may die after 1–2 weeks. In infested nestlings, wasting

is observed. Following an infection, carrier birds may occur among survivors; in these birds the organism can be found in the caecal tonsils. These carriers are a source of infection for other pigeons.

### Diagnosis

Hexamitiasis can be diagnosed *in vivo* by direct microscopic examination of fresh cloacal samples or intestinal contents of very fresh cadavers. The organism can be recognized by its linear movement when seen microscopically, the optimal microscopic magnification being 200–400 $\times$ . This diagnostic tool allows differentiation of hexamitiasis from other agents causing similar clinical disease signs, such as *Salmonella* spp., *E. coli*, adenovirus and paramyxovirus.

### Control

Pigeons suffering from hexamitiasis can be treated successfully with ronidazole (100 mg/l) or metronidazole (1 g/l) over 7 days. Dimetridazole (400 mg/l) is equally effective, but pigeons suffering from polyuria may ingest extremely high amounts of the product, resulting in acute toxicity.

In severe cases, it is advisable to use an antimicrobial simultaneously with the 5-nitroimidazoles to control secondary bacterial invasion of the lesions. Trimethoprim (200 mg/l) or enrofloxacin (100 mg/l) are suited for this purpose.

## Worm infestations

### Aetiology

Pigeons can suffer from nematode, cestode and trematode intestinal infestations (Thienpont *et al.*, 1979). The main pigeon nematodes include *Ascaridia columbae*, *Capillaria obsignata* and *Capillaria caudinflata*. *A. columbae* is approximately 10 cm long, and produces oval eggs with a smooth, thick shell that measure 68–90  $\mu\text{m} \times$  40–50  $\mu\text{m}$ . Capillaria worms, on the other hand, are only 1–2 cm long and less than 1 mm in diameter, and their eggs are lemon-shaped with bipolar plugs (Plate 40). *C. obsignata* eggs measure 50–62  $\mu\text{m} \times$  20–25  $\mu\text{m}$ , and *C. caudinflata*

eggs are 43–60  $\mu\text{m} \times$  20–27  $\mu\text{m}$ . Occasionally, nematode species belonging to the genera *Tetrameres* and *Acuaria* are seen in pigeons.

The main cestodes in pigeons are *Raillietina* spp. and *Hymenolepis* spp. Trematodes usually belong to the genus *Echinostoma* (e.g. *E. paraulum*, *E. recurvatum* and *E. revolutum*).

### Epidemiology

In racing pigeons, the genera *Ascaridia* and *Capillaria* have the highest prevalence, occurring world-wide. This can be explained mainly by the fact that these nematodes do not have intermediate hosts in their life cycles, in contrast to the Tetramerial and Acuerial nematodes (cestodes and trematodes) (Eckert and Bürger, 1992), and because racing pigeons are usually kept indoors they have little contact with intermediate hosts. Furthermore, it must be kept in mind that such parasites only occur under climatic and environmental conditions that allow survival of the intermediate hosts.

Ascaridial and Capillarial infestations occur most frequently in lofts with poor hygienic conditions.

### Pathogenesis

*A. columbae* and *C. obsignata* have direct life cycles without intermediate hosts (Ruff, 1991). For *C. caudinflata* on the other hand, intermediate stages develop in the earthworm. Adult Ascaridial and Capillarial worms live in the intestinal tract of pigeons, and produce eggs that embryonate in the outer world. *C. obsignata* is not host-specific, and also parasitizes chickens, pheasants, quails and guinea-fowl, which may additionally act as a source of infection for pigeons. Depending on humidity and temperature, embryonation of the eggs takes place within 16–20 days for *Ascaridia* and within 3–14 days for *Capillaria* spp. Organic materials promote survival of the eggs. Following the uptake of embryonated eggs, larvae will grow to adult Ascaridial worm in 42–45 days and to adult Capillarial worm in 21–28 days.

*Tetrameres* spp. and *Acuaria* spp. use sow bugs, which predominantly occur in tropical or subtropical areas, for intermediate development (Eckert and Bürger, 1992). Pigeon cestodes have an indirect life cycle, with



earthworms, beetles or snails as intermediate hosts.

The life cycle of pigeon trematodes is complex and includes intermediate stages in two different hosts, such as water snails, mussels and insects. Pigeons are infested with these parasites at pasture or in brooks. Besides pigeons, these trematodes also infest water birds.

### **Clinical signs and lesions**

*Capillaria* spp. adhere to the villi of the intestinal mucosa and feed on epithelium and glandular secretions, causing a catarrhal or fibrinous enteritis and mild anaemia. A poor general condition and weight loss are observed, even when pigeons are infested with few of these parasites. Heavily infested pigeons show diarrhoea, vomiting and emaciation. *Ascaridia* spp. are less pathogenic. In most cases, poor racing performance is the only complaint in the owner's anamnesis. In mass infestations, the worms may migrate to the stomach and the oesophagus. Clinical signs in such pigeons are similar to those seen in capillariosis.

*Tetrameres* spp. and *Acuaria* spp. can be found in the proventriculus. *Tetrameres* are not very pathogenic and only leads to a poor general condition. *Acuaria*, on the other hand, causes severe anaemia and a high mortality rate.

The pathological and clinical significance of cestode infestations is minimal. *Echinostoma* spp. cause haemorrhagic enteritis in squabs.

### **Diagnosis**

Nematode and trematode infestations can be diagnosed by demonstrating parasite eggs in the faeces, preferably by using flotation techniques. Enteritis resulting from worm infestations must be differentiated from adenovirus, salmonellosis and hexamitiasis. Cestode infestations usually are found incidentally during necropsy.

### **Control**

Treatment of pigeons suffering from ascariidiosis or capillariosis is by a single oral dose of levamisole 20 mg/kg, febantel 30 mg/

kg, fenbendazole 15 mg/kg or cambendazole 60 mg/kg (Devriese, 1986; Baert *et al.*, 1993). In heavily infested pigeons, treatment must be repeated after 10 days. Pigeons should be left unfed during levamisole administration, since this product induces vomiting. Benzimidazole anthelmintics should not be used during moulting, since they can induce feather abnormalities. Ivermectin 200 µg/kg is 100 per cent effective against *Capillaria* spp., but it is less active against *Ascaridia* spp. It is the product of first choice against *Tetrameres* spp. and *Acuaria* spp. Occasionally, ivermectin administration leads to shock in pigeons.

Cestodes in pigeons can be controlled by peroral treatment with praziquantel 10 mg/kg and by eliminating contact with the intermediate hosts.

Re-infection of pigeons must be avoided by taking hygienic measures such as thorough cleaning of the loft. Embryonation of the eggs will be arrested in a dry environment without organic materials. Disinfectants are not effective against worm eggs.

## **Coccidiosis**

### **Aetiology**

Two species of *Eimeria* can cause coccidiosis in pigeons; *E. labbeana* and *E. columbarum* (Varghese, 1980). The species can be distinguished by their morphological characteristics; *E. labbeana* measures approximately 16.5 × 15 µm, while *E. columbarum* is somewhat larger at 20 × 18.7 µm.

### **Epidemiology**

In Belgium, more than 80 per cent of pigeons suffering from coccidiosis are infested with *E. labbeana* (Devos *et al.*, 1980) and less than 20 per cent with *E. columbarum*. The pathogenicity of both *Eimeria* spp. is rather low. Approximately 50 per cent of all pigeons are infested. Infection pressure is especially high in lofts with poor standards of hygiene.

### **Pathogenesis**

Pigeons become infested with *E. labbeana* or *E. columbarum* by the uptake of sporulated

oocysts. Sporozoites are released from these oocysts, and infect the epithelial cells of the small intestine. *E. columbarum* predominantly parasitizes the jejunum and ileum, while *E. labbeana* develops in the colon. After a developmental cycle, oocysts are formed and shed in the faeces. The prepatent period is 5–7 days (Van Reeth and Vercruyse, 1992). The prepatent period after a single infection is approximately 30 days. Sporulation of oocysts is promoted by temperature and humidity, and usually occurs within 4 days.

Immunity against coccidiosis is species-specific. This immunity quickly disappears in the absence of re-infection.

### **Clinical signs and lesions**

As in other birds, feather abnormalities can be due to nutritional deficiencies (e.g. of vitamins and amino acids). The administration of benzimidazole products during moulting may lead to various feather anomalies. In the authors' experience, febantel is safe but should never be administered to squabs under the age of 3 weeks. Translucent stripes across the vane of the feathers indicate temporary growth stops, which may be due to severe physical efforts, starvation or generalized disease conditions. 'Stress lines' at regular intervals usually indicate intermittent administration of corticosteroids. These drugs are often misused in pigeons for doping purposes.

In 10–12-day-old nestling pigeons with diarrhoea, high numbers of oocysts are often found in the faeces (Devriese, 1986). It has not been proved, however, that coccidiosis is actually the aetiology of these clinical signs.

### **Diagnosis**

Coccidiosis can be diagnosed by microscopic examination of the faeces. Usually Oocytes per grame (OPGs) are less than 5000, but in winter they may be higher. Pooling of faecal samples may give misleading results, since a single shedder of oocysts may give the impression that the entire group is positive. Before the onset of important races, it may be useful to perform an individual check on the pigeons' faeces to assess the birds' general condition.

### **Control**

To prevent coccidiosis, contact with contaminated faeces must be avoided. This can be achieved by using wire floors. Daily cleaning of the loft is also effective, since oocysts will not have the opportunity to sporulate and will die in the absence of organic materials. Survival of oocysts can be reduced by keeping the environment dry. Disinfection can only be achieved by heat (burning); oocysts are resistant to the common disinfectants.

Treatment of infested pigeons is by a single oral administration of clazuril 2.5 mg (Vercruyse, 1990), or by drinking water medicated with toltrazuril (15 mg per pigeon for 2 days) (Vercruyse, 1990) or sulphonamides (dose depending on the type of sulphonamide, usually administered over 7 days) (Vindevogel and Duchatel, 1979). However, the authors' believe that in most cases it is unnecessary to treat pigeons with coccidiosis.

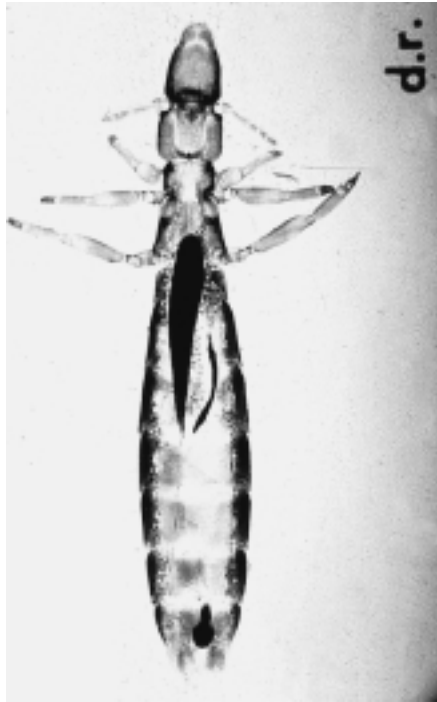## **Ectoparasite infestations**

### **Aetiology**

Many species of ectoparasites may occur in pigeons (Kutzer, 1992). *Columbicola columbae* and *Campanulotes bidentatus* are the most important pigeon lice, parasitizing the feathers of the wings and the tail respectively (Figures 14.3, 14.4). Feather mites include *Megninia columbae* and *Falculifer rostratus*. Mange of the feathers is usually induced by *Neoknemidocoptes laevis* mites, while *Cnemidocoptes mutans* is responsible for leg mange lesions. *Dermanyssus gallinae* and *Ornithonyssus sylviarum* are the main blood-sucking mites in pigeons. The tick *Argas reflexus* is also of major importance, because it feeds on pigeon blood. Hippoboscids flies are flat, and transmit *Haemoproteus* spp. during feeding. These flies remain on the bird, darting in and out of the feathers.

### **Pathogenesis, clinical signs and lesions**

Each of the different pigeon ectoparasites has a typical life cycle, but these are not discussed here.

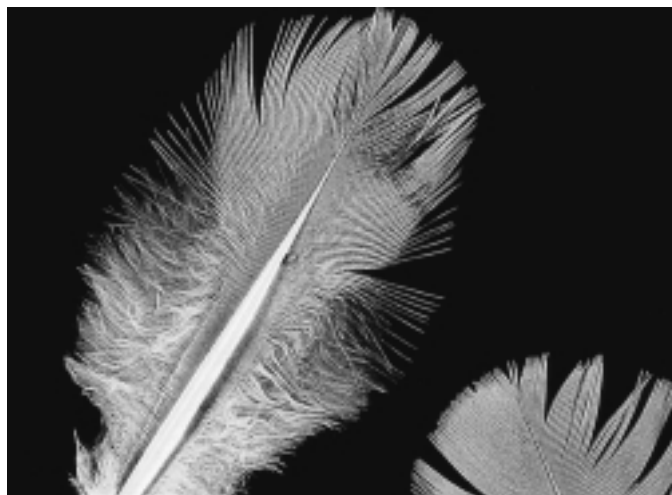


(a)



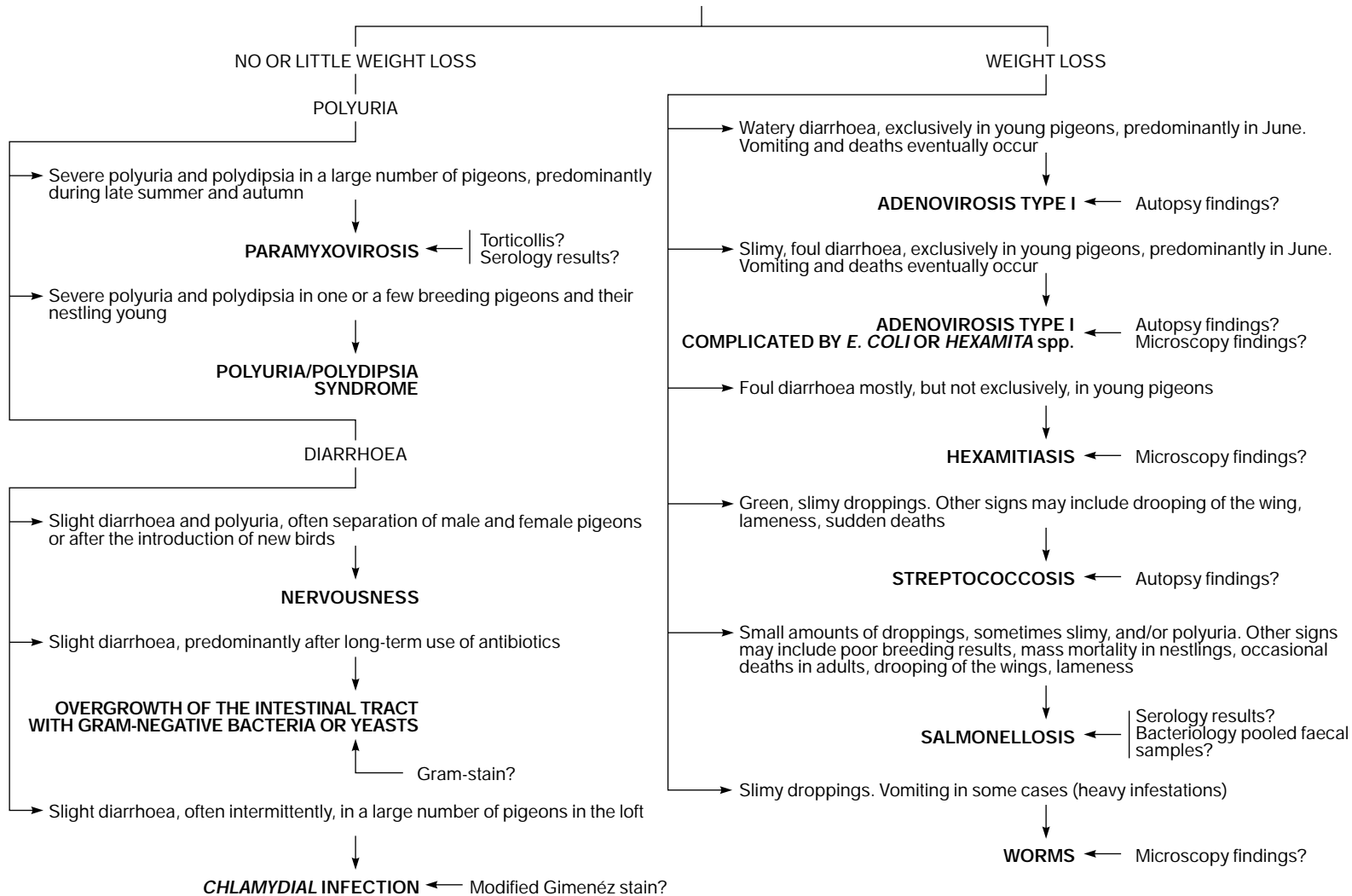
(b)

**Figure 14.3** (a) The pigeon louse (*Columbicola columbae*) and (b) feathers infected with the louse.



**Figure 14.4** *Campanulotes bidentatus*, another common pigeon louse that parasitizes the feathers of the tail.

## ABNORMAL ASPECT OF PIGEON DROPPINGS



**Figure 14.5** Abnormal aspects of pigeon droppings.

*Columbicola columbae*, *Campanulotes bidentatus*, *Megninia columbae* and *Falculifer rostratus* feed on pigeon feather dust. The significance of these parasites is not so much the damage to the feathers, which is minimal, but the restlessness in infested birds.

*Neoknemidokoptes laevis* and *Cnemidocoptes mutans* induce typical mange lesions on the body and legs of pigeons. Clinical signs include broken feathers, scaly skin and legs, and baldness occurring predominantly in the neck region. *Dermanyssus gallinae*, *Ornithonyssus sylviarum* and *Argas reflexus* are temporary pigeon parasites. Most of the time they hide in the environment, and they come out only for a short time (often during the night) for a pigeon-blood meal. This may lead to

restlessness, fatigue, anaemia and even death in nestlings.

**Diagnosis**

Most ectoparasite infestations can be seen on external inspection. To diagnose blood-sucking parasites, it is often necessary to visit the pigeon loft during night and examine the pigeons and their environment. Careful inspection of nest cups and the floor beneath is indicated.

**Control**

Different insecticides can be used to treat pigeons infested with ectoparasites. For the

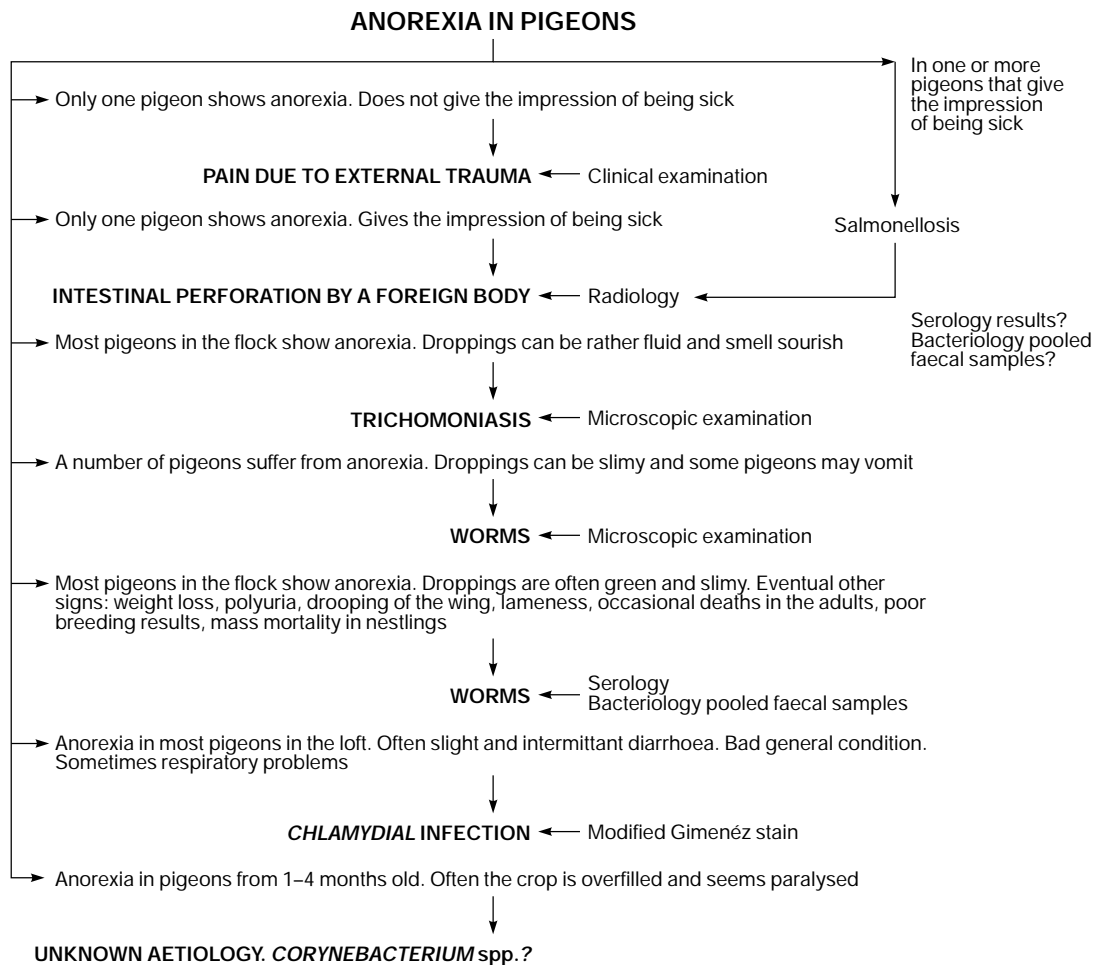
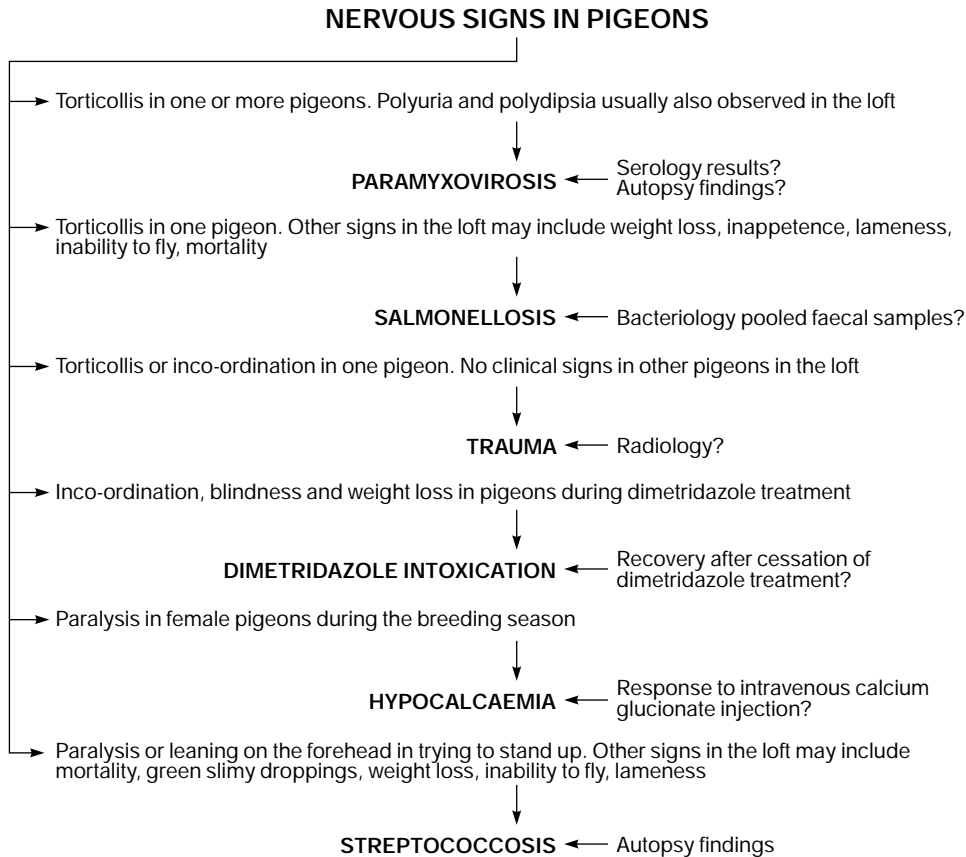


Figure 14.6 Anorexia in pigeons.



**Figure 14.7** CNS signs in pigeons.

control of blood-sucking mites and ticks, it is also necessary to thoroughly clean and disinfect the environment. Long-acting drugs can be very useful in such cases.

## Summary

Figures 14.5–14.8 summarize the paths to diagnosis of disease in pigeons.

## Non-infectious diseases

Besides infectious agents, non-infectious factors may cause polyuria in pigeons. Non-infectious polyuria is often related to stress. Transport is a typical stress factor frequently associated with polyuria. Stress due to the sexual urge is predominantly seen in male pigeons kept separately from females. Polyuria may also occur when squabs are converted

from crop milk to grain feed. At that time, some parent pigeons ingest excessive amounts of water, leading to polyuria in both parents and squabs. Finally, vitamin D<sub>3</sub> overload is an occasional cause of polyuria in pigeons.

Pigeons suffering from polyuria due to stress or breeding usually produce normal droppings during the night. This information may be important for differentiation from infectious polyuria.

Treatment is not generally required; however, minerals should be available *ad libitum* for affected pigeons.

Rupture of air sacs may have an infectious or traumatic aetiology. Infectious causes have been described above. Trauma may be due to bone fractures (e.g. humerus) or puncture lesions resulting from injections. Air that escapes from the ruptured air sac accumulates subcutaneously, especially in the neck region, and this may lead to respiratory distress.

### MORTALITY IN PIGEONS

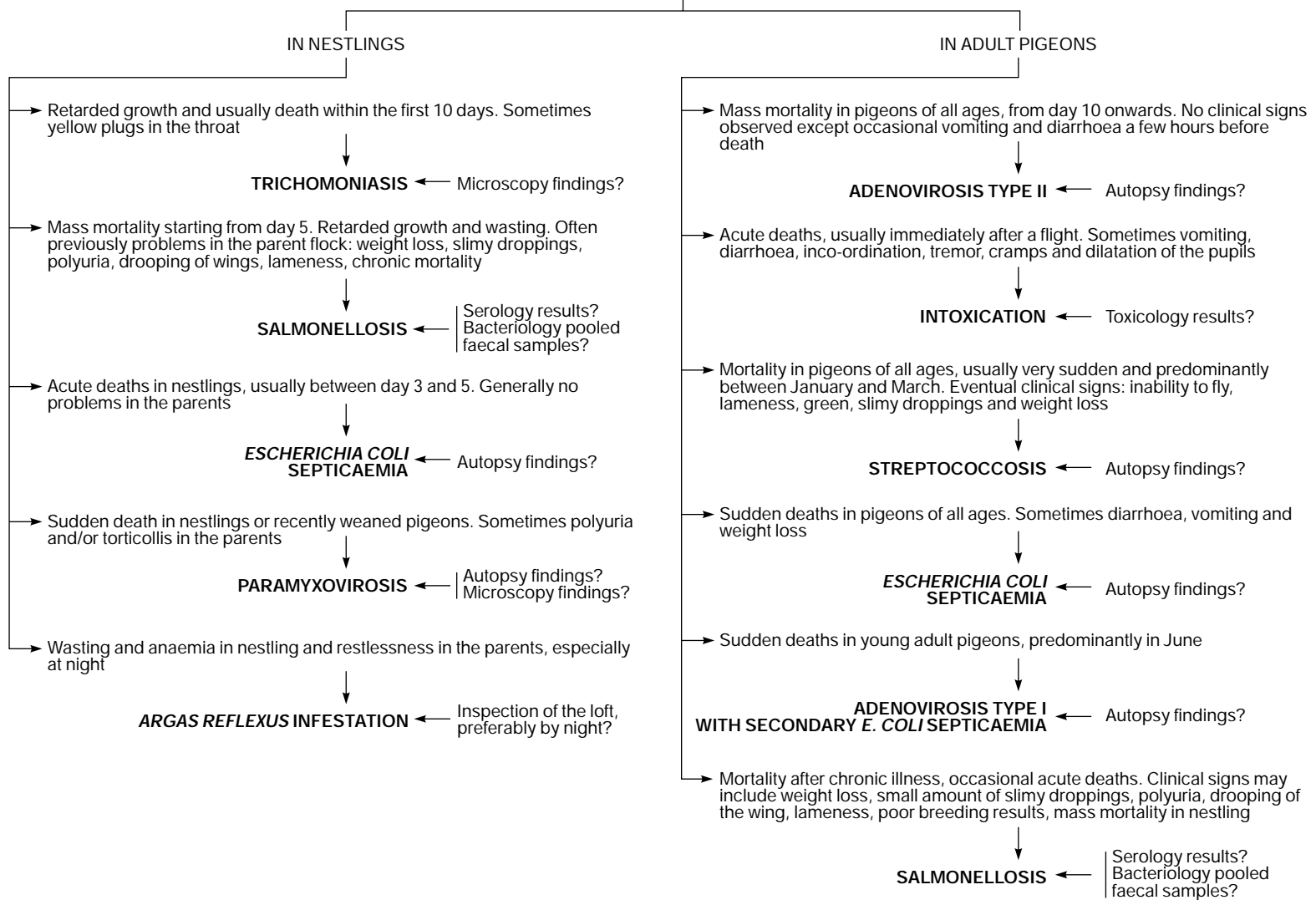


Figure 14.8 Mortality in pigeons.

For treatment, subcutaneous air must be removed by puncturing the affected area with a hollow needle and repeatedly squeezing. Movement of the pigeons must be limited. Infections leading to airsacculitis must be controlled.

Egg binding or dystocia can be suspected if there is distension of the abdomen, anorexia and dyspnoea. The diagnosis can be confirmed with palpation and/or diagnostic imaging. Muscle dysfunction, usually resulting from calcium deficiency, misshapen eggs or anatomical abnormalities, is frequently involved. Eggs should be removed as soon as possible, since prolonged presence of eggs in the oviduct may cause complications to the blood vessels, nerves, kidneys and oviduct. In most cases, the egg can be pushed out by pressure on the abdomen and inoculation of the cloaca with glycerine. Other therapeutic options, depending on the aetiology of the problem, are intramuscular administration of calcium gluconate 1 mg/kg, intravenous injection with 1 iu oxytocin followed by placing the pigeon in a quiet and dark environment, or surgical removal.

As in other birds, feather abnormalities can be due to nutritional deficiencies (e.g. of vitamins and amino acids). The administration of benzimidazole products during moulting may lead to various feather anomalies. In the authors' experience, febantel is safe but should never be administered to squabs under the age of 3 weeks. Translucent stripes across the vane of the feathers indicate temporary growth stops, which may be due to severe physical efforts, starvation or generalized disease conditions. 'Stress lines' at regular intervals usually indicate intermittent administration of corticosteroids. These drugs are often misused in pigeons for doping purposes.

Organophosphates are the predominant drugs causing intoxication in pigeons. Clinical signs include salivation, tremor, tetany, paresis, diarrhoea, mydriasis and death. It is advisable to induce vomiting in intoxicated pigeons, for example through administration of levamisole. Atropine 1 mg/kg can also be administered, subcutaneously. Treatment must be repeated when clinical signs reappear. Dimetridazole given in overdose may cause intoxication in pigeons, with clinical signs of inco-ordination, blindness and weight loss. Pigeons recover completely after cessation of the treatment.

## Acknowledgements

The authors would like to thank Prof. R. Ducatelle for his helpful advice, and C. Puttevilis for the preparation of the figures.

## References

- ALEXANDER, D. J. (1991). Newcastle disease and other paramyxovirus infections. In: *Diseases of Poultry* (B. W. Calnek, ed.), pp. 496–519. Wolfe Publishing Ltd.
- ALEXANDER, D., RUSSEL, P., PARSONS, G. *et al.* (1985). Antigenic and biological characterization of avian paramyxovirus type 1 isolates from pigeons – an international collaborative study. *Avian Pathol.*, **14**, 365–76.
- BAERT, L., VAN POUCKE, S., VERMEERSCH, H. *et al.* (1993). Pharmacokinetics and anthelmintic efficacy of febantel in the racing pigeon. *J. Vet. Pharmacol. Ther.*, **16**, 223–31.
- BURKHART, R. L. and PAGE, L. A. (1971). Chlamydiosis. In: *Infectious and Parasitic Diseases of Wild Birds* (J. W. Davis, ed.), pp. 118–40. Iowa State University Press.
- COUSSEMENT, W., DUCATELLE, R., LEMAHIEU, P. *et al.* (1984). Pathologie van adenovirus infecties bij duiven. *Vlaams Diergeneeskd Tijdschr.*, **53**, 227–83.
- DE HERDT, P., DEVRIESE, L. S., UYTTEBROEK, E. *et al.* (1991). *Streptococcus bovis* infecties bij duiven. *Vlaams Diergeneeskd Tijdschr.*, **60**, 51–4.
- DE HERDT, P., DESMIDT, M., HAESBROUCK, F. *et al.* (1992a). Experimental *Streptococcus bovis* infections in pigeons. *Avian Dis.*, **36**, 916–25.
- DE HERDT, P., HAESBROUCK, F., DEVRIESE, L. A. and DUCATELLE, R. (1992b). Biochemical and antigenic properties of *Streptococcus bovis* isolated from pigeons. *J. Clin. Microbiol.*, **30**, 2432–4.
- DE HERDT, P., DEVRIESE, L. A., DE GROOTE, B. *et al.* (1993). Antibiotic treatment of *Streptococcus bovis* infections in pigeons. *Avian Pathol.*, **22**, 605–15.
- DE HERDT, P., HAESBROUCK, F., DEVRIESE, L. A. and DUCATELLE, R. (1994a). Prevalence of *Streptococcus bovis* in racing pigeons. *Vet. Q.*, **16**, 71–4.
- DE HERDT, P., DUCATELLE, R., HAESBROUCK, F. *et al.* (1994b). An unusual outbreak of *Streptococcus bovis* septicaemia in racing pigeons. *Vet. Rec.*, **134**, 42–3.
- DE HERDT, P., HAESBROUCK, F., DE GROOTE, B. *et al.* (1994c). *Streptococcus bovis* infections in pigeons: virulence of different serotypes. *Vet. Microbiol.*, **41**, 321–32.
- DE HERDT, P., VAN GINNEKEN, C., HAESBROUCK, F. *et al.* (1994d). *Escherichia coli* infections in pigeons: Characteristics of the disease and its etiological agent. In: *Proc. IX Tagung über Vogelkrankheiten, München*, pp. 211–214.
- DE HERDT, P., DUCATELLE, R., LEPOUDRE, C. *et al.* (1995a). An epidemic of fatal hepatic necrosis of viral origin in racing pigeons (*Columba livia*). *Avian Pathol.*, **24**, 475–83.
- DE HERDT, P., HAESBROUCK, F., CHARLIER, G. *et al.* (1995b). Intracellular survival and multiplication of virulent and less virulent strains of *Streptococcus bovis* in pigeon macrophages. *Vet. Microbiol.*, **45**, 157–69.



- DE HERDT, P., HAESBROUCK, F., DEVRIESE, L. A. and DUCATELLE, R. (1995c). Immunity in pigeons against homologous and heterologous serotypes of *Streptococcus bovis* after infection. *Vet. Microbiol.*, **42**, 111-19.
- DE HERDT, P., DEVRIESE, L. A., VEREECKEN, M. *et al.* (1998) Bacteria associated with respiratory disease of racing pigeons. In: *Proc. XI Tagung Über Vogelkrankheiten München*, pp. 83-89.
- DEVOS, A., VIAENE, N., SPANOGHE, L. *et al.* (1980). De gezondheidssituatie bij pluimvee en konijnen in 1979. *Vlaams Diergeneeskd Tijdschr.*, **49**, 414-21.
- DEVRIESE, L. (1986). *Ziekten van Siervogels en Duiven*, 3rd edn. Rijksuniversiteit Gent.
- DEVRIESE, L. A., UYTTEBROEK, E., GEVAERT, D. *et al.* (1990). *Streptococcus bovis* infections in pigeons. *Avian Pathol.*, **19**, 429-34.
- DUCHATTEL, J. and H. VINDEVOGEL (1986). Assessment of vaccination of pigeons against paramyxovirus type 1 infection with inactivated aqueous suspension or oil emulsion vaccines. *Avian Pathol.*, **15**, 455-65.
- ECKERT, J. and BÜRGER, H. J. (1992). Parasitosen des Nutzgeflügels: Helminthen. In: *Veterinärmedizinische Parasitologie* (J. Buch and R. Supperer, eds), pp. 694-732. Paul Parey.
- ELEAZER, T. H., HARREL, J. S. and BLALOCK, H. G. (1983). Transmission studies involving a wet fowl pox isolate. *Avian Dis.*, **18**, 495-506.
- HARTIG, F. and FRESE, K. (1973). Tumorförmige Tauben- und Kanariepocken. *Zbl. Vet. Med.*, **20**, 153-60.
- HESS, M., PRUSAS, C., GELDERBLOM, H. and MONREAL, G. (1996). Characterisation of adenoviruses isolated from pigeons. In: *Proc. Int. Symp. Adenovirus Reovirus Inf. Poultry*, pp. 122-8.
- HOLZ, B. (1992). Virusisolierungen aus Korproben von Kabinenexpressfahrzeugen. In: *Proc. VIII Tagung über Vogelkrankheiten, München*, pp. 1-6.
- KUTZER, E. (1992). Parasitosen des Nutzgeflügels: Arthropoden. In: *Veterinärmedizinische Parasitologie* (J. Buch and R. Supperer, eds), pp. 734-48. Paul Parey.
- LEVINE, N. D. (1985a). Flagellates: the trichomonads. In: *Veterinary Protozoology* (N. D. Norman, ed.), pp. 59-79. Iowa State University Press.
- LEVINE, N. D. (1985b). Flagellates: Spiroplasma, Giardia and other flagellates. In: *Veterinary Protozoology* (N. D. Norman, ed.), pp. 89-108. Iowa State University Press.
- MCFERRAN, J. B., CONNOR, T. J. and MCCracken, R. M. (1976a). Isolation of adenoviruses and retroviruses from avian species other than domestic fowl. *Avian Dis.*, **20**, 519-524.
- MCFERRAN, J. F., MCCracken, R. M., CONNOR, T. J. and EVANS, R. T. (1976b). Isolation of viruses from clinical outbreaks of inclusion body hepatitis. *Avian Pathol.*, **5**, 315-24.
- NASTASI, A., MAMMINA, C. and VILLFRATE, M. R. (1993). Epidemiology of *Salmonella typhimurium*: ribosomal DNA analysis of strains from human and animal sources. *Epidemiol. Infect.*, **110**, 553-65.
- POHL, P., LINTERMANS, P., VANDENDRIESSCHE, A. and BOUTIFLAT, Y. (1983). Epidémiologie de *Salmonella typhimurium* variété Copenhagen. *Ann. Méd. Vét.*, **127**, 279-87.
- RUFF, M. D. (1991). Nematodes and Acantocephalans. In: *Diseases of Poultry* (B. W. Calnek, ed.), pp. 731-78. Wolfe Publishing Ltd.
- SCHACHTER, J. and CALDWELL, H. D. (1980). Chlamydiae. *Ann. Rev. Microbiol.*, **34**, 285-309.
- THIENPONT, D., ROCHETTE, F. and VANPARIIS, O. (1979). *Diagnose van Verminose door Koprologisch Onderzoek*. Janssen Research Foundation.
- TRIPATHY, D. N. (1991). Pox. In: *Diseases of Poultry* (B. W. Calnek, ed.), pp. 583-96. Wolfe Publishing Ltd.
- UYTEBROEK, E. and DUCATELLE, R. (1991). Epidemiology of adenovirus infections in pigeons. In: *Proc. 1st Conf. Eur. Comm. Assoc. Avian Vet., Vienna*, pp. 289-92.
- UYTEBROEK, E., DEVRIESE, L. A., GEVAERT, D. *et al.* (1991). Protective effects of vaccines against experimental salmonellosis in racing pigeons. *Vet. Rec.*, **128**, 152-3.
- VAN REETH, K. and VERCRUYSE, J. (1992). Coccidiose bij de duif. Pathologie, epidemiologie en behandeling. *Vlaams Diergeneeskd Tijdschr.*, **61**, 104-10.
- VANROBAYE, M., DE HERDT, P., HAESBROUCK, F. *et al.* (1996). Secreted antigens as virulence associated markers in *Streptococcus bovis* strains from pigeons. *Vet. Microbiol.*, **53**, 339-48.
- VANROMPAY, D., DUCATELLE, R. and HAESBROUCK, F. (1992). Diagnosis of avian chlamydiosis: specificity of the modified Giménez staining on smears and comparison of the sensitivity of isolation in eggs and three different cell cultures. *J. Vet. Med.*, **39**, 105-12.
- VARGHESE, T. (1980). Coccidian parasites of birds of the avian order Columbiformes with a description of two new species of *Eimeria*. *Parasitology*, **80**, 183-7.
- VERCRUYSE, J. (1990). Efficacy of toltrazuril and calzuril against experimental infections with *Eimeria labbeana* and *E. columbarum* in racing pigeons. *Avian Dis.*, **34**, 73-9.
- VIAENE, N., SPANOGHE, L., DEVRIESE, L. *et al.* (1983). Paramyxovirus bij duiven. *Vlaams Diergeneeskd Tijdschr.*, **52**, 278-86.
- VINDEVOGEL, H. and DUCHATEL, J. P. (1978). Contribution 'a l' étude de l' étiologie du coryza infectieux du pigeon. *Ann. Méd. Vét.*, **122**, 507-13.
- VINDEVOGEL, H. and DUCHATEL, J. P. (1979). Les principales maladies parasitaires du pigeon. *Ann. Méd. Vét.*, **123**, 85-92.
- VINDEVOGEL, H. and PASTORET, P. (1981). Pathogenesis of pigeon herpesvirus infection. *J. Comp. Pathol.*, **91**, 415-26.
- VINDEVOGEL, H., PASTORET, P. P., BURTONBOY, G. *et al.* (1975). Isolement d' un virus herpés dans un élevage de pigeons de chair. *Ann. Rech. Vét.*, **6**, 431-6.
- VINDEVOGEL, H., PASTORET, P. P., LEROY, P. and COIGNOUL, F. (1980). Comparaison de trois souches de virus herpétique isolées de psittacides avec le virus herpes du pigeon. *Avian Pathol.*, **9**, 385-94.
- VINDEVOGEL, H., DAGENAIS, L., LANSIVAL, B. and PASTORET, P. P. (1981). Incidence of rotavirus, adenovirus and herpesvirus infections in pigeons. *Vet. Rec.*, **109**, 285-6.

# Seabirds

---

*Ian Robinson*

'Seabirds' is a general term used to describe birds from a wide range of taxa, all of which share a common environment – the sea. Within this generic group there is a vast diversity of morphology and behaviour, as each species is adapted to its particular range of habitats, from the poles to the tropics, from the open oceans to coastal shallows. However, some adaptations are common to all.

## **Morphological, physiological and behavioural adaptations for survival in the marine environment**

### **Seawater is hypertonic**

Seabirds must be able to maintain their water balance in a permanently hypertonic environment.

#### ***The nasal or salt glands***

Birds have a very limited capacity to produce hyperosmotic urine, and the kidneys alone are incapable of maintaining homeostasis in a marine environment. Many species are able to move between environments in which their intake of water and electrolytes varies greatly. They do this by activating excretion of a hypertonic saline solution containing  $\text{Na}^+$ ,  $\text{Cl}^-$  and  $\text{K}^+$  ions from the nasal glands (Crocker *et al.*, 1974). Paired nasal glands lie dorsal to the orbit. They are usually bilobed, with a lateral and medial lobe each consisting of blind ended secretory tubules emptying into a central canal. Each lobe has a separate duct and ostium, opening into the vestibular region of the nasal cavity, or into the oral cavity in

taxa without nares. The nasal glands are capable of secreting a hypertonic saline of up to 5 per cent concentration. This enables birds to drink seawater (approximately 3 per cent solution) and still maintain homeostasis (King and McLelland, 1984).

When moving from fresh to salt water, the rate of uptake of ingested electrolytes by the intestinal mucosa increases. This triggers secretion from the nasal glands, which continue to function as long as the bird continues to ingest hypertonic drinking water. Any disease or condition that interferes with intestinal absorption will affect the functioning of the nasal glands and the bird's ability to survive in a saltwater environment.

### **Water is a good thermal conductor**

As most seabirds spend prolonged periods floating on or diving beneath the sea, they have plumage that provides an efficient waterproof outer layer over a thick layer of insulating down. Body temperature can be further controlled by the use of circulatory countercurrents in the extremities.

#### ***Waterproofing***

Water repellency is a function of the anatomy of the feathers. The feather vane, consisting of barbs connected by interlocking barbules, creates a lattice structure with air spaces between. The size of these air spaces is such that an impenetrable air-water interface is created and the feather surface repels water. The efficiency of this lattice structure can be expressed mathematically (Rijke, 1968).

The shape of the feathers can also contribute to the efficiency of the waterproof layer as a whole. In particular, the shaft curvature of

the ventral contour feathers helps to maintain the continuity of the waterproof layer, and is most pronounced in aquatic birds (Mahaffy, 1990). Different species vary in how effectively their plumage is waterproofed; cormorants (*Phalacrocoracidae*), for example, have incompletely effective plumage (Rijke, 1968), and will eventually 'wet out' as water penetrates into the air spaces. Birds are then forced to leave the water and can be observed with wings outspread, drying out.

### **Preening**

Preening has two functions:

- 1 To ensure the integrity of the layer of contour feathers – feathers must be correctly aligned with all interlocking barbules in place.
- 2 To spread the secretions of the uropygial (preen) gland onto the feathers.

The uropygial gland secretes an oily substance consisting mainly of fatty acids, and this is spread on the feathers and skin. The water-repellent characteristics of body feathers are often, and incorrectly, attributed to this secretion; feathers are waterproof by their intrinsic structure. However, over time, feathers exposed to environmental insult, abrasion, immersion in water, ultraviolet light, etc. become dry and brittle, and tend to break. Once the structure of interlocking barbules is lost and a stable lattice no longer exists, the feathers lose their natural water repellency. Regular application of oil from the uropygial gland increases the life of the feathers, which remain supple and strong from one moult to the next.

Although physical abrasion or loss of interlocking barbules will cause loss of water repellency until feathers are replaced at the next moult, there are several other circumstances under which a physically intact feather can lose its water repellency:

- 1 Clogging of the barbules (e.g. with oil, dirt, etc.). Contamination may not always be obvious to the naked eye.
- 2 Reduction of the surface tension of water. If contamination with surfactants or small particulate matter cause the surface tension of seawater to drop from the normal 720–750  $\mu\text{N}/\text{cm}$  (72–75  $\text{dyn}/\text{cm}$ ) to

650  $\mu\text{N}/\text{cm}$  (65  $\text{dyn}/\text{cm}$ ) or below, water will penetrate a bird's plumage and it will become waterlogged (Swennen, 1977).

- 3 Contamination of feathers with surfactant. At a microscopic level, water will fail to form droplets and will penetrate the feather lattice structure. Failure to remove all surfactant from feathers is the commonest cause of failure of treated oiled birds to regain waterproofing.

### **Adaptation to extremes of temperature**

Although their dense waterproof plumage insulates against both heat and cold, seabirds that live and nest within the tropics have a limited area of skin available to expose to cooling breezes. The *rete mirabile ophthalmicum* is an adaptation to maximize cooling without having large areas of exposed skin and is well developed in many taxa. A network of anastomosing arterioles arising from the external ophthalmic branch of the internal carotid artery enmeshes within a venous reté receiving cooled blood from the rostral region of the face and pharyngeal wall, where there is heat loss by evaporation. Some of the emerging arterioles anastomose with intracranial arteries and can thus supply the brain with cooled blood (King and McLelland, 1984).

Adaptations for survival in cold climates include a lower body temperature (down to 38.8°C) and a countercurrent tibiotarsal rete in the legs to prevent heat loss from the distal limb.

### **Seabirds spend most of their time swimming on or flying over the sea**

Birds that are adapted to spend much of their lives on the water surface are often ungainly on land. The sea warms slowly and is relatively flat, providing poor thermal uplift for flight, and aerial ocean wanderers therefore have extreme adaptations for soaring flight.

### **Limb placement and shape**

In birds adapted for swimming the pelvic limbs are far caudal on the body, leading to an inability to stand on land or a tendency to an upright posture, bearing weight on the caudal surface of the whole of the lower limb below

the hock. Feet are usually webbed or palmate. Surface diving birds may have reduced pneumatization of bones and absence of some air sacs to make them less buoyant. Some aerial oceanic species have long, high aspect-ratio soaring wings. In both cases birds require space free from obstacles and a water surface on which the feet can be used to gain extra speed to become airborne. Take-off from land may require launching from a cliff or a raised mound.

Some surface diving birds (divers, grebes, anhingas, auks) undergo a synchronized annual moult of flight feathers and a flightless period until new feathers grow. This flightless period may be associated with reduced appetite and increased susceptibility to disease.

## Marine diets usually consist of fish and/or invertebrates

Marine diets are usually soft and high in protein and fat. Seabirds therefore tend to have a relatively simple digestive system.

### Gastrointestinal tract

Beaks may be adapted for catching, holding and swallowing large fish, or for specialized feeding on plankton. The crop is often a simple dilatable portion of the oesophagus, and the gizzard is often vestigial.

## Taxonomic classification

(Table 15.1)

Penguins (*Sphenisciformes*), herons, storks and ibises (*Ciconiiformes*) and shorebirds (various genera from the order *Charadriiformes*) are not considered in this chapter.

### Gaviiformes and Podicipediformes

Divers (*Gaviidae*) and grebes (*Podicipitidae*) are foot-propelled, surface diving, fish-eating birds, with a reputation for extreme shyness. They are rarely seen on land. They nest on the margins of freshwater lakes, and the nest is accessible directly from the water. Birds winter in shallow coastal waters.

**Table 15.1** Taxonomic classification of seabirds

<i>Gaviiformes</i>	<i>Gaviidae</i>	Divers, loons
<i>Podicipediformes</i>	<i>Podicipitidae</i>	Grebes
<i>Procellariiformes</i>	<i>Diomedidae</i>	Albatrosses
	<i>Procellariidae</i>	Petrels, prions, shearwaters
<i>Pelecaniformes</i>	<i>Phaethontidae</i>	Tropic birds
	<i>Pelecanidae</i>	Pelicans
	<i>Sulidae</i>	Gannets, boobies
	<i>Phalacrocoracidae</i>	Cormorants
	<i>Anhingidae</i>	Anhingas
	<i>Fregatidae</i>	Frigate birds
<i>Charadriiformes</i> (selected taxa only)	<i>Stercorariidae</i>	Skuas
	<i>Laridae</i>	Gulls, terns
	<i>Rhynchopidae</i>	Skimmers
	<i>Alcidae</i>	Auks

Their legs are extremely caudal, resulting in difficulty in locomotion on land. The tarsometatarsi are flattened craniocaudally with a teardrop cross-section for maximum hydrodynamic efficiency. Grebes have a lobate foot. When swimming, the tibiotarsus is rotated 90° at the end of the power stroke to reduce resistance to forward motion on the recovery stroke (King and McLelland, 1984).

The feather structure is primitive, with few barbs and barbules and an open structure, and birds must spend a considerable time on the water preening in order to maintain waterproofing. Feather eating is a phenomenon observed in grebes. Adults will ingest their own feathers, and even feed feathers to their chicks. Grebes have also been observed to regurgitate pellets of feather and bone. It has been postulated that this activity may have a function in reducing proventricular parasitic burdens (Piersma and Van Eerden, 1988). This behaviour has not been observed in hospitalized or captive birds. Unusually for fish-eating birds, grebes have a small but distinct gizzard. Gizzard impaction with a mixture of feathers, oil and sand was considered to be a contributory factor in mortality of grebes in the Gulf War oil spill (Greth *et al.*, 1995).

In captivity, whenever these birds are on land they move by resting on their keel and propelling themselves with their back feet, resulting in keel lesions and damage to feather structure over the breast leading to waterproofing problems. Their extreme shyness

makes them difficult patients, prone to stress-associated deaths.

## Procellariiformes

All except the storm petrels (*Hydrobatidae*) have long slender wings adapted to soaring flight. They require considerable space to become airborne, and use wind and wave action to aid uplift. Nest sites are often close to cliffs, which are utilized to become airborne. All are oceanic birds that come ashore only to breed and nest, on cliffs or isolated islands. Shearwaters and smaller petrels (*Procellariidae*) breed in burrows, and often return to the nest site only at night. Legs are placed caudally, and the gait on land is shuffling, utilizing all the caudal aspect of the leg below the hock. The nares are covered dorsally by the operculum, a keratinized flap tubular in structure. The tiny Wilson's storm petrel (*Oceanites oceanicus*) is, surprisingly, one of the world's most numerous birds.

Food consists of fish, invertebrates and plankton. Albatrosses (*Diomedidae*) and large petrels will scavenge and often follow ships. Prions (*Procellariidae*) have hair-like lamellae fringing the bill to aid in straining plankton from the water. Small petrels will flutter close to the surface of the sea, 'walking on the water', whilst feeding.

Fulmars (*Fulmarus glacialis*) are capable of projectile vomiting an oily crop secretion as a defence mechanism. This foul-smelling oil is particularly difficult to remove from plumage, and birds contaminated in the wild frequently die as a result. Captive fulmars often become oiled by their own vomit and require careful washing before release.

## Pelecaniformes

Pelecaniformes are fish-eating birds and may be surface divers, such as cormorants and anhingas (*Anhingidae*), or aerial divers, such as gannets (*Sulidae*) and brown pelicans (*Pelicanus occidentalis*). Frigate birds (*Fregatidae*) are specialized piratical feeders, and harry other birds until they disgorge their stomach contents.

In pelicans (*Pelecanidae*), the entire floor of the mouth is enormously enlarged for catch-

ing fish. The tongue is vestigial in pelicans, cormorants, anhingas and gannets. Cormorants, gannets, anhingas and frigate birds have no nostrils and breathe through the corners of the mouth, which should not be obstructed during handling or restraint. The salt gland duct opens directly into the oral cavity. Gannets and cormorants have cranio-caudally flattened tarsometatarsi with a teardrop profile, and cormorants have webs on all four digits.

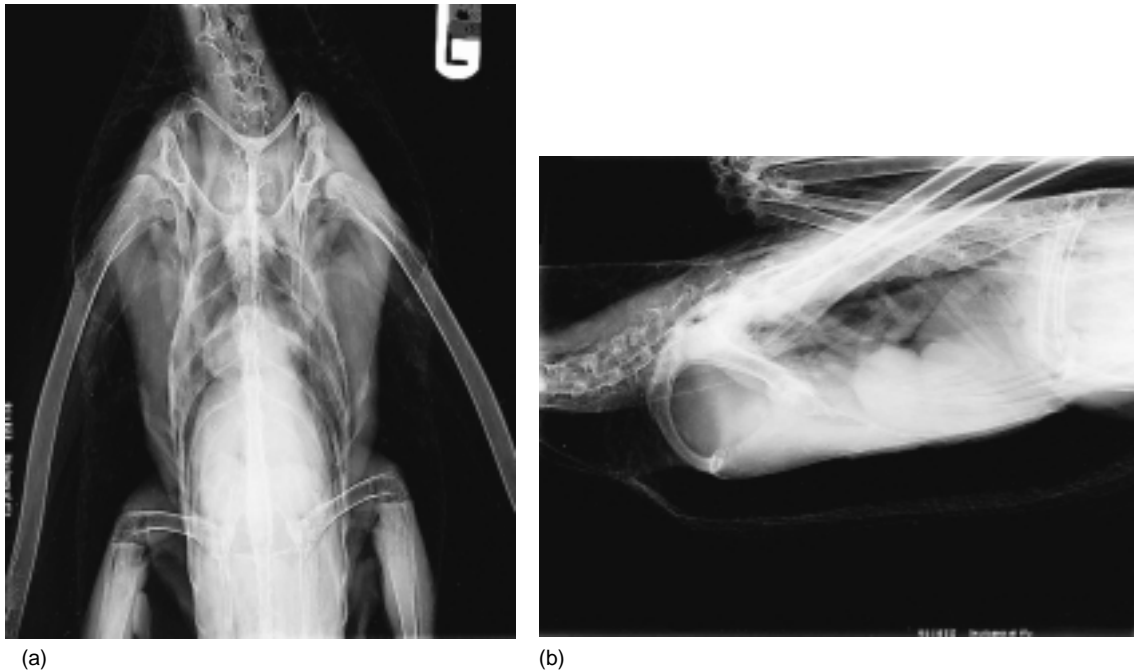The plumage of cormorants and anhingas is imperfectly waterproof, and after a period in the water they must come ashore to dry out – they are often seen in their typical open-winged posture. Frigate birds also have imperfectly water-repellent plumage. As piratical feeders they do not land on the water, and if forced to do so may become waterlogged and unable to take off again.

Gannets and brown pelicans have air sac diverticulae subcutaneously and following the fascial planes between the skeletal muscles over the neck and breast. These are presumed to act as pneumatic shock-absorbers when diving for fish from heights of 35 m or more. These air sac diverticulae can be inflated when stressed, e.g. when handled (Figure 15.1).

## Charadriiformes

Skuas (*Stercorariidae*) are aggressive and piratical, but also eat offal and food scraps. Gulls (*Laridae*) are gregarious and largely coastal. They will often feed on offal, and can be found far inland. Terns (*Sterninae*) are long winged and graceful and are totally aquatic in lifestyle, so they are rarely found far from open water. They are colony breeders and often migrate long distances. The arctic tern (*Sterna paradisaea*) has the longest migration of any bird, breeding in the Arctic and migrating to the Antarctic.

Auks (*Alcidae*) are dumpy, wing-propelled diving birds. Their wings are short and narrow, and they can have some difficulty in becoming airborne, paddling the surface of the water with their feet for some distance to build up sufficient speed for take-off. Their legs are placed caudally, and on land they stand upright with their weight resting on the whole of the caudal surface of the leg below the hock. Special rings (bands) have been developed by



**Figure 15.1** Normal radiographs of a gannet. This bird has inflated its air sac diverticulae, and subcutaneous air can clearly be seen.

researchers for cliff ledge nesters such as guillemots (*Uria aalge*) (known as murre in North America) and razorbills (*Alca torda*). These birds are triangular in section so they present a flat surface to the rock when the bird is standing and thus avoid excessive wear. Puffins (*Fratercula arctica*) are burrow nesters. They have ornate coloured keratinized bill plates, which are shed in sheets at the end of the breeding season. The epithelium of the inside of the mouth of guillemots and razorbills is yellow, and is particularly bright during the breeding season.

## Husbandry

### Environment

Three separate media – land, water and air – must be considered when providing a captive environment for seabirds. The balance between the three media in an enclosure will vary depending on the anatomical and behav-

oural specializations of the species under consideration, and the purpose for which the enclosure is intended (display, rehabilitation, captive breeding, etc.). Auks have been successfully maintained in enclosures with water and air only and no access to land, except for artificial breeding ledges during the breeding season (Swennen, 1977).

### Land

Pool surrounds should be free draining, easy to clean, and have a textured surface to avoid constant pressure on the weight-bearing surfaces of the foot and lower limb.

Concrete surrounds to pools usually become covered with a thin layer of moist guano, and lead to abrasions and pressure necrosis of the feet (and tarsometatarsi and hocks if in contact with the ground). Lesions on webbing and joints progress to pododermatitis (bumble-foot). To avoid this problem, various substrates have been used, e.g. pea gravel, textured rubber or plastic matting (solid or perforated for drainage), clay, cat litter, natural and

artificial turf, and natural and artificial rocks. In general, the floor surface should be free draining and dry quickly, and it should allow the bird to spread its weight over the whole of the weight-bearing surface of the lower limb. If a hard surface is preferred for ease of cleaning, it should be sufficiently textured or uneven to distribute the weight of the bird variably across the weight-bearing surface as it moves, without trapping dirt easily. Perches should be provided for those birds that will use them (cormorants, anhingas and pelicans), and perch surfaces should be chosen for the same characteristics.

Whatever materials are selected for the land surface in a pen or exhibit, it is necessary that adequate cleanliness can be maintained to avoid build-up of excretions, waste food, etc., which may lead to outbreaks of gastrointestinal disease and secondary infection of any skin lesions. Care must be taken that disinfectants used are compatible with any pool water biocide. Disinfectants can be toxic if used at excessive concentrations. The new generation of 'oxygen disinfectants' is generally effective and safe.

### **Water**

Seabirds can be kept on fresh water, but if they are to be released onto the sea they may benefit from the addition of salt to the diet (3 g/kg) to maintain the function of the nasal gland.

Water systems can vary from simple pools with a constant through-flow for waste, to highly sophisticated recycling systems. Clean water is essential for the health and welfare of the birds. Clarity of water is often important in display facilities, especially those with underwater viewing. Water treatment systems may work by one or more of the following methods.

#### *Surface skimming*

Contamination of the water surface can lead to a reduction in the surface tension or direct contamination of feathers, resulting in a loss of waterproofing. Fish-eating birds are especially prone to contamination with oil from food and faeces. Surface skimming, e.g. draining all or some of the water flow through the pool from the surface, either to waste or into a recirculation system, is an efficient method of controlling this problem.

#### *Pressure sand filtration*

Pressure sand filtration removes inorganic particles and some organic matter. Excess organic matter will rapidly cause compaction and channelling of the filter bed, with water streaming through channels between compacted masses of sand, resulting in reduced efficiency and, eventually, the need to replace the filter bed. If used alone, regular replacement of a proportion of the water is required to prevent build-up of organic matter.

#### *Biological filtration*

A biological filter, containing a stable population of autotrophic and heterotrophic microorganisms, will turn nitrogenous waste first into nitrites and then into non-toxic nitrates. In larger units, the filter usually consists of a biotower full of plastic spheres to maximize the active surface area through which some or all of the water will pass on each recirculation.

#### *Biocides*

- 1 *Chlorine*. Free chlorine is an effective biocide at 0.3–3.0 ppm and a pH of not less than 7.6. Free chlorine is usually achieved by the addition of sodium hypochlorite to the water. However, chlorine can combine with organic matter to produce toxic chloramines, especially at lower pH. Chloramines produce skin and eye lesions. Difficulty in monitoring and controlling chloramine levels has led to the abandonment of the use of chlorine in most modern systems.
- 2 *Ozone*. Bubbled through a tower to allow maximum water contact, ozone is an effective oxidative biocide. In salt water (minimum 2.5 per cent NaCl), ozone can also be used for protein skimming (see later). Ozone is toxic at low levels, so its use is limited to the plant room. Residues in the water returning to the pool must be maintained at below 0.1 mg/l. A suitably calibrated redox meter can be used to control any violations automatically. Unlike with chlorine systems, there is no residual biocidal activity in the pool water. This can lead to algal growth on pool surfaces, which may require physical removal or the use of a proprietary algicide.
- 3 *Ultraviolet light*. Ultraviolet light can be an effective biocide in clear water. Scintillation from particles in the water rapidly reduces

the effectiveness of the treatment, so ultraviolet light is generally used after filtration, when water is at its clearest. Ultraviolet light also accelerates the breakdown of ozone, and can be useful in preventing free ozone returning to the pools. Its use is obviously restricted to the plant room.

### *Algicides*

A variety of commercial algicides are available, including those based on copper and bromine.

### *Protein skimming*

First used in saltwater fish farming, protein skimming is now utilized successfully in water systems for marine mammals and birds. Ozone and air are injected into a column of water through a venturi. This ensures good mixing and agitation. Long-chain fat and protein molecules are oxidized and broken down into smaller molecules, which are surfactant and form a stable foam on the surface. This can then be skimmed to waste. If the biological load on the system is very high it is possible that some surfactant may remain on the water surface, resulting in lowered surface tension and wetting of plumage. However, this does not appear to be a problem in well-designed systems.

### *Air*

Larger species that are mobile on land and water may be rendered permanently flightless by pinioning, e.g. cormorants, pelicans.

Surface diving birds such as auks have difficulty in becoming airborne and need to paddle along the surface of the water with their feet. They are relatively unmanoeuvrable in flight, and are therefore in danger of crashing into enclosure netting. Pinioning is inadvisable, as they use their wings to propel themselves whilst diving. The design of the enclosure must take this into account, although reports of injury are rare despite repeated collisions with enclosure netting (Swennen, 1977). Enclosures sited in exposed locations may be subject to high winds, which can blow birds against the netting.

In extremes of ambient temperature, it may be necessary to provide an artificially heated or cooled environment. When conditioned air is recirculated, it should be filtered through a

fine particulate filter capable of removing fungal spores.

## **Breeding**

Recent editions of *The International Zoo Yearbook* list only a few seabirds as breeding successes, including:

- *Pelecaniformes* – pelicans, gannets and cormorants
- *Charadriiformes* – gulls, terns, guillemots and puffins.

Although this is not a complete list of all successful breeding, it does indicate that only limited taxa are commonly bred in captivity.

Colony breeders, such as cormorants, may be stimulated to courtship and nesting behaviour by the presence of other birds, and may require a minimum colony size of a dozen or more pairs. A sufficient area for suitable nesting sites must be available, bearing in mind the territorial behaviour of the species concerned.

Guillemots and razorbills will breed on artificial ledges. The height above the water level of these ledges is not critical (Swennen, 1977). Puffins can be provided with artificial burrows.

## **Handling**

Seabirds present no special problems in handling, although some have sharp and pointed beaks and require careful restraint. Cleanliness of operators and equipment is important to ensure that plumage is not contaminated during handling, and care must be taken not to damage or excessively disrupt the feathers. Birds usually require a period of preening following handling to ensure their feathers are correctly aligned for waterproofing.

Soft-rimmed aviary nets are useful for catching birds. Care must be taken to avoid personal injury from sharp pointed beaks, and safety glasses or goggles are recommended. Keeping the bird's head covered with a towel is usually adequate. Light gloves can be used for protection if preferred.

Beaks may be controlled with tape or a rubber band during more prolonged handling, e.g. washing. In species with no nares the



beak must not be taped closed, and a small gag – a matchstick or syringe plunger is adequate – should be taped across the beak to ensure that breathing is not restricted.

## Feeding

The majority of seabirds are fed on fresh or frozen fish. The wet weight required for daily maintenance is variable, as fish can vary greatly in energy density through the season. Most seabirds can be safely fed to appetite, but some (e.g. gulls and skuas) may become obese. Regular monitoring of body weight and adjustment of the feeding level is preferable. The total daily requirement may be up to 30 per cent of the body weight.

### *Vitamin supplementation*

It is usual to supplement diets for captive seabirds with both mixed B vitamins and oil-soluble vitamins A, D and E. However, alcids have been kept in captivity for years on a diet of frozen fish without any supplementation (Swennen, 1977).

There is a danger of thiaminase-induced thiamine deficiency with stored frozen fish. For adequate maintenance of thiamine levels in the presence of dietary thiaminase, oral supplements should be given about an hour before feeding. A better alternative is supplementation by parenteral administration.

## Nursing

### Hospitalization

Hospitalized birds may be kept individually or in groups in cages or pens. In social birds, the behavioural advantage of group housing must be balanced against the necessity for isolation for disease control and clinical monitoring. Usually sick, injured or oiled birds will not be allowed access to water, to avoid the danger of waterlogging and hypothermia. Damage to the feet and legs, keel and feathers can easily occur. Abrasion and faecal soiling must be kept to a minimum. Birds unable to stand, such as divers and grebes, can be kept on soft nylon netting stretched across a frame

inserted into cages or pens to form a false floor. This allows droppings to fall through, reducing soiling, and lessens abrasion on the limbs, keel and feathers. Soft bedding such as rubber mats, deep layers of newspaper, old towels or blankets or even woodshavings can be utilized, but will need frequent changing.

The copious quantities of highly nitrogenous droppings produced by fish-eating birds can rapidly lead to unacceptable atmospheric conditions within the hospital area and the danger of respiratory disease, especially aspergillosis. A ventilation rate of 12 or more air changes per hour is required to prevent the build-up of ammonia in the atmosphere. Such high ventilation rates may necessitate air conditioning to maintain an adequate room temperature.

When birds are kept off water for several days, legs and webbed feet may become dry and brittle. Regular application of petroleum jelly will prevent this, but care must be taken because contaminated plumage will become non-waterproof and require washing before the bird returns to the water.

*Alcidae* will climb on rocks placed in a cage or pen, with a beneficial effect on foot condition. Cormorants will perch on anything, even an upturned bucket, which will keep feet and plumage clear of a soiled floor.

## Nutrition

### *Fluid therapy*

The detection and treatment of dehydration follow the general principles of avian medicine, although close feathering and thick down can make detection of dehydration more difficult. As a rule of thumb, if dehydration is detectable, the bird is more than 5 per cent dehydrated. More than 15 per cent dehydration is incompatible with life; therefore it is fair to assume a 10 per cent dehydration level. Fluid deficits should be rectified by administration of 10 per cent of bodyweight (BW) daily in divided doses. This can be considered as 5 per cent BW maintenance + 5 per cent BW (e.g. half the deficit). This dose can be repeated in each 24 h period until there are no signs of dehydration.

Fluids can be administered i.v., s.c., i.o. or p.o. in divided doses. The i.v. route can be

**Table 15.2** Feeding sick birds*Days 1 and 2*

Oral rehydration fluid, either as part of rehydration therapy, or as a bland base from which to start any change of diet.

After 24 hours substitute the following mixture given by gavage at 10% body weight/day in two to four feeds:

- 50 ml Lectade Plus (SmithKline Beecham) – Oral rehydration fluid
- Two tins A/D Diet (Hills Pet Nutrition) – a canine/feline convalescent diet
- 10 ml Ensure Plus (Abbot Laboratories) – a human liquid nutrition product
- $\frac{1}{2}$  Aquavit (International Zoological Veterinary Group) – Vitamin supplement high in B1 and E
- 1 × 200 mg ferrous sulphate tablet.

*Days 3 and 4*

Offer whole fish of a suitable size from Day 3. Birds normally select fish by girth rather than length, and prefer fish smaller than the maximum size they can swallow. Use fish of high calorific value.

*Day 5 onwards*

If the bird does not start to self-feed, start force feeding fish from Day 5, in addition to gavage, and continue until self-feeding starts. Up to 30% body weight can be given in up to four feeds daily. However, unless there is weight loss keep force feeding to a minimum to avoid suppressing appetite and delaying the onset of self-feeding. It is rare to force feed more than 20% body weight in two feeds.

*Throughout treatment*

Weigh bird daily and continue gavage until there is a consistent weight gain over several days, and preferably until the bird has achieved the acceptable minimum weight (amw) for the species, if known. However, amw can vary with sex, age, time of year, race or subspecies, etc. and may be difficult to determine

used through any accessible vein. If a slow infusion is impossible due to difficulties of restraint or the small size of available veins, an initial bolus of fluid may be given by slow intravenous injection over 1–2 minutes and the rest by an alternative route.

The intraosseous (i.o.) route is possible where i.v. infusion is impracticable (Otto *et al.*, 1989). Power- or pressure-driven syringes (e.g. Flowline, Pacific Medical Supplies Pty Ltd, Vic., Australia) are ideal for this method of administration.

Birds should be offered food within 24 hours (Table 15.2), and many will start to eat. If clinical evidence of dehydration persists, administration of fluids should be continued despite self-feeding. Emaciated birds, or birds that fail to self-feed, may be started on a high-energy supplement. Oiled birds may require fluids routinely for 4–8 days despite self-feeding.

**Starvation/emaciation**

Birds received in rescue centres are frequently emaciated. Clinical investigation is always indicated; however, such birds are rarely suffering from chronic wasting diseases. Emaciated birds may be individual cases or part of a larger incident. There are many reasons why seabirds may suffer from starvation/emaciation, including the following:

- 1 Immaturity – immature birds may be naive hunters and fail to meet their nutritional requirements. Parasitism and population pressures may be additional stressors.
- 2 Inclement weather – this may result in reduced feeding opportunities.
- 3 Failure of local fish stocks – due to commercial over-fishing or climatic variations.
- 4 Long migration.
- 5 Oiling.

Emaciated birds that have been starving for some time require careful nursing. Over-feeding can result in collapse and death, the physiological demands of a full proventriculus apparently precipitating circulatory failure.

**Feeding**

Often fish tossed into a tray of shallow water will attract attention and trigger feeding behaviour. The tray should be dark in colour so the silver fish stand out against it. Communal species may be stimulated to eat in the presence of other birds.

Scavengers such as gulls can be treated in a similar way, but offered chopped fish or day-old chicks, or dog or cat food. It may be difficult to persuade plankton eaters to self-feed. However, live brine shrimp or artificial diets for plankton-eating fish available through the aquarium trade are worth trying. Some may eat chopped fish or shrimp.

**'Die-offs' or 'Wrecks'**

These are terms used to describe mass mortality in wild birds. Often the first sign of a large scale mortality in seabirds will be the discovery of large numbers of sick, dying and dead birds, either at a breeding site or washed up along the shore.

**Trauma**

Traumatic injuries can be treated according to the basic principles of avian medicine, and present no special problems. Commonly encountered problems in wild seabirds include:

- entanglement in or ingestion of fishing tackle (hooks, monofilament line and nets) or general marine debris such as cargo nets and six-pack plastic rings
- gunshot wounds
- attack by predators, birds, mammals or fish
- laceration by boat propellers, collision with speedboats, jet skis, etc.

Commonly encountered problems in captive birds include:

- pododermatitis and sternal ulceration
- ingestion of foreign bodies
- heatstroke in polar birds kept in warm climates
- frostbite in tropical birds kept in cold climates.

These can all be prevented by provision of a suitable captive environment.

Care must be taken when treating body wounds not to remove excessive numbers of feathers and not to contaminate the plumage if the bird is to be returned quickly to water. For example, keel ulceration can be treated by debridement and removal of necrotic tissue followed by closure of the wound with absorbable sutures, tissue glue or a combination of the two. A non-detergent skin disinfectant is used for skin preparation and a minimum number of feathers plucked from the wound edges, so that after wound closure the breast feathers, once realigned, will completely cover the wound. The bird can then be rapidly reintroduced to water to prevent recurrence of the condition.

Dressings for webbed feet are best applied with the digits extended, to prevent loss of elasticity of the web and flexibility of the foot. A template of stiff cardboard or light plastic is cut in the shape of the extended foot. The required dressing is sandwiched between the plantar surface of the foot and the template, and with the foot extended a lightly adhesive tape is applied around the dorsal surface of the foot and the template. A protective dressing can then be applied.

Soaring birds with legs far caudal, such as fulmars, may be unable to take off from flat ground, and if they accidentally land they can become stranded. If in good condition, such birds can simply be moved to a suitable elevated location from which they can re-launch themselves. Recently fledged juvenile birds are frequently found many miles inland after severe onshore storms. They are often undamaged but dehydrated and/or starving, and require first aid and feeding before release at a suitable coastal site. Newly-fledged petrels and shearwaters leave their nest burrows at dusk and head towards the open sea, which they recognize by its lighter horizon compared to land. Artificial light can confuse them and cause them to fly inshore. If stranded on shore or close to the coast during daylight, they will easily fall prey to predators such as gulls and skuas. Such birds can be collected, confined in safety over the day, and released at dusk in a suitable location away from artificial lights.

**Metabolic diseases*****Visceral gout***

At post-mortem examination, chalky white urate deposits are found on all visceral surfaces and in renal tubules. Visceral gout is usually considered to be secondary to dehydration.

**Infectious diseases****Bacterial**

Bacteria, especially Enterobacteriaceae, are a major cause of death in captive collections (Kaneene *et al.*, 1985). In contrast, wild birds

**Table 15.3** Some isolates associated with clinical signs and/or pathology

Bacterial isolate	Clinical signs	Pathology	Taxa affected, comments	Source
<i>E. coli</i>	Diarrhoea, dehydration, soiling of vent. Respiratory distress, sudden death	Enteritis, peritonitis, pericarditis, air sacculitis, granulomatous and necrotic pneumonia	Various, including <i>alcidae</i> , <i>laridae</i> , <i>phalacrocoridae</i>	Author
(With <i>E. tarda</i> and <i>S. aureus</i> )	Dehydration, drooping wings, rapid death	Septicaemia, swollen liver, necrotic enteritis	Shags (secondary to oiling)	Wood <i>et al.</i> , 1993
<i>Klebsiella pneumoniae</i> (with <i>Y. enterocolitica</i> )	Seabird wreck	Diffuse lymphoid infiltration of lungs	Kittiwakes and guillemots	Louzis <i>et al.</i> , 1984
<i>Salmonella</i> spp. (with <i>Clostridia</i> spp. and <i>Pseudomonas</i> spp.)	Emaciation, dehydration, severe diarrhoea	Haemorrhagic gastroenteritis, peritonitis	Brown pelicans (associated with sewage contamination)	Ankerberg, 1984
<i>Clostridium perfringens</i> , <i>C. ramosum</i> , <i>C. limosum</i> , <i>C. histolytica</i> , <i>C. subterminale</i> , <i>C. hastiforme</i> (with <i>Pseudomonas</i> spp. and <i>Salmonella</i> spp.)	Dehydration, emaciation, severe diarrhoea	Haemorrhagic gastroenteritis, peritonitis with petechiae	Brown pelicans (associated with sewage contamination)	Ankerberg, 1984
<i>Clostridium perfringens</i>	Not known	Severe haemorrhagic necrotizing enteritis	<i>Alcidae</i>	Petermann <i>et al.</i> , 1989
<i>Yersinia enterocolitica</i> (with <i>K. pneumoniae</i> )	Seabird wreck	Diffuse lymphoid infiltration of lungs	Kittiwakes and guillemots (in a die-off)	Louzis <i>et al.</i> , 1984
<i>Streptococcus zooepidemicus</i>	Die-off, sudden death	Enlarged buff-coloured liver, congested and oedematous lungs	Grebes	Jensen, 1979
<i>Erysipelothrix rhusiopathiae</i>	Die-off, sudden death	Enlarged friable liver, petechial haemorrhage in pericardial and subcutaneous fat	Mainly grebes, some gulls and ducks	Jensen and Cotter, 1976
<i>Edwardsiella tarda</i> (with <i>E. coli</i> and <i>S. aureus</i> )	Dehydration, drooping wings, sudden death	From liver and spleen	Shag ( <i>E. coli</i> also present)	Wood <i>et al.</i> , 1993
<i>Edwardsiella tarda</i>	Weak, unable to fly, rapid death	Necrotic enteritis but no histological evidence of systemic bacterial invasion	Brown pelicans, common loons and ring-billed gulls	White <i>et al.</i> , 1973
<i>Pseudomonas</i> spp.	Dehydration, collapse, sudden death	air sacculitis, septicaemia	Oiled guillemots and razorbills	Author
	Emaciation, inappetence	Multifocal granulomatous hepatitis	Red-throated diver, <i>Gavia stellata</i>	Author
<i>P. putrefaciens</i> , <i>P. fluorescens</i>	Emaciation, dehydration, severe diarrhoea	Haemorrhagic gastroenteritis, peritonitis	Brown pelicans, associated with sewage contamination	Ankerberg, 1984
<i>Nocardia asteroides</i>		Adherent plaques in air sacs, fibrinous exudate with branching filamentous bacteria	Laysan albatross ( <i>Diomedea immutabilis</i> )	Sileo <i>et al.</i> , 1990
<i>Staphylococcus aureus</i> (CPHS) with <i>E. coli</i> and <i>E. tarda</i>	Dehydration, drooping wings, rapid death	Septicaemia, swollen liver, necrotic enteritis	Shags (secondary to oiling)	Wood <i>et al.</i> , 1993.

rarely die of primary bacterial disease. Carcasses recovered during die-offs or mortality surveys are frequently autolysed, and it can be difficult to determine the significance of isolates. Some isolates associated with clinical signs and/or pathology are shown in Table 15.3.

Therapy is best matched to *in vitro* sensitivity testing when possible, but in the absence of such specific guidelines, the clinician may choose any of the broad-spectrum antibiotics commonly used in birds, bearing in mind the common potential pathogens in seabirds.

### Viral

#### Newcastle disease (*paramyxovirus type 1*)

A neurotropic velogenic, Newcastle disease virus (NDV) has caused excessive mortality in breeding flocks of double-crested cormorants (*Phalacrocorax auritus*) (Banerjee *et al.*, 1994). Clinical signs included weakness, lethargy, diarrhoea, respiratory distress, paralysis of wings and legs, torticollis and inco-ordination. On gross postmortem examination, the most consistent lesions were oedema of the eyelids and periocular tissues, pulmonary oedema and congestion, splenomegaly, hepatic necrosis and scattered haemorrhages in visceral organs. Histological lesions included severe lymphocytic meningoencephalitis and myelitis, and splenic lymphoid necrosis with haemorrhage.

Paramyxovirus type 1 of unknown clinical significance has also been isolated from guillemots, tufted puffins and European cormorants (Stoskopf and Kennedy-Stoskopf, 1986; Petermann *et al.*, 1989). A single gannet (*Sula bassana*) died of nephritis apparently associated with Newcastle disease (Wilson, 1950).

#### Tick-borne viruses

A large number of viruses have been isolated from seabird ticks, and in some cases have been shown to infect their host (Holmes, 1995). Occasionally such viruses have been implicated in clinical disease. For example, Soldado virus, an arbovirus isolated from the tick *Ornithodoros capensis*, was implicated in the die-off of thousands of sooty terns (*Sterna fuscata nubilosa*) on Bird Island in the Seychelles (Converse *et al.*, 1975).

However, many isolations are from ticks only, either from dead birds, or from ticks recovered at nest sites.

### Puffinosis

Manx shearwaters (*Puffinus puffinus*) breeding on the islands of Skokholm and Skomer off Southwest Wales annually suffer significant mortality amongst fledglings. Large vesicles develop on the webs of the feet, and rapidly rupture. There may be unilateral or bilateral paresis, particularly a spastic paralysis of the legs. Some birds develop a purulent conjunctivitis. There are no pathognomonic lesions on gross postmortem. Histology of the developing vesicles reveals enlarged nucleoli and vacuolation of the cytoplasm.

Morbidity is highest in late fledging chicks, and may be up to 25 per cent. Mortality may average 4 per cent of total fledglings annually, and does not appear to affect the total population (Brooke, 1990).

It is believed that the disease is caused by an uncharacterized virus and spread by the trombiculid mite (*Neotrombicula autumnalis*), which infests breeding burrows. Use of doxycycline has been found to reduce mortality in affected chicks (Brooke, 1990).

Other taxa have shown similar foot lesions, including oystercatchers (*Haematopus ostralegus*), various gulls and shags (*Phalacrocorax aristotelis*). Foot lesions combined with conjunctivitis have been seen in fulmars, but with no associated mortality. Significant mortality has occurred in some penguin species (Stoskopf and Kennedy-Stoskopf, 1986).

### Avipox

Cutaneous lesions caused by avipox viruses have been described in guillemots (Hill and Bogue, 1978), white-tailed tropic birds (*Phaethon lepturus*) (Wingate *et al.*, 1980) and royal terns (*Sterna maxima*) (Jacobson *et al.*, 1980). Lesions are typically dry, crusty, raised papules, usually occurring on unfeathered skin. Although persistent in the environment, particularly in dried scabs, the virus cannot penetrate intact epithelium. Aggressive pecking during territorial disputes at the nest site can cause small traumatic skin lesions that become infected with virus, which can persist from year to year or be shed in faeces, skin or

feather quills from birds with latent infection. Biting insects, particularly mosquitos, are also a possible mode of transmission.

The diphtheroid form of pox, which produces caseous lesions in the oral cavity, has been recorded in a guillemot (*Uria aalge*) (Hill and Bogue, 1978). Cutaneous lesions were also present. The large amount of necrotic exudate in the nasal and oral cavities caused inanition and death by asphyxiation.

### **Adenovirus**

Adenovirus-like particles have been identified in kidney from an oiled guillemot. The infection was thought to have been latent and activated by stress, and not a significant cause of disease (Fry and Lowenstine, 1985).

### **Avian influenza**

More than 1300 migratory common terns (*Sterna hirundo*) died in an explosive epizootic of avian influenza in South Africa (Becker, 1966). Death was peracute, and of 16 carcasses examined histologically lesions were only found in three, all of which showed a meningoencephalitis.

### **Herpesvirus**

Small eosinophilic inclusions of Cowdry type A, typical of herpesvirus infection, were found in the liver of oiled birds during the Arabian Gulf oil spill. The damage caused to hepatocytes was assumed to have been present before the ingestion of oil, and may have increased the susceptibility to toxic damage (Greth *et al.*, 1995).

## **Fungal**

Seabirds are a particularly high-risk group for aspergillosis. Housed birds are very prone to infection, especially if ventilation and/or hygiene are sub-optimal. Oiled seabirds frequently develop acute aspergillosis during rehabilitation as a complication of rescue and hospitalization.

Clinical signs of acute disease include inappetence, respiratory distress and open mouth breathing, and sudden death.

Gross postmortem signs are varied, depending on the stage and severity of disease. Early cases show small irregular dark foci with a dry appearance in lung tissue. On histology, septate branching fungal hyphae can be seen. These lesions have been noted in rescued guillemots within 8 days of housing. Later, 12–14 days after housing, classic yellow focal lesions develop on air sac surfaces and fluffy white fungal hyphae may be seen.

Treatment is rarely effective once clinical signs are established, but prophylactic treatment with itraconazole has been effective in preventing further losses among birds at risk. Pre-emptive treatment may be worthwhile, and itraconazole 10 mg/kg p.o. b.i.d. for up to 1 week, followed by 10 mg/kg p.o. s.i.d. for up to 3 weeks, is recommended for divers (Redig, 1996). Itraconazole is widely available as capsules containing sustained-release granules. It has been suggested that dividing the number of granules in a capsule to obtain the required dose is unreliable and may lead to toxicity due to the uneven concentration of drug in each granule (Forbes, 1992), but the author has experienced no problems.

*Aspergillus fumigatus* is the most common isolate. More rarely, *A. flavus* may be isolated. *Mucor* spp. has been isolated from puffins, *Geotrichum candidum* from a pelican (Stoskopf and Kennedy-Stoskopf, 1986) and blastomycosis from a guillemot (Stoskopf, 1993).

## **Parasites**

### **Ectoparasites**

A large number of hard and soft ticks have been associated with seabirds and their nesting sites world-wide. Although associated with transmission of bacteria and viruses, they are rarely themselves a cause of clinical disease.

*Ixodes uriae* is a common ectoparasite of seabirds. It infests a wide range of hosts, although the guillemot is considered the preferred host in the northern hemisphere (Barton *et al.*, 1995). It has a far-reaching distribution in the temperate regions of both hemispheres. The life cycle of the tick takes 2–4 years to complete (Steele *et al.*, 1990), depending on seasonal constraints and the length of the nesting season and fledging times for available hosts. Duration of attachment and

engagement of each individual tick is up to 6 days (Barton *et al.*, 1995). Off the host, the tick may be found in soil around nests and nesting burrows, and in cracks and crevices of the cliff face of breeding ledges, rather than in nests (Steele *et al.*, 1990).

Spirochaetes of the genus *Borrellia* (*B. burgdorferi* and *B. garinii*), responsible for Lyme disease in man, have been demonstrated in *Ixodes uriae* ticks (Olsen *et al.*, 1993, 1995). It has been suggested that seabirds could play an important role in the spread of borreliosis around the globe. There have been no reports of clinical signs associated with *Borrellia* spp. infection in seabirds.

Death of Laysan albatross chicks (*Diomedea immutabilis*) has been associated with infestation with 'chiggers' (*Womersia midwayensis*). Oedema and focal haemorrhage and necrosis were associated with the ectoparasites. There was secondary bacterial cellulitis and anaemia (Sileo *et al.*, 1990).

Both lice and feather mites infest seabirds. Louse species of 16 genera have been described in Procellariiformes alone (Palma, 1994). Feather mites tend to favour the distal barb in the trailing vane of the ventral surface of the flight feathers, where they are least likely to be dislodged by airflow or preening activity (Choe and Kim, 1991).

Ectoparasite infestations rarely require treatment. However, if treating with an acaricide, care must be taken to choose product that will not affect waterproofing (see earlier). Excessive application of powders or oily sprays can clog feather barbules. Ivermectin injection (Ivomec, MSD Agvet) diluted 1 : 10 in propylene glycol and a few drops applied topically is usually effective and safe.

## Endoparasites

Seabirds can be infested with a wide range of endoparasites. Cestodes, trematodes, nematodes and protozoa have been recorded. Some are host-specific, others infect a range of hosts. These parasites are rarely a cause of primary disease. However, young birds, which are most frequently heavily parasitized and in poor body condition, may succumb more easily to the effect of other stressors, such as oiling, disease challenge, severe weather or food shortage. Nematodes of the genus *Con-*

*tracaecum*, found in the proventriculus, are perhaps the most common parasites. In such birds it is best to treat symptomatically, paying particular attention to correction of dehydration and the instigation of nutritional therapy and ensuring the bird is stable before using anthelmintics.

Gapeworm (*Syngamus tracheae*) has been the cause of respiratory distress in gulls feeding on agricultural land where they have access to the earthworm intermediate host. Diagnosis is made by the presence of blood-red nematodes in the trachea and large bipolar nematode ova in faeces. Treatment with bendimidazole anthelmintics at standard avian doses is effective.

Renal coccidiosis occurs in several taxa, most notably in the colonies of short-tailed shearwaters (*Puffinus tenuirostris*) in Tasmania. Young birds are emaciated, with diarrhoea and soiling of the down. This disease, known as 'Limey disease', was first noticed when the birds were of economic importance as a source of meat and down.

Avian malaria has been recorded in guillemots contaminated with oil (Roertgen, 1990), but does not appear to be associated with primary disease.

Free-living metacercariae of the trematode *Distomum filiferum*, a parasite of crustacea, have been responsible for the death of white-faced petrels (*Pelagodroma marina*). It was considered that, as the petrels paddled along the surface feeding, large numbers of metacercariae attached to their legs. Long elastic filaments trailing from the metacercariae bound together round both legs, forming 'shackles' of fibrous material that restricted leg movement. Once on land in the breeding colony, the birds were unable to manoeuvre and therefore to take off again, as they rely on launching themselves into the air from a cliff or other suitable vantage point. The birds therefore starved to death. Some 200 000 birds died out of a colony of at least 1 million pairs (Claugher, 1976).

## Toxins and poisons

### *Synthetic organic chemicals*

Halogenated hydrocarbons (HHCs) are totally artificial compounds, and are not found in nature. They are very persistent in the

environment and in living organisms, having an affinity for high-fat tissues including the nervous system. Bioaccumulation occurs in the food chain, resulting in the presence of far higher levels of chemicals in top predators such as fish-eating birds than in the environment generally.

Bioaccumulation of HHC residues in birds first became an issue in the 1960s, particularly in relation to the decline in raptor numbers, but the effects were just as dramatic in aquatic environments. HHCs used as agricultural pesticides, such as lindane, DDT, aldrin, dieldrin, etc., caused eggshell thinning, resulting in reduced hatchability and population decline.

HHCs such as dieldrin, DDT and DDE have been implicated in seabird die-offs (Scott *et al.*, 1975; Bourne, 1976). Healthy herring gulls (*Larus argentatus*) can normally loose up to 30 per cent of their body weight in 17 days without losing vigour (Gilbertson, 1988), but periods of starvation and weight loss that would normally cause no loss of vigour can result in signs of acute poisoning due to release of HHCs from body fat depots. Clinical signs of acute pesticide poisoning include nystagmus and clonic convulsions. HHCs can also have an immunosuppressive effect, and deaths may be due to multiple environmental factors.

With the banning of agrochemicals containing lindane, DDT and the 'drin' family, the effects of another equally persistent toxic HHC group, the polychlorinated biphenyls (PCBs), became evident. These chemicals have a wide range of uses, but are not used as agricultural pesticides. They accumulate in the environment mainly through industrial pollution. PCBs have been implicated in embryonic mortality and poor hatching success. Pathological findings associated with high PCB levels include reduced embryonic size, enlarged livers, porphyria, and accumulations of peritoneal and pericardial fluid and subcutaneous mucoserous exudates (Gilbertson and Fox, 1977).

Environmental legislation controlling the use and disposal of toxic substances has led to greatly reduced concentrations of HHCs of the 'drin' family and of PCBs. However, in the Great Lakes of North America, despite reduced environmental concentrations of total HHCs, increased mortality rates in chicks and embryos of double-crested cor-

morants have been linked to yet another HHC group, planar halogenated hydrocarbons (PHHs). This group contains the highly toxic dioxins. Selective enrichment of individual HHC congeners (especially those with dioxin-like activity) and interaction between them in the environment may have caused this toxic effect. The ecological significance of such effects is as yet poorly understood (Tillet *et al.*, 1992).

Pollution of the environment with persistent synthetic organic chemicals, and their effects on wildlife, will no doubt remain a major environmental issue for the foreseeable future.

## Heavy metals

### Mercury

High levels of mercury from industrial pollution have been detected in a variety of seabirds, but have not been directly related to disease or mortality. Mercury intoxication has been suspected of contributing to emaciation and death in loons (Brand *et al.*, 1988).

### Lead

The accidental ingestion of lead from shotgun cartridges or anglers' weights is not generally a problem in fish-eating seabirds. Lead poisoning has been recorded in Laysan albatross chicks due to ingestion of flakes of lead paint from building debris used as nesting material. Symptoms were drooping wings in birds of good nutritional status. On postmortem there was yellow watery bile and paint chips in the proventriculus (Sileo *et al.*, 1990).

## Botulism

Botulism is a paralytic disease that affects vertebrates, and is caused by the toxin of the anaerobic bacterium *Clostridium botulinum*.

Avian botulism is an intoxication, not an infectious disease. It is contracted only by the ingestion of toxin pre-formed in suitable media. Type C toxin causes sporadic deaths in birds world-wide, but type E toxin is



largely restricted to the Great Lakes of North America. *C. botulinum* cannot survive, nor its toxin persist, in a saline environment equivalent to seawater (Ankerberg, 1984). However, deaths of seabirds in fresh or brackish water environments have occurred. High temperatures, shallow, still or slow moving water and decaying organic matter creating a nutrient-rich anaerobic environment predispose to outbreaks of botulism from the germination of *C. botulinum* spores found naturally in soil. Carcasses of botulism casualties and maggots feeding on them are rich sources of toxin, and will cause further deaths if ingested.

Rubbish tips are a common source of toxin for scavenging gulls of many species. Gulls and terns may ingest toxin from shallow stagnant pools used for bathing and loafing (Lloyd *et al.*, 1976).

Perhaps most difficult to understand is an outbreak of type E botulism among common loons (*Gavia immer*) in Michigan in 1983 (Brand *et al.*, 1988), as loons appear to feed exclusively on live fish. It was considered possible that dead or moribund fish contaminated with toxin were consumed.

Clinical signs of botulism are the acute onset of flaccid paralysis of voluntary muscles. Long-necked seabirds may show classic 'limberneck', as seen in wildfowl, but gulls show unco-ordinated gait, become unable to stand, and may show respiratory distress with open mouth breathing before the head carriage becomes affected.

Forbes (1996) links the prognosis to the severity of symptoms in waterfowl, but gulls seem less predictable, often recovering with basic care despite severe clinical signs.

Treatment consists of fluid therapy, oral and parenteral, administration of intestinal adsorbents such as activated charcoal and/or bismuth, and good nursing. Type C antitoxin is produced experimentally in small quantities and has been effective in the treatment of birds, but any such treatment must comply with national legislation regarding the use of such serum-based products.

Confirmation of diagnosis can be made by detection of the toxin in serum or stomach contents. However, the author has found that samples from birds showing classical clinical signs frequently fail to reveal the presence of the toxin.

## Algal blooms

Phytoplankton are algae, usually single-celled plants, which survive by photosynthesis and absorption of nutrients directly from the water. They are prey for zooplankton, and both taxa exist in equilibrium. Algal blooms can be part of natural cycles. For example, in the temperate regions of the northern hemisphere algal blooms can occur naturally in Spring as the daylight length increases and surface water warms up, and in Autumn when strong winds and tides push nutrient-rich water to the surface (upwelling) while there is still sufficient daylight length for rapid algal growth.

Some species of phytoplankton produce potent toxins, especially neurotoxins. Blooms of phytoplankton can occur in such local abundance that the toxins reach a concentration at which fish and invertebrates are killed. Some toxic phytoplankton are coloured, and in particularly profuse blooms they can reach densities of  $20\text{--}30 \times 10^6$  cells/l (MacGarvin, 1990), causing the sea to be discernibly coloured red, yellow or brown, leading to the term 'red tide'. Toxic phytoplankton include *Chrysochromulina* spp., *Dynophysis* spp., *Gonyaulax* spp. and *Gymnodinium* spp. The latter two are particularly associated with red tides.

Shellfish, especially mussels, appear to be immune to the toxin but temporarily concentrate it in their flesh, leading to outbreaks of poisoning – including 'paralytic shellfish poisoning' (PSP) in humans who consume them. Similarly, birds that consume affected shellfish, dead or dying invertebrates or affected fish during a bloom can develop poisoning. The disease is characterized by sudden death, with a high mortality (>80 per cent has been recorded), which is localized and of short duration – the toxins can build up and decline again in as little as 2 weeks. Taxa affected include fulmars, cormorants, eiders (*Somateria mollissima*), gulls, terns and auks (Armstrong *et al.*, 1978).

Nutrient enrichment of coastal waters with nitrogen and phosphates, particularly from agricultural run-off into rivers, can lead to a significant increase in the quantity and frequency of algal blooms to the point where in some sea areas die-offs of seabirds due to PSP are recurrent and shellfish for human consumption must be constantly monitored.

Field diagnosis is by clinical signs and circumstantial evidence. Peracute mortality of diverse taxa (which can include birds, marine mammals and fish) is suspicious, and often adults in good physical condition are worst affected because they consume most prey and therefore most toxin. Confirmation of diagnosis is by detection of lethal levels of toxin in very fresh carcasses or stomach contents, although toxins tend to be labile and degrade rapidly. Some toxins are associated with specific brain lesions that can be detected histologically, but generally histology is useful in elimination of other differential diagnoses. Detection of high numbers of toxic phytoplankton in water samples, or high toxin levels in the food chain, is suspicious. As the disease is characterized by sudden death, treatment is rarely an issue, but if birds are recovered alive they should be treated symptomatically. Specific antitoxins have been used successfully experimentally in marine mammals and man, but are not commercially available.

## Oil

Although any bird can become contaminated with oil, for example pet birds falling into cooking oil, by far the largest problem is created by pollution of the sea with crude or heavy fuel (bunker) oil. The taxa worst affected are surface swimming and diving birds. Major oil spills are not the only cause of oiling of seabirds. Many minor pollution episodes, such as leakage at offshore wells, accidental spills and illegal dumping, combine to cause a background pollution level that results in annual seabird casualties in the UK equivalent to those caused by one major tanker disaster.

When a bird swims into an oil slick the oil becomes distributed on the feathers, clogging the feather structure and causing loss of waterproofing. Water penetrates to the skin and the layer of air normally trapped in the down feathers is lost, resulting in loss of insulation and buoyancy. Birds become hypothermic and may drown. Normal behaviour (including feeding) is disrupted, and there is an increase in metabolic requirements to maintain body temperature. Survivors lose weight rapidly.

The net effect of oiling of the plumage is to make water a hostile environment, and sur-

vivors of the spill will seek refuge on the shore, where they may be picked up and brought to a rescue centre for treatment.

The behavioural response to feather contamination is vigorous preening, which leads to ingestion of oil and oil toxicosis.

The toxicity of different oils varies greatly, most obviously with the ratio of 'light' aromatic hydrocarbons to the 'heavy' tar-like fraction. Refined oils, having the tar fraction removed, are the most toxic. Crude oils vary considerably; Arabian oils have a large heavy fraction, North Sea oils have a large light fraction. Once spilt, the oil starts to 'weather' – i.e. the light fraction evaporates and disperses, leaving the less toxic heavy tars, which often end up as tar balls on the beach. Thus the degree of toxic effects of ingestion will depend not only on the volume ingested, but also on the type of oil and how long it has been spilt.

The ingestion of crude oil prevents the uptake of water and electrolytes by the intestinal mucosa, resulting in diarrhoea and dehydration. In a saltwater environment, this in turn prevents the functioning of the nasal gland, rapidly exacerbating dehydration. Birds experimentally dosed with crude oil died rapidly from dehydration in a saltwater environment, but survived on freshwater (Flemming *et al.*, 1982).

A primary toxic effect of crude oil ingestion is haemolytic anaemia (Leighton *et al.*, 1983). The haemolytic crisis occurs between 3 and 6 days post-exposure, and recovery starts from day 7 (Fry and Lowenstine, 1985).

Other sequelae of oil ingestion reported include:

- hepatic haemosiderosis, especially in Kupffer cells, dissociation of hepatocytes and hepatic necrosis
- renal tubular degeneration and necrosis (Fry and Lowenstine, 1985; Khan and Ryan, 1991; Greth *et al.*, 1995)
- lipid pneumonia (Hartung and Hunt, 1966)
- hyperaemia, oedema and venous thrombi in lungs (Greth *et al.*, 1995)
- adrenocortical hyperplasia (Holmes *et al.*, 1978) and necrosis (Greth *et al.*, 1995)
- lymphoid depletion of the spleen (Greth *et al.*, 1995)
- immunosuppression (Holmes *et al.*, 1978)
- embryonic death and reduced hatchability of eggs (Leighton *et al.*, 1995).

A wide range of gastrointestinal lesions have been reported, with and without occult blood. Severe necrotic enteritis is often associated with secondary bacterial infection (Wood *et al.*, 1993).

Black fluid in the gastrointestinal tract, a black residue lining the gizzard and red/black mucus at the isthmus of the gizzard is frequently seen on postmortem in both oiled and non-oiled birds, but is not an oil residue. Its origin is unclear, but may be associated with poor body condition (Holmes, 1995).

In practice, veterinary treatment and nursing of survivors of oil pollution must first be directed at maintaining hydration and body condition. Although the first 4 days are most critical, auks have become dehydrated up to 8 days after hospitalization despite good appetite and access to fresh water. Birds that appear bright and eat well can rapidly become dull, with drooping wings and hunched appearance. Collapse and death can occur within 2 hours of the onset of clinical signs.

On post-mortem examination, carcasses appear dry, with lack of elasticity of the skin, which is tightly adherent to the underlying musculature (Wood *et al.*, 1993). Urate tophi in the kidney is a common histological finding.

Routine examination and treatment should include:

- 1 Body temperature. Less than 32.5°C carries a poor prognosis. Hypothermic birds should be warmed gradually until normal body temperature is reached, and blown hot air is the method of choice. Once normothermic, birds are best maintained in an air temperature of 22–25°C. Higher ambient temperatures may create heat stress. Social birds kept in groups show marked aggression at higher temperatures.
- 2 State of hydration. Many oiled birds will be severely dehydrated and diarrhoeic. Adsorbents and activated charcoal mixed with oral rehydration fluids can be administered routinely. Fluid therapy may have to be continued, with or without nutritional support, for 4–8 days.
- 3 Body condition. This should be assessed and the weight compared to a normal for the species, if available. Normal bodyweight can vary with age, sex and time of year, and if in doubt condition is better assessed by examination than by absolute weight. When

assessing the prominence of the keel bone, care must be taken to penetrate the thick down over the breast to the skin beneath.

- 4 Prophylactic antibiotics. Prophylactic use of antifungals is indicated if birds are considered at risk of aspergillosis, either through species susceptibility or high environmental challenge.
- 5 PCV and total solids (Tables 15.4, 15.5). Monitoring packed cell volume (PCV or HCT) and total solids (TS), which correlates with total protein (TP), is possible on site with minimal equipment (haematocrit, refractometer) and can be performed using one drop of blood. This is a very useful way of monitoring haemoconcentration due to dehydration, anaemia due to haemolysis and hypoproteinaemia due to negative caloric balance. Even if birds are eating well, additional fluid and nutritional therapy can be administered accordingly.

Only when birds are stable, bright and active, and of adequate bodyweight and health status, should they be selected for washing, as the process itself is stressful and vigorous preening afterwards is essential.

Several detergents are used world-wide by different rehabilitation groups. *In vitro* testing (Brynza *et al.*, 1990) has indicated that the surfactant of choice is 'Dawn' or 'Fairy Liquid' (Proctor and Gamble). A 2 per cent solution is adequate, but in practice small amounts of neat detergent are applied to difficult residues. Well-weathered tar, fulmar oil or other difficult residues may be pretreated to soften the residue, which is then washed with detergent in the normal way. Vegetable oil, methyl oleate and a variety of biodegradable detergents used in the offshore oil industry have been used successfully.

#### **Technique for hand washing**

Two people are required, one to hold and one to wash. The bird is immersed in a solution of detergent at 42°C (range 40–45°C). The holder keeps as much of the bird's body as possible immersed and in contact with the detergent whilst presenting the required area to the washer (Figure 15.2).

The washer rubs the feathers between his or her fingers and thumb from base to tip until they are all clean. It is essential that no oil

**Tables 15.4(a) and (b)** Haematology and clinical chemistry. Reference values from clinically healthy birds are available for some seabird species, although often from very limited numbers of individuals**(a) Haematology**

Parameter	Unit	Guillemot (Newman and Zinkl, 1996)	Manx shearwater (Kirkwood <i>et al.</i> , 1995)	Herring gull (Averbeck, 1992)	American white pelican (Pelicanus erythrorhynchos) (Bennett <i>et al.</i> 1991)	Cormorant (Bennett <i>et al.</i> 1991)
Total haemoglobin (Hb)	g/dl	10.2–16.8** (n = 10)	13.00–16.74 (n = 10)	11.14–14.86 (n = 109)	10.7–17.3 (n = 12)	8.4–13.1** (n = 5)
Red blood cell count (RBC)	10 <sup>12</sup> /l	2.43–3.94** (n = 10)	2.49–3.25 (n = 9)	1.8–2.4 (n = 143)	1.91–3.0 (n = 12)	1.62–2.30** (n = 5)
Packed cell volume (PCV)	l/l	33–58** (n = 10)	0.43–0.53 (n = 9)	0.40–0.42 (n = 109)	0.32–0.47 (n = 12)	0.27–0.41** (n = 5)
Mean cell volume (MCV)	fl	136–179** (n = 10)	152.3–179.7 (n = 9)	164.6–236.6 (n = 109)	139.3–185.4 (n = 12)	164.8–180.4** (n = 5)
Mean cell haemoglobin (MCH)	pg	36.3–48.3** (n = 10)	48.1–58.6 (n = 9)	52.7–72.7 (n = 109)	51.19–61.86 (n = 12)	51.9–57.0** (n = 5)
Mean cell haemoglobin concentration (MCHC)	g/dl	26.0–30.9** (n = 10)	0.37–33.63 (n = 9)	28.2–34.8 (n = +109)	29.94–39.96 (n = 12)	31.1–33.0** (n = 5)
Total white cell count (WBC)	10 <sup>9</sup> /l	2.0–9.5** (n = 10)	1.13–9.65 (n = 10)	12.4–18.6 (n = 103)	2.55–18.7 (n = 12)	6.10–15.5** (n = 5)
Heterophil count	10 <sup>9</sup> /l	1.26–4.86** (n = 9)	0.28–5.34 (n = 10)	2.6–8.2 (n = 103)	0–16.28 (n = 12)	5.37–13.2** (n = 5)
Lymphocyte count	10 <sup>9</sup> /l	0.08–1.68** (n = 9)	0–3.43 (n = 10)	6.4–12.4 (n = 103)	0.38–4.5 (n = 12)	0.4–2.17** (n = 5)
Monocyte count	10 <sup>9</sup> /l	0** (n = 10)	0–0.87* (n = 10)	0–1.4* (n = 103)	0–0.34* (n = 12)	0–0.12** (n = 5)
Eosinophil count	10 <sup>9</sup> /l	0.48–4.46** (n = 9)	0–0.23 (n = 10)	0–1.6* (n = 103)	0–0.41* (n = 12)	0 (n = 5)
Basophil count	10 <sup>9</sup> /l	0–0.24** (n = 10)	0–0.76 (n = 10)	0.5–1.4* (n = 103)	0–0.40* (n = 12)	0–0.49** (n = 5)
Thrombocyte count	10 <sup>9</sup> /l		6.74–16.26 (n = 10)		12.46–34.08 (n = 11)	25–50** (n = 5)
Fibrinogen	g/l		1.54–2.43 (n = 6)		0–3.5 (n = 11)	2.06–3.86** (n = 5)

\* Parameters that are not normally distributed and are therefore expressed as ranges rather than standard deviations. \*\* Small datasets expressed as standard deviations can result in parameters so widely spread they are of little practical value, and these are also expressed as ranges.

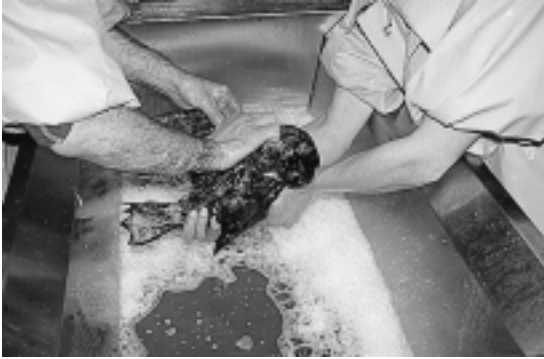residue remains. The feel of the feather between the fingers is helpful in assessing cleanliness, and many operators prefer to wash with bare hands. However, continuous exposure to detergents can lead to defatting of skin and dermatoses in operators, so use of suitable gloves may be important for health and safety. It is important to follow a standard routine so that no feathers are missed. It is usual to start with the head, using a tooth-

brush or cotton bud if necessary to remove oil from around the nares and inside the beak. The neck, back and dorsal surface of the tail are then cleaned. The bird is rolled onto one side and then the other to wash each wing and flank, and finally, the bird is held on its back while the breast feathers and ventral side of the tail feathers are washed. Heavily contaminated birds may be washed in this manner two or even three times, discarding the

**Table 15.4(b)** Biochemistry

<i>Parameter</i>	<i>Units</i>	<i>Guillemot (Newman and Zinkl, 1996)</i>	<i>American white pelican (Bennett <i>et al.</i> 1991)</i>
Urea	mmol/l		0–1.5** (n = 6)
Creatinine	µmol/l	35.4–70.2** (n = 10)	22–51** (n = 6)
Bicarbonate	mmol/l	17–33** (n = 10)	7–30** (n = 6)
Chloride	mmol/l	103–121** (n = 10)	110–116** (n = 6)
Sodium	mmol/l	152–163** (n = 10)	149–157** (n = 6)
Potassium	mmol/l	3.3–10** (n = 10)	1.7–3.1 ** (n = 6)
Total protein	g/l	39–48** (n = 10)	24–42** (n = 6)
Albumin	g/l	11–14** (n = 10)	10–16** (n = 6)
Globulin	g/l	26–34** (n = 10)	
Calcium	mmol/l	2.08–2.77** (n = 10)	2.14–2.65** (n = 6)
Inorganic phosphate	mmol/l	1.41–2.94** (n = 10)	0.22–1.66** (n = 6)
Total bilirubin	µmol/l	0–5.13** (n = 10)	2–4** (n = 6)
Conjugated bilirubin	µmol/l	0–1.71** (n = 10)	0–1.0** (n = 6)
Urate	µmol/l	267–1118** (n = 10)	341–601** (n = 5)
Alkaline phosphatase	iu/l	22–149** (n = 10)	300–1052** (n = 6)
Alanine transaminase	iu/l	53–216** (n = 10)	23–75** (n = 6)
Gamma glutamyl transferase	iu/l	0–10.0** (n = 10)	0–5** (n = 4)
Aspartate transaminase	iu/l	117–1491** (n = 10)	56–464** (n = 6)
Creatine kinase	iu/l	537–3801** (n = 10)	
Iron	µmol/l		8.2–28.1** (n = 6)
Cholesterol	mmol/l	8.22–10.95** (n = 10)	
Glucose	mmol/l	12.26–17.19** (n = 10)	

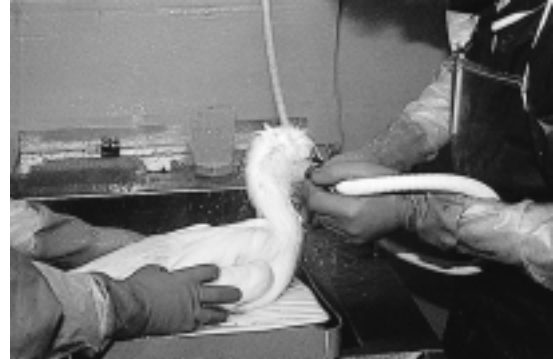\* Parameters that are not normally distributed and are therefore expressed as ranges rather than standard deviations. \*\* Small datasets expressed as standard deviations can result in parameters so widely spread they are of little practical value, and these are also expressed as ranges.



**Figure 15.2** Washing oiled birds. The bird, a common scoter (*Melanitta nigra*) is restrained by the handler and its breast presented to the washer, who can use both hands to manipulate the feathers.

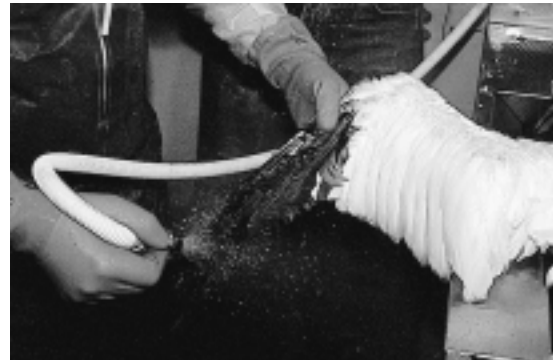heavily soiled detergent solution each time until no more oil comes off the feathers.

The operators must ensure that their hands and clothing, and the working surfaces, are free of detergent contamination before commencing to rinse. Using a high-pressure shower jet at 42°C, the washer rinses against the lie of the feathers until all detergent is removed and water is beading on the feathers. Water pressure must be sufficient to lift the feathers and fluff up the underlying down (Figure 15.3). As detergent is removed the feathers begin to shed water, which beads and runs off leaving feathers dry (Figures 15.4, 15.5). Water pressure between 345 and 620 kPa (60 and 90 psi) is ideal. A standard domestic shower attachment can be used, but if water pressure is a problem, using a commercial spray head with a more restricted flow rate (a smaller jet) may give better results. However, a minimum acceptable flow is required,



**Figure 15.3** Rinsing. The water pressure must be sufficient to lift the feathers and ensure all detergent is removed.

depending on the size of bird, to avoid prolonged rinsing time. Spray heads designed for 'drive through' car washes come in a variety of suitable sizes. Specialized equipment, including water holding tanks and



**Figure 15.4** Water should bead and run freely off feathers at the end of the rinse.

**Table 15.5** Treatment guidelines based on PCV and total protein (based on Tseng, 1993)

Parameter	Comments
PCV > 55%	Require fluid therapy
TS < 2.0 g/dl	Require nutritional therapy, even if self-feeding
PCV < 15%	Require nutritional therapy, even if self-feeding
TP > 2.0 g/dl	Before selecting for washing
PCV > 25%	Before selecting for washing



**Figure 15.5** The wing at the end of the rinse.

booster pumps, is required if a water main of suitable size and pressure is not available.

It is the job of the holder to ensure that contaminated water always flows off the bird away from areas already rinsed. The same methodical routine should be used for rinsing to ensure that no feathers are missed.

On completion, water should be beading freely on all areas of the bird's plumage and the underlying down should look fluffy and dry. Water from the showerhead can be run over the plumage. Any area where water is seen to penetrate the feathers is not 'proofed' and needs further attention. Because of the danger of recontamination by detergent residues, the whole body should be rinsed again, concentrating on areas of water penetration.

Total time taken can vary from 15–40 minutes, depending on the size of the bird, the degree of contamination and the skill of the washers. Very large birds such as swans (*Anseriformes*) or penguins (*Sphenisciformes*) may take longer.

Once completed, the bird is placed in the drying area and left in a current of warm air until dry. A domestic fan heater is adequate in most circumstances, and individual birds can be dried with a hair drier. Most birds will quickly start to preen to align their feathers correctly. As soon as they are completely dry, birds can be put on water. In practice birds are

usually left overnight and introduced to the pool the following day (Figure 15.6).

Once on water, it is essential that the bird preens. Failure of waterproofing can be due to residual contamination with oil or detergent, failure to preen, or contamination of the surface of the pool. Efficient surface skimming (see earlier) is important to remove oily faeces, and fish-eating birds should be fed in shallow trays away from the water to ensure the water surface is not contaminated with fish oil. Pool sides should be easy to clean and gently sloping for an easy exit if the birds become wet.

Birds usually require 4–5 days on water to preen sufficiently to restore the feather structure adequately, although some may take up to 10 days before their plumage shows no water penetration and they are fit for release.

An integrated automatic process using a purpose-designed machine and detergent has been developed (Basseres *et al.*, 1995). Birds are restrained in a frame, which is lowered into a tank within which are rotating bars carrying spray nozzles. The bird's body is sprayed first with the detergent, then with fresh water, while the head, which is left protruding from the top of the apparatus, is cleaned by hand. In this way a reduction in cleaning time to 7 minutes can be achieved. The use of such a machine during an oil spill



**Figure 15.6** After drying overnight the birds are placed on a surface skimming pool, where preening will restore any remaining disrupted feather structure.

enables the rapid deployment of washing facilities to the site of the spill. Also, variability in expertise in washing technique and the need for large numbers of skilled washers can be eliminated. However, the numbers of birds that can be rehabilitated, and the time they must spend in captivity, will be determined not by the speed at which they can be washed but by the facilities for nursing before washing, and pool facilities for holding birds after washing before they become fit for release. These are the most important factors to consider in the siting of any washing facility, manual or automated.

### **Survival to release**

Survival of oil spill victims depends on many factors – the type of oil, species involved, weather conditions, facilities available for collection and treatment of casualties, skill and experience of staff, etc. However, overall survival rates of over 60 per cent are now regularly achieved. For example, when the tanker *Sea Empress* ran aground in Milford Haven, Wales, in February 1996, the Royal Society for the Prevention of Cruelty to Animals (RSPCA) co-ordinated a rescue effort which resulted in 2266 live oiled casualties of 15 species admitted to RSPCA wildlife hospitals. A total of 1434 birds (63.3 per cent) were released.

### **Post-release survival**

The simplest way of monitoring post-release survival of rehabilitated birds is by the use of numbered leg rings (bands). Use of the same ringing system as for monitoring healthy wild birds provides a natural comparison. However, ring returns from pelagic seabirds are generally low, and therefore a large sample size is required before sufficient returns are obtained for a significant statistical analysis. Of the species of seabirds commonly rehabilitated, only guillemots have been ringed in sufficient numbers for such analyses.

Recent statistical analyses of ring returns from rehabilitated oiled guillemots in both North America and Britain have suggested that post-release survival is very low. In a statistical review of 127 ring returns from 3200 released rehabilitated oiled seabirds in North America, Sharp (1996) concluded that guillemots

had a post-release life expectancy of only 9.6 days and a negligible number survived more than 12 months. Wernham *et al.* (1997) found that of 309 returns from 2834 released rehabilitated guillemots in Britain, the median survival time was 7 days, equating to an annual survival of 0.6 per cent. This compares to 599 days and 88 per cent respectively for non-rehabilitated adults. Anderson *et al.* (1996) radio-tracked oiled rehabilitated and unaffected brown pelicans. The rehabilitated birds disappeared from the population faster than unaffected birds, and also failed to breed.

In contrast, mute swans (*Cygnus olor*) contaminated with light fuel oil and treated conservatively without washing suffered higher mortality than unaffected birds for 5 months and failed to breed that year, after which mortality and breeding returned to normal (Collins *et al.*, 1994). Oiled and rehabilitated Jackass penguins (*Spheniscus demersus*) had a survival rate to release of 68 per cent, of which 87 per cent were recorded back at their colony some 900 km from the release site within 7 months.

The remarkable success of rehabilitation in penguins and swans in sharp contrast to the almost complete failure in auks would suggest that death in non-survivors is not directly due to the effects of contamination with or ingestion of oil. Many suggestions for non-survival have been put forward, including stress during rehabilitation, persistent immunosuppression and the failure to find an adequate food source after release. At present, all suggestions are purely conjecture. However, although survival rates during rehabilitation have improved remarkably in recent years, there is no evidence that improved techniques during rehabilitation have had any effect on post-release survival (Sharp, 1996; Wernham *et al.*, 1997).

It can be seen from these studies that the rehabilitation of oiled seabirds is a controversial field. The cost of rehabilitation of birds after a major spill can be high, and the cost-effectiveness and conservation value of such efforts have been questioned (Anderson *et al.*, 1996; Sharp, 1996). However, the rehabilitation of oiled seabirds is perhaps best considered primarily as a welfare issue. The welfare of oil spill victims is not best served by attempted rehabilitation unless an acceptable chance of post-release survival can be



achieved, and those involved in wildlife rescue must address this problem rationally and scientifically as a matter of urgency.

## References

- ANDERSON, D. W., GRESS, F. and FRY, D. M. (1996). Survival and dispersal of oiled brown pelicans after rehabilitation and release. *Marine Poll. Bull.*, **32**(10), 711–18.
- ANKERBERG, C. W. (1984). Pelican deaths in the vicinity of a sewage lift station: a bacteriological investigation. *Microbios Letters*, **26**, 33–42.
- ARMSTRONG, I. H., COULSON, J. C., HAWKEY, P. and HUDSON, M. J. (1978). Further mass seabird deaths from paralytic shellfish poisoning. *Br. Birds*, **71**, 58–68.
- AVERBECK, C. (1992). Haematology and blood chemistry of healthy and clinically abnormal great black-backed gulls (*Larus marinus*) and herring gulls (*Larus argentatus*). *Avian Pathol.*, **21**, 215–23.
- BANERJEE, M., REED, W. M., FITZGERALD, S. D. and PANIGRAHY, B. (1994). Neurotropic velogenic Newcastle disease in cormorants in Michigan: pathology and virus characterization. *Avian Dis.*, **38**, 873–8.
- BARTON, T. R., HARRIS, M. P. and WANLESS, S. (1995). Natural attachment duration of nymphs of the tick *Ixodes uriae* (*Acar*: *Ixodidae*) in Kittiwake *Rissa tridactyla* nestlings. *Exp. Appl. Acarology*, **19**, 499–509.
- BASSERES, A., VERSCHUERE, B., JACQUES J.-P. *et al.* (1995). A new cleaning product for oiled birds and an integrated automated process. Oil Spill Conference. Poster Session W3 *Evolving Technologies*. Tri-State Bird Rescue and Research Inc., Delaware, USA.
- BECKER, W. B. (1966). The isolation and classification of tern virus: influenza virus A/Tern/South Africa/1961. *J. Hygiene*, **64**, 309–20.
- BENNETT, P. M., GASCOYNE, S. C., HART, M. G. *et al.* (1991). *The Lynx Database*. Dept. of Veterinary Science, Zoological Society of London.
- BOURNE, W. R. P. (1976). The mass mortality of common murres in the Irish Sea in 1969. *J. Wildlife Man.*, **40**(4), 789–92.
- BRAND, C. J., SCHMITT, S. M., DUNCAN, R. M. and COOLEY, T. M. (1988). An outbreak of type E. botulism among common loons (*Gavia immer*) in Michigan's upper peninsula. *J. Wildlife Dis.*, **24**(3), 471–6.
- BROOKE, M. (1990). *The Manx Shearwater*, pp. 144–67. T. & A.D. Poyser.
- BRYNZA, H. E., FOSTER, J. P., MCCARTNEY, J. H. *et al.* (1990). Surfactant efficacy in removal of petrochemicals from feathers. The Effects of Oil on Wildlife Oil Symposium. The 13th Annual Conference of the International Wildlife Rehabilitation Council. International Bird Rescue Research Center, Berkeley, USA.
- CHOE J. C. and KIM, K. C. (1991). Microhabitat selection and adaption of feather mites (*Acar*:*Analgoidea*) on murres and kittiwakes. *Can. J. Zool.*, **69**, 817–21.
- CLAUGHER, D. (1976). A trematode associated with the death of white-faced storm petrels (*Pelagodroma marina*) on the Chatham Islands. *J. Natural History*, **10**, 633–41.
- COLLINS, R., BRAZIER H. and WHELAN, J. (1994). Rehabilitating a herd of oiled mute swans (*Cygnus olor*). *Biology and Environment: Proceedings of the Royal Irish Academy*, **94B**(1), 83–99.
- CONVERSE, J. D., HOOGSTRAAL, H., MOUSSA, M. I. *et al.* (1975). Soldado virus (Hughes group) from *Ornithodoros (alektorobius) capensis* (Ixodoidea: Argasidae) infesting sooty tern colonies in the Seychelles, Indian Ocean. *Am. J. Tropical Med. Hygiene*, **24**, 1010–18.
- CROKER, A. D., CRONSHAW, J. and HOLMES, W. N. (1974). The effects of a crude oil on intestinal absorption in ducklings (*Anas platyrhynchos*). *Environ. Poll.*, **7**, 165–77.
- FLEMMING, W. J., SILEO, L. and FRANSON, J. C. (1982) Toxicity of Prudhoe Bay crude oil to sandhill cranes. *J. Wildlife Man.*, **46**(2), 474–6.
- FORBES, N. A. (1992). Diagnosis of avian aspergillosis and treatment with itraconazole. *Vet. Rec.*, **130**, 519.
- FORBES, N. A. (1996). *Manual of Raptors, Pigeons and Waterfowl* (P. H. Benyon, N. A. Forbes and N. H. Harcourt-Brown, eds). BSAVA.
- FRY, D. M. and LOWENSTINE, L. J. (1985). Pathology of common murres and Cassin's auklets exposed to oil. *Arch. Environ. Contam. Toxicol.*, **14**, 725–37.
- GILBERTSON, M. and FOX, G. A. (1977). Pollutant-associated embryonic mortality of Great Lakes herring gulls. *Environ. Poll.*, **12**, 211–16.
- GILBERTSON, M. (1988). *Toxic Contaminants and Ecosystem Health: A Great Lakes Focus*. John Wiley & Sons.
- GRETH, A., RESTER, C., GERLACH, H. *et al.* (1995). Pathological effects of oil in seabirds during the Arabian Gulf Oil Spill. In: *Wildlife and Oil Spills, Response Research and Contingency Planning* (Frink, ed.), pp. 134–41. Tri-state Bird Rescue and Research Inc.
- HARTUNG, R. and HUNT, G. S. (1966). Toxicity of some oils to waterfowl. *J. Wildlife Man.*, **30**, 564–9.
- HILL, J. R. and BOGUE, G. (1978). Natural pox infection in a common murre (*Uria aalge*). *J. Wildlife Dis.*, **14**, 337.
- HOLMES, J. P. (1995). Health of free-living guillemots (*Uria aalga*) and razorbills (*Alca torda*): the value of detailed post-mortem examinations in a sample of beached seabird carcasses. MSc thesis, University of London.
- HOLMES, W. N., CRONSHAW, J. and GORSLINE, J. (1978). Some effects of ingested petroleum on seawater-adapted ducks (*Anas platyrhynchos*). *Environ. Res.*, **17**, 177–90.
- JACOBSON, E. R., RAPHAEL, B. L., NGUYEN, H. T. *et al.* (1980). Avian pox infection aspergillosis and renal trematodiosis in a royal tern. *J. Wildlife Dis.*, **16**, 627.
- JENSEN, W. I. (1979). An outbreak of streptococcosis in eared grebes (*Podiceps nigricollis*). *Avian Dis.*, **23**, 543.
- JENSEN, W. I. and COTTER, S. E. (1976). An outbreak of erysipelas in eared grebes (*Podiceps nigricollis*). *J. Wildlife Dis.*, **12**, 583.
- KHAN, R. A. and RYAN, P. (1991). Long-term effects of crude oil on common murres (*Uria aalge*) following rehabilitation. *Bull. Environ. Contam. Toxicol.*, **46**, 216–22.

- KANEENE, J. B., FLINT TAYLOR, R., SIKARSKIE, J. G. *et al.* (1985). Disease patterns in the Detroit Zoo: a study of the avian population from 1973 through 1983. *JAVMA*, **187**(11), 1129–31.
- KING, A. S. and MCLELLAND, J. (1984). *Birds, their Structure and Function*. Ballière Tindall.
- KIRKWOOD, J. K., CUNNINGHAM, A. A., HAWKEY, C. *et al.* (1995). Haematology of fledgling Manx shearwaters (*Puffinus puffinus*) with and without 'puffinosis'. *J. Wildlife Dis.*, **31**(1), 96–8.
- LEIGHTON, F. A., PEAKALL, D. B. and BUTLER, R. G. (1983). Heinz-body haemolytic anaemia from the ingestion of crude oil: a primary toxic effect in marine birds. *Science*, **220**, 871–3.
- LEIGHTON, F. A., COUILLARD, C. M. and LUSIMBO, W. S. (1995). Recent studies on the toxicity of petroleum oils to avian embryos. In: *Wildlife and Oil Spills, Response Research and Contingency Planning* (L. Frink, ed.), pp. 115–18. Tri-state Bird Rescue and Research Inc.
- LLOYD, C. S., THOMAS, G. J., MACDONALD, J. W. *et al.* (1976). Wild bird mortality caused by botulism in Britain, 1975. *Biol. Conserv.*, **10**, 119–29.
- LOUZIS, C., GUITTET, M., RICHARD, C. *et al.* (1984). Un exemple de déséquilibre naturel au sein d'un écosystème marin: la mortalité de mouettes triactyles. *Bull. Acad. Vet. France*, **57**, 315–23.
- MACGARVIN, M. (1990). *The North Sea*. Collins and Brown Ltd.
- MAHAFFY, L. (1990). The question of avian water repellency: why are some birds more difficult to rehabilitate? Oil Symposium 1990. The 13th Annual Conference of the International Wildlife Rehabilitation Council. International Bird Rescue Research Center, Berkeley, USA.
- NEWMAN, S. and ZINKL, J. (1996). Establishment of haematological, serum biochemical and electrophoretogram reference intervals for species of marine birds likely to be impacted by oil spill incidents in the state of California. Baseline Marine Bird Project for the California Dept of Fish and Game, Office of Oil Spill Prevention and Response.
- OLSEN, B., JAENSON, T. G. T., NOPPA, L. *et al.* (1993). A Lyme borreliosis cycle in seabirds and *Ixodes uriae* ticks. *Nature*, **362**, 340–42.
- OLSEN, B., DUFFY, D. C., JAENSON, T. G. T. *et al.* (1995). Transhemispheric exchange of Lyme disease spirochaetes by seabirds. *J. Clin. Microbiol.*, **33**(12), 3270–74.
- OTTO, C. M., MCCALL KAUFMAN, G. and CROWE, D. T. (1989). Intraosseous infusion of fluids and therapeutics. *Comp. Cont. Ed. Pract. Vet.*, **11**(4), 421–31.
- PALMA, R. L. (1994). New synonymies in lice (Insecta: Phthiraptera) infesting albatrosses and petrels (*Procellariiformes*). *NZ Entomol.*, **17**, 64–9.
- PETERMANN, S., GLUNDER, G., HEFFELS-REDMANN, U. and HINZ, K. H. (1989). Post-mortem findings in guillemots, kittiwakes, herring gulls and black headed gulls found ill or dead in the Heligoland Bight between 1982 and 1985. *Deutsche Tierärztliche Wochenschrift*, **96**, 271–7.
- PIERSMA, T. and VAN EERDEN, M. R. (1988). Feather eating in great crested grebes (*Podiceps cristatus*): a unique solution to the problems of debris and gastric parasites in fish-eating birds. *Ibis*, **131**, 477–86.
- REDIG, P. T. (1996). Nursing avian patients. In: *Manual of Raptors, Pigeons And Waterfowl* (Benyon, P. H., Forbes, N. A. and Harcourt-Brown, N. H., eds), pp. 42–6. (1996). BSAVA.
- RIJKE, A. M. (1968). The water repellency and feather structure of cormorants (*Phalacrocoracidae*). *J. Exp. Biol.*, **48**, 185–9.
- ROERTGEN, K. E. (1990). Avian malaria in oil contaminated common murres (*Uria aalge*). *Wildlife J.*, **13**(3), 3–8.
- SCOTT, M. J., WIENS, J. A. and CLAEYS, R. R. (1975). Organochlorine levels associated with a common murre die-off in Oregon. *J. Wildlife Man.*, **39**(2), 310–20.
- SHARP, B. E. (1996). Post-release survival of oiled cleaned seabirds in North America. *Ibis*, **138**, 222–8.
- SILEO, L., SIEVERT, P. R. and SAMUEL, D. M. (1990). Causes of mortality of albatross chicks at Midway Atoll. *J. Wildlife Dis.*, **26**(3), 329–38.
- STEELE, G. M., DAVIES, C. R., JONES, L. D. *et al.* (1990). Life history of the seabird tick, *Ixodes (Ceratiodes) uriae*, at St Abbs Head, Scotland. *Acarologia*, **31**(2), 125–30.
- STOSKOPF, M. K. (1993). *Zoo and Wild Animal Medicine: Current Therapy* 3. W. B. Saunders.
- STOSKOPF, M. K. and KENNEDY-STOSKOPF, S. (1986). *Zoo and Wild Animal Medicine*. W. B. Saunders.
- SWENNEN, C. (1977). *Laboratory Research on Seabirds*. Netherlands Institute for Sea Research.
- TILLET, D. E., ANKLEY, G. T., GIESEY, J. P. *et al.* (1992). Polychlorinated biphenyl residues and egg mortality in double-crested cormorants from the Great Lakes. *Environ. Toxicol. Chem.*, **11**, 1281–8.
- TSENG, F. S. (1993). Care of oiled seabirds: a veterinary perspective. In: *Proc. 1993 Int. Oil Spill Conf.*, pp. 421–4. American Petroleum Institute.
- WERNHAM, C. V., PEACH, W. J. and BROWNE, S. (1997). Survival rates of rehabilitation. Unpublished report prepared for Sea Empress Environmental Evaluation Committee. SEEEC.
- WHITE, F. H., SIMPSON C. F. and WILLIAMS L. E. (1973). Isolation of *Edwardsiella tarda* from aquatic animal species and surface waters in Florida. *J. Wildlife Dis.*, **9**, 204.
- WILSON, J. E. (1950). Newcastle disease in a gannet (*Sula bassana*). *Vet. Rec.*, **62**, 33.
- WINGATE, D. B., BARKER, I. K. and KING, N. W. (1980). Poxvirus infection of the white-tailed tropic bird (*Phaethon lepturus*) in Bermuda, North Atlantic Ocean. *J. Wildlife Dis.*, **16**, 619.
- WOOD, A. M., MUNRO, R. and ROBINSON, I. (1993). Oiled birds from Shetland, January 1993. *Vet. Rec.*, **132**, 367–8.

# The management of a multi-species bird collection in a zoological park

*Alan Abrey*

## Introduction

The management of multi-species collections, which may include ratites to hummingbirds, is obviously far more complex than that of collections containing single species such as psittacines or gallinaceous birds.

Management and curator staff are required to have a broad knowledge base of aviculture regarding the inter-relationships and compatibility of different species in mixed exhibits, particularly regarding aggression and the competition for nesting sites and food (certain principles must be adhered to in the preparation of food to prevent contamination by organisms that might not be pathogenic for some species but are for others).

Diets containing fish, meat or dog food should never be prepared in the same area of the kitchen as they are dispensed. Utensils used in the cutting or storage of fish, meat and dog food must never be used for cutting up fruit, vegetables or other food products for psittacines and softbills, and after use should be washed and disinfected.

In large aviaries containing mixed collections of seed-eaters and softbills, the keeper should place food that can become contaminated quickly (e.g. meat, fish, soaked dog cubes and fruit) at stations separate from dry seed locations in order to reduce food spoilage. Soiled feeding stations must be frequently cleaned and disinfected to prevent exposure to dangerous sources of infection.

Breeding success can be a direct reflection of good management, particularly with regard to

dietary standards. Frequently, birds on poor diets do not breed. All birds kept at Umgeni River Bird Park are kept in circumstances where they can breed and are given appropriate nutrition, regardless of their commercial value.

The exchange of surplus stock with other zoological institutions or private aviculturists can have a significant positive economic impact on an institution, but it also contributes toward conservation. Conservation benefits because the demand for birds is fulfilled in this way, thereby obviating the need for wild capture. It is also a widely accepted fact that captive-bred birds make far better breeders than their wild-caught counterparts, because they generally breed at a younger age and make better parents.

## Psittacines

### Lories and lorikeets

These are Psittacines forming the subfamily Loriidae, and originate from South-Eastern Asia, Papua New Guinea, Australia and Polynesia. They are referred to as the brush-tongued parrots, because the tip of the tongue has elongated papillae that give it a brush-like tip (Figure 16.1). The tongue's papillae have developed because, in nature, Loriidae collect nectar and pollen from flowers as a significant

Rights were not granted to include this figure in electronic media.  
Please refer to the printed publication.

**Figure 16.1** (a) and (b) Modified tongue anatomy found in the family Loriidae. (From Forshaw, 1973).

part of their diet. Another important dietary element for lorries and lorikeets is fruit. Since Loriidae eat a diet high in sugar, fruit and water, their stool is often very liquid and difficult to clean.

Almost all of the Loriidae are brightly coloured, and this family includes some of the most beautiful birds in the world (Plate 41). Apart from their coloration, lorries and lorikeets are attractive to keep as companion animals because of their positive response to human contact. They are also good breeders and often nest three or four times a year in warm climates, especially if the chicks are removed and hand raised from about 2–3 weeks of age.

### **Housing**

Aviaries suitable for pairs of lorries or lorikeets are 1–1.2 m wide, 3 m long and 2 m high. These birds can also be kept very successfully in suspended cages 1 m × 1 m × 3 m long, which of course are not suitable for display purposes. They are very aggressive when mating, so only breeding pairs should be maintained in reproductive flights.

Nest boxes vary in size from 20 × 20 × 30 cm to 25 × 25 × 50 cm, depending on the size of the lorikeet. Entrance holes are placed 10 cm from the top of the box, and observations indicate that birds prefer holes that are just big enough for them to squeeze through.

Approximately 10–15 cm of coarse wood shavings should be placed in the bottom of the box as nesting material. It should be noted that wood shavings may be a source of bacterial and fungal infections; both *Salmonella* spp. and *Klebsiella* spp. infection have been introduced via wood shavings, possibly due to contamination by rodent faeces or urine. Shavings or any psittacine nesting material

that has been allowed to become damp constitute a serious risk of infecting either the chicks or nesting adults with *Aspergillus fumigatus* or *A. flavus*. It is also dangerous to use shavings from any treated wood, or from timber that has a strong resin content.

Nestboxes should be left in the aviary throughout the year, as lorikeets like to use them for sleep and protection.

### **Feeding**

Lorikeets must be fed artificial nectar and fruits such as apples, pears, grapes, papaya and guavas, with the intake of fruit being controlled. Too much fruit will affect the bird's appetite for the balanced artificial nectar. An exception to this rule is the Musschenbroek's lorikeet, which is mainly a seed eater and consumes small seeds such as millet, canary seed and sunflower.

Lorikeets have become one of the most popular species kept in aviculture, and thus a species that veterinary practitioners will frequently encounter. The availability of balanced commercial lorikeet diets in many countries has contributed to an increase in popularity over recent years. These diets come in the form of dry powder that can easily be reconstituted with water.

Some totally dry diets are available, which have the advantage that they are less likely to sour rapidly, but the author has found that birds are reluctant to accept these dry diets. The birds may take the powder in their beaks and bring it to the water dish. This 'self reconstitution' usually makes for a dirty, messy, sticky environment.

Many home-made nectar recipes provide adequate nutrition. The one fed at Umgeni River Bird Park contains cane syrup, a human breakfast cereal called Pronutro (which has a

22 per cent protein analysis), minerals, vitamins and an amino acid additive, with the addition of water to form the consistency of a thin soup. Zinc bacitracin (50 ppm of dry matter) is added to this mixture. Since nectar is an ideal medium for bacterial and fungal growth, especially in hot weather, the feed dishes and trays must be sterilized.

The cleaning routine adopted at the author's institution begins with the collection and washing of the nectar dishes, which are then placed in a 1:100 solution of Virkon antiseptic (potassium peroxomonosulphate 50 per cent) for 2 hours, after which they are placed in the sun to dry. The food dish trays are also washed with antiseptic before placing previously sterilized dishes on them.

After mixing the nectar, it must always be refrigerated. Fresh nectar is added to the dishes in the afternoon. Lorikeets rarely drink water but, because of their sticky diet, like to bathe regularly; so water baths or mist sprays must be provided.

### **Breeding**

Loriidae usually only lay two eggs, and incubation periods vary from 22–26 days. Chicks leave the nest boxes between 55 and 85 days of age, depending on the species. When there are chicks in the nest the shavings become very wet and soiled, and should be changed every 3–4 weeks. A 1–2 cm layer of old shavings should be placed on top of the new shavings to encourage the parents to return to the chicks.

Baby lorikeets are very easy to hand raise by using nectar manufactured for adults and feeding it using a small spoon pinched at the end to resemble the bottom beak of a psittacine.

### **Pathology**

Common medical problems encountered with lorikeets in this institution have included *Salmonella typhimurium*, *Escherichia coli*, *Klebsiella* spp. and, very occasionally, *Streptococci* spp., *Staphylococci* spp. and *Pseudomonas* spp.

Due to the nature of their diet, lorikeets are prone to *Candida albicans* infections. These mainly affect the mouth and tongue, the corners of the mouth and the crop. Signs noted with *C. albicans* infections include vom-

iting and frequent licking around the mouth. Lorikeets are also prone to superficial dermatomycoses around the corners of the mouth and on the cere and forehead, again obviously due to sugary nectar sticking to the feathers in these areas.

Of the viral diseases, avian viral serositis is occasionally seen in this locality.

Psittacosis in lorikeets has rarely occurred in this institution, probably due to the management practice of keeping adult birds only in pairs and the low incidence of the disease in wild bird populations.

Almost all pathology seen in lorikeets seems to involve the liver and, to a lesser degree, the intestines. Exposure to infectious organisms occurs through food contamination, poor hygiene and management practices, and contamination from rodents.

Recently, trichomoniasis has been a problem among lorikeets at the author's institution. *Trichomonas gallinae* infections have occurred, mainly in young hand-fed lorikeets just prior to weaning or among young weaned lorikeets held in communal aviaries. The main sign associated with trichomoniasis infections is vomiting, as with candidiasis. *Trichomonas* organisms have been recovered from damp swabs of the crop and oesophagus, and the organisms were also found in adult lorikeets showing no clinical signs. There is thickening of the mucosa of the crop and oesophagus and, in some cases, the presence of yellow caseous material. Treatment with nitroimidazole drugs usually gave a satisfactory and reasonably rapid response.

Due to their generally beautiful coloration and their tameness, which often brings them to the front of aviaries, lorikeets have become popular exhibits in many zoological parks.

### **Larger psittacine species**

These include macaws, cockatoos, African greys, Amazon parrots and species such as eclectus, etc.

Although the purpose of any zoological institution is primarily to exhibit birds in a manner that is attractive to visitors and provides environmental enrichment, birds should always be placed in an enclosure where they have the opportunity to breed. Some zoo curators erroneously think the

likelihood of birds breeding in exhibition aviaries in front of thousands of visitors is so remote that it is not worth providing nest logs or boxes. During the past breeding season, eight species of cockatoos and six species of macaws have been bred at the author's institution in aviaries in public view, including the rare black palm cockatoo (*Probosciger aterrimus*), the Major Mitchell cockatoo (*Cacatua leadbeateri*) and the hyacinth macaw (*Anodorhynchus hyacinthinus*).

In large multi-species collections, management and feeding has to be rationalized wherever possible, as it is not practical to cope with minor variations for individual species.

### Housing

Breeding pairs of macaws and cockatoos are housed in aviaries 2 m wide, 6–8 m long and 3 m high. African greys, Amazons and eclectus parrots are kept in aviaries 2 m wide, 4 m long and 2.5–3 m high. At one end of the aviary there is a 2 m covered area with a concrete floor, above which the nest log or box and feed tray are placed. The floor of the rest of the aviary is covered by 10–15 cm of coarse river sand so that it drains well. A mixture of rye grass, oats and sorghum seed is regularly sowed into this sand to give an attractive green cover. This is not just for the sake of appearance, but also affords a diverse environment and diet to counter boredom, as the birds spend hours on the ground digging out the sprouted seeds.

To counteract the possibility of the birds picking up severe worm infestations (particularly *Capillaria* spp.) during this activity, they are dewormed three or four times a year, and regular faecal examinations are part of the management protocol. The top 10 cm of soil is renewed from time to time.

### Feeding

The birds are initially fed a 'vegetable mixture' in the morning. This is made up as follows:

- 1 kg of yellow corn (dry weight off the cob) and 1 kg white sugar beans (dry weight), which are boiled separately and then put through a coarse mincer with 5–6 mm holes.
- 1 kg of a commercial psittacine supplement containing 20 per cent protein, vitamins,

minerals and carbohydrates is then mixed into the minced beans and corn with one loaf of minced, whole wheat brown bread.

- Vegetables in the form of grated carrot, beetroot, spinach, green alfalfa or green peas are also coarsely minced and added to form approximately 20 per cent of the total volume.

The ingredients are mixed together until they form a crumbly consistency, and this mixture is fed in the morning with apple.

Sunflower, oats and sorghum seeds are also sprouted in trays, and a handful is given to each pair of large psittacines along with the vegetable mixture each morning. When sprouting seeds, extreme care must be taken to see there is no fungal growth as this can produce disastrous mortalities from *Aspergillus flavus* and *A. fumigatus*. When the seeds are initially soaked for 24 hours, an antifungal additive should be placed in the water to prevent fungal growth, and the seeds must be washed well before feeding. Each tray of sprouted seed should not be used for more than 2 days.

In the afternoon, by which time most of the vegetable mixture and sprouted seeds have been consumed, sunflower seed is given with peanuts, macadamia nuts or pecans.

Care must be taken not to overfeed with larger nuts due to the risk of obesity and its possible negative effect on reproduction. It is also risky to feed nuts in the shell, because there may be hidden fungal infections; it is far safer to feed only shelled nuts.

Galahs (roseate cockatoos, *Eolophus roseicapillus*) are very prone to obesity, so they need more sprouted seed and vegetable mixture in their diet and only a very small amount of sunflower seed. They are also very fond of canary seed, white millet, and the green feed sprouting on the floor of the aviary.

### Breeding

Cockatoos, amazons, African greys and eclectus parrots require either natural hollow logs or artificial nest boxes made from very hard timber that are approximately 1 m deep and have an internal diameter of about 30 cm. Inspection doors must be provided in the nests approximately 30 cm from the base.

Regular nest inspections must be made during the breeding season at least biweekly, as a dead chick in the nest could cause the loss of the whole brood.

On the base of the nest, 10–15 cm of nesting material is placed in the form of soft wood chips, which the nesting birds may chew up. Care must be taken not to introduce *Aspergillus* spp. spores into the nest by using damp, rotten wood chips.

It is difficult to find sufficiently large hollow logs that come from hard enough wood to withstand the ravages of macaws. In the author's institution, 200 l metal drums can be used. The nest drums are attached to the wall under the covered section in a horizontal position, the top half of one end is cut out to form an entrance, and strips of hard timber are bolted around the outside of the drum. This not only improves its appearance in exhibition aviaries, but also acts as insulating material during hot weather. The bottom of the drum is covered by 15–20 cm of coarse wood chips.

Nesting material, especially for black palm cockatoos, is an important management concern for reproductive success. These birds require branches and twigs which they chew-up and use to fill the nest cavity to about 40–50 cm below the entrance hole. Placing fresh branches such as eucalyptus in the aviary seems to act as a stimulus to nest building and breeding.

Most cockatoo species enjoy chewing-up green branches from trees such as eucalyptus or willow; this probably has psychological benefits rather than providing nourishment.

### **Hand raising**

In the author's institution, most baby psittacines of the larger species are hand raised after being removed from their parents at 2–3 weeks of age. There are now reliable, scientifically prepared commercial parrot-rearing foods available in most countries, and these remove much of the guesswork from hand feeding. Bird breeders must avoid the temptation to add some of their favourite ingredients of past home-made concoctions to 'improve' these diets, as doing so could seriously alter the balance of the diet.

Allowing breeding pairs to raise one brood a year naturally is a practice that may have merit if the birds have proved in the past to be competent parents. Having a pair of birds raise a clutch is the only way in which an aviculturist may assess whether they are breeding a strain of birds that has the ability and instinct to raise young. Often aviculturists mention that they have had to hand raise babies from a particular pair of birds because the parents never seem to be able to raise them beyond a certain age, or because they only raise about 25 per cent or less of the clutch. This does prompt the question of whether breeders should be perpetuating that line of birds at all, but unfortunately, in the case of valuable birds, economics will usually dictate policy.

The author's institution does not routinely remove psittacine eggs for incubator hatching. Past experience has shown that incubator-hatched chicks generally do not achieve the growth rates attained by parent-raised chicks at 10–14 days of age, and they are often not as heavy at weaning as those chicks in which hand feeding started at 2–3 weeks of age. It is accepted that these results pertain to the rearing foods available here, and other breeders may achieve different results with different feeds; however, psittacine eggs are only incubator-hatched by the author in situations such as the death or illness of a parent.

Until 15 years ago, aviculturists in this country generally believed that 'tame birds do not make good breeders'. This has been proven, world-wide, to be a fallacy, and now hand-raised birds are sought for breeding pairs. It is not the effect of hand raising itself that may make the bird a shy breeder, but the way it is treated after weaning. If the young birds are intended for breeding, they should be placed in communal aviaries in groups soon after weaning so that they can socialize with their own species until they are surgically sexed and placed in pairs. The prejudice against tame birds stemmed from the fact that many birds that had been household pets for many years became totally imprinted on humans and lost the natural instincts to bond and mate. However, experience has shown that a fair percentage of these pet birds will finally accept mates and breed if placed in an environment with little human contact.

## Smaller psittacines

These include the pionus and conure species (*Aratinga* and *Pyrrhura*).

These birds are managed and fed in much the same way as the larger psittacines, except that they are housed in aviaries 1–1.5 m wide, 3 m long and 2–2.5 m high.

Nest boxes or natural logs with an internal diameter of 15–20 cm and 30–50 cm deep are used, depending on the species.

The 'vegetable mixture' and sprouted seed plus fruit is given daily as for the larger psittacines, but with *Pyrrhura* spp. and similar sized psittacines, canary seed and white millet is given *ad lib* in preference to unsprouted sunflower seed.

## Protocols for hand raising psittacines

When chicks are removed from their nests, they should be carefully inspected before being placed in the brooder room for psittacines. This physical examination should include observation for discharges around the vent, nostrils or mouth, and ensure the chick is not underweight. If any suspicious sign(s) are noted, the chicks should be placed in a brooder in the hospital rather than run the risk of introducing some infection into the brooder room.

Psittacine chicks must not be reared in a room with baby fruit- or meat-eating softbills or gallinaceous birds because of the risk of food contamination and disease transmission.

The chicks are placed in thermostatically controlled Plexiglas® brooders in a room that must be maintained at hospital standards of hygiene. The room temperature should also be maintained as constantly as possible, particularly in environments where there is a big difference between night and day temperatures.

Facilities for the storage of food (such as refrigerators), the heating of food (such as microwave ovens) and the storage and sterilization of utensils should be attached to the brooder room to prevent movement of open food and utensils to other parts of the zoologic park and the brooder room. Adequate facilities must also be provided for staff to wash and store clean laboratory coats and towels.

The success or failure of any hand-raising operation will depend largely on the staff involved. There are certain essential prerequisites for any prospective baby bird raiser, and these include the following:

- 1 The diligence and dedication required to get up at night to feed the babies at the correct times.
- 2 Acute observation and the ability to detect signs that a chick may be developing a problem as early as possible.
- 3 Being meticulous over matters such as brooder and food temperatures.
- 4 A good understanding of hygiene requirements.

Newly hatched chicks, whether hatched by parent or incubator, are placed on soft tissue paper in small boxes in the brooders at an initial temperature of 33–35°C. For the first 8 hours, small quantities of warm Ringer's lactate solution are administered orally by either a spoon with the end pinched or a syringe, until the chick has passed its first dropping. Chicks from the small species (such as *Pyrrhura* spp.) start getting liquid rearing food as soon as they have passed a normal dropping. Chicks weighing less than 10 g (small conure species such as *Pyrrhura* spp. weigh 5.2–5.5 g at hatching) are fed every 2 hours for the first 6–7 days, while newly hatched chicks of the larger species are fed every 3 hours.

During the second week, the chicks are fed every 3.5 hours. When the pin feathers start to appear, this is reduced to four to five times a day; when the pin feathers are opening, the frequency of feeding is reduced to three times a day. The feeding periods vary according to the species (smaller species need to be fed more frequently) and the individual chick.

If the chick's crop is slow to empty it should not be filled up with food again, because this sign may indicate a problem. In these cases, the hand feeder should administer warm Ringer's lactate and then gently massage the affected area. No food should be fed until the crop has reduced in size and hardness.

With newly hatched chicks, the food is initially fed at a more liquid consistency for 2–3 days and then gradually prepared to the normal consistency. Some species, such as the black palm cockatoo, will refuse to eat if the food is too cold.



The brooder temperature is reduced by approximately 2°C per week, so that by the time the chicks are 2 weeks of age it is 30–32°C. At 3 weeks it is 28°C, and is kept at about that level until the chick has sufficient feathers to be independent of artificial heating. If there are several chicks in one box, the temperature does not need to be as high due to companion warmth.

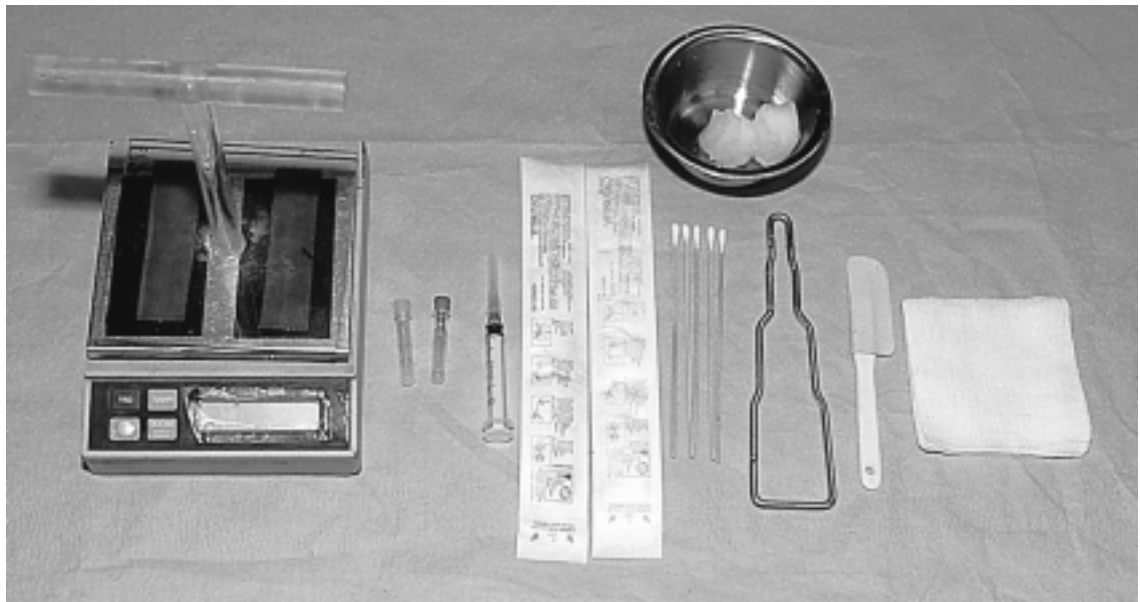A most essential piece of equipment in any psittacine hand-raising facility is an accurate scale (Figure 16.2). The chicks are weighed after hatching and then daily for a few days, and then every second or third day until 12 weeks of age in order to monitor growth rate. The same procedure is used for chicks removed from the parents at 10–14 days old. During the first 2 weeks of life a daily weight gain of 15 per cent is expected; after that stage it usually rises to between 15 and 20 per cent, and is maintained or drops slightly at weaning.

A drop in daily weight gain can be an early warning of some problem, and the following should be assessed:

1 Is the crop emptying properly between feedings and not becoming hard and pendulous?

- 2 Are the chick's faecal evacuations normal (relating the colour to the hand-feeding diet)? The faeces should be voluminous and a pale asparagus green in colour, but not too soft and runny.
- 3 Is the chick in fact passing droppings and not constipated or obstructed? If there are no or scant droppings, first administer warm Ringer's lactate orally. If that does not improve gastrointestinal motility, try a few drops of sunflower oil or, as a last resort, a mild laxative syrup.
- 4 What colour is the chick? If the skin looks unusually red and the beak is open, then the chick may be too hot.
- 5 Is the chick 'tight' and the skin lacking elasticity, appearing dry and wrinkled? If so, it is dehydrated or getting insufficient oil in the diet.

If the crop feels hard and is slow to empty, this could be an indication that the food is being prepared too dry or that there is a bacterial or fungal infection in the crop. Chicks that are raised on coarse wood shavings may ingest some of the shavings, causing similar symptoms to develop. To correct the problem, first rehydrate the chick by administering warm fluids orally and, if necessary, systemically,



**Figure 16.2** Essential basic equipment for avian physical exams includes a digital scale with a Plexiglass® perch.

and then gently massage the crop to soften the contents. Aspirated crop contents should be cultured for bacteria and examined microscopically for fungi. If the cultures indicate the presence of bacteria, it is advisable to perform antibiotic sensitivity testing on the isolate(s). As small chicks are extremely sensitive to disease, it is considered prudent to administer an antibiotic and an antifungal drug promptly while awaiting the results of the laboratory investigations.

In the case of crop impaction due to the ingestion of foreign material such as wood shavings, surgical removal of foreign bodies through the crop may be necessary. Inguvotomies are very successful, even in quite small chicks.

### Hand feeding

There are three ways of administering food to baby psittacine chicks:

- 1 By syringe into the back of the mouth.
- 2 By syringe and tube directly into the crop – this is more suitable for the administration of fluids or medicines than routine feeding, as inexperienced hands can cause crop injuries.
- 3 By spoon, which has the tip pinched in to form a groove.

If there are a lot of chicks to feed, the quickest way is to use a feeding syringe and deposit the food into the back of the mouth. However, the author's institution only hand raises 150–200 psittacine chicks a year, so time is not such a crucial factor. Under these circumstances, feeding by spoon, although the slowest procedure, is the preferred method for the following reasons:

- 1 If a chick is becoming ill and losing its appetite, it will show a reluctance to feed from the spoon; with syringe feeding directly into the mouth, it has no option but to swallow. Often, early disease detection is noted by the hand-feeder when a bird shows a reluctance to eat.
- 2 There is less risk of the bird getting food down the trachea when using a spoon, so it is a safer method for less experienced operators.
- 3 The natural pumping action of feeding is probably easier for chicks when feeding from a spoon than from a syringe.

Any feed that is spilled on the chick's breast or accumulates on the beak or corners of the mouth must be cleaned away thoroughly after each feed to avoid the risk of *Candida albicans* or bacterial infections. Only sufficient food for each feeding should be mixed up at one time, and the balance discarded. It is very risky to keep rehydrated food from one feed to another, even if the mixed food is kept in the refrigerator.

When chicks are sufficiently developed to crawl out of their brooder boxes and sit on top of them, they should be placed in cages with enough room for exercise. At this stage, a little weaning food such as parrot vegetable mixture, crumbly rearing food with a few sunflower kernels sprinkled on top and some boiled corn is placed in a dish in the cage to encourage the chicks to pick at it and learn to feed on their own.

### Handling psittacines

When psittacines have to be removed from aviaries, this is best accomplished with the use of nets resembling butterfly nets (Figure 16.3). When catching birds for routine procedures such as deworming, it is good practice to avoid capture during the heat of the day in order to prevent stress-related injuries.

When catching parrots that are in cages or boxes, use a towel to wrap around the bird so that only the head protrudes. Towels are preferable to using heavy leather gloves, where the operator's feel would be less



Figure 16.3 Light, durable mesh nets are helpful when catching birds in large enclosures.

sensitive and undue pressure may be placed on the bird's chest and abdomen.

## Ratites

### Rheas

Rheas can be kept in groups, preferably in large areas, since they place great demands on the enclosure's environment and vegetation. An area of at least 200 square metres per bird is recommended to prevent the enclosure from becoming a desert.

Although the male rheas display some competitiveness for the females during the breeding season, they are not aggressive birds, either amongst themselves or with other species kept in the same enclosure (such as cranes or waterfowl).

If the intention is to allow the birds to incubate their own eggs and raise their own young, it is acceptable to have a sex ratio of more males than females in the group because it is the males that undertake all the parental duties. The males make shallow hollows in the ground in which they encourage the females to lay their eggs. A normal clutch size is 10–12 eggs, but males can cover as many as 15 eggs and are very protective of their nests. In the author's institution, the policy is to place all rhea eggs in incubators because it has been found that most of the eggs left for parental incubation become rotten. The reason for rotten eggs in South Africa is the fact that rhea's breeding season coincides with the local rainy season. When non-native birds are being maintained as a zoological exhibit, local environmental conditions must be monitored to maintain the breeding success and optimum health.

The eggs are incubated at 36.2°C and turned automatically 48 times a day. The humidity control in the incubators is turned off, as the ambient humidity during this period of the year is more than sufficient for incubation. On the thirty-eighth day, eggs are placed in the hatcher at 36.4°C and turning ceases. The incubation period varies from 38–40 days, but the incubation process is monitored during the whole period by noting weight loss and candling of the eggs.

Many rhea chicks seem to need a little assistance to hatch. If the egg has not hatched

by the fortieth day, and on candling it is noted that the chick has pipped internally into the air sac, a hole 1–2 cm in diameter is made through the shell into the air sac. The chick can be assisted to leave the shell over a 12-hour period, taking care not to rupture blood vessels in the egg membranes.

The adult rheas are fed a commercial poultry breeders' pellet, high in calcium and containing 18 per cent protein, and a mixed poultry grain. They also like a large amount of green food. As with other ratites, care must be taken when raising young rheas that one does not literally 'kill them with kindness' by placing them on too high a plane of nutrition, resulting in too rapid growth, which can lead to osteodystrophia, fractures and deviations at the growth plates. This can occur despite feeding a diet with adequate levels of calcium and phosphorus.

The practice in this institution is to raise the rhea chicks on a poultry broiler crumble with a 22 per cent protein content until about 4 weeks of age, when they are changed onto a pellet diet. If a commercial poultry broiler food is used, it is extremely important to ascertain that this product does not contain a growth stimulant, which will cause rapid growth and result in leg problems. Four times as much green food by volume is given with the crumbles or pellets, in the form of grated carrot and green alfalfa, on which a mineral supplement containing calcium, phosphorus and manganese is sprinkled.

Exercise is also of considerable importance in raising rheas as well as other ratites and long-legged walking birds such as cranes and secretary birds. To make them walk and run as much as possible, they are raised in long narrow pens with a shelter at one end and the food and water at the opposite end of the pen.

Another important requirement in raising baby rheas is gravel chips from 0.5–1 cm in diameter, which are an important aid to digestion. These may be scattered on the floor of their pen, where the young birds can pick them up with their beak.

### Cassowaries

These solid, heavy, wedge-shaped birds with coarse hair-like plumage are well suited to crashing through the dense forests of North-

ern Australia and New Guinea at great speed. They are reputed to be aggressive and bad tempered, and have caused many deaths to humans, both in their natural habitat and zoological gardens. Their method of causing injury is to leap feet first at their victim, slashing downward with their powerful toes and long sharp nails (Figure 16.4).

In captivity, cassowaries need large enclosures and, because they are secretive in nature, undergrowth is required in order to rest and hide. Fencing for cassowaries has to be far more robust than for rheas and emus. These strong birds can easily damage normal fencing with their kicking. From the author's experience, it is very difficult to introduce adult birds even of the opposite sex into one enclosure. For this reason birds often have to be kept singly in adjoining enclosures, and are put together only at breeding time and then separated again when the male commences incubation. The male takes on the entire responsibility of incubating the eggs, which takes 56–58 days, and raising the young.

In the author's bird park, the basic diet for cassowaries is chopped or diced fruit of various types (apples, pears, bananas, melons and grapes) along with grated carrot and soaked dog-food cubes. The birds have also been observed to eat poultry breeders' pellets and insects and rodents that they have caught.

The aggressive nature of these birds prohibits them from being used in mixed collections with species such as cranes.



**Figure 16.4** Handlers must be aware of the dangerous, sharp claws of the cassowary.

## Emus

The natural habitat for this species is the open semi-arid plains of Australia, where they can run at considerable speed over short distances. These birds therefore need spacious enclosures where they can be kept in groups. Caution must be exercised in introducing a strange adult into an established group unless the area of the enclosure is very large.

In disposition, the emu is less placid than the rhea but not as aggressive or bad tempered as the cassowary. Emus can therefore be used in mixed exhibits.

In captivity, emus can be fed the same diet as cassowaries.

Like rheas and cassowaries, the male emu undertakes all parental responsibilities and incubates (for 59–60 days) and broods the chicks.

## Handling and restraint of ratites

Handling and restraint are important aspects when working with adult ratites, as their nervous, fractious natures can result in injuries to both birds and handlers.

Adult rheas may be moved by having two or three curators quietly link hands and closely crowd the birds, or by having one big strong handler straddle the rear of the bird with the arms clasped around the bird's sternum.

This technique is not likely to work so well with cassowaries, ostriches and emus due to their more aggressive dispositions, and would probably result in severe kicks to the handlers. For these birds, the use of permanent or portable crush pens erected in one corner of their enclosures is a safer option. These crush pens must have solid sides to the height of the hips to avoid the risk of birds kicking sideways through gaps, which would probably result in tibiotarsal or tarsometatarsal fractures. Although rheas can be quietly shepherded from one part of the zoological park to another along pathways, this is a risky procedure for cassowaries, emus and ostriches, who invariably panic and race headlong through gardens and fences, injuring themselves in the process. These birds are best moved in crates with sliding doors, which are placed at the end of the crush pen. The birds must not be given too much room in the

crates, as they are less likely to injure themselves if they are slightly cramped.

Placing a hood over the head and upper part of the neck will also help to quiet the birds when in the crush pen or crate. Ostriches may be restrained by grasping the neck and pulling it downwards until the head is close to the ground. This will prevent the bird from kicking the handler.

Where total restraint is necessary, for instance with surgical procedures, anaesthesia is induced by injecting a combination of ketamine hydrochloride and xylazine into the right jugular vein. Anaesthesia is maintained with isoflurane. Birds should be allowed to recover either in a crate or a small room with the floor and lower walls well padded with straw or some sponge material, and in subdued light.

## Health problems

Due to the space requirements and generally aggressive dispositions of ratites, zoological institutions do not maintain many animals – generally only a pair of each species and maybe a small group of rheas. For this reason, the veterinary problems encountered amongst ratites in zoological institutions are not necessarily the same as those found on commercial farms where large numbers of young birds are raised together and there is a far greater concentration of adults.

Over the last 13 years, it has been the author's experience that the three species of ratites kept (rheas, emus and cassowaries) have been remarkably disease-free and healthy. The only bacterial losses experienced were due to *Escherichia coli* enteritis and botulism amongst young rheas during periods of excessive rainfall, which possibly affected the hygiene in the feeding areas. Ninety-five per cent of the problems encountered have been associated with trauma or foreign body ingestion.

Routine dosing of the adult birds for internal parasites twice a year, more often for young birds in groups, has resulted in healthy animals.

### Fractures

Attempts at internal and external fixation of femoral and tibiotarsal fractures of adult ratites

have been disappointing due to the strength and weight of the birds and the difficulties of restraint and support during convalescence.

The prognosis is better with birds weighing less than 10 kg, but even with these patients there is a problem in finding a way to support them until a solid union of the fracture has taken place. Any form of external support that causes inflexibility of the femoro-tibiotarsal joints usually results in the young bird being unable to rise to its feet again if it falls.

The author's results with slinging of young ratites recovering from limb fractures have not been good, but there has been more success with another form of body support using foam sponges. The foam is cut up into 10–15 cm cubes and the bird is placed standing in a wooden or cardboard box that comes to about 15 cm above the height of its shoulders. The foam cubes are then packed in underneath the bird to a height level with the shoulder joint, allowing the bird to lie on the sponges with its limbs extended downwards. Birds have been kept in these boxes for several weeks at a time with food and water suspended at their head, but soiled sponges near the bird's vent must be removed and replaced twice a day. Some birds need to have a form of nylon netting attached to the top of the box and pulled over the back to stop them from pushing upwards, whereas others are quite content to just lie on the sponges.

Wing fractures involving the humerus or ulna and radius are commonly encountered with young ratites. Most wing fractures are a result of rough handling by keepers during capture. As long as the fractures are not open, and good apposition of the ends is achieved, the wing may simply be placed in the normal position and taped to the body for 5–8 weeks depending on the size of the patient. In the case of a compound fracture or where it is difficult to obtain good apposition of the bone ends, it is advisable to use an intramedullary pin in addition to taping to the body.

### Capture myopathy

Extreme care must be taken to limit the movement of ratites, whether adult or young, when capturing them, as stress caused by excitement due to too much chasing around by handlers may lead to injury or death

associated with capture myopathy. Staff must be aware that if a bird starts to show stress, it is better to abandon the mission temporarily, leave the bird in a cool environment and reassess the whole procedure. Signs noted in birds diagnosed with capture myopathy include panting, increased respiratory and cardiac rates, difficulty in rising and walking, lying on the side and kicking followed by morbidity and death.

The use of selenium and vitamin E injections is the suggested treatment, but if severe signs are already apparent the treatment will yield limited success. When ratites are being transhipped to other destinations, requiring a several-hour layover in crates, a prophylactic injection of selenium and vitamin E may have some benefit.

## Flamingoes

Flamingoes must certainly be one of the world's most beautiful and elegant species, and they form one of the most important exhibits in any zoological garden. Six species of flamingoes exist, and this institution keeps three of them.

They are very gregarious birds, and like to be together in relatively large numbers. This gregarious nature can produce problems when sick or injured flamingoes need to be removed from the flock and hospitalized. Isolated birds may become depressed and their health condition steadily declines, even if there appears to be no medical explanation. For this reason it is now the policy in this institution that if a flamingo has to be isolated in the hospital or recuperation area, one or two other birds are utilized for psychological therapy.

Flamingoes spend most of their lives in or near water, therefore allowing a relatively small enclosure size compared to that needed for other species of birds with comparable population densities.

The ponds do not need to be very deep – 30–40 cm in the deepest part and sloping up very gently at the edges to minimize injury to feet and legs. As flamingoes spend a great deal of their lives standing in water, the contamination of the water by faeces is con-

siderable. When planning and building flamingo ponds, it is therefore essential that the ponds can be cleaned out at least twice a week with relative ease. The ideal situation is to have a continual flow of water through the pond.

### **Feeding**

Flamingoes have a unique bill structure and method of feeding. The bill is bent downwards about halfway along its length, and when feeding the bill is in an upside-down position with upper bill just below the surface of the water and the lower bill about level with the surface. Lamellae line the edges of the bill and correspond with similar projections on the tongue, and the birds feed by filtering the top layer of the water with a pump-like action and forcing the water through the lamellae. Their natural food is algae, insect larvae, small crustaceans such as brine shrimp, protozoa, and other fine aquatic plants.

Due to this method of feeding, foods fed in captivity must be very finely milled. If this is not done and a commercial poultry mash is used as the base of a flamingo food, a large amount of grain particles such as corn will be filtered out and not ingested.

In the author's institution, three separate flocks of greater, lesser and Caribbean flamingoes have been successfully maintained and bred on a diet consisting of eight parts of a commercial broiler starter mash with a 22 per cent protein content and one part of dried fish meal, which gives a final analysis of 25 per cent protein. Initially a ration containing the same ingredients but in proportions giving a 30 per cent protein level was used, but several cases of visceral gout were encountered after some time. In a dietary reassessment, the protein level was reduced. No visceral gout cases have occurred since the diet change.

Flamingo diets are available that contain natural products such as ground-up shrimp and green food to replace the algae. These additions would undoubtedly improve the ration, but expense is an important consideration when maintaining over 160 birds. An additional cost to consider is the extra labour involved in food preparation.

To maintain a good colour in captivity, flamingoes must be fed Carophyll Red in their diet at a level of 1 g of Carophyll Red per five birds per day. This can either be incorporated into the feed at mixing, or simply dissolved in a jug of water and poured into each food dish over the food (Plate 42).

Natural products such as paprika and liquidized carrots and beetroot can be added to flamingo diets to improve the birds' colour, but very large amounts would have to be used to totally replace the Carophyll Red in the diet. The food is given in the consistency of a thin porridge in 15 cm deep dishes, and these must be replaced with clean ones each day.

The positioning of the feed dishes is of some importance, not only because of food wastage but also because of the maintenance of hygiene. Flamingoes have a natural habit of stamping with their feet when feeding in order to disturb the food organisms in the mud. If the feed dishes are placed on the ground near the pond, the flamingoes tend to stand in the dishes and stamp while feeding. This not only causes a lot of food wastage when they step out of the dishes, but also contributes to an unhealthy area surrounding the dishes. In this zoological institution, the feed dishes are about 5 cm above the water level. The birds now stand in the pond while feeding and stamp their feet, but do not climb into the feed dishes.

On several occasions the author has had to treat wild-caught birds for various reasons, such as injury or abandonment of young. These birds must not be placed in a large area where there is a pond, or they will spend their entire time trying to feed in the clear water and not go near the food dishes. Such birds should be placed in small enclosures where the only water available has food, until they learn to recognize the feed. Placing a few tame birds with the newly acquired specimens will help the birds to adapt to their new surroundings.

### **Breeding**

In order to breed, flamingoes need to be kept in relatively large groups with an approximately equal number of male and female birds. The generally accepted minimum flock size required for breeding is 20 birds. It is necessary to provide a nesting area with a mud bottom close to the concreted pond. The

soil is removed from this area to a depth of 25 cm, and 5–10 cm of clay then is placed over the floor so that it will retain water. To save the birds some effort and time, clay is mixed with soft grass and grass roots and mounds are made approximately 30 cm in diameter, 30 cm high and about 1 m apart over the whole nesting area. Coarse salt is then sprinkled over the whole mud pond, which is filled with water to a depth of 10–15 cm. Short pieces of soft grass and roots are scattered in the water and around the edge of the pond. The birds then use their beaks to pack the clay and grass pieces onto the existing mounds to create a crater-shaped nest, which in the case of the Caribbean flamingoes can be 40 cm in diameter and 40 cm high. Water must be added to the mud pool every few days, as well as clay and grass, until nest building is complete.

Just before the breeding season flamingoes become very noisy, and display while quarrelling over nest sites. This display takes the form of 'head flagging', when the birds twist their heads from side to side in jerky movements, and 'flashing', when they quickly extend their wings downwards or above their backs to expose their pink covert feathers and black primaries.

A single egg is laid on top of the mound, and both sexes assist in the incubation. The chick takes 28–30 days to hatch, and thereafter spends 5–7 days in the nest. The chick is fed a secretion, initially red but later straw-coloured, from glands in the upper digestive tract of the parents. The adults can be seen dribbling this secretion into the open up-turned mouth of the chick, whose bill is still straight at this stage. The chicks grow quickly, but in captivity they are still seen being fed by their parents at 4 months of age.

### **Pathology**

Although flamingoes often quarrel amongst each other, in 10 years' management of a flock of over 160 birds the author has not recorded a single instance of injury to a bird by one of its own kind or to any other species in the same enclosure. For this reason, flamingoes are well suited to mixed exhibits with other species.

Flamingoes are very long living, both in the wild and in captivity. The author has found them to be remarkably disease- and internal

parasite-free. With wild-caught, imported birds in quarantine, the problems encountered have been enteritis from *Salmonella typhimurium*, *E. coli* and *Klebsiella pneumoniae*. In the case of *K. pneumoniae*, the bacteria was isolated from liver cultures where a haemorrhagic enteritis had been present. Aspergillosis has also occurred in some of the imported birds in quarantine. None of the above diseases have been a problem in the author's institution's flocks, and this is really a reflection on the unsatisfactory conditions under which birds were held prior to export from their country of origin.

Apart from visceral gout, which occurred when the flamingo diet was too high in protein, the few problems encountered with flamingoes have been associated with the legs. Bumblefoot periodically occurs and usually necessitates surgical intervention.

The most common fractures have been tibiotarsal fractures and epiphyseal fractures of the femoro-tibiotarsal joint. Tibiotarsal fractures are frequently compound fractures and have a very poor prognosis due to vascular compromise to the limb distal to the fracture site. Generally fracture repairs in flamingo legs have given disappointing results, as the legs are so thin and delicate. Even if reasonable apposition of the fracture ends is achieved by either external or internal fixation, post-operative restraint and support presents a problem because flamingoes do not take kindly to slinging or isolation. If they are being hospitalized in a situation where they cannot get their legs in water, it is important to sponge down their legs twice a day to prevent the skin from becoming excessively dry.

The author has seen flamingoes released after being held for some procedure (such as pinioning or cutting primaries) rush away and then stumble and fall headlong, resulting in fractures in the proximity of the femoro-tibiotarsal joint. To minimize the risk of this happening, the patient should be walked into the pond by the handler and released into the water.

## Gallinaceous birds

### Housing

Peafowl, pheasants, partridge and Guinea fowl are kept in pairs in well-planted aviaries

5 m wide, 7–8 m deep and 3 m high. For exhibition purposes, compatible species such as mynahs, pigeons and jays are exhibited with the pheasants in order to provide some interest in the top section of the aviary. Care must be exercised in choosing suitable soft-bills (e.g. non-egg eaters) to live with the pheasants.

Guinea fowl may be kept in flocks, because there is only mild aggression between competing males during the breeding season. Pheasants, on the other hand, cannot be kept in groups except as juveniles. At the onset of the breeding season, male pheasants will fight to the death over hens and territory.

Most pheasant species, such as the eared pheasants, peacock pheasants, great argus, monals, fireback pheasants, tragopans and Kalij, are best kept in pairs. Some species, such as golden, Lady Amherst's, Reeves' and silver pheasants, may be kept in trios. The common ringneck may be kept in groups of one cock to four or five hens.

Indian peafowl and Javanese green peafowl can co-exist in groups until the breeding season, at which time the males will start fighting. Breeding peafowl should be separated in smaller groups of one male to three or four females. Peafowl are very tolerant of other non-gallinaceous bird species, making them an excellent bird to be used in mixed exhibits with flamingoes, cranes, waterfowl and rheas.

The floor of aviaries housing gallinaceous birds should be covered with 10–15 cm of coarse river sand into which seeds such as rye grass and oats are regularly planted to provide green food for birds. Being a coarse sand, it dries out rapidly and hopefully desiccates worm eggs quicker than a substrate that retains moisture. This soil should be replaced several times a year.

### Feeding

During the breeding season, the gallinaceous birds are fed a commercial poultry breeders' pellet containing 18 per cent protein and a high level of calcium. In addition, minerals are supplied in the form of oyster shell grit, ground-up eggshells and cuttlefish bone. A small amount of green food in the form of lettuce, cabbage, spinach, green alfalfa or just succulent green grass is supplied daily.



During the non-breeding season, 50 per cent of the pellets are replaced by a mixed poultry grain that includes crushed corn, oats and sorghum. Certain gallinaceous birds deserve special mention, such as the crested wood partridge (*roul roul*) and the peacock pheasants. In addition to the standard diet for gallinaceous birds, *roul rouls* should be given chopped-up fruit daily and a few mealworms. Palawan peacock pheasants also require some live food to obtain good breeding results.

### **Breeding**

When breeding starts, eggs are collected daily and stored on trays in an air-conditioned room where they are turned twice a day. No eggs are kept longer than 5 days before being placed in incubators.

If during the rainy season eggs are brought in dirty, it is advised not to wash them. Washing dirty eggs may enhance bacterial migration through the shell pores, infecting the developing embryo. Rotten eggs usually explode in the incubator at some stage during incubation, thereby spreading the infection throughout the incubator. With a dirty egg, it is preferable to allow the mud to dry and then dry brush it to remove as much of the dirt as possible before dipping the egg in a chlorhexidine solution or similar suitable antiseptic. It is a good routine to dip all eggs in such a solution after collection and before being placed in the incubators whether they appear dirty or not. Any egg-dipping solution should be slightly warmer than the egg temperature, again to prevent contamination across the eggshell.

For routine disinfection of incubators between egg settings or after a rotten egg has exploded in the incubator, 45 ml of formalin should be added to 30 g of potassium permanganate for each cubic metre of incubator space and the mixture placed in a container in the incubator.

Most gallinaceous birds' eggs are incubated at a temperature of 37.5°C and a humidity of 29.5°C wet bulb, but certain species such as fireback pheasants require a slightly higher humidity (30.5°C wet bulb).

The eggs are turned 48 times a day automatically, and 48 hours before hatching the eggs are placed in a hatcher, at which time turning ceases. During the incubation period, all eggs are regularly weighed and candled so

that infertile eggs or eggs showing embryonic death may be removed.

With valuable eggs, the weight loss is plotted on a graph to compare with a normal 14–15 per cent weight loss until 48 hours before hatching. If the weight loss is excessive the humidity in the incubator will have to be increased, and *vice versa*. Most pheasant eggs hatch between 22 and 28 days, but some, like the palawan and grey peacock pheasants, hatch after 18 days.

After hatching, the chicks are left in the hatcher for 12–18 hours to dry off and are then placed in brooders on coarse wood shavings. A 250-W infrared bulb suspended about 30 cm above the floor provides heat for the chicks. This should be placed at one end of the brooder so that there is sufficient space to allow the chicks to move away from the lamp should they become too hot, as overheating produces several stress-related problems.

Should a large number of fully developed chicks not hatch, or a high mortality of chicks within a few days of hatching occur, bacterial cultures should be taken from the chicks' internal organs, including the yolk sac. Cultures are also taken from equipment, including the inside of the hatcher and incubator, and a random sample from the external surfaces of eggs being incubated.

Severe mortality may occur in young gallinaceous chicks as a result of:

- 1 Dietary problems – starter rations that are too low in protein may lead to cannibalism, which takes the form of pecking around the toes, wing tips, vent, cere and the base of the beak.
- 2 Brooder temperatures – if chicks are noticed to be huddled in the corners of brooders, this is an indication that the brooder temperature is too low and chicks are feeling cold. On the other hand, overheating also produces stress if the chicks cannot move away from the heat source to a comfortable temperature. This also can bring on cannibalism.

Overcrowding is probably the prime cause of cannibalism in chicks. If cannibalism is noticed in a batch of chicks, remedial measures must be taken immediately before it becomes a vice throughout the group. Any of the causes of cannibalism mentioned above must be corrected and instigators in the batch isolated. If the instigators are too numerous,

the entire group will have to be 'de-beaked' (approximately 20 per cent of the beak is snipped off). Any bleeding is easily controlled with the use of a styptic solution. If cannibalism is taking place, a small bunch of green food (such as lettuce or spinach) should be tied together and hung just out of reach of the chicks so that they have to jump up to peck at it. This provides a diversion, exercise and nourishment.

Chicks should be fed a 28–30 per cent starter crumble or mash during the first week of life. In nature, their initial diet is almost entirely insectivorous. After 1 week the ration should be gradually changed to a 22 per cent protein broiler starter crumble. Some chicks, such as palawan peacock pheasants and roul rouls, may need encouragement to develop feeding skills. To teach feeding skills, some termites or mealworms (cut into very small pieces) should be scattered on top of the starter mash for a few days and the keeper should scratch around in it with something like a pencil to attract the chick's attention.

The chicks are moved to outside brooders at about 2 weeks of age, where they have access to a run. Heat must be provided at night for another 1–2 weeks, depending on prevailing weather conditions.

## Health problems

In the author's institution, the main veterinary problems encountered in gallinaceous birds have been included:

- 1 Internal parasites – *Heterakis gallinarum*, *Syngamus trachea*, *Capillaria* spp. and, of far lesser importance, tapeworms. A deworming program using mebendazole by gavage and ivermectin by injection has been effective in keeping the internal parasites under control. Where cestodes have been encountered, niclosamide by gavage has been used with good effect.
- 2 Histomoniasis – this has occurred sporadically in isolated areas, causing severe mortality. Postmortems have shown typical hepatomegaly with prominent necrotic foci. Metronidazole has been used in any groups of birds where *Histomonas meleagridis* has been diagnosed. The affected birds are

immediately moved onto cement floors until the outbreak is under control.

- 3 Pox – this has been a very rare and minor problem, causing some temporary morbidity but no mortality.
- 4 Bacterial infections caused by *E. coli* and *Salmonella* spp. have been very isolated and sporadic.

## Hornbills

This family, the Bucerotidae, only occurs in Africa and Asia. Hornbills vary in size from 30 cm to over 1 m in length, and in general do not have bright body colours, being a combination of black, white, brown and grey. Usually it is their beaks that are colourful, and many species have large casques on the top beak, often extending above the level of the head. The head and neck regions frequently have interesting patterns and colours. Hornbills are also noted for their long eyelashes.

They feed on a variety of fruits, berries, nuts, insects, rodents, small mammals, eggs, reptiles and birds. Ground hornbills are entirely carnivorous and insectivorous, and may walk up to 10 km daily in their search for food.

Probably the most remarkable feature about hornbills is their breeding habits. All breed in hollow trees, and the female of all species except ground hornbills becomes walled into the nest chamber after she has laid the eggs. This is done mainly by the female, but with some assistance from the male, using faeces, food, clay and saliva, all of which become very hard, leaving a narrow slit through which the female and the babies are fed until the latter are about 3 weeks old. This is obviously a defence mechanism against predators.

When the chicks are about 3 weeks old, the female breaks out of the nest and assists the male with the continued feeding, although at this stage she may be quite scruffy and not able to fly well. The chicks in the meantime reclose the hole until they have developed sufficiently to be able to fly. Both the female and the chicks defecate through the slit, but while chicks are very young the female will be seen to drop their faeces and food residues through the slit to the outside.

In captivity hornbills are fed a variety of chopped up fruits such as apples, bananas, pears, guavas, grapes and papaya, and soaked dog-food cubes. The dog-food cubes must not be allowed to get too soft because, in order to feed, hornbills toss the food particle in the air, then open the beak and allow the particle to drop to the back of the throat for swallowing. When they have chicks, a protein supplement is sprinkled on the food and strips of ox heart are also placed on top of it.

Ground hornbills have a basic diet of dead day-old chicks plus rodents and snakes when available. It has also been observed that they are very fond of any wild birds, such as sparrows and doves, which are unfortunate enough to find their way into the enclosures.

Several years ago the author was asked by Dr Alan Kemp to assist in a research project to raise sibling ground hornbill chicks from the Kruger National Park. Ground hornbills usually have two eggs, which hatch 3–5 days apart. The second smaller chick never survives, as it is 'out-begged' by the larger chick, which takes all the food so the smaller one dies before it is 5 days old. Researchers had been trying to raise these sibling chicks with natural foods such as grasshoppers, mealworms, scorpions, etc, but most of the chicks died from gastrointestinal obstructions resulting from undigested insect skeletons between at between 5 and 7 days of age.

After receiving advice from the San Diego Zoo, the author fed five 1–2-day-old ground hornbill chicks from the Kruger National Park with chopped up 'pinky' mice and geckos and small strips of ox heart with vitamins and minerals sprinkled on top. All five chicks survived and were successfully raised. It is difficult to understand why, in nature, when these same insects are fed to the chicks by their parents obstructions do not arise and the exoskeletons of the insects are obviously passed.

The chicks were placed in separate boxes in the brooders at 32°C and fed every 3 hours. The food particles were warmed and moistened by dipping them into warm Ringer's lactate solution initially and then fed to the chicks using forceps. The consistency and frequency of droppings was monitored very closely and at the first suggestion of constipation, only fluids such as beef extract with Ringer's solution were given until the droppings

appeared normal again. As the chicks grew older, the food particle size became bigger and included chopped up snakes, rodents, geckos and pieces of day-old chicks (with the skin removed) with mineral and vitamin supplementation.

This chick-raising procedure was used very successfully on subsequent hornbill chicks and other carnivorous birds such as kookaburras and ibis, where insect skeletons have also caused obstructions in young chicks.

Hornbills are both mischievous and aggressive birds. The larger Asian species can only be kept in pairs if a serious breeding programme is being established. Ground hornbills may be kept in family groups if introduced together at a young age. A dominant female is less likely to tolerate other females in the group than a dominant male to tolerate subservient males.

The smaller hornbill species may be exhibited in large walk-through aviaries or in mixed collections, but are not above killing smaller species if the opportunity presents itself.

Hornbills have proved to be tough, long-living birds with few medical problems. A few cases of aspergillosis have been diagnosed. These fungal infections may have been associated with contaminated fruit.

Most zoological institutions have rodent extermination programmes where the use of warfarin poison is routine. It is not advisable to use anticoagulant products in the vicinity of hornbill aviaries. If poisoned rodents can get into the hornbill enclosures this extermination policy should not be used, since these birds have died from eating affected rats.

## Toucans

The family Ramphastidae, which includes toucans, toucanettes and aricarais, is native to an area that extends from southern Mexico through Central and South America to northern Argentina. Their natural habitat is rainforests, where they fly from tree to tree in their quest for food. Generally they are seen in small family groups of two to five individuals, but the author has seen flocks of Toco toucans in the rainforest around Iguazu Falls in Brazil numbering over 20 birds.

Toucans are intelligent and interesting birds whose unusual beak shape, beautiful colours

and continual activity make them a highly desirable species for zoological institutions. The larger species are basically black in colour, with white, yellow or red breasts, some with transverse colour bands. Red patches under the tail in the vent area are also common to several species, as well as an area of blue surrounding the eyes. The primary physical characteristic that makes the members of this family so distinctive is their incredible beaks. Although the beaks are large, they are very light and strong due to their internal support matrix. Usually the beaks are extremely colourful, featuring amazing combinations of streaks, patches or dots, such as are found in keel-billed, channel-billed, Swainson's and spot-billed toucanettes, among others.

### **Housing**

Toucans should be kept in large, well-planted aviaries for exhibition purposes. These birds are most attractive when viewed actively moving in attractive vegetation. In this institution, pairs live in aviaries 4 m wide, 7 m deep and 3 m high, which affords them ample room for exercise, and have a covered area 2 m deep at one end, under which the food and nest log are placed.

### **Feeding**

In nature, toucans feed on a wide variety of fruits, berries, eggs and baby birds, reptiles, insects and small rodents. In captivity, fruit such as papaya, pears, guavas, apples, melons, peaches and grapes may be used, diced into 1 cm pieces. Citrus fruits are not recommended as ramphastid food, as they are acidic and reputed to increase the absorption of iron. In addition to fruit, a concentrated food in the form of a dog kibble or cube that has been lightly soaked is also given. Like hornbills, toucans toss the food in the air before opening their beaks and allowing it to drop into the back of the throat for swallowing, so they are unable to handle food particles that are too soft and mushy. Diced vegetables such as beet and carrots may also be included in the toucans' diet.

Along with birds of paradise and mynah birds, toucans are extremely prone to haemochromatosis (iron storage disease). Haemochromatosis was responsible for the death of

most of the toucan population in this country before veterinarians learned about the problem. If no suitable commercial extruded or pelleted toucan diet with a low iron content is available, it is vital to select a dog kibble or cube with an iron content of less than 80 ppm (less than 60 ppm if possible).

### **Breeding**

Toucans prefer natural logs for nest locations rather than artificial nest boxes of the type used for psittacines species. For the larger toucans, a log approximately 1.2 m deep with an internal diameter of 25–35 cm is suitable, whereas for toucanettes and aricaris a log 60–80 cm deep and 15–20 cm in internal diameter is adequate. The birds prefer a side entrance to the log, just large enough for that particular species to enter, with a wire ladder down from the entrance to about 25 cm from the bottom. Toucans do not like nest material in the log, but prefer a dish-like hollow in the base of the log in which they lay their eggs.

The Ramphastidae are not easy birds to breed, and breeding requires more effort and expertise than in other species such as psittacines. Naturally, lucky opportunistic breedings occur in zoos and private collections, but regular large-scale reproduction of toucans requires attention to detail for success. One management area that needs close monitoring is the dietary requirements of parents feeding young.

In the author's institution toucans have laid eggs and sat, but none have raised young. The infertility problem may be due to a lack of sufficient live food (e.g. mealworms, crickets and 'pinky' mice).

The incubation period for toucans is 16 days, and the chicks fledge at 7–8 weeks.

### **Health problems**

The main problem encountered in toucans has been haemochromatosis, possible due to the difficulty in finding a suitable concentrate diet.

Very few ante-mortem diagnoses have been observed with confirmed haemochromatosis-related deaths. Most cases have involved a keeper picking up a dead bird, despite food having been consumed in the previous 24

hours. All postmortems consistently indicated that the birds were in good bodily condition, but had enlarged, mustard-coloured livers. Histological examinations confirmed the presence of iron in the liver and quantitative test results for iron were between 1500 and 3000 ppm, ten times the normal value.

In this author's experience, internal parasites do not cause health problems in rhamphastids. This may be due to the arboreal nature of these birds. Overall, the toucans have been healthy and seem to be well protected against most infectious diseases. Two birds died at the author's institution from a haemorrhagic enteritis. Bacterial examination of the gut contents isolated *Clostridium welchii*.

## Ibis

The author's zoological institution keeps five species of ibis; scarlet, bald, glossy, Hadededa and sacred.

### Scarlet ibis

These are housed in a very large walk-through aviary with a marsh-type environment. Scarlet ibis spend a considerable amount of time digging in the mud with their long, thin beaks and on the water edges looking for food organisms. The food shelter should be within a few metres of the edge of the ponds to allow the birds to take food particles and dip them in the water before swallowing them. They have also been observed catching small fish, frogs and tadpoles in the ponds. The diet supplied to scarlet ibis consists of soaked dog-food cubes and chopped fish, sardines and ox heart. In order to maintain the brilliant red colour of this species, it is necessary to sprinkle Carophyll Red onto the soaked dog cubes and allow it to soak in, at the rate of 3 g per 20 birds per day.

For nesting, wire platform baskets 10 cm deep and 30 cm in diameter are attached to trees 4–5 m off the ground. Coarse grass and thin sticks are used for nesting material. Ibis breed readily, and prefer to nest in colonies where the nests are grouped together about 1.5–2 m apart. Both sexes share incubation duties, which last for about 24 days. Normally two or three eggs are laid.

### Glossy ibis

These birds also like wetland conditions and may be managed in the same manner as scarlet ibis, except they do not require Carophyll Red in their diets. They also breed in colonies using platform nests with coarse grass and twigs, and have a similar clutch size and incubation period.

### Bald ibis

The natural habitat of these birds is cliff faces, preferably in the vicinity of waterfalls. In this institution, bald ibis are maintained in a large walk-through aviary that includes a 12-m high natural cliff face and an artificial waterfall.

Their diet consists of soaked dog-food cubes and pieces of ox heart or other types of meat on which a vitamin and mineral supplement is sprinkled, particularly when they are breeding. These birds are often found on the ground foraging for insects, worms, snails, frogs and small reptiles.

Bald ibis breed in colonies, creating flimsy platforms of sticks on the cliff ledges. Clutches average two eggs, and the incubation period is from 25–28 days with both sexes sharing the duties of incubation and feeding the chicks. At this institution, bald ibis are usually given the opportunity to raise their own young.

No aggressive tendencies have been noted among the above ibis species, either towards each other or to other avian species maintained in the same mixed collection.

Remarkably few health problems have been encountered involving the ibis colonies, apart from a few isolated cases of visceral gout diagnosed in scarlet ibis. The birds are dewormed regularly using mebendazole added to the food, because it is an extremely difficult task to catch birds in the large walk-through aviaries.

### Sacred ibis and Hadededa ibis

These are free ranging in the park. The former live in flocks, whereas the latter are usually found in pairs or small family groups. Sacred ibis are seen helping themselves to dead day-old chicks, fish and soaked dog-food cubes fed to other avian species such as storks, and

also feeding from the dishes of flamingo food. Hadedas are almost entirely insectivorous, and at times are noticed taking soaked dog-food cubes and pieces of chicks.

Both species breed in the park on platform nests; the sacred ibis can become a nuisance due to fouling the environment in the vicinity of the colony.

On two occasions sacred ibis have been found either dead or in extremis. A diagnosis of botulism was made on the affected birds, but unfortunately the toxic condition spread to some waterfowl before it was contained. There are a number of hazards faced by keepers of avian species that are free ranging within a park setting.

## Roseate spoonbills

These are kept in the same aviary and treated in exactly the same manner as scarlet ibis, with whom they have a very compatible existence.

## Cranes

These elegant, handsome birds form an important exhibit in any zoological collection, but there are management problems. Most crane management problems relate to their flighty natures, and cranes are often referred to as 'accidents waiting to happen'.

This park keeps six species of cranes, three indigenous species (the blue crane, the wattled crane and the South African crowned crane) and three foreign species (the Sarus crane, the white-naped crane and the Demoiselle crane). Of these, the three South African species and the Demoiselle cranes have been successfully bred, whereas the other two species have laid infertile eggs.

Cranes are best kept in pairs in grass enclosures approximately 10 × 20 m in area. The goal of having a crane pen this size is to optimize breeding results and minimize problems associated with an aggressive nature. The enclosure fencing must be at least 1.5 m high, preferably 1.8 m, to prevent wing-clipped or pinioned birds from climbing over. It

must be remembered that the average crane stands at a very convenient height to peck at children's eyes, and this can happen quickly with very dangerous consequences.

Experienced researchers claim that pinioned or wing-clipped male cranes have a lower fertility than full-winged birds, but the author has not had the opportunity to substantiate this opinion. Perhaps it is not so much the fertility as the act of copulation that is affected, perhaps by imbalance of the wings. However, if this is a concern, the enclosure fencing will have to be made higher and a nylon shade cloth or large aperture bird netting stretched on top. For aesthetic reasons, most zoological institutions would probably not build a totally enclosed crane pen and would aim, wherever possible, to incorporate the birds into mixed exhibits with other species.

From the author's experience, it is very risky to put larger crane species such as wattled or Sarus cranes into mixed collections. During the breeding period large crane species become aggressive, not only to other species but also to curators. These birds may live in a mixed exhibit of birds such as waterfowl and flamingoes for some time with no apparent problems, and then suddenly turn on a bird such as a flamingo and kill it.

Demoiselle cranes are very gentle and may be kept in a group of two to four pairs. These cranes may be maintained in a mixed collection exhibit with species such as flamingoes and waterfowl if the enclosure is of a reasonable size.

Crowned cranes and blue cranes may also live together in groups of two or three pairs, combined with other avian species such as storks and flamingoes if the enclosure is large enough. These cranes need some privacy at nesting time to ensure breeding success. Occasionally aggressive individuals will be noted, and these must be removed from mixed exhibits.

The adult cranes are fed a commercial poultry breeder pellet with a 22 per cent protein analysis and a mixed poultry grain containing mainly corn and sorghum. With the approach of the breeding season, the grain component is eliminated and only the pellets are fed. In mixed exhibits, it is impossible to restrict cranes' feeding. Birds have been observed feeding in the flamingo food dishes, helping themselves to soaked dog-food cubes

and even ingesting day-old chicks. They also catch a certain number of insects, small rodents, frogs and tadpoles. The self-generated diet is desirable, as the overall protein analysis should be higher than 22 per cent at breeding time.

The nesting habits of cranes vary considerably: wattled, crowned and Sarus cranes build grass mounds up to 20 cm high; Demoiselle cranes make virtually no nest but select a bare piece of ground where they gather a few small stones to place around the eggs; blue cranes make a very shallow nest in grassland then gather a small amount of grass around the eggs.

Cranes lay either one or two eggs, and have a wide range of incubation periods from 27–30 days for Demoiselles to 35–38 days for wattled cranes. Many crane species will successfully hatch and rear two chicks, but the wattled crane abandons the second egg after the first chick hatches. Parent birds have been allowed to hatch all four species bred in this park, but due to the presence of many winged and ground predators, such as spotted cats, the survival rate has been poor. There is now a policy to remove some eggs for hatching in the incubator or remove the chicks if they are parent-hatched.

Eggs are incubated at 37.5°C with a wet bulb reading of 30–30.5°C, in a horizontal position, and are turned automatically every 30 minutes. Forty-eight hours before hatching, the eggs are placed in a hatcher at a high humidity, and turning ceases. Frequently the hatching process will take another 48 hours from the onset of external pipping before the chick is out of the shell.

After hatching, the chick is left in the hatcher for about 12 hours to dry off before being placed in a brooder at a temperature of 32–35°C. A suitable covering for the floor of the brooder is required to prevent leg injuries. Wood shavings or a coarse river sand has worked well for crane chicks.

Although small crane chicks can be very aggressive and peck each other to death, a single chick can get very lonely and depressed. In these situations, it can be very comforting to the crane chick (and indeed gallinaceous birds) to hang a feather duster near the heat source in the brooder. Chicks will be seen to stand between the feathers of the duster.

The chick will not eat for the first 24–36 hours while the yolk sac is being reabsorbed. The starter feed used for crane chicks during the first 7–10 days is a 1:1 mixture of 22 per cent broiler starter crumble with soaked dog-food cubes crushed into a crumbly consistency. Only a small amount of this food is mixed at one time, to prevent the risk of souring. Small mealworms are sprinkled on top of the food, as well as thin strips of ox heart cut to the size of mealworms. The movement of the mealworms attracts the chicks' interest. Food attraction can also be accomplished by scratching around in the food dish with a pencil or piece of wire to draw the chicks' attention to the contents.

When the chick has started to feed readily, a vitamin and mineral supplement is also added to the food mixture. After about 10 days of age, the diet is gradually changed to the straight broiler starter crumbles and then the pelleted form.

Care must be taken that the chick does not gain weight too rapidly or that the commercial broiler starter feed does not contain a growth hormone. If the growth rate becomes too fast, lateral deviations and rotation of the legs occurs, ultimately causing an inability to walk. The author has experienced the above problem with blue crane and wattled crane chicks when the food supplier changed the formulation by adding a growth hormone to the ration. As soon as the lateral leg deviations were noticed, the tibiotarsal/metatarsal joints were bandaged using elastoplast so that there was still movement of the joint. A strip of thick elastic rubber was incorporated in the bandage in the medial aspect of the joint, allowing tension to pull the leg inward distal to the joint. The bandages were changed and tightened weekly, and over a period of about 6 weeks the lateral deviation was corrected.

At this institution crane chicks are not in a release programme. To strengthen their legs, from 3 weeks of age the chicks are taught to walk behind a keeper twice a day.

After 3 months of age, the instinct amongst chicks to kill each other diminishes and they may therefore be placed in communal groups. Management skills must be in place when introducing new chicks because disasters can happen rapidly.

## Health problems

Cranes are long living, and as adults seem to be remarkably free from the diseases that affect gallinaceous birds. In the author's experience, 95 per cent of the problems associated with cranes are related to trauma: cranes trying to scramble over fences and breaking legs; cranes chasing each other and running into trees or shrubs and breaking wings or legs; cranes getting into other cranes' enclosures and fighting. Mostly they are problems associated with the management of cranes in mixed collections, where the aesthetic appearance of enclosures is a consideration. Aggressive species should not be kept within sight of each other.

The problems associated with repair of leg fractures in cranes are similar to those with other long-limbed birds such as flamingoes and secretary birds – it is not so much the difficulty of the surgical procedure but the aftercare until the fracture has formed a solid union that is the problem.

The capture and restraint of birds with long thin legs housed in fairly large enclosures is always something of a nightmare for curators. The procedure used here is to erect some 1.8 m high portable wooden frames covered with shade cloth of the sort used in plant nurseries to form a small enclosure in one corner of the pen. Similar dense shade cloth is stretched out from the entrance to the enclosure, forming a

funnel similar to that used in game capture. The birds are then quietly walked into the funnel by staff linking hands or holding 1.2 m high shade cloth between them. When erecting the capture enclosure, care must be taken to see the shade cloth is on that side of the wooden frame closest to the birds to prevent wing injuries on the frames.

In this bird park it is the management's policy to place all birds, regardless of value, in situations where they have the opportunity to breed. The author feels it is the duty of all zoological institutions to endeavour to breed endangered and threatened species, thereby reducing the necessity for the trade in wild birds, and to pass on the information gained to other zoological institutions, private aviculturists and avian veterinarians.

## Reference

FORSHAW, J. M. (1973). *Parrots of the World*, 2nd edn. Lansdowne Editions.

## Recommended reading

JOHNSGARD, P. (1983). *Cranes of the World*. Indiana University Press.

RITCHIE, B. W., HARRISON, G. J. and HARRISON, L. R. (1994). *Avian Medicine: Principles and Application*. Wingers.



# Quick reference for drug dosing

Gerry M. Dorrestein

## Introduction

Most formularies for pet birds are based on information derived from studies in poultry, parrots or pigeons. The advised individual dosages and drinking water concentrations can be considered to be based on an average bodyweight of 4–500 gram and a drinking water intake of 40–60 ml/kg bw for birds of again 500 grams. Allometric scaling or metabolic dosing is based on the principle that amount of drug to be administered to animals is more related to daily energy use than to body weight. The average basal metabolic rate

as expressed by the formula  $BMR \text{ (kcal)} = K \cdot W^{0.75}$  of the passerine bird ( $K=129$ ) is 50 to 60 percent higher than those of non-passerines ( $K=78$ ) of the same body size. Based on the calculated daily energy use of the bird (Table 17.1) the amount of drug for treatment of that bird can easily be found (Table 17.2) expressed in mg/kcal.

In Table 17.3 drinking water concentrations are suggested, but when possible an even distribution of the dose over water and food should be considered.

**Table 17.1.** Conversion of body weight (g) to basal metabolism (kcal) for passerines (Pass) and nonpasserines (N-pass).

Bw (g)	Pass (kcal)	N-pass (kcal)	Bw (g)	Pass (kcal)	N-pass (kcal)	Bw (g)	Pass (kcal)	N-pass (kcal)	Bw (g)	Pass (kcal)	N-pass (kcal)
10	4	2	120	26	16	340	57	35	780	107	65
11	4	3	125	27	16	350	59	35	800	109	66
12	5	3	130	28	17	360	60	36	820	111	67
13	5	3	135	29	17	370	61	37	840	113	68
14	5	3	140	30	18	380	62	38	860	115	70
15	6	3	145	30	18	390	64	38	880	117	71
16	6	4	150	31	19	400	65	39	900	119	72
17	6	4	155	32	19	410	66	40	920	121	73
18	6	4	160	33	20	420	67	41	940	123	74
19	7	4	165	33	20	430	69	41	960	125	76
20	7	4	170	34	21	440	70	42	980	127	77
25	8	5	175	35	21	450	71	43	1000	129	78
30	9	6	180	36	22	460	72	44	1020	131	79
35	10	6	185	36	22	470	73	44	1040	133	80
40	12	7	190	37	22	480	74	45	1060	135	81
45	13	8	195	38	23	490	76	46	1080	137	83
50	14	8	200	39	23	500	77	46	1100	139	84
55	15	9	210	40	24	520	79	48	1125	141	85
60	16	9	220	41	25	540	81	49	1150	143	87
65	17	10	230	43	26	560	84	50	1175	146	88

Table 17.1. (Continued).

Bw (g)	Pass (kcal)	N-pass (kcal)	Bw (g)	Pass (kcal)	N-pass (kcal)	Bw (g)	Pass (kcal)	N-pass (kcal)	Bw (g)	Pass (kcal)	N-pass (kcal)
70	18	11	240	44	27	580	86	52	1200	148	89
75	18	11	250	46	28	600	88	53	1225	150	91
80	19	12	260	47	28	620	90	54	1250	153	92
85	20	12	270	48	29	640	92	56	1275	155	94
90	21	13	280	50	30	660	94	57	1300	157	95
95	22	13	290	51	31	680	97	58	1325	159	96
100	23	14	300	52	32	700	99	60	1350	162	98
105	24	14	310	54	32	720	101	61	1400	166	100
110	25	15	320	55	33	740	103	62	1450	170	103
115	25	15	330	56	34	760	105	63	1500	175	106

Table 17.2 Formulary (dosage regimen for common drugs used in avian practice expressed in mg/kcal)

Antibiotics and Chemotherapeutics	Routes	Dose	mg/kcal	Interval	Remarks
<i>tbBeta-lactams</i>					
cloxacillin	IM	2.16	4.31	24	
ampicillin-Na	IM		3.50	12-24	Gram-positives
ampicillin-trih.	PO		0.58	12-24	Gram-positives
	PO	2.80	4.08	12-24	Gram-negatives
amoxycillin-Na	IM		1.17	12-24	Gram-positives
			5.83	12-24	Gram-negatives
amoxycillin-trih.	PO		0.47	12-24	Gram-positives
	PO	2.55	4.46	12-24	Gram-negatives
AX-"long-acting"	IM		2.33	48	Gram-positives
amoxycillin/clavulanic acid (1)	IM		1.17	8-12	Gram-positives
	PO		2.33	8-12	Gram-positives
	IM		2.33	8-12	Gram-negatives
	PO		4.67	8-12	Gram-negatives
carbenicillin	PO	1.17	2.33	12	intestinal infections
	IM	2.55	5.10	8-12	synergistic aminoglycosides
	IV	2.55	5.10	8-12	
	IT		2.55	24	pseudomonas infections
ticarcillin	IM,IV	3.82	5.10	2-4	synergistic aminoglycosides
cefotaxime	IM,IV	1.62	2.16	6-8	
cefoxitin	IM,IV	1.08	1.62	6-8	
ceftriaxone	IM,IV	1.62	2.16	4-6	
ceftazidime	IM,IV	1.62	2.16	6-8	
ceftiofur	IM	1.08	2.16	6	
cephalothin	IM,IV		2.16	2-6	
cephalexin monhydr	PO	1.08	2.16	8	
		0.16	0.23	2-6	
cephradine	PO	0.75	1.08	6	
piperacillin	IM,IV		4.31	6-8	synergistic with aminoglycosides
		1.91	2.55	4-6	
<i>Polymyxins</i>					
polymixin B	PO		1000.00	12	

Table 17.2. (Continued)

<i>Aminoglycosides</i>					
neomycin	PO		0.22	24	
streptomycin	PO	0.64	1.28	24	
	PO	2.33	4.67	24	
kanamycin	IM	0.22	0.65	8-12	
	IM	0.22	0.43	12	
gentamycin	IM	0.05	0.22	6-12	nephrotoxicity
	PO		1.02	8-24	intestinal tract inf
amikacin	IM,IV	0.38	0.51	8-12	nephrotoxicity
		0.51	1.02	12-24	
tobramycine	IM,IV	0.05	0.11	12	
<i>Lincosamides, Macroliden, and Pleuromutilins</i>					
spectinomycin	IM,SC		0.58	8	
	PO	0.65	24		
	PO	1.92	3.21	24	flock treatment
lincomycin	PO	0.82	1.17	12-24	enteritis
lincomycin/spect	PO		1.08	24	overdose caused
	PO		2.33	24	death
clindamycin	IM	0.23	0.47	24	
	PO	1.17	2.33	8-12	
erythromycin	IM		0.58	24	
	PO		1.08	24	
spiramycin	IM	0.22	0.86	6-8	
	PO		1.08	24	
tylosin	PO	0.54	1.08	24	
	IM		0.58	24	
tiamulin	PO		1.17	24	
	IM		0.58	24	
oleandomycin	PO		1.17	24	
	PO		1.17	24	
<i>Chloramphenicol</i>					
chloramphenicol-succinate.	IM		2.33	6	
			1.27	8-12	
		1.08	1.72	12-24	
chloramphenicol.palmitate.	PO	1.27	2.55	6-12	
<i>Tetracyclines</i>					
chlortetracyclin	PO	0.93	1.17	8	grit
	PO	0.93	1.17	12	no grit
	Diet			45 days	
oxytetracyclin	IM,SC	0.32	1.08	12-24	tissue damage
	IM,SC	1.27	2.55	48-72	
tetracyclin	PO		1.27	8	
doxycyclin	PO		0.58	12grit	
	PO		0.18	12no grit	
doxycyclin (Vibramycin-IV)	IM,SC	1.75	2.33	5-7 days	
<i>Sulfonamides and Potentiators</i>					
trimethoprim	PO	0.35	0.47	8	
T + sulfatroxazole	PO	0.23	1.17	12	
T + sulfamethoxaz.	PO	0.23	1.17	24	
<i>Fluoroquinolones</i>					
flumequine	IM,PO		0.70	8-12	vomiting !
ciprofloxacin	PO,IM	0.32	0.43	12	
enrofloxacin	IM,SC	0.12	0.23	24	
	PO	0.23	0.47	12-24	
<i>Miscellaneous Antimicrobial drugs</i>					
furazolidone	PO	0.35	0.47	24	
furaltadone	PO	0.35	0.47	24	

Table 17.2. (Continued)

<i>Tuberculostatica</i> (in combination three or more drugs; initial therapy should include rifabutin, ethambutol, and either azithromycin or clarithromycin).					
isoniazid	PO	0.11	0.32	12	GI- and CNS disorder
rifampin	PO	0.22	0.43	12-24	
rifabutin	PO	0.38	1.15	24	
ethambutal	PO	0.32	0.65	12-24	for combination treatment
streptomycin	PO	0.51	1.02	24	
amikacin	IM	0.38	0.76	12-24	
ciprofloxacin/enrofloxacin	PO	0.38	0.76	12-24	
clofazamine	PO	0.15	0.31	24	
clarithromycin	PO		1.83	24	
azithromycin	PO		0.97	24	
<i>Antimycotic drugs</i>					
5-fluorocytosine	PO	0.76	1.27	6-12	icw amphotericin B 14-28 days 5-7 days
amphotericin B	IV		0.03	8-12	
amphotericin B	IT		0.02	8-12	
amphotericin B	PO		0.11	24	
caprillic acid	PO		5.39	24	
chlorhexidine	PO	0.11	0.22	24t	oxic for finches only disinfection equipment
enilconazole	aerosol			-	
fluconazole	PO	0.04	0.11	24	7-10 days
griseofulvine	PO		0.26	24	4-6 weeks, dermatomycosis
itraconazole	PO	0.13	0.25	12-24	14 days, in orange juice or 0.1N HCl
ketoconazole	PO	0.51	0.76	12	14-30 days ?liver damage?
miconazole	IM,IV	0.22	0.43	8-24	candida or cryptococcus inf.
nystatin	PO	2,500	7,500	8-12	7-10 days
ronidazol	PO	0.4			against flagellates
toltrazuril	PO	0.09			coccidiostat
<i>Miscellaneous drugs</i>					
deferoxamine	IM		1.28	24	Iron chelator used in toucans
insuline	IM	0.006	0.013	24	
<i>Antiparasitica</i> commonly used by the author					
chloroquine	PO	0.216	0.539	24	bloodparasites
clazuril	PO	0.108	0.216	24	coccidiostatic
dimetridazole	PO		0.065	24	against flagellates
fenbendazole	PO		0.032	24	anthelmintic
ivermectin	IM/PO		0.004	6 wks	anthelmintic
levamisole	PO		0.043	24	anthelmintic
metronidazole	PO		0.108	24	against flagellates
oxfenbendazole	PO		0.862	24	anthelmintic
praziquantel	PO	0.270	0.539	24	anthelmintic (trematodes and cestodes)
pyrmetamine	PO	0.011	0.022	24	bloodparasites, see spec protocol
ronidazol	PO		0.323	24	against flagellates
toltrazuril	PO		0.090	24	coccidiostatic

Adapted from Dorrestein, G.M.: Antimicrobial drug use in pet birds. In: Prescott, J.F., Baggot, J.D. (eds) *Antimicrobial Therapy in Veterinary Medicine*. Ames, IA, Iowa State University Press, 1993, p 490 with permission.

**Table 17.3.** Table for suggested starting drinkingwater concentrations (mg/l) based on the dosage in mg/kcal and a waterintake of 0.5 mg/kcal. The calculated water concentration should preferably be divided over water and food.

Amoxycillin (low level)	1 000	Levamisole	80
Amoxycillin (high level)	5 000	Lincomycin	100–200
Amoxycillin/clav. Acid (1)	3 000	Lincospectine	100–200
Ampicillin (low level)	1 000	Ketoconazole	1 000
Ampicillin (high level)	6 000	Metronidazole	200
Chloroquine	400	Neomycin	200
Chlortetracycline (2) (low level)	1 000	Polymyxin (IU)	3.000.000
Chlortetracycline (2) (high level)	2 500	Nystatin (5) (IU)	1.000.000
Dimetridazole (3)	100	Ronidazole	650
Doxycycline (2) with grit	1 000	Spectinomycin	1 000
Doxycycline (2) without grit	250	Spiramycin	2 000
Enrofloxacin (4)	200–400	Sulphachlor-pyrazin (3)	150
Erythromycin	125	Sulphadimidine (3)	150
Fenbendazole	50	Toltrazuril	150
Furazolidone	100–200	Trim/sulpha (6)	150–400
Ivermectin (3)	10	Tylosin	750

(1) calculated for amoxycillin part only; (2) for psittacosis/ornithosis at least 30 days; (3) toxic in higher concentrations; (4) for psittacosis/ornithosis 21 days; (5) for Candidiasis 3–6 weeks; (6) calculated for the trimetoprim part only

## Examples:

1. An amazon parrot 355 gram (Table 17.1, N-pass) uses 35 kcal/day receives amikacin IM (Table 17.2)  $35 \times 0.38 \text{ mg} = 13.3 \text{ mg/day}$  every 8 hours.
2. A mynah 210 gram (Table 17.1, Pass) uses 40 kcal/day receives praziquantel PO (Table 17.2)  $40 \times 0.27 = 10.8 \text{ mg/day}$  once.
3. A pigeon 450 gram (Table 17.1, N-Pass) uses 43 kcal/day receives amphotericin B PO (Table 17.2)  $43 \times 0.11 = 5.7 \text{ mg/day}$  every 24 hours.

## Reference

- DORRESTEIN, G.M. (2000) Passerine and softbill therapeutics. *Veterinary Clinics of North America: exotic animal practice*, **3**, 35–57.

---

# Index

- Abdominal distension, 126–7
- Abdominal examination, 33
- Abdominal fluid therapy, 90
- Accipiter cooperi* (Cooper's hawk), 193
- Accipiter gentilis* (goshawk), 193
- Accipiters, 180, 192
  - feet, 183
- Acetylsalicylic acid, 101
- Acuaria* (gizzard worms), 6, 329, 330
- Acuaria skrjabini*, 175
- Adenovirus infection
  - pigeons, 315
    - type I, 315–16
    - type II, 316–17
  - raptors, 199
  - seabirds, 351
- Adrenal corticotropic hormone (ACTH), 11
- Adrenal glands, 12
- Aegolius funereus* (saw-whet owl), 182
- Aeromonas*, 169
- African grey parrot (*Psittacus erithacus*), 113, 114–15, 118, 130, 131, 366
  - hypocalcaemia syndrome, 96
- Agapornis* spp. (lovebirds), 113, 119
- Aggression
  - cranes, 225–6, 383, 384
  - galliformes, 278
  - passerines, 153, 166
- Air sac infection, 126
- Air sac injections, 92–3
- Air sac intubation, 39, 97, 98
- Air sac mites (*Sternostoma tracheacolum*), 177
- Air sac worms, 126
- Air sacs, 9, 58
- Aix sponsa* (Carolina; wood duck), 236, 257
- Albumin:globulin ratio, 44
- Albumin, 44, 45
- Alca torda* (razorbill), 343
- Alcidae* (auks), 342
- Alectoris chukar* (Chukar partridge), 280
- Alectoris rufa* (red-legged partridge), 280
- Algal toxins
  - seabird poisoning, 354–5
  - waterfowl poisoning, 261
- Alkaline phosphatase, 45
- All-meat diet, 17, 19, 192
- All-seed diet, 21, 30, 117, 137
- Allopurinol, 134
- Alpha globulins, 45
- Amazon haemorrhage syndrome, 121
- Amazona aestiva*, 122
- Amazona* spp., 113, 115, 366
- American kestrel (*Falco sparverius*), 182, 196
- Amidostomum*, 237
- Amino acid requirements, 15–16
- Amoxicillin, 327
- Amphotericin B, 132, 138
- Amylase, 45
- Amyloidosis, 164
- Anaemia, post-fluid therapy, 86
- Anaesthesia, 38–42, 78
  - cranes, 216, 218
  - explorative laparotomy, 71
  - induction, 38
  - injectable agents, 39–40, 245
  - maintenance, 38–9
  - monitoring, 40–2
  - radiography, 53, 56
  - raptors, 202, 205
  - ratites, 230
  - surgical sexing, 67
  - waterfowl, 244–5
- Anaesthetic agents
  - injectable agents, 39–40, 245
  - volatile agents, 38
- Analgesia
  - trauma, 100
  - waterfowl, 245
- Anas actua* (pintail), 257
- Anas crecca* (teal), 257

- Anas platyrhynchos* (mallard), 235, 257  
*Anas platyrhynchos* (Peking duck), 257  
 Anatidae, 234–6  
 Anatini, 235–6  
 Anatomy, 1–14  
 Anhingas (*Anhingidae*), 342  
*Anodorhynchus hyacinthinus* (hyacinth macaw), 112, 367  
 Anorexia, 79  
     pigeons, 334  
     raptors, 211–12  
*Anseranas semipalmata* (magpie goose), 234  
 Anseranatidae, 234  
 Anserini, 235  
 Anthini, 236  
 Antibiotics, fluid therapy, 87  
 Antigen detection, 49–50  
 Aorta, 60  
*Aquila chrysaetos* (golden eagle), 196  
*Ara chloroptera*, 113  
*Ara nobilis*, 113  
*Ara* spp., 133  
 Aracaris, 296  
*Aratinga* spp., 114, 369  
 Arctic tern (*Sterna paradiseae*), 342  
 Arginine vasopressin, 11  
 Arteria pulmonalis, 60  
*Ascaridia*, 174, 175, 222, 329, 330  
 Asian saker falcon (*Falco cherrug*), 193  
 Aspartate aminotransferase, 46  
*Aspergillus fumigatus*, 50, 200  
*Aspergillus* infection  
     antigen detection, 49  
     cranes, 221  
     passerines, 171–2  
     psittacines, 126, 138  
         laryngeal, 125  
         lung/air sac, 125  
     ramphastids, 307  
     raptors, 200  
     seabirds, 351  
     serology, 49  
 Atoxoplasmosis, 172  
 Atropine, 97, 201  
 Auks (*Alcidae*), 342  
*Aulcorhynchus prasinus* (emerald toucanette), 297  
 Avian cholera, 246–7, 257  
 Avian pox  
     passerines, 166  
     pigeons, 318–20  
     raptors, 199  
     seabirds, 350–1  
 Avian tuberculosis  
     cranes, 220–1  
     passerines, 169  
     raptors, 199  
     waterfowl, 247  
 Avocado toxicity, 165  
*Aythya valisineria* (canvasback), 236  
 B cells, 12  
 Back examination, 33  
 Bacterial culture, 50  
 Bacterial hepatitis, 127, 128  
 Bacterial sensitivity testing, 50  
 Bald ibis, 382  
 Bali mynah (*Leucospa rothschildi*), 145  
 Barium sulphate double contrast studies, 55, 56  
 Barn owl, 180  
 Barnacle goose (*Branta leucopsis*), 235  
 Barred owl (*Strix varia*), 182  
 Basal metabolic rate  
     determination, 107–8  
     passerines, 145–6  
 Basilic (wing) vein access, 88  
 Beak  
     anatomy, 5  
     galliformes, 274  
     physical examination, 31–2  
     psittacines, 112, 142  
     raptors, 181  
 Beak injury, 101  
     haemorrhage, 100  
 Behavioural feather plucking, 34  
 Bengalese finch (*Lonchura striata domestica*), 145  
 Beta globulins, 45  
 Bewick swan (*Cygnus bewickii*), 244  
 Bicarbonate  
     fluid therapy, 86  
     serum level, 46  
 Bile acid serum level, 46  
 Bilirubin acid serum level, 46  
 Biotin requirement, 19  
 Bite wounds, 102  
 Black palm cockatoo (*Probosciger aterrimus*), 367  
 Black-hooded red Siskin (*Spinus cucullatus*), 144  
 Blood, 12, 43  
 Blood glucose, 47–8  
 Blood loss  
     monitoring during anaesthesia, 41  
     quantitation, 100  
     trauma, 100

- Blood parasites, 174
- Blood sampling  
 cranes, 218–19  
 passerines, 155–6, 157  
 psittacines, 122  
 ramphastids, 302  
 ratites, 230  
 waterfowl, 245
- Blood tests, psittacines, 122–3
- Blood transfusion, 86, 87  
 trauma management, 100
- Blood tubes, 36
- Blood urea nitrogen, 48
- Blue grouse (*Denragapus obscurus*), 274
- Body  
 physical examination, 33–4  
 radiographic imaging, 53
- Body temperature  
 monitoring during anaesthesia, 41  
 monitoring sick bird, 85  
 regulation in seabirds, 339
- Body weight monitoring in sick bird, 85
- Bone, 13  
 radiography, 56, 57
- Botulism  
 ibis, 383  
 seabirds, 353–4  
 waterfowl, 261
- Branta leucopsis* (barnacle goose), 235
- Breathing, 9  
 assessment in psittacines, 123, 124  
 monitoring during anaesthesia, 41
- Breeding  
 cranes, 384  
 flamingoes, 376  
 galliformes, 276–7, 281–2, 378–9  
 multi-species collections, 364  
 mynahs, 153–4  
 passerines, 151–3  
 psittacines, 119, 367–8  
 lorries/lorikeets, 366  
 ramphastids, 154, 301, 381  
 raptors, 186–7  
 incubation periods, 187  
 seabirds, 345  
 toucans, 154, 381  
 waterfowl, 238–41
- Bronchi, 9
- Brood patch, 4
- Brotgeris* spp., 113
- Brown pelican (*Pelicanus occidentalis*), 342
- Brown-headed parrot (*Poicephalus cryptoxanthus*), 113
- Brush-tongued parrots, 364
- Bubo virginianus* (great horned owl), 192
- Budgerigar fledgling disease virus 1 (BFDV-1), 138
- Budgerigar fledgling disease virus 3 (BFDV-3), 138
- Budgerigar (*Melopsittacus undulatus*), 113, 114, 116, 122  
 digestive problems, 132
- Bullfinch (*Pyrrhula pyrrhula*), 145
- Bumblefoot (pododermatitis)  
 raptors, 196–8  
 prevention, 197–8  
 waterfowl, 264
- Buprenorphine, 101
- Burns, 103
- Buteo jamaicensis* (red-tailed hawk), 192
- Buteo regalis* (ferruginous hawk), 192
- Buteo swainsoni* (Swainson's hawk), 192
- Buteos, 180, 181  
 feet, 183
- Butorphanol, 101
- Cacatua galerita* (sulphur-crested cockatoo), 113
- Cacatua leadbeateri* (Major Mitchell cockatoo), 367
- Cacatua* spp., 112
- Caeca, 7
- Cage examination, 27–8  
 droppings, 28–9  
 passerines, 157  
 psittacines, 120  
 digestive system diseases, 127
- Cages, 36  
 nursing environment, 75, 76
- Cairina moschata* (muscovy duck), 239, 257
- Calcitonin, 20
- Calcium deficiency  
 passerines, 162  
 psittacines, 135, 136
- Calcium requirement, 20, 21
- Calcium serum level, 46–7
- Cambendazole, 330
- Campylobacter fetus*, 168–9
- Canaries, 144  
 breeding, 151–2  
 diagnostic table, 159–60  
 drug dosage regimens, 158  
 housing, 148–9  
 sex identification, 152  
 singing ability, 147
- Canary (*Serinus canaria*), 144



- Candida albicans*, 35, 50, 161, 171, 200, 212, 307, 366  
*Candida* infection, 59, 132  
   cranes, 221  
   passerines, 171  
   psittacines, 138  
   ramphastids, 307  
   toucans, 171, 307  
 Canvasback (*Aythya valisineria*), 236  
 Capercaillie (*Tetrao urogallus*), 273, 275  
*Capillaria*, 133, 174, 175, 195, 222, 307, 329, 330  
 Capsules, 91  
 Capture myopathy  
   cranes, 225  
   ratites, 374–5  
 Carbohydrate requirements, 16–17  
 Carbon dioxide poisoning, passerines, 165  
 Carbon monoxide poisoning, passerines, 165  
 Cardiogenic shock, 99  
 Cardiomegaly, 64  
 Cardiopulmonary arrest, 96–7  
*Carduelis carduelis* (goldfinch), 145  
*Carduelis chloris* (greenfinch), 145  
 Carolina duck (*Aix sponsa*), 236, 257  
*Carpodacus mexicanus* (house finch), 170  
 Carporfen, 87, 88  
*Caryospora*, 196  
 Cassowaries, 228, 372–3  
 Castings/casts, 6, 7, 186  
 Catecholamines, trauma-induced release, 100  
 Central nervous system disorders  
   psittacines, 135–7  
   raptors, 212–13  
*Centrocercus urophasianus* (sage grouse), 274  
 Chaffinch (*Fringilla coelebs*), 145  
 Charadriiformes, 342–3  
*Charmosyna* spp., 119  
*Chlamydia psittaci*, 50  
 Chlamydial infection, 30, 31, 92  
   antigen detection, 49  
   investigation, 50  
   mynahs, 170  
   passerines, 169–70  
   pigeons, 325–7  
   psittacines  
     digestive tract disease, 133  
     loriidae, 366  
     respiratory diseases, 124  
     samples for PCR, 123  
   ramphastids, 306  
   serology, 49  
*Chloebia gouldiae* (Lady Gouldian finch), 145  
 Chloride requirement, 21  
 Chloride serum level, 47  
 Choana, 5, 6  
 Choanal abscess, psittacines, 125  
 Cholesterol serum level, 47  
 Choline requirement, 19  
 Cholinesterase-inhibiting compound  
   poisoning, raptors, 200, 201, 212, 213  
*Chrysolophus pictus* (golden pheasant), 274  
 Chukar partridge (*Alectoris chukar*), 280  
 Circulatory collapse, 95  
 Circulatory system, 12  
   supportive care, 95  
*Circus cyaneus* (Northern harrier), 182  
 Cisapride, 129  
 Claw anatomy, 4  
   see also Talons  
 Claw disorders  
   haemorrhage, 100  
   psittacines, 142  
 Clazuril, 196, 330  
 Clinical history, 29–30  
 Clinical tests, 43–51  
 Cloaca  
   anatomy, 7–8  
   endoscopic examination, 66  
   physical examination, 33  
 Cloacal bursa of Fabricius, 12  
*Clostridium*, 220  
*Clostridium botulinum*, 261, 353, 354  
 Clotrimazole, 125, 138, 200  
*Cnematoptes* (scaly mite), 4, 31, 35, 176  
 Coccidiosis  
   cranes, 222  
   passerines, 172–3  
   pigeons, 330–1  
   raptors, 196  
 Cochlosomosis, passerines, 173–4  
 Cockatiel (*Nymphicus hollandicus*), 113, 114, 116, 118  
 Cockatoos, 113, 115, 366  
 Colloid fluid therapy, 87  
 Common eider (*Somateria mollissima*), 236  
 Common pheasant (*Phasianus colchicus*), 266, 274, 280  
 Common tern (*Sterna hirundo*), 351  
 Complete blood count, 43–4  
 Contour feathers, 2  
 Contusions, 102  
 Conures, 114, 369  
 Cooper's hawk (*Accipiter cooperi*), 193  
 Copper requirement, 20  
 Core body temperature, 41–2, 85  
 Cormorants, 342

- Corticosteroids  
 adverse effects, 88  
 fluid therapy, 87–8  
 topical administration contraindication, 93
- Corticosterone, 12
- Coternix japonica* (Japanese quail), 274
- Cranes, 215–26  
 aggression, 225–6, 383, 384  
 anaesthesia, 216, 218  
 biology, 215  
 blood collection, 218–19  
 breeding, 384  
 capture myopathy, 225  
 ectoparasites, 222  
 haematological values, 218  
 handling, 215–16, 217  
 infectious disease, 219–22  
 metabolic disorders, 219  
 neoplasia, 225  
 nutrition, 219, 223, 383–4  
 orthopaedic problems, 222–5, 385  
 adults, 224–5  
 chicks, 223–4  
 parasitic diseases, 221–2  
 tracheal morphology, 215, 216  
 zoological park management, 383–5
- Creatine kinase, 47
- Creatinine serum level, 47
- Crop  
 anatomy, 6  
 endoscopic examination, 66  
 physical examination, 32
- Crop feeding, 80
- Crop foreign body, 103, 104
- Crop swabs, 157
- Crop tubes, 36, 37
- Cross infection control, 77–8
- Cryptococcus neoformans*, 172
- Cryptosporidiosis, passerines, 173
- Crystalloid fluid therapy, 86–7
- Cyringophilus bipectinatus*, 35
- Cyanopsitta spixii* (Spix's macaw), 112
- Cyanoramphus novaezelandiae* (kakariki), 113
- Cyathostoma*, 193, 222, 237
- Cygnini, 235
- Cygnus bewickii* (Bewick swan), 244
- Cygnus buccinator* (trumpeter swan), 244
- Cygnus cygnus* (whooper swan), 240, 244
- Cygnus olor* (mute swan), 235, 240, 244, 361
- Cytodites nudus*, 177
- Cytology, 51
- Cytomegalovirus infection, 167
- Deferoxamine, 306
- Dehydration  
 assessment, 95  
 calcium serum level, 47  
 critical care, 95
- Delta-aminolevulinic acid dehydratase, 47
- Dendrocygna bicolor* (fulvous whistling duck), 234
- Denragapus obscurus* (blue grouse), 274
- Derma glyphys*, 35, 176
- Dermanyssus gallinae* (red mite), 35, 176
- Dermatophytes, 35  
 passerines, 172
- Devolcalization, 8
- Dextrans, 87
- Diabetes mellitus, ramphastids, 164, 303–4
- Diazepam, 141, 201
- Digital scales, 35–6, 78
- Dimetridazole, 328
- Disinfection of housing units, 78
- Divers (*Gaviidae*), 341
- Dorisiella*, 173
- Double-crested cormorant (*Phalacrocorax auritus*), 350
- Doxapram, 97
- Doxycycline, 92, 327
- Droppings examination, 28–9  
 pigeons, 313, 333  
 psittacines, 120–2  
 digestive system disorders, 127  
 surgical nursing, 86
- Drug dosing, 386–90  
 passerines, 158
- Duck viral enteritis, 247–58
- Ducks, 234, 235, 236
- Duodenostomy, 82–3
- Eagles, 180, 181
- Ears, 5  
 endoscopic examination, 66  
 physical examination, 32  
 raptors, 180
- Eastern equine encephalitis, 219
- Echinostoma*, 329, 330
- Ectoparasites  
 cranes, 222  
 passerines, 176–7  
 pigeons, 331, 332, 334–5  
 raptors, 196  
 seabirds, 351–2
- Egg binding  
 pigeons, 337  
 psittacines, 134, 135, 136–7  
 ultrasonography, 64–5

- Egg drop syndrome, galliformes, 295
- Egg formation, 10–11
- Eimeria* spp., 173, 222, 330, 331
- Electrophoresis, serum proteins, 44–5
- Elizabethan collar, 85
- Emerald toucanette (*Aulacorhynchus prasinus*), 297
- Emergency treatment, 94
  - drugs, 111
- Emus, 228, 373
- Endocrine system, 11–12
- Endoscopy, 65–72, 78
  - diagnostic procedures, 65–6
  - surgical sexing, 66–71
- Endotracheal intubation, 38–9
  - cardiopulmonary arrest, 96
- Endotracheal tubes, 8, 38, 78
- Enrofloxacin, 124, 128, 170, 221, 327
- Enteral feeding, 79–81
  - calculation of requirements, 106–7
- Enterobacter* spp., 161
- Enterococcus faecalis*, 169
- Environment assessment, 27–8
- Environmental enrichment, psittacines, 116
- Environmental nursing requirements, 74–8
  - cross infection control, 77–8
  - housing areas, 75–7
  - ventilation system, 77, 78
- Epinephrine, 97
- Equipment, 35–7, 78
- Erysipelothrix*, 170, 220
- Erythrocytes, 12, 43
- Erythrura psittacea* (parrot finch), 145
- Escherichia coli*, 127, 161, 366
  - passerines, 167–8
  - pigeons, 324–5
  - toucans, 167, 307
- Essential fatty acid requirements, 16
- Estrilda* spp., 153
- Ethanol toxicity, passerines, 165
- Eucoleus*, 222
- Explorative laparotomy, 71
  - anaesthesia, 71
  - presurgical preparation, 71
  - procedure, 71–2
- Eye examination, 31
  - raptors, 208–9
- Eyes, 4–5
  - raptors, 180
- Face masks for anaesthesia, 38
  - toucans, 155
- Faecal culture, 128
- Faecal examination, 28–9
  - colour, 28
  - monitoring sick bird, 84
  - parasites, 51
  - passerines, 157
  - psittacines, 121, 122
    - digestive system disorders, 127–8
  - raptors, 205
  - volume, 28–9
- Faecal flotation, 128
- Faecal microscopy, 128
- Falco cherrug* (Asian saker falcon), 193
- Falco columbarus* (merlin), 182, 192
- Falco mexicanus* (prairie falcon), 193
- Falco peregrinus* (peregrine falcon), 193, 195, 280
- Falco sparverius* (American kestrel), 182, 196
- Falcons, 180, 181
  - feet, 183
- Fat requirements, 16
- Fat/fatty acid imbalance, 16
- Fatty liver, passerines, 164
- Feather abnormalities
  - blue/green/grey colour change, 24
  - nutritional disorders, 24
  - pigeons, 337
  - psittacines, 141–2
  - raptors, 198
- Feather cysts, 165–6
- Feather loss, 34–5
  - psittacines, 140–1
- Feather plucking/picking, 24
  - passerines, 166
  - psittacines, 140, 141
- Feathers
  - anatomy, 1–3
  - physical examination, 32, 34–5
    - head, 32
  - raptors, 181–3
  - traumatic blood loss, 100
- Febantel, 330
- Fee for consultation, 26
- Feed medication, 91
- Feet
  - anatomy, 4, 146, 147
  - galliformes, 266
  - passerines, 146
  - psittacines, 112
  - raptors, 183–5
  - seabirds, 341
- Female reproductive system, 10–11
- Femur, 14
- Fenbendazole, 132, 133, 175, 194, 330
- Ferruginous hawk (*Buteo regalis*), 192

- Filoplume feathers, 3
- Finches, 144–5  
 breeding, 152  
 parasitic species, 153  
 sex identification, 152–3
- Fishing tackle injuries, waterfowl, 262–3
- Flamingoes, 375–7  
 breeding, 376  
 feeding, 375–6  
 pathology, 376–7
- Flight feathers, 2
- Flight muscles, 13–14
- Fluid supplementation, 80
- Fluid therapy, 86–90, 108  
 abdominal approach, 90  
 antibiotics, 87  
 colloids, 87  
 contraindications, 88  
 corticosteroids, 87–8  
 crystalloids, 86–7  
 fluid requirement calculation, 108–9  
 intraosseous approach, 88–9  
 intravenous approach, 88  
 oral approach, 90  
 passerines, 156  
 psittacines, 109  
 raptors, 210  
 seabirds, 346–7  
 subcutaneous approach, 90  
 supportive care of critically ill patient, 95  
 trauma management, 100  
 waterfowl, 245
- Flunexritine, 141
- Flunixin, 87, 101
- Folic acid requirement, 19
- Force-feeding, 80
- Foreign bodies  
 metallic, 59  
 tracheal  
 psittacines, 125–6  
 tracheoscopy, 65  
 upper alimentary canal, 103–4
- Fractures  
 appendicular skeleton, 102–3  
 radiography, 57  
 ratites, 374
- Francolis, 271
- Frankelia*, 196
- Fratercula arctica* (puffin), 343
- Freckled duck (*Stictonetta naevosa*), 235
- Frigate birds (*Fregatidae*), 342
- Fringilla coelebs* (chaffinch), 145
- Frounce, 194–5
- Fulmar (*Fulmarus glacialis*), 342, 350
- Fulvous whistling duck (*Dendrocygna bicolor*), 234
- Fungal culture, 50
- Fungal infection  
 cranes, 221  
 mynahs, 171–2  
 passerines, 171–2  
 psittacines, 138–9  
 ramphastids, 171–2, 307  
 raptors, 200  
 seabirds, 351  
 toucans, 171–2
- Fusarium* mycotoxins, 221
- Gall bladder ultrasonography, 62
- Galliformes, 266–95  
 aggression, 278  
 alimentary canal, 274  
 biology, 275  
 breeding, 276–7, 281–2, 378–9  
 egg drop syndrome, 295  
 housing, 275, 282, 377  
 hygiene, 282, 293  
 infectious diseases, 283–93, 294, 379  
 integument, 273–4  
 management problems, 282  
 nutrition, 278–9, 293, 377–8  
 reproductive system, 274–5  
 respiratory system, 274  
 sex determination, 281  
 skeleton, 266, 273  
 taxonomy, 266, 267–73  
 zoological park collection management, 377–9
- Gallus gallus* (red jungle fowl), 274
- Gallus sonneratii* (grey jungle fowl), 274
- Gamma globulins, 45
- Gamma glutamyl transferase, 47
- Gannets (*Sulindae*), 342
- Gastrointestinal contrast radiography, 55–6
- Gastrointestinal disorders  
 nutritional imbalance, 22  
 psittacines, 127–33
- Gastrointestinal tract  
 anatomy, 5–8  
 galliformes, 274  
 passerines, 146–7  
 pigeons, 312–13  
 radiography, 59–60  
 raptors, 185–6  
 ratites, 228–9  
 seabirds, 341  
 softbills, 147  
 ultrasonography, 63

- Gavage feeding, 80–1  
 oral fluid therapy, 90  
 volume/frequency, 107
- Gavia immer* (loon), 354
- Gaviidae* (divers), 341
- Gaviiformes, 341–2
- Geese, 234, 235
- Gender determination *see* Sex determination (sexing)
- Geopetitia aspiculata*, 175
- Giardia* spp., 51, 132  
 passerines, 174  
 toucans, 311
- Gizzard, 6  
 galliformes, 274
- Globulin, 45
- Glossy ibis, 382
- Glucagon, 12, 16
- Glucose serum level, 47–8
- Glutamate dehydrogenase, 48
- Goitre, 21
- Golden eagle (*Aquila chrysaetos*), 196
- Golden pheasant (*Chrysolophus pictus*), 274
- Goldfinch (*Carduelis carduelis*), 145
- Gonads  
 endoscopic examination for sexing, 69–70  
 radiography, 60
- Goshawk (*Accipiter gentilis*), 193
- Gout  
 psittacines, 134  
 seabirds, 348  
 waterfowl, 264
- Gracula religiosa* (Indian Hill Mynah), 144, 145
- Gracula* spp., 144, 145
- Gram's stain, 51, 128
- Grass parakeets (*Neophema* spp.), 18, 113
- Great horned owl (*Bubo virginianus*), 192
- Grebes (*Podicipitidae*), 341
- Greenfinch (*Carduelis chloris*), 145
- Grey hen (*Lyrus tetrix*), 274
- Grey jungle fowl (*Gallus sonneratii*), 274
- Grey partridge (*Perdix perdix*), 280
- Grouse, 269–70
- Growth deficit, 24
- Grus americana* (whooping crane), 215, 223
- Grus canadensis* (sandhill crane), 215, 223
- Guillemot (*Uria aalge*), 343, 350, 351, 361
- Guinea fowl, 273, 377
- Gulls (*Laridae*), 342
- Hadeda ibis, 382–3
- Haematological values  
 cranes, 218  
 passerines/softbills, 158  
 raptors, 207  
 ratites, 233  
 seabirds, 357  
 waterfowl, 246
- Haematopus ostralegus* (oyster catcher), 350
- Haemochromatosis, 20, 59
- ramphastids, 162–4, 304–6, 381–2
- Haemoproteus* spp., 174
- Haemorrhage, 100
- Haemorrhagic enteritis, passerines, 165
- Halogenated hydrocarbons, accumulation in  
 seabirds, 352–3
- Halothane, 38
- Hand rearing of psittacines, 120, 368  
 hand feeding, 371  
 protocol, 369–71
- Handling, 27, 30  
 cranes, 215–16, 217  
 critically ill patient, 94  
 mynahs, 156  
 passerines, 155  
 pigeons, 312  
 psittacines, 371–2  
 ramphastids, 156, 302  
 raptors, 202, 205  
 ratities, 373–4  
 seabirds, 345–6  
 toucans, 156  
 waterfowl, 242, 243  
*see also* Restraint
- Harpyrhynchus*, 176, 198
- Harris' hawk (*Parabuteo unicinctus*), 192
- Hawks, 180
- Head  
 physical examination, 31–2  
 radiographic imaging, 54, 55
- Head trauma, 99, 103  
 treatment protocol, 111
- Hearing, 5
- Heart, 12  
 monitoring during anaesthesia, 41  
 physical examination, 33  
 radiography, 60  
 ultrasonography, 63–4
- Heart sounds, 33  
 cardiopulmonary arrest, 97  
 psittacines, 124
- Heating source, 37
- Heavy metal assays, 51
- Heavy metal poisoning  
 passerines, 165  
 seabirds, 353

- Helmeted guinea fowl (*Numida meleagris*),  
     273  
 Helminth parasites  
     passerines, 174–6  
     pigeons, 329–30  
     seabirds, 352  
 Hen harrier (*Circus eyaneus*), 280  
 Hepatic neoplasms, 62  
 Hepatomegaly, 58  
 Hermaphrodites, 70  
 Herpesvirus infection  
     passerines, 167  
     pigeons, 317–18  
     psittacines, 137  
     raptors, 198  
     seabirds, 351  
 Heterophils, 12, 43  
*Hexamita columbae*, 328  
 Hexamitiasis, pigeons, 328–9  
 Histomoniasis, 7  
 Holocrine glands, 3, 4  
 Hornbills, 379–80  
 Hospitalization  
     advantages, 74  
     cross infection control, 77–8  
     disadvantages, 74–5  
     intensive care, 75  
     intensive care units, 76–7  
     isolation units, 76  
     record keeping, 83  
     seabirds, 346–8  
     ventilation system, 77, 78  
 House finch (*Carpodacus mexicanus*), 170  
 Housing, 75–7  
     galliformes, 275, 282, 377  
         hygiene, 282, 293  
     passerines, 148–9  
     psittacines, 115–16, 367  
         lories/lorikeets, 365  
     raptors, 187–92  
         enclosure minimum size requirements,  
             189–91  
         species safely housed together, 192  
     seabirds, 343–5  
         hospitalization, 346  
     softbills, 148–9  
     toucans, 297–9, 381  
     waterfowl, 236–7  
 Humerus, 13  
 Hyacinth macaw (*Anodorhynchus  
     hyacinthinus*), 112, 367  
*Hydrobatidae* (storm petrels), 342  
 Hygiene-related problems, passerines, 165  
*Hymenolepsis*, 329  
 Hyperglycaemia, 47  
     traumatic stress response, 100  
 Hyperparathyroidism, secondary nutritional,  
     20, 57–8, 192  
 Hypertonic saline, 87  
 Hypocalcaemia, 20  
     psittacines, 137  
         African grey parrots, 96  
*Hypochera* spp., 153  
 Hypoglycaemia, 17  
 Hypoproteinaemia, post-fluid therapy, 86  
 Hypothermia  
     neonatal/young waterfowl, 241  
     supportive care of critically ill patient, 95  
 Hypovolaemic shock, 98–9  
  
 Ibis, 382–3  
 Imaging techniques, 52–72  
 Immune response deficit, 24  
 Imping, 182  
 Inappetance *see* Anorexia  
 Inclusion body disease of cranes, 219–20  
 Indian Hill Mynah (*Gracula religiosa*), 144,  
     145  
 Infection  
     antigen detection, 49–50  
     microbiology, 50–1  
     serology, 49  
 Infectious diseases  
     galliformes, 283–93, 294, 379  
     passerines, 166–77  
     pigeons, 313–35  
     ramphastids, 306–7  
     seabirds, 348, 349, 350–2  
     transmission prevention in hospital, 77–8  
     waterfowl, 246–58  
 Influenza virus infection  
     passerines, 167  
     seabirds, 351  
 Information sources, 37  
 Infusion pumps, 88  
 Injection sites  
     passerines, 156  
     ramphastids, 302  
 Insulin, 12  
 Integument  
     anatomy, 3–4  
     galliformes, 273–4  
 Intensive care units, 76–7  
 Intermittent positive pressure ventilation  
     (IPPV), 39  
 Intestinal anatomy, 7  
 Intramuscular injections, 92

- Intraosseous catheterization, 88–9  
 Intratracheal injections, 92–3  
 Intravenous fluid therapy, 88  
 Intravenous injections, 92  
 Iodine deficiency, psittacines, 137  
 Iodine requirement, 21  
 Iron deficiency anaemia, 20  
 Iron requirement, 20  
 Iron serum level, 48  
 Iron storage disease *see* Haemochromatosis  
 Isoflurane, 37, 38, 40, 67, 71, 78, 202, 205, 230, 244  
 Isolation units, 76  
*Isospora canaria*, 172  
*Isospora laxazei*, 172  
*Isospora serini*, 172  
 Itraconazole, 138, 200, 221  
 Ivermectin, 194, 330
- Jackass penguin (*Sphenicus demersus*), 361  
 Japanese quail (*Coturnix japonica*), 274  
 Jardine's parrot (*Poicephalus guilielmi*), 124  
 Jugular vein catheterization, 88
- Kakapo (*Strigops habroptilis*), 112  
 Keel musculature examination, 32–3  
 Keel-billed toucan (*Ramphastos sulfuratus*), 145, 296  
 Kestrels, 192  
 Ketamine, 216  
 Ketoconazole, 138  
 Ketoprofen, 87  
 Kidneys, 11  
   radiography, 60  
 Kiwis, 228  
*Klebsiella*, 127, 161, 366  
 Kyphosis, 57
- Laboratory equipment, 78  
 Laboratory tests, monitoring sick bird, 84–5  
 Lacerations, 102  
 Lactate dehydrogenase, 48  
 Lactated Ringer's solution, 86  
 Lady Gouldian finch (*Chloebia gouldiae*), 145  
*Lagonosticta* spp., 153  
*Lagopus lagopus scoticus* (red grouse), 274, 279–80  
*Lamprospreo superbus* (superb glossy starling), 145  
*Lamprotornis purpureus* (purple glossy starling), 145
- Laridae* (gulls), 342  
 Laryngeal aspergillosis, 125  
 Larynx, 8  
 Lead poisoning, 51  
   passerines, 165  
   psittacines, 135–6, 139  
   raptors, 200–1, 212, 213  
   seabirds, 353  
   waterfowl, 258–61  
 Legs, 14  
   anatomy, 4  
   examination, 32, 33  
   radiographic imaging, 54, 55  
*Leucocytozoon*, 174  
*Leucospar rothschildi* (Bali; Rothschild's mynah), 145  
 Levamisole, 330  
 Library access, 37  
 Lice  
   passerines, 176  
   pigeons, 331  
*Lichenostomus melanops* var. *cassidix* (helmeted honeyeater), 19  
 Limbs  
   examination, 32, 33  
   seabirds, 340–1  
 Lipase serum level, 48  
 Lipomas, 23–4  
 Liquid oral medication, 91  
 Liquified diets, 79–80  
*Listeria monocytogenes*, 170  
 Liver  
   biopsy, 66  
   endoscopic examination, 66  
   radiography, 58–9  
   ultrasonography, 61–2  
*Lonchura punctulata* (spice finch), 145  
*Lonchura striata domestica* (Bengalese finch), 145  
 Loon (*Gavia immer*), 354  
 Lories, 114, 364–6  
   breeding, 366  
   housing, 365  
   nutrition, 365–6  
   pathology, 366  
 Lorikeets, 114, 364–6  
   breeding, 366  
   housing, 365  
   nutrition, 365–6  
   pathology, 366  
 Lovebirds (*Agapornis* spp.), 113, 119  
 Low body weight, 24  
 Low condition/starvation in raptors, 212

- Lung sounds, 33  
 cardiopulmonary arrest, 97  
 psittacines, 124
- Lungs, 8  
 physical examination, 33
- Lymphatic system, 12–13
- Lymphocyte count, 44
- Lyrus tetricus* (grey hen), 274
- Macaws, 112–13, 115, 366
- Magnesium requirement, 20
- Magpie goose (*Anseranas semipalmata*), 234
- Maintenance energy requirement (MER), 108
- Major Mitchell cockatoo (*Cacatua leadbeateri*), 367
- Male reproductive system, 9–10
- Mallard (*Anas platyrhynchos*), 235, 257
- Manganese requirement, 21
- Manx shearwater (*Puffinus puffinus*), 350
- Medial metatarsal vein access, 88
- Medication administration, 90–4  
 nebulization, 93–4, 109  
 oral, 91  
 via feed/water, 91–2  
 parenteral, 92–3  
 topical, 93
- Medullary bone, 13, 56
- Megabacteriosis, passerines, 170–1
- Melanin stimulating hormone (MSH), 11
- Melopsittacus undulatus* (budgerigar), 113, 114, 116, 122  
 digestive problems, 132
- Mental support, nursing care, 79
- Mercury poisoning, seabirds, 353
- Mergini, 236
- Mergus serrator* (red breasted merganser), 236
- Merlin (*Falco columbarus*), 182, 192
- Mesotocin, 11
- Metabolic bone disease, toucans, 302–3
- Metabolic disorders, 162–5
- Metallic foreign body, 59
- Methoxyflurane, 38
- Metronidazole, 132, 195, 328, 329
- Meyer's parrot (*Poicephalus meyeri*), 113
- Microbiology, 50–1
- Micropsitta*, 112, 116
- Microscope, 37, 78
- Microsporium* spp., 172
- Microsporium gallinae*, 35
- Mineral nutrients, 20–1  
 psittacines, 117
- Monitoring sick bird, 83–5  
 body temperature, 85
- laboratory tests, 84–5  
 observation, 83–4  
 preliminary evaluation, 83
- Monk parakeet (*Myiopsitta monachus*), 119
- Multi-species collection management, 364–85  
 breeding, 364  
 cranes, 383–5  
 flamingoes, 375–7  
 gallinaceous birds, 377–9  
 hornbills, 379–80  
 ibis, 382–3  
 nutrition, 364  
 psittacines, 364–72  
 larger species, 366–8  
 lorries/lorikeets, 364–6  
 smaller species, 369  
 ratites, 372–5  
 roseate spoonbills, 383  
 toucans, 380–2
- Murres *see* Guillemot
- Muscle, 13  
 nutritional imbalance disorders, 23
- Muscovy duck (*Cairina moschata*), 239, 257
- Musculoskeletal system, 13–14  
 raptors, 186
- Mute swan (*Cygnus olor*), 235, 240, 244, 361
- Mycobacterium*, 307, 311
- Mycobacterium avium*, 133, 169, 199, 201, 220, 237, 247
- Mycobacterium genavense*, 169
- Mycobacterium tuberculosis*, 220
- Mycobacterium-avium-intracellulare*, 169
- Mycoplasma gallisepticum*, 170
- Mycoplasma* infection  
 investigation, 50  
 passerines, 170  
 psittacines, 124
- Mycotoxicosis  
 cranes, 221  
 waterfowl, 261
- Myiopsitta monachus* (monk parakeet), 119
- Mynahs, 144, 145  
 breeding, 153–4  
 haemochromatosis, 162–4  
 handling, 156  
 housing, 149  
 nutrition, 150  
 sex identification, 154  
 vocal mimicry, 148
- Nares, 8  
 endoscopic examination, 66  
 physical examination, 31



- Nasal flushes, 93  
 Nasal salt gland, 21, 339  
 Nebulized medication, 93–4, 109  
 Neck  
   physical examination, 32  
   radiographic imaging, 54  
 Needles, 37, 78  
 Nematodes  
   passerines, 174–5  
   pigeons, 329–30  
   raptors, 195  
   seabirds, 352  
*Neophema* spp. (grass parakeets), 18, 113  
 Neoplasia, cranes, 225  
 Nets, 37  
 Neurological signs, nutritional disorders, 17, 23  
 Neurological system, 12  
 Newcastle disease  
   psittacines, 137  
   seabirds, 350  
 Niacin requirement, 19  
 Non-steroidal anti-inflammatory drugs (NSAIDs), 87  
 Northern harrier (*Circus cyaneus*), 182  
 Northern mite (*Ornithonyssus sylvarium*), 177  
*Numida meleagris* (helmeted guinea fowl), 273  
 Numididae, 266, 273  
 Nursing sick bird, 74–104  
   cross infection control, 77–8  
   discharge, 104  
   emergency treatment, 94  
   drugs, 111  
   environmental requirements, 74–7  
   equipment, 78  
   feeding, 79–83  
   fluid therapy, 86–90  
   follow-up, 104  
   medication, 90–4  
   mental support, 79  
   monitoring, 83–5  
   supportive care of critically ill patient, 94–6  
     checklist, 105  
     surgical nursing, 85–6  
 Nutrition, 14–22  
   cage assessment, 28  
   clinical history-taking, 30  
   cranes, 219, 223  
   flamingoes, 375–6  
   galliformes, 278–9, 293, 377–8  
   multi-species collection management, 364  
   nursing care, 79–83  
     duodenostomy, 82–3  
     gavage/tube feeding, 80–1  
     liquified diets, 79–80  
     oesophagostomy, 82  
   passerines, 149–50  
   practical aspects, 21–2  
   psittacines, 116–19, 367  
     lories/lorikeets, 365–6  
   ramphastids, 299–300, 381  
   raptors, 192–3  
   ratites, 229  
   recommended allowances, 15  
   seabirds, 346  
     sick birds, 346–7  
   softbills, 150  
   stomach anatomy, 6  
   waterfowl, 237–8  
     intensive care/convalescence, 238  
 Nutritional allowances, recommended, 15  
 Nutritional disorders, 22–4  
   digestive, 22  
   general ill health, 23  
   musculoskeletal, 23  
   neurological signs, 23  
   passerines, 161–2  
   reproductive disorders, 23  
   respiratory, 22–3  
   skin, 23  
   softbills, 161–2  
   sudden death, 23  
*Nymphicus hollandicus* (cockatiel), 113, 114, 116, 118  
  
 Obesity, 23–4  
 Observations, monitoring sick bird, 83–4  
*Oceanites oceanicus* (Wilson's storm petrel), 342  
 Odontophoridae, 266, 272  
 Oesophageal foreign body, 103  
 Oesophagostomy, 82  
 Oesophagus  
   anatomy, 6  
   endoscopic examination, 66  
   physical examination, 32  
 Oil contamination of seabirds, 355–6  
   hand washing technique, 356–7, 359–61  
   post-release survival, 361  
   survival to release, 361  
 Omphophlebitis, waterfowl, 241  
 Operculum, 8  
 Oral cavity examination, 32  
 Oral fluid therapy, 90  
 Oral medication, 91

- Organochloride pesticides toxicity, raptors, 200
- Organophosphate poisoning, pigeons, 337
- Ornithonyssus sylvarium* (white; Northern mite), 176
- Ornithosis *see* Chlamydial infection
- Oropharynx anatomy, 5–6
- Orthopaedic problems, cranes, 222–5, 385
- Osprey (*Pandion haliaetus*), 182
- Ospreys, 180  
feet, 183
- Osteomalacia, 57
- Osteoporosis, 20
- Ostriches, 228
- Ovarian cyst, 70
- Ovaries, 10  
endoscopic examination for sexing, 69–70
- Oviduct, 10
- Ovulation, 10  
calcium serum level, 47
- Owls, 180, 181, 182  
feet, 183  
gastrointestinal tract, 185–6
- Oxygen therapy  
cardiopulmonary arrest, 96  
supportive care of critically ill patient, 95–6
- Oxytetracycline, 92
- Oxytocin, 135, 137
- Oxyura jamaicensis* (ruddy duck), 236
- Oxyura leucocephala* (white-headed duck), 236
- Oxyurini, 236
- Oyster catcher (*Haematopus ostralegus*), 350
- Pacheco's disease, 30, 58, 137
- Packed cell volume interpretation, 110
- Pagoda starling (*Temenuchus pagodarum*), 145
- Pain, trauma response, 100
- Pancreas, 12
- Pandion haliaetus* (osprey), 182
- Panic attack, 102
- Pantothenic acid requirement, 19
- Papilloma virus infection  
passerines, 166–7  
psittacines, 129
- Parabuteo unicinctus* (Harris' hawk), 192
- Paradise whydah (*Steganura spp.*), 153
- Parakeets, 113
- Paralysis, psittacines, 136
- Paramyxovirus infection  
passerines, 167  
pigeons, 313–15  
psittacines, 135, 136, 137  
*see also* Newcastle disease
- Parasitic finches, 153
- Parathyroid hormone, 20
- Parenteral medication, 92–3
- Parrot finch (*Erythrura psittacea*), 145
- Parrots, 113  
diet, 116  
pet birds, 114–15  
wobbly/convulsant, 135–7
- Partridges, 271, 377  
management on shooting estates, 280–1
- Passerines, 144–78  
aggression, 153  
amyloidosis, 164  
anatomy/physiology, 145–8  
basal metabolic rate, 145–6  
blood collection, 155–6  
breeding/sexing, 151–3  
parasitic species, 153  
diagnostic procedures, 156–61  
clinical examination, 157  
necropsy, 157–8, 161  
diagnostic table, 159–60  
digestive tract, 146–7  
digits, 4  
drug dosage regimens, 158  
fatty liver, 164  
feather cysts, 165–6  
haematological values, 158  
haemorrhagic enteritis, 165  
handling, 155  
housing, 148–9  
hygiene-related problems, 165  
infectious disease, 166–77  
injection sites, 156  
metabolic disorders, 162–5  
nutrition, 149–50  
nutritional disorders, 161–2  
serum biochemical values, 158  
singing ability, 147  
toxycosis, 165  
vitamin deficiencies, 161–2  
vocal mimicry, 148  
water intake, 146  
zoonotic diseases, 177
- Pasteurella multocida*, 102, 170, 220, 246
- PCR tests, 123
- Peafowl, 269, 377
- Peking duck (*Anas platyrhynchos*), 257
- Pelecaniformes, 342
- Pelicans (*Pelicanidae*), 342
- Pelicanus occidentalis* (brown pelican), 342
- Pellets, 186
- Pelvis, 14
- Penicillium griseofulvin*, 171

- Perches, nursing environment, 76  
*Perdix perdix* (grey partridge), 280  
 Peregrine falcon (*Falco peregrinus*), 193, 195, 280  
 Pericardial effusion, 64  
*Phaethon lepturus* (white-tailed tropic bird), 350  
*Phalacrocorax aristotelis* (shag), 350  
*Phalacrocorax auritus* (double-crested cormorant), 350  
 Phallus, 9  
   ratites, 229  
 Phasiandidae, 266, 267–9  
*Phasianus colchicus* (common pheasant), 266, 274, 280  
 Pheasants, 267–9, 377  
   management on shooting estates, 280–1  
 Phosphorus requirement, 20  
 Phosphorus serum level, 48  
 Physical examination, 26, 30–5  
   body, 33–4  
   head, 31–2  
   neck, 32  
   plumage, 34–5  
   skin, 34–5  
 Pigeons, 312–37  
   anatomy, 312–13  
   anorexia, 334  
   central nervous system signs, 335  
   droppings examination, 313, 333  
   ectoparasite infestations, 331, 332, 334–5  
   egg binding, 337  
   feather abnormalities, 337  
   handling, 312  
   helminth infections, 329–30  
   infectious diseases, 313–35  
   mortality, 336  
   non-infectious disease, 335, 337  
 Pinching off, 198  
 Pineal body, 12  
 Pintail (*Anas actua*), 257  
*Pionus* spp., 113, 125, 369  
 Pituitary gland, 11  
*Plasmodium*, 174  
*Platycercus* spp. (rosellas), 113  
 Plectropterinae, 235  
*Plectropterus gambensis* (spur-winged goose), 235  
 Plume (down) feathers, 3  
 Pneumatic bone, 13, 56  
 Podicipediformes, 341–2  
*Podicipitidae* (grebes), 341  
 Pododermatitis *see* Bumblefoot  
*Poephila guttata* (zebra finch), 145  
*Poicephalus cryptoxanthus* (brown-headed parrot), 113  
*Poicephalus guilielmi* (Jardine's; red-fronted parrot), 124  
*Poicephalus meyeri* (Meyer's parrot), 113  
*Poicephalus senegalus* (Senegal parrot), 113  
 Poisoning  
   passerines, 165  
   psittacines, 139  
   raptors, 200–1  
 Polydipsia, 29  
   psittacines, 133  
 Polyomavirus infection  
   antigen detection, 49–50  
   passerines, 166–7  
   psittacines, 138  
   samples for PCR, 123  
 Polyphagia, 24  
 Polytetrafluoroethylene (PTF) poisoning  
   passerines, 165  
   psittacines, 126, 139  
 Polyuria, 29  
   pigeons, 313, 335  
   psittacines, 134  
*Porrocaecum*, 174, 175  
 Positive pressure ventilation, 96  
 Potassium serum level, 48  
 Powder down feathers, 3  
 Power line injuries, waterfowl, 263  
 Prairie chicken (*Tympanuchus cupido*), 274  
 Prairie falcon (*Falco mexicanus*), 193  
 Pre-albumin, 44  
 Preen gland *see* Uropygial gland  
 Preening, 2  
   seabirds, 340  
   following oil contamination/washing, 360  
*Probosciger aterrimus* (black palm cockatoo), 367  
 Procellariiformes, 342  
 Propatagium, 13, 14  
*Prosthogonium*, 176  
 Protein deficiency, 16  
 Protein excess, 16  
 Protein requirements, 15–16  
 Protozoal infection, passerines, 172–4  
 Proventricular dilatation disease (PDD), 59  
   psittacines, 28, 29, 128–9  
 Pruritus, psittacines, 141  
*Pseudomonas*, 127, 366  
   passerines, 169  
 Pseudotuberculosis (yersinosis)  
   mynahs, 168  
   passerines, 168

- psittacines, 131–2
- ramphastids, 307
- Psittacine beak and feather disease (PBFD), 30, 34, 137–8, 142
  - antigen detection, 50
  - samples for PCR, 123
- Psittacine proventricular dilatation syndrome (PPDS), 28, 29, 128–9
- Psittacines, 112–42
  - beak disorders, 142
  - breeding, 119, 366, 367–8
    - lories/lorikeets, 366
  - central nervous system disease (wobbly/convulsant parrot), 135–7
  - claw disorders, 142
  - clinical examination, 120
    - bacteriological samples, 123
    - blood samples, 122–3
    - droppings, 120–2
    - regurgitation, 122
    - samples for PCR tests, 123
  - digestive system diseases, 127–33
    - examination, 127–8
  - digits, 4
  - environmental enrichment, 116
  - fluid therapy, 109
  - fungal diseases, 138–9
  - gender determination (sexing), 119
  - hand rearing, 120, 368
    - hand feeding, 371
    - protocol, 369–71
  - handling, 371–2
  - housing, 115–16, 367
  - infectious viral diseases, 137–8
  - multi-species collection management, 364–72
  - nesting, 119–20
  - nutrition, 116–19, 367
    - lories/lorikeets, 365–6
    - minerals, 117
    - protocol for dietary change, 118–19
    - vitamin supplements, 117
  - pet birds, 114–15
  - poisons, 139
  - reproductive system disease, 134–5
  - respiratory diseases, 123–7
  - skin disease, 139–42
    - baldness, 140–1
    - feather defects/damage, 141–2
    - pruritus, 141
    - pyoderma, 141
    - xanthoma, 141
  - urinary system disease, 133–4
  - uropylgial glands, 4
- Psittacosis, 58, 60
  - see also Chlamydial infection
- Psittacula krameri* (ring-necked parakeet), 114
- Psittacula* spp., 113
- Psittacus erithacus* (African grey parrot), 96, 113, 114–15, 118, 130, 131, 366
- Pteroclididae* (sand grouse), 273
- Puffin (*Fratercula arctica*), 343
- Puffinosis, 350
- Puffinus puffinus* (Manx shearwater), 350
- Pulse oximeters, 41
- Purple glossy starling (*Lamprolornis purpureus*), 145
- Pyoderma, 141
- Pyridoxine requirement, 19
- Pyrrhula pyrrhula* (bullfinch), 145
- Pyrrhura* spp., 114, 369
- Pytilia* spp., 153
  
- Quails, 271, 272
- Quill mites, 35
  - passerines, 176
  - raptors, 198
  
- Radiography, 52–61
  - contrast studies, 55–6
  - gastrointestinal tract, 59–60
  - heart, 60
  - liver, 58–9
  - raptors, 208
  - respiratory tract, 58
  - restraint, 52–3
  - skeletal system, 56–8
  - spleen, 59
  - standard views, 53–5
  - urogenital tract, 60–1
  - vascular system, 60
  - waterfowl, 242, 244
- Raillientina*, 329
- Rainbow-billed toucan (*Ramphastos sulfuratos*), 150
- Ramphastids, 296–311
  - anatomical variation, 296
  - biology, 296–7
  - blood collection, 302
  - breeding, 301
  - diabetes mellitus, 164, 303–4
  - diagnostic table, 308–11
  - diet, 299–300
  - handling/restraint, 302
  - housing, 297–9
  - infectious diseases, 306–7

- Ramphastids – *continued*  
 injection sites, 302  
 metabolic bone disease, 302–3  
 sex determination, 300–1  
 surgery, 302  
 zoonotic disease, 311  
*see also* Toucans
- Ramphastos sulfuratos* (rainbow-billed toucan), 150
- Ramphastos sulfuratus* (sulphur-breasted; keel-billed toucan), 145, 296, 303
- Ramphastos toco* (Toco toucan), 145, 296, 301
- Raptors, 180–213  
 anorexia, 211–12  
 assessment, 201–2, 204  
 checklist, 206  
 key observations, 204  
 ophthalmoscopy, 208–9  
 radiography, 208  
 biology, 180–1  
 breeding, 186–7  
 incubation periods, 187  
 bumblefoot, 196–8  
 central nervous system disorders, 212–13  
 dyspnoea, 212  
 ectoparasitic diseases, 196  
 endoparasitic disease, 193–6  
 faecal examination, 205  
 feather abnormalities, 198  
 feathers, 181–3  
 feeding, 192–3  
 feet, 183–5  
 gastrointestinal tract, 185–6  
 haematological values, 207  
 handling, 202, 205  
 history-taking, 203, 204–5  
 housing, 187–92  
 enclosure minimum size requirements, 189–91  
 species safely housed together, 192  
 infectious diseases, 198–200  
 injury treatment programme, 202  
 laboratory tests, 205, 208  
 low condition/starvation, 212  
 musculoskeletal anatomy, 186  
 serum biochemical reference values, 207  
 toxins, 200–1  
 trauma management, 209–11  
 fluid therapy, 210  
 stabilization protocol, 210  
 urine examination, 205  
 zoonoses, 201
- Ratites, 228–33  
 anatomical features, 228–9  
 capture myopathy, 374–5  
 developmental disorders, 231  
 digestive tract, 228–9  
 fractures, 374  
 haematological values, 233  
 health examinations, 230–1  
 history-taking, 231  
 infectious diseases, 232  
 nutrition, 229  
 parasitic diseases, 232  
 restraint/handling, 229, 374  
 sedation, 229–30  
 vital signs monitoring, 230  
 sex determination, 229  
 zoological park collections, 372–5
- Ravens, 180
- Razorbill (*Alca torda*), 343
- Receptionist booking of appointments, 27
- Recommended nutritional allowances, 15
- Record keeping, 83
- Rectal water absorption, 8, 11
- Red breasted merganser (*Mergus serrator*), 236
- Red grouse (*Lagopus lagopus scoticus*), 274  
 management on grouse moors, 279–80
- Red jungle fowl (*Gallus gallus*), 274
- Red muscle, 13
- Red-fronted parrot (*Poicephalus guilielmi*), 124
- Red-legged partridge (*Alectoris rufa*), 280
- Red-tailed hawk (*Buteo jamaicensis*), 192
- Referral, 37
- Reflexes, anaesthesia monitoring, 40
- Regurgitation, psittacines, 122
- Renal cysts, 64
- Renal disease, psittacines, 134
- Renal neoplasia, 64  
 psittacines, 134
- Reproductive disorders  
 nutritional imbalance, 23  
 psittacines, 134–5
- Reproductive system  
 female, 10–11  
 galliformes, 274–5  
 male, 9–10
- Respiratory diseases  
 critical care, 97–8  
 nutritional imbalance, 22–3  
 psittacines, 123–7  
 examination, 123–4  
 raptors, 212
- Respiratory system, 8–9  
 galliformes, 274  
 radiography, 58

- Restraint, 30  
   radiography, 52–3  
   ramphastids, 302  
   ratites, 229–30  
   waterfowl, 242, 243  
   *see also* Handling
- Rheas, 228, 372
- Rhinoliths, psittacines, 124
- Ring-necked parakeet (*Psittacula krameri*), 114
- Ronidazole, 328, 329
- Roseate spoonbills, 383
- Rosellas (*Platycercus* spp.), 113
- Rothschild's mynah (*Leucospa r rothschildi*), 145
- Roundworms, 132  
   passerines, 174–5  
   raptors, 195
- Royal tern (*Sterna maxima*), 350
- Ruddy duck (*Oxyura jamaicensis*), 236
- Sacred ibis, 382–3
- Sage grouse (*Centrocercus urophasianus*), 274
- Salmonella, 50, 128, 129, 220, 320, 321, 322
- Salmonella typhimurium*, 128, 129, 168, 366
- Salmonellosis, 30  
   passerines, 168  
   pigeons, 320–2  
   psittacines, 129
- Sand grouse (*Pteroclididae*), 273
- Sandhill crane (*Grus canadensis*), 215, 223
- Sarcocystis, 173, 196, 212
- Saw-whet owl (*Aegolius funereus*), 182
- Scarlet ibis, 382
- Schistosoma, 176
- Seabirds, 339–62  
   algal bloom toxicity, 354–5  
   biochemistry, 358  
   body temperature control, 339  
   botulism, 353–4  
   breeding, 345  
   cold climate adaptations, 340  
   die-offs/wrecks (mass mortality), 348  
   ectoparasites, 351–2  
   endoparasites, 352  
   environment, 343–5  
   feeding, 346  
   feet, 341  
   fluid therapy, 346–7  
   gastrointestinal tract, 341  
   gout, 348  
   haematological values, 357  
   halogenated hydrocarbons accumulation,  
     352–3  
   handling, 345–6  
   heavy metal poisoning, 353  
   hospitalization, 346–8  
   infectious diseases, 348, 349, 350–2  
   limb adaptations, 340–1  
   oil contamination, 355–6  
     hand washing technique, 356–7, 359–61  
     post-release survival, 361–2  
     survival to release, 361  
   preening, 340, 360  
   salt balance, 339  
   starvation/emaciation, 347  
   taxonomy, 341–3  
   trauma, 348  
   waterproofing, 339–40
- Secretary birds, 180
- Sedation  
   radiography, 53, 55, 56  
   ratites, 229–30  
   drug dosages, 230
- Selenidera maculirostris* (spot-billed toucan),  
 155, 301
- Selenium requirement, 21
- Semen, 9–10
- Semi-liquid diet, 80
- Semiplume feathers, 3
- Senegal parrot (*Poicephalus senegalus*), 113
- Senses, 4–5
- Serinus canaria* (canary), 144
- Serology, 49
- Serratospiculum*, 193
- Serum biochemistry, 45–9  
   monitoring sick bird, 84  
   passerines/softbills, 158  
   raptors, 207  
   seabirds, 358  
   waterfowl, 247
- Serum protein electrophoresis, 44–5
- Sex chromosomes, 11
- Sex determination (sexing)  
   galliformes, 281  
   mynahs, 154  
   passerines, 151–3  
   psittacines, 119  
   ratites, 229  
   surgical sexing, 66–71, 155, 301  
   toucans, 154–5, 300–1  
   ultrasonography, 64  
   waterfowl, 245–6
- Sex-linked inheritance, 11
- Shag (*Phalacrocorax aristotelis*), 350
- Shelduck (*Tadorna tadorna*), 235
- Shock  
   critical care, 98–9  
   treatment, 110

- Sight, 4–5  
 Singing ability, passerines, 147  
 Sinus flushes, 93  
 Sinusitis, psittacines, 124  
 Skeletal disorders, nutritional imbalance, 23  
 Skeletal system  
   galliformes, 266, 273  
   radiography, 56–8  
   seabird limbs, 340–1  
 Skin disorders  
   nutritional imbalance, 23  
   psittacines, 139–42  
 Skin examination, 34–5  
 Skuas (*Stercorariidae*), 342  
 Small-tailed whydah (*Tetranura* spp.), 153  
 Smell sensation, 5  
 Snowcocks, 271  
 Sodium requirement, 21  
 Sodium serum level, 48  
 Softbills, 144–78  
   anatomy/physiology, 145–8  
   digestive tract, 147  
   haematological values, 158  
   haemochromatosis, 162–4  
   housing, 148–9  
   metabolic disorders, 162–5  
   nutrition, 150  
   nutritional disorders, 161–2  
   serum biochemical values, 158  
   tracheal deviation, 148  
*Somateria mollissima* (common eider), 236  
 Somatostatin, 12  
*Sphenicus demersus* (Jackass penguin), 361  
 Spice finch (*Lonchura punctulata*), 145  
 Spinal needles, 37, 78  
*Spinus cucullatus* (black-hooded red Siskin), 144  
 Spiurooids, 175  
 Spix's macaw (*Cyanopsitta spixii*), 112  
 Spleen, 12  
   radiography, 59  
   ultrasonography, 62–3  
 Spot-billed toucan (*Selenidera maculirostris*), 155, 301  
 Spur-winged goose (*Plectropterus gambensis*), 235  
 Staff training, 37  
*Staphylococcus*, 220, 307, 366  
   passerines, 169  
*Staphylococcus aureus*, 50  
 Star-gazing syndrome, 212, 213  
 Starlings, 145  
 Starvation  
   raptors, 212  
   seabirds, 347  
 Starve out, neonatal/young waterfowl, 241  
*Steganura* spp. (paradise whydah), 153  
*Stercorariidae* (skuas), 342  
*Sterna hirundo* (common tern), 351  
*Sterna maxima* (royal tern), 350  
*Sterna paradiseae* (Arctic tern), 342  
*Sterninae* (terns), 342  
*Sternostoma tracheacolum*, 177  
 Stictinettinae, 235  
*Stictonetta naevosa* (freckled duck), 235  
 Stomach anatomy, 6–7  
 Storm petrels (*Hydrobatidae*), 342  
*Streptococcus*, 220, 307, 366  
   passerines, 169  
   pigeons, 322–4  
*Streptococcus gallolyticus*, 322–4  
 Stress  
   nursing care, 79  
   polyuria in pigeons, 335  
   trauma, 100–1  
 Stress marks, 198, 337  
*Strigops habroptilis* (kakapo), 112  
*Strix varia* (barred owl), 182  
 Subcutaneous fluid therapy, 90  
 Subcutaneous injections, 92  
 Sudden death, 23  
*Sulindae* (gannets), 342  
 Sulphonamides, 18, 331  
 Sulphur-breasted toucan (*Ramphastos sulfuratus*), 145, 296, 303  
 Sulphur-crested cockatoo (*Cacatua galerita*), 113  
 Superb glossy starling (*Lamprospreo superbus*), 145  
 Supportive care of critically ill patient, 94–6  
   checklist, 105  
 Surgical nursing, 85–6  
 Surgical sexing, 66–71  
   anaesthesia, 67  
   complications, 70  
   errors, 70–1  
   gonads, 69–70  
   presurgical preparation, 67  
   procedure, 67–9  
   toucans, 155, 301  
 Swainson's hawk (*Buteo swainsoni*), 192  
 Swans, 234, 235  
 Sweating disease, 168  
*Syngamus trachea* (gapeworm), 175, 193, 222, 237, 352  
 Syringe pumps, 88

- Syringeal aspergillosis, 139  
 Syringes, 36, 78  
 Syringitis, psittacines, 126  
*Syringophilus* spp., 142, 176  
 Syrinx, 8  
     passerines, 147  
     psittacines, 112
- T cells, 12  
 Tablets, 91  
 Tadorinae, 235  
*Tadorna tadorna* (shelduck), 235  
 Tail examination, 33  
 Talons, 183–5  
 Tapeworms  
     passerines, 175–6  
     pigeons, 329–30  
 Taste, 5  
 Taste buds, 5  
 Teal (*Anas crecca*), 257  
*Temenuchus pagodarum* (pagoda starling), 145  
 Temperature, nursing environment, 75  
 Terns (*Sterninae*), 342  
 Testes, 9  
     endoscopic examination for sexing, 69  
 Tetracycline, 162, 170  
*Tetrameres* (gizzard worms), 174, 329, 330  
*Tetanura* spp. (small-tailed whydah), 153  
*Tetrao urogallus* (capercaillie), 273, 275  
 Textbooks, 37  
*Thalassornis leuconotus* (white-backed duck), 235  
 Thoracic girdle, 13  
 Thrombocytes, 12, 43  
 Thyroid, 11–12  
 Thyroxine, 21  
 Tibiotarsus intraosseous catheterization, 89  
 Tick-borne viruses, 350  
 Timing of consultation, 26–7  
 Toco toucan (*Ramphastos toco*), 145, 296, 301  
 Toltrazuril, 196  
 Topical medication, 93  
 Total serum protein, 48  
 Toucanettes, 296  
 Toucans, 144, 145, 296–311  
     biology, 296–7  
     breeding, 154, 301, 381  
     diabetes mellitus, 164, 303–4  
     haemochromatosis, 162–4, 304–6, 381–2  
     handling, 156, 302  
     housing, 149, 297–9, 381  
     metabolic bone disease, 162, 302–3  
     nutrition, 150, 299–300, 381  
     sex identification, 154–5, 300–1  
     surgical sexing, 155  
     zoological park management, 380–2  
 Towels, 35, 75, 76  
 Toxoplasmosis, 173  
 Trachea, 8  
     cranes, 215, 216  
     swans, 244  
 Tracheal foreign bodies, 65  
     psittacines, 125–6  
 Tracheal plaque, 65  
 Tracheoscopy, 65–6  
 Transportation, 27  
 Trauma  
     blood loss, 100  
     cranes, 226  
     critical care, 99–103  
     golden period, 99  
     haemorrhage treatment, 100  
     pain/analgesia, 100  
     passerines, 166  
     pigeons, 335  
     raptors, 209–11  
     seabirds, 348  
     stress, 100–1  
 Trematodes  
     passerines, 176  
     pigeons, 329–30  
     raptors, 195  
*Trichomonas columbarum*, 194  
*Trichomonas gallinae*, 194, 327–8, 366  
*Trichomonas* infection, 6, 32  
     passerines, 173  
     pigeons, 327–8  
*Trichophyton* spp., 172  
 Trimethoprim-sulphonamide, 129, 168  
 Trumpeter swan (*Cygnus buccinator*), 244  
*Trypanosoma*, 174  
 Tube feeding *see* Enteral feeding  
 Tuberculosis, 58  
     psittacines, 133  
 Turkeys, 266, 271  
*Tympanuchus cupido* (prairie chicken), 274  
*Tyroglyphus farinae*, 176
- Ulna intraosseous catheterization, 89  
 Ultrasonography, 61–5  
     gall bladder, 62  
     gastrointestinal tract, 63  
     heart, 63–4  
     liver, 61–2  
     patient preparation, 61  
     spleen, 62–3  
     urogenital tract, 64–5



- Upper alimentary canal foreign body, 103–4  
*Uraeginthus* spp., 153  
 Urates, droppings assessment, 29  
   psittacines, 120, 121  
 Urea serum level (BUN), 48  
*Uria aalge* (guillemot), 343, 350, 351, 361  
 Uric acid excretion, 134  
 Uric acid serum level, 49  
 Urinalysis, 51  
 Urine  
   deposition, 8, 11  
   droppings assessment, 29  
   monitoring sick bird, 85  
   raptors, 205  
 Urogenital tract, 11  
   psittacine disorders, 133–4  
   radiography, 60–1  
   ultrasonography, 64–5  
 Urography, 56  
 Uropygial (preen) gland, 3, 4  
   physical examination, 34  
   psittacines, 112  
   seabirds, 340
- Vaporizer, 38  
 Vascular system radiography, 60  
 Vasogenic shock, 99  
 Venepuncture *see* Blood sampling  
 Vent anatomy, 7–8  
 Ventilation system, 77, 78  
 Vertebrae, 13  
 Viral infection  
   cranes, 219–20  
   investigation, 50–1  
   passerines, 166–7  
   psittacines, 137–8  
   ramphastids, 306  
   raptors, 198–9  
   seabirds, 350  
   waterfowl, 247–58  
 Vital signs monitoring, ratites, 230  
 Vitamin A deficiency, 4, 6, 17, 31, 32, 60  
   passerines, 161  
   psittacines, 137  
   respiratory diseases, 124  
 Vitamin A requirements, 17  
 Vitamin BU<sub>1</sub> (thiamine), 18–19  
 Vitamin BU<sub>6</sub> (riboflavin), 19  
 Vitamin BU<sub>12</sub> (cyanocobalamin), 19  
 Vitamin B deficiency, 17  
   passerines, 161  
   raptors, 212, 213  
 Vitamin C deficiency, passerines, 161–2  
 Vitamin D, 17, 18  
 Vitamin DU<sub>3</sub>, 20  
   deficiency  
     passerines, 162  
     psittacines, 135, 136  
   imbalance, 57  
 Vitamin deficiencies, passerines, 161–2  
 Vitamin E deficiency, 18  
   passerines, 161  
   psittacines, 137  
 Vitamin E requirements, 17–18  
 Vitamin K requirements, 18  
 Vitamin requirements, 17–19  
   fat-soluble vitamins, 17–18  
   water-soluble vitamins, 18–19  
 Vitamin supplements  
   psittacines, 117  
   seabirds, 346  
 Vitelline diverticulum, 7  
 Vocal mimicry, passerines, 148  
 Voice, 8  
   passerines, 147, 148  
 Vultures, 180
- Warfarin, 18  
 Water intake, 14–15  
   passerines, 146  
   raptors, 193  
 Water medication, 91–2  
 Waterfowl, 234–64  
   algal toxins, 261  
   anaesthesia, 244–5  
     injectable agents, 245  
   analgesics, 245  
   biochemistry, 247  
   botulism, 261  
   breeding, 238–41  
   bumblefoot (pododermatitis), 264  
   developmental syndromes, 242  
   differential diagnosis, 256  
   fishing tackle injuries, 262–3  
   fluid therapy, 245  
   gout, 264  
   haematological values, 246  
   handling/restraint, 242, 243  
   housing, 236–7  
   infectious diseases, 246–58  
   lead poisoning, 258–61  
   mycotoxicosis, 261  
   neonatal/young bird disorders, 241–2  
   nutrition, 237–8  
     intensive care/convalescence, 238  
   power line injuries, 263

- radiology, 242, 244
- sexing, 245–6
- taxonomy, 234
- venepuncture, 245
- Waterproofing, seabirds, 339–40
- Watery droppings, 8
  - pigeons, 313
  - psittacines, 121, 127
- Weight loss, monitoring sick bird, 85
- Wendyonella*, 173
- Whistling ducks, 234
- White mite (*Ornithonyssus sylvarium*), 177
- White muscle, 13
- White-backed duck (*Thalassornis leuconotus*), 235
- White-headed duck (*Oxyura leucocephala*), 236
- White-tailed tropic bird (*Phaethon lepturus*), 350
- Whooper swan (*Cygnus cygnus*), 240, 244
- Whooping crane (*Grus americana*), 215, 223
- Whydahs, 153
- Wilson's storm petrel (*Oceanites oceanicus*), 342
- Wings, 13–14
  - physical examination, 32–3
  - radiographic imaging, 54, 55
- Wood duck (*Aix sponsa*), 236, 257
- Xanthoma, psittacines, 141
- Xylazine, 216
- Yersinia* infection *see* Pseudotuberculosis
- Yolk sac problems, neonatal/young
  - waterfowl, 241–2
- Yolk sac retention, 241
- Yolk sac rupture, 242
- Yolk sacculitis, 241
- Zebra finch (*Poephila guttata*), 145
- Zinc requirement, 20–1
- Zinc supplementation, 79
- Zinc toxicity, 28, 51
  - passerines, 165
  - psittacines, 135, 139
  - waterfowl, 262
- Zoonoses, 30, 96
  - passerines, 177
  - ramphastids, 311
  - raptors, 201