

THE VALIDITY OF ULTRASOUND IN DIAGNOSING HYPERTROPHIC PYLORIC STENOSIS

Mehdi Alehossein¹, Faramarz Hedayat², Payman Salamati³,
Hooshang Akhtar Khavari⁴, Mansour Mollaeian⁵

ABSTRACT

Objectives: To evaluate the validity of ultrasound for diagnosis and exclusion of pyloric stenosis in the infants with nonbilious vomiting.

Methodology: In a cross-sectional study, 444 consecutive infants with clinical suspicion of pyloric stenosis were evaluated by ultrasound (US) and categorized as pyloric stenosis or not according measuring parameters as muscle thickness, muscle width and canal length of pylorus. Positive findings were confirmed at surgery; Negative findings were confirmed by means of follow up. Sensitivity, specificity and accuracy were calculated.

Results: Sensitivity, specificity and accuracy of ultrasound were 100% if pyloric muscle thickness of ≥ 3 mm was chosen as diagnostic. When muscle thickness more than 4mm was used, sensitivity, specificity and accuracy were 96%, 100% and 99.32% respectively.

Conclusions: Ultrasound is highly sensitive and specific if pyloric muscle thickness 3 mm is used as cut off point. By virtue of direct visualization of the pyloric muscle, ultrasound is method of choice for both the diagnosis and exclusion of pyloric stenosis in infants.

KEY WORDS: Diagnosis, Infant, Pyloric stenosis, Sensitivity and specificity, Ultrasonography.

Pak J Med Sci January - March 2009 Vol. 25 No. 1 65-68

How to cite this article:

Alehossein M, Hedayat F, Salamati P, Khavari HA, Mollaeian M. The Validity of Ultrasound in Diagnosing Hypertrophic Pyloric Stenosis. Pak J Med Sci 2009;25(1): 65-68

1. Mehdi Alehossein, Assistant Professor of Radiology,
 2. Faramarz Hedayat, Pediatric Specialist,
 3. Payman Salamati, Assistant Professor of Community Medicine,
 4. Hooshang Akhtar Khavari, Assistant Professor of Pediatric Gastroenterology,
 5. Mansour Mollaeian, Associate Professor of Pediatric Surgery,
- 1-5: Medical Sciences/ University of Tehran, Bahrami Hospital, Shaheed Kiaee St, Damavand Ave, Tehran 16417, Iran.

Correspondence

Payman Salamati,
Bahrami Children's Hospital,
Shaheed Kiaee Street, Damavand Avenue,
Tehran, Iran.
E- mail: psalamati@tums.ac.ir

* Received for Publication: June 20, 2008

* Accepted: November 16, 2008

INTRODUCTION

The diagnosis of infantile pyloric stenosis basically has been relegated to ultrasound in some centers. However, there is controversy about the role of ultrasound especially when the diagnosis is mostly relied on the muscle thickness. Hypertrophic Pyloric Stenosis (HPS) is a cause of non-bilious progressive vomiting between the first week and fifth month of life.^{1,2} HPS prevalence increases in male gender, in first child, white race, positive mother familial history, geographic districts, O and B blood groups and macrolid usage during pregnancy.^{2,3} Some of its differential diagnosis during infancy are; Pylorospasm, gastro esophageal reflux (GER), duodenal stenosis or obstruction and malrotation.^{1,2,4} Clinical exam (Olive sign), measuring gastric residue, endos-

copy, upper gastrointestinal series (UGI) and recently ultrasound are used for diagnosis.^{2,4,5} The clinical diagnosis of HPS has traditionally been made by palpation of an olive-shaped mass in the epigastrium, representing the hypertrophied muscle (49-87%).^{2,4} Imaging studies are indicated when the clinical findings are unclear or equivocal.¹

The use of ultrasound in the diagnosis of hypertrophic pyloric stenosis was first reported in 1977, by Teele and Smith by direct visualization of pyloric muscle.⁶ Since then however, controversy on the definition of the abnormal dimension(s) of hypertrophied muscle continues.^{1,4,7,8} Three, 3.5 and 4 mm are used as cut-off points for pyloric muscle thickness.^{1,2,4,8,9} According to the relation of HPS prevalence to race and geographic districts, this study was designed choosing appropriate pyloric measurement for Iranian infants.

METHODOLOGY

This is a cross-sectional study with simple sampling method. Four hundred and eighty five consecutive infants with progressive, non bilious vomiting and/or regurgitation were examined at our institution (Bahrami Children's Hospital - Tehran University of Medical Sciences) between October 1999 and November 2005. Forty one cases are excluded due to other findings which were confirmed as sepsis, metabolic disorder or not doing Ultrasound at all. Remaining 444 study population cases had Ultrasound at our center.

All images were obtained on a Siemens Sonoline 2 and G 50 US units with use of either 5, 7.5 or 10 MHZ transducers as sector, linear or curvilinear probes. All examination were performed by an attending radiologist with experience in children hospital. Infants were in supine or right posterior oblique position for better identification of pylorus in the longitudinal axis. Measurements were taken at the center of the pylorus, defined as the site of the pyloric lumen and identified by the double track sign of the pyloric mucosa to avert inaccuracy from tangential scans. The length of pyloric canal was measured from base of

duodenal cap to the gastric antrum. The width of the canal was measured from outer edge of the muscle in both sides including the double layer of mucosa & central lumen. The muscle thickness was measured in the standard manner, from the outer wall of the pyloric muscle to the outer edge of the mucosa, which thus included the thickness of one muscle layer and excluded the mucosa and lumen. (Fig-1)

A positive diagnosis of HPS was made when a persistent olive-like mass was found in place of the normal pyloric channel, with a muscle thickness of 3 mm or more (Figure 1). Three mm is used to including more cases and not missing them for surgery. Positive findings were confirmed surgically.

Negative diagnosis of HPS was made if either normal pylorus (consisted of an adjacent antrum and duodenal cap without as interposed, measurable canal length or muscle thickness was less than 2mm) or borderline cases with muscle thickness 2-3mm (Fig-2). For the latter cases, follow up ultrasound were performed to confirm pylorospasm or ongoing early HPS. All negative cases were confirmed by 6-week follow-up clinic visits or telephone calls and if needed repeating ultrasound or using UGI. Demographic data, gestational age, blood group, familial history, physical exam (olive sign) and coexistent anomalies were also determined.

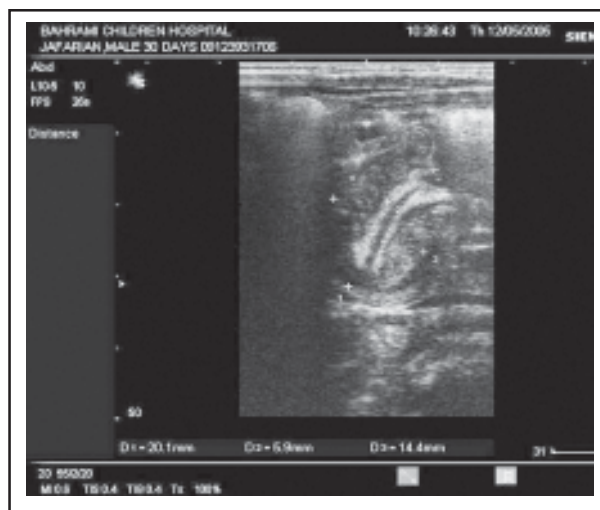


Fig-1: Longitudinal sonogram of the pyloric channel in an infant with pyloric stenosis. Canal length, anterior muscle thickness & width are numbered one to three respectively.

RESULTS

Four hundred forty four cases with non-bilious vomiting were evaluated by sonography. Seventy five patients were HPS positive with pyloric thickness of 3mm or more on Ultrasound. All cases were confirmed with surgery. Three cases had pyloric thickness between 2-3 mm without morphologic signs of HPS (pylorospasm). Therefore follow up ultrasound and observation was done. During two weeks pyloric thickness decreased below 2mm.

Three hundred and sixty six cases had normal pylorus which was confirmed by follow up. Eighty eight cases had GER, two cases had malrotation and one had duodenal web. Pyloric length was between 16-28 mm (20.22 ± 2.33), width 8.7-17 mm (13.14 ± 1.97) and thickness 3-6.50 mm (4.94 ± 0.65). The Histogram of pyloric muscle thickness is illustrated in Figure 3. Seventy five HPS-positive cases were aged 16-180 days (mean 40.26 ± 23.28 SD); which included 63 boys (84%) and 12 girls (16%). Their weight ranges were 1900-4300 gram (mean 3303.60 ± 499.89 SD). Seventy three cases (97.3%) were term and two (2.7%) preterm.

The most prevalent blood group was O+ by 33 cases (44%) and A+ by 15 cases (20%). Clinical olive sign was seen in 25 cases (33.3%). Horseshoe kidneys were seen in two and PDA

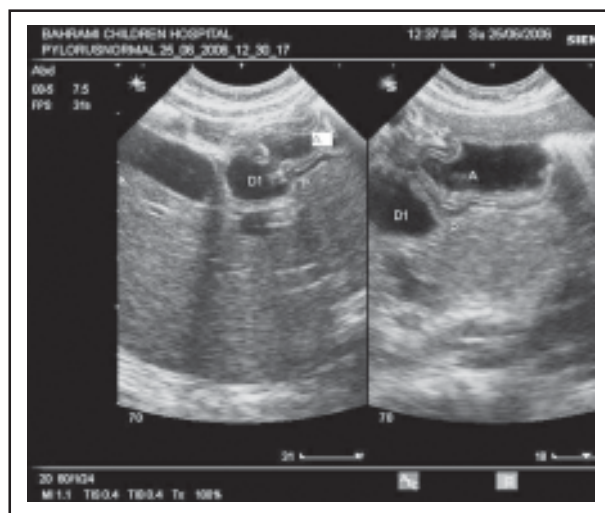


Fig-2: Longitudinal sonogram of normal pylorus (P) in relaxed (left sided image) & closed (right sided image) positions. D1= Duodenal cap, A = Distal antrum.

(patent ductus arteriosus) in one case. By choosing muscle thickness 3mm or more as diagnostic for HPS, sensitivity, specificity and accuracy were 100%. When muscle thickness more than 4mm was used, sensitivity, specificity and accuracy were 96%, 100% and 99.32%.

DISCUSSION

Infantile hypertrophic Pyloric Stenosis results from a defect in the pyloric contractility or relaxation, which result in hypertrophy of the antropyloric muscle.^{2,4,9} Accurate measurement of the antropyloric canal and its muscle is important in the diagnosis of HPS. Cohen and Haller suggested measuring the length, width and thickness of the pylorus for depicting HPS while muscle thickness is the most reliable measurement and the width is the least reliable one.^{4,10}

Mean of pyloric length in Assefa study on 39 patients was 19.1mm.¹¹ Wilson and Vanhoutte suggested the length higher than 20 mm diagnostic for HPS.¹² Our study shows 20.22 mm as mean of the length in HPS group. In Strauss study pylorus width more than 15mm was determined as abnormal.¹³ In Assefa study the mean of pyloric width was 14.05 mm.¹¹ In our study the mean was 13.14 ± 1.97 mm.

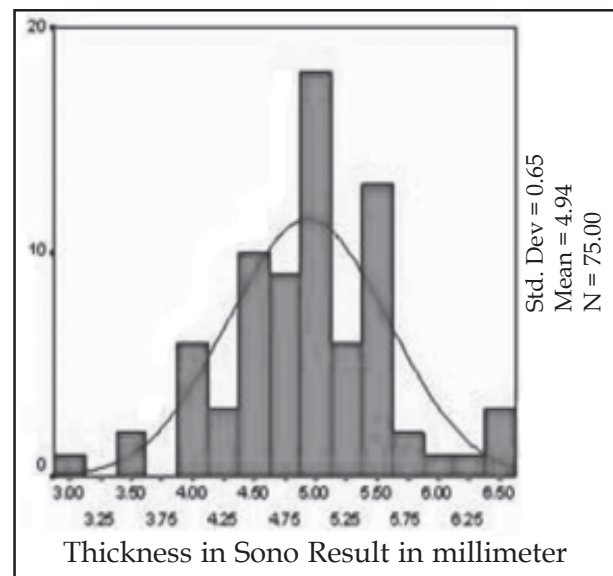


Fig-3: Histogram of pyloric muscle thickness at Ultrasound.

The mean of Pylorus muscle thickness was 4.46 mm in Assefa study.¹¹ In Blumhagen studies thickness more than 4mm was suggested as diagnostic for HPS.^{14,15} However Swischuk study concluded that muscle thickness 3mm or more as HPS, less than 2mm as normal and 2-3mm as borderline cases which need follow up.⁸

In our study pylorus muscle thickness was between 3-6.5mm by 4.94 ± 0.65 mm mean similar to other studies. With using muscle thickness 3mm or more as diagnostic for HPS, all 74 patients were HPS true positive (without false positive or false negative case). Our results were similar to Marta Hernanz-Schulman study in which sensitivity, specificity and accuracy were 100%.⁷ By using 4mm as cut off point for the diagnosis of HPS (according to Nelson text book 2004), we missed diagnosis of HPS in three cases which was surgically confirmed HPS and had muscle thickness between 3-4mm.

Demographic data including age and sex were also almost similar in our group with previous studies. However, blood groups O and B were the most prevalent blood groups among HPS patients in other studies.² In our study O+ 44% and A+ 20% were the most prevalent blood groups.

Palpation of Olive in Oates and Macdessi study was positive in 87% and it was 48% during 1988-1991.¹⁶ Clinical Olive sign was seen in 33.3% of our cases. In other studies positive Olive sign was between 40-100%.^{10,17} It seems that over the time physicians get more dependent on sonography.

In conclusion, Ultrasound is highly sensitive and specific if pyloric muscle thickness of 3mm is used as cut-off point. By virtue of direct visualization of the pyloric muscle, ultrasound is the method of choice for both diagnosis and exclusion of pyloric stenosis.

REFERENCES

1. Sivit C, Siegel M. Gastrointestinal tract: Siegel M. Pediatric Sonography. 3rd ed. Philadelphia: Lippincott Williams & Wilkins 2002;340-3.
2. Wyllie R. Pyloric stenosis and congenital Anomalies of the stomach, Nelson Textbook of Pediatric, Beherman, Kliegman, Genson: Saunders, USA. 2004;1229-31.
3. Headback G, Abrahamssonk, Husberg B. The epidemiology of infantile Hypertrophic pyloric stenosis in Sweden 1987-96. Arch Dis Child 2001;85(5):379-81.
4. Hernanz -Schulman M. Infantile Hypertrophic Pyloric stenosis, Radiology 2003;227:319-31.
5. Finkelstein M, Mandell G, Trabell K, Hypertrophic Pyloric stenosis: Volumetric of Measurement of Nasogastric Aspirate to determine the imaging modality. Radiology 1997;177:759-67.
6. Teele RL, Smith EH. Ultrasound in the diagnosis of idiopathic hypertrophic pyloric stenosis. N Engl J Med 1997;296:1149-50.
7. Hernanz-Schulman M, Sells LL, Ambrosino MM. Hypertrophic Pyloric Stenosis in the Infant without a Palpable Olive : Accuracy of Sonographic Diagnosis, Radiology 1994;193:771-6.
8. Okeefee FN, Stansberry SD, Swischuk LE. Antropyloric muscle thickness at ultrasound in infant: What is normal? Radiology 1991;178:827-30.
9. Kirks DR, Buonomo C, Taylor GA, Share JC. Gastrointestinal Tract, practical pediatric imaging: Diagnostic Radiology of Infants and Children, 13th ed. Philadelphia: Lippincott-Raven: 1998;899-903.
10. Haller J, Cohen H. Hypertrophic Pyloric Stenosis: diagnosis using us. Radiology 1986;161:335-9.
11. Assefa G: Sonographic diagnosis of hypertrophic pyloric stenosis. Preliminary experience: Ethiop Med J 2002;40:149-54.
12. Wilson DV, Vanhoutte JJ. The reliable sonographic diagnosis of Hypertrophic pyloric stenosis. J Clin Ultrasound 1984;12:201-4.
13. Strauss S, Manor A, Graif M. Sonography of Hypertrophic pyloric stenosis. AJR 1981;135:1057-105.
14. Blumhagen JD, Coombs JB, Ultrasound in diagnosis of Hypertrophic pyloric stenosis. J Clin Ultrasound 1981;9:289-92.
15. Blumhagen JD, Noble HG. Muscle thickness in Hypertrophic pyloric stenosis: Sonographic determination. AJR 1983;140:221-3.
16. Macdessi J, Oates R. Clinical diagnosis of pyloric stenosis; a declining art. BMJ 1993;306:553-5.
17. Stevenson RJ. Non-neonatal intestinal obstruction in children. Surg Clin North Am 1985;65:1217-34.